



Managing abnormal liver tests in children with inflammatory bowel disease

Patrick F. van Rheenen

Purpose of review

Liver test abnormalities in children with inflammatory bowel disease (IBD) are usually insidious in onset. By the time that symptoms referable to liver disease have appeared, the liver injury may be well advanced. It is, therefore, important that children with an incidental finding of abnormal liver tests are investigated in an appropriate and timely manner.

Recent findings

The most prevalent cause of liver test elevations in paediatric IBD is immune-related liver disease, including primary sclerosing cholangitis, autoimmune sclerosing cholangitis, and autoimmune hepatitis. Although less common, drugs used in the treatment of IBD can also cause liver injury. The diagnosis of drug-induced liver injury relies largely on excluding other causes of liver injury, such as viral hepatitis, nonalcoholic fatty liver disease, and biliary and vascular complications.

Summary

This review highlights an avenue to a step-wise approach for investigating children with IBD and silent liver test elevations. Central to the timing of diagnostic actions is grading the severity of liver test elevations.

Keywords

autoimmune hepatitis, autoimmune sclerosing cholangitis, drug-induced liver injury, paediatric, primary sclerosing cholangitis

INTRODUCTION

Inflammatory bowel disease (IBD) is a chronic inflammatory condition of the gastrointestinal tract with the principal forms being Crohn's disease and ulcerative colitis. A heterogeneous group of hepatobiliary manifestations can occur in IBD, ranging from a transient liver test abnormality to life-threatening liver failure [1,2^a,3]. Liver test abnormalities, which refers to levels outside the laboratory reference range, may already be present at diagnosis, or develop throughout the course of the disease. They tend to develop silently without any symptoms, or appear in combination with nonspecific symptoms (such as fatigue, nausea, anorexia, or pruritis) that go unnoticed in the patient with IBD. It is, therefore, important to perform a basic panel of liver blood tests in the treatment-naive patient with suspected IBD, and to repeat this periodically throughout the follow-up [4,5].

Children with IBD have an estimated risk of just under 10% to develop an immune-related liver disease, including primary sclerosing cholangitis (PSC), autoimmune sclerosing cholangitis (ASC) or autoimmune hepatitis (AIH) [6]. Several drugs used in

the treatment of IBD have been implicated in causing liver injury, with thiopurines, allopurinol, methotrexate, and anti-TNF agents being the most common but liver injury in children taking these drugs is rare. The diagnosis of drug-induced liver injury (DILI) relies largely on excluding other rare causes of liver injury (Table 1). In the following sections, we provide a step-wise approach for

Department of Pediatric Gastroenterology, Hepatology and Nutrition, University of Groningen, University Medical Centre Groningen - Beatrix Children's Hospital, Groningen, The Netherlands

Correspondence to Patrick F. van Rheenen, MD, PhD, Department of Pediatric Gastroenterology, Hepatology and Nutrition, University of Groningen, University Medical Centre Groningen - Beatrix Children's Hospital, PO Box 30001, 9700 RB Groningen, The Netherlands.
Tel: +31 50 3614147; e-mail: p.f.van.rheenen@umcg.nl

Curr Opin Pediatr 2021, 33:521–529

DOI:10.1097/MOP.0000000000001045

This is an open access article distributed under the terms of the Creative Commons Attribution-Non Commercial-No Derivatives License 4.0 (CCBY-NC-ND), where it is permissible to download and share the work provided it is properly cited. The work cannot be changed in any way or used commercially without permission from the journal.

KEY POINTS

- Transaminases, bilirubin (total and conjugated) and gamma glutamyl transferase should be determined in the treatment-naïve child with suspected IBD and then repeated periodically throughout the follow-up.
- Patients with IBD have a 10% risk to develop immune-related liver disease, including primary sclerosing cholangitis, autoimmune hepatitis, or autoimmune sclerosing cholangitis.
- Most agents used for the treatment of IBD have the potential to cause drug-induced liver injury.
- Moderate-to-marked liver test elevations should trigger immediate investigations of the aetiology.

investigating children with IBD who have an incidental finding of abnormal liver tests.

STEP 1: WHAT IS CONSIDERED A LIVER BLOOD TEST?

A basic panel of liver tests in children should include alanine aminotransferase (ALT), gamma glutamyl transferase (GGT), and total serum bilirubin (TSB),

together with tests of synthetic function, including albumin and the international normalized ratio (INR).

Alanine aminotransferase

ALT values outside the laboratory reference range suggest hepatocyte injury. ALT is more liver-specific than aspartate aminotransferase (AST), which is also present in cardiac and skeletal muscle, kidney, and brain. In children with a disproportionate elevation of AST compared with ALT, testing for creatine phosphokinase could help to detect muscle-derived AST. Establishing normal ranges for ALT in the paediatric population has been challenging because of differences in the definition of healthy controls and inter-laboratory variability. A recently published article that included over 8000 healthy Chinese children and adolescents showed that the true upper limits of normal (ULN; 30 U/l for boys and 24 U/l for girls) are significantly lower than previously thought [7].

Gamma glutamyl transferase

GGT is abundant in the liver, and also present in the kidney and intestine but not in bone.

Table 1. Causes of abnormal liver tests in children with inflammatory bowel disease and the accompanying biochemical profile

Causes	Biochemical profile		
	Hepatocellular	Cholestatic	Mixed type
	ALT ↑↑-↑↑↑ GGT =↑	ALT ↑ GGT ↑↑-↑↑↑	
Immune-related liver disease			
Autoimmune hepatitis (AIH)	☒	☐	☐
Primary sclerosing cholangitis (PSC)	☐	☒	☐
Autoimmune sclerosing cholangitis (ASC)	☐	☐	☒
Viral hepatitis			
Primary infection (Hep A/B/C/E, EBV, CMV)	☒	☐	☐
Reactivation Hep B (associated with anti-TNF or steroid use)			
Drug-induced liver injury (DILI)			
Mesalamine, thiopurines, allopurinol, methotrexate and anti-TNF	☒	☒	☒
Nonalcoholic fatty liver disease (NAFLD)			
Hepatic steatosis caused by obesity or starvation	☒	☐	☐
Biliary obstruction			
Bile stones	☐	☒	☐
Choledochal malformation			
Vascular liver disease			
Portal or hepatic vein thrombosis	☒	☐	☐
Other			
Celiac disease	☒	☐	☐
Wilson disease			
Alpha-1-antitrypsin deficiency			

In adults, GGT is measured to confirm the hepatic origin of an alkaline phosphatase elevation [8,9]. In children, on the other hand, GGT is the better marker for injury to biliary epithelium. Alkaline phosphatase is frequently elevated because of nonhepatic causes, such as rapid growth or vitamin D deficiency. The ULN for GGT was recently established in a cohort of over 3000 healthy German children and adolescents and is 27 U/l for boys and 18 U/l for girls [10].

Total serum bilirubin

Total serum bilirubin constitutes unconjugated and conjugated fractions. Elevations of either fraction lead to a rise in the total bilirubin concentration. A rise in the unconjugated fraction, in the absence of haemolysis, is almost always Gilbert’s syndrome, and is not associated with liver disease or ill health. Conjugated hyperbilirubinemia, on the other hand, is usually caused by parenchymal liver disease or obstruction in the biliary tract.

In healthy children and adolescents, the ULN for TSB is 1.0 mg/dl (17 µmol/l) irrespective of gender, and the unconjugated fraction is approximately 70% [11].

Markers of liver synthesis

Markers of hepatocellular function are albumin and PT. Albumin is exclusively synthesized by the liver and has a half-life of 3 weeks. Albumin concentrations (normal range 35–52 g/l) [12] are reduced in many clinical situations, including sepsis, systemic inflammation, malabsorption, and protein-losing enteropathy.

PT better reflects the actual synthetic function than albumin as it may already be prolonged within 24 h after significant liver injury. As the reagents to perform the PT vary between laboratories, PT is better expressed as an international normalized ratio (INR) to standardize results across different laboratories. The normal range of INR is 0.9–1.2 [13].

STEP 2: RETEST LIVER BIOCHEMISTRY (OR PROCEED WITH LIVER AETIOLOGY SCREEN)?

The first abnormal liver test should be interpreted with caution as it may not represent the true time of liver injury onset. The liver injury may already be advanced or subsiding when first identified. Grading of the liver test elevation is important to determine the timing of the next diagnostic step. The classification shown in Table 2 is based on the National Cancer Institute’s grading system of Common Toxicity Criteria for Adverse Events [14]. This system is useful for signal detection and identification of changes in liver tests at the individual level, although the cut-offs are somewhat arbitrary.

Retesting liver biochemistry is necessary to evaluate whether the liver injury is progressing or regressing. In the context of a child with IBD, who has no symptoms referable to liver disease and who has mild liver test elevations, it is reasonable to retest after 1 month. Mild abnormalities that persist after 1 month require further investigation. Moderate to marked elevations, or mild elevations combined with clinical symptoms (such as fatigue, pruritis, right upper quadrant pain, anorexia, and oedema in lower extremities) should trigger immediate investigations of the aetiology [9].

STEP 3: RECOGNITION OF THE BIOCHEMICAL PATTERN

The first abnormal liver test is generally the basis for establishing the liver injury type. The ratio between ALT and GGT can help recognizing the pattern and may point towards a different set of differential diagnoses [15]. A hepatocellular profile is characterized by a disproportionate elevation of ALT compared with GGT. Common causes include viral hepatitis, autoimmune hepatitis, and nonalcoholic fatty liver disease (NAFLD). In the absence of positive clues for these disorders, an evaluation for Wilson’s disease and alpha-1antitrypsin deficiency is warranted. A cholestatic profile is a disproportionate elevation of GGT compared with ALT, with or without elevated

Table 2. Grading of liver test elevations

Grading of elevation	Alanine amino transferase (ALT)	Gamma-glutamyl transferase (GGT)	Total serum bilirubin (TSB)
Upper limit of normal (ULN)	♂30 U/l ♀24 U/l	♂27 U/L ♀18 U/L	17 µmol/l (=1 mg/dl)
↑ Mild	>1–3× LN	>1–2.5× ULN	>1–1.5× ULN
↑↑ Moderate	>3–5× ULN	>2.5–5× ULN	>1.5–3× ULN
↑↑↑ Marked	>5× ULN	>5× ULN	>3× ULN

Table 3. Drugs used for the treatment of inflammatory bowel disease and the phenotype of liver injury they induce^a

IBD drug	Phenotype	Enzyme pattern			Latency	Discontinuation required?	Comment
		ALT	GGT	TSB			
Aminosalicylates	Serum enzyme elevations	↑-↑↑	↑-↑↑		Days-months	No	Usually transient and asymptomatic
Thiopurines (azathioprine, 6-mercaptopurine, 6-thioguanine)	Serum enzyme elevations	↑-↑↑	↑-↑↑		Days-months	No	Occurs shortly after starting therapy with thiopurines. Usually asymptomatic and resolves spontaneously without dose adjustments Measure 6-methylmercaptopurine
	Cholestatic hepatitis	↑	↑	↑↑	Week-months	Yes	Pruritis, often protracted. Usually self-limited. Some cases evolve into vanishing bile duct syndrome
	↓	↓	↓	↓			
	Vanishing bile duct syndrome	↑↑	↑↑↑	↑↑↑			The latter has a poor outcome requiring liver transplantation in many instances
	Nodular regenerative hyperplasia, peliosis hepatis and veno-occlusive disease	↑	↑		Years	Yes	Primarily related to long-term exposure to the active metabolite 6-thioguanine, causing proliferation of endothelial cells
Allopurinol	Hypersensitivity syndrome (cutaneous reactions) with liver involvement (50%)	↑↑↑			Weeks- months	Yes	Requires systemic corticosteroids to reduce widespread inflammation
Methotrexate	Hepatic steatosis	↑	↑		Months-years	Yes	Usually asymptomatic. Fatty liver on ultrasound. Can progress to fibrosis and cirrhosis. Supplementation with folic acid may lower rates of abnormal liver biochemistries
Anti-TNF (infliximab more than adalimumab)	Serum enzyme elevations	↑-↑↑	↑-↑↑		Days-months	No	Usually transient and asymptomatic
	Chronic hepatitis (immune-mediated)	↑↑		↑↑	Weeks-months	Yes	Insidious onset, may require corticosteroid treatment. Rarely relapses after steroid discontinuation

^aData have been gathered from the published literature [15,16,18[■],37]. ALT, alanine aminotransferase; GGT, gamma glutamyl transferase; TNF, tumour necrosis factor; TSB, total serum bilirubin.

TSB. Common causes include PSC and bile stones. DILI can present with a hepatocellular, cholestatic or mixed pattern (Table 1).

STEP 4: DISCONTINUE THE POTENTIALLY IMPLICATED DRUG?

Most drugs used for treatment of IBD have the potential to cause DILI [16]. Attributing abnormal liver tests to any of these drugs requires systematic evaluation. The Roussel Uclaf Causality Assessment Method is the most widely used tool to assess the likelihood of DILI [17]. Regardless of the method used, the major

diagnostic elements include time to liver test abnormality after the implicated drug has been started (latency), resolution after the drug is stopped (dechallenge), recurrence on re-exposure (rechallenge) and previous information on the drug’s potential for hepatotoxicity (likelihood) [18[■]]. Table 3 shows that each IBD drug causes its own typical liver injury, also known as ‘signature’. Differences in drug signatures are most strikingly related to differences in latency and biochemical injury pattern [19].

Critical thresholds of liver test elevations that should trigger immediate discontinuation of the implicated drug are not well established. The

biochemical observation by the late Hyman Zimmerman that drug-induced hepatocellular jaundice is a potentially life-threatening event has evolved into one of the most important clinical measures of hepatic safety [20]. Hy's Law, as it is affectionately referred to, states that ALT greater than $3 \times$ ULN in combination with TSB greater than $2 \times$ ULN in the absence of cholestatic injury should prompt immediate drug discontinuation [20,21]. In addition to this stopping rule, discontinuation of therapy is also advised in cases of marked ALT elevation ($>5 \times$ ULN) for more than 2 weeks in the absence of symptoms, or ALT greater than $3 \times$ ULN in combination with fatigue, nausea, vomiting, and right upper quadrant pain [21].

Rechallenge of a patient to a drug thought to be responsible for DILI is usually not advisable for fear of inducing an even more severe reaction. The strategy of switching to another drug in the same or related class to avoid recurrent hepatotoxicity is frequently executed in clinical practice but formal studies are lacking. Where no alternative therapies are available, re-exposure to the implicated drug will provide essential information to improve future care for the individual patient [20]. A drug rechallenge should be planned as an 'N-of-1 clinical trial'. The

SPENT checklist is recommended to ensure that relevant trial details have been considered [22**].

STEP 5: LIVER AETIOLOGY SCREEN

The timing of extended differential diagnostic actions depends on the severity of liver test elevations, as shown in Table 2. In fact, only in case of mildly raised liver tests and a high index of clinical suspicion that this is because of intercurrent illness, it is reasonable to retest liver biochemistry and delay the aetiology screen (Fig. 1). Moderate-to-marked elevations, mild abnormalities that persist after 1 month, and mild abnormalities co-occurring with liver-related symptoms should trigger immediate investigations of the aetiology.

The biochemical profile of the liver test abnormalities, as depicted in Table 1, may be useful to narrow down the extended aetiology checklist (Table 4).

Immune-related liver disease

Autoimmune hepatitis is a chronic inflammatory liver disease characterized by elevated transaminases,

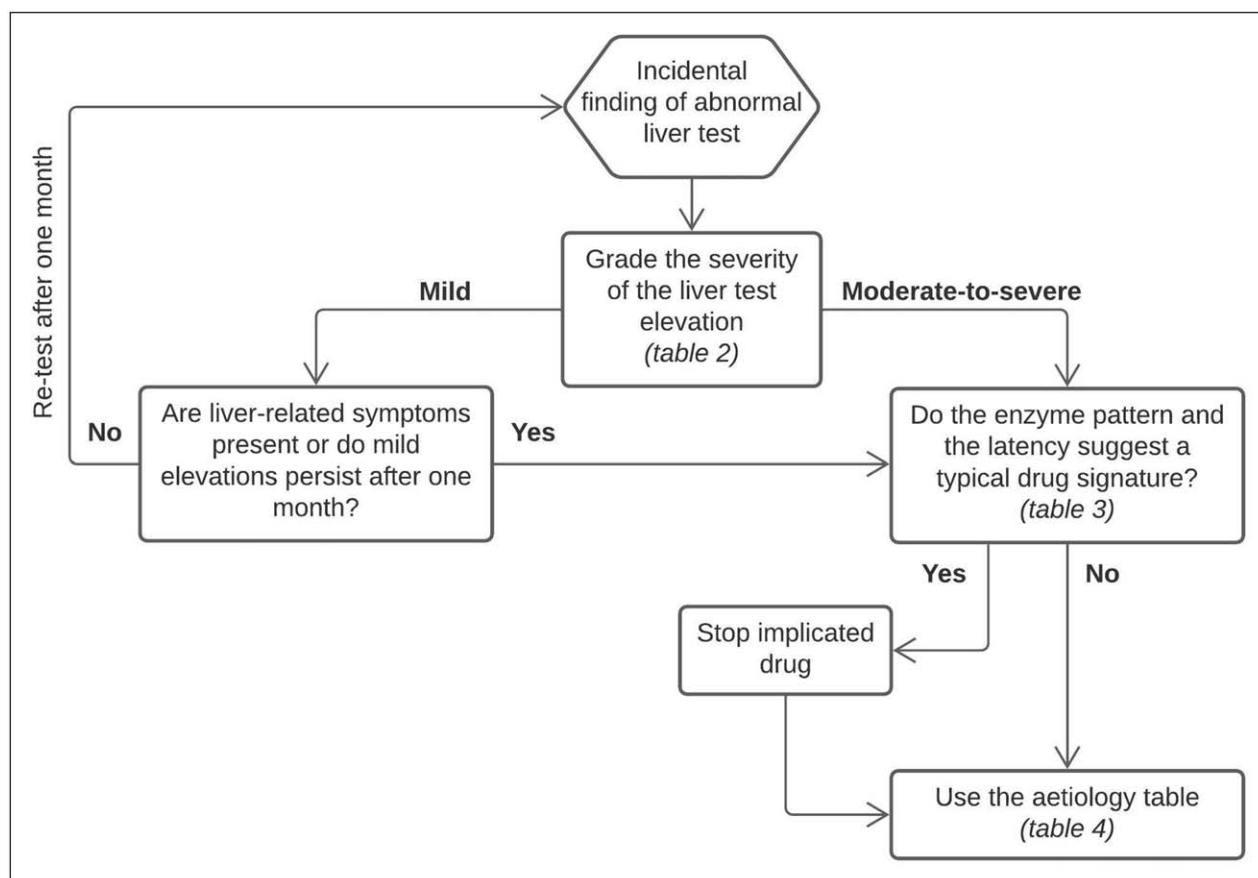


FIGURE 1. Step-wise approach for investigating children with inflammatory bowel disease and liver test elevations.

Table 4. Aetiology table and accompanying diagnostic work-up for children with IBD and nonacute abnormal liver blood tests

Causes	Diagnostic tests
Immune-related liver disease	
Autoimmune hepatitis (AIH)	<input type="checkbox"/> Auto-antibodies (antimitochondrial, antismooth muscle, antinuclear and antiliver-kidney-microsome) <input type="checkbox"/> Immunoglobulin G <input type="checkbox"/> Liver histology (interface hepatitis)
Primary sclerosing cholangitis (PSC)	<input type="checkbox"/> MR cholangiopancreatography
Autoimmune sclerosing cholangitis (ASC)	<input type="checkbox"/> Auto-antibodies (antimitochondrial, antismooth muscle, antinuclear and antiliver-kidney-microsome) <input type="checkbox"/> Immunoglobulin G <input type="checkbox"/> MR cholangiopancreatography <input type="checkbox"/> Liver histology (interface hepatitis and bile duct involvement)
Viral hepatitis	
	<input type="checkbox"/> Hepatitis A (IgM) <input type="checkbox"/> Hepatitis B (HBsAg, anti-HBc IgM, anti-HBs) <input type="checkbox"/> Hepatitis C (Anti-HCV, HCV RNA) <input type="checkbox"/> Hepatitis E (IgM, HEV RNA) <input type="checkbox"/> Cytomegalovirus (IgM, CMV-DNA) <input type="checkbox"/> Epstein–Bar virus (IgM, EBV-DNA)
Drug-induced liver injury (DILI)	
Thiopurines	<input type="checkbox"/> Thiopurine metabolite levels [6-thioguanine nucleotides (6-TGN) and 6-methylmercaptopurine (6-MMP)]
Nonalcoholic fatty liver disease (NAFLD)	
Hepatic steatosis caused by obesity	<input type="checkbox"/> BMI, ultrasound
Hepatic steatosis caused by starvation	<input type="checkbox"/> BMI, ultrasound
Biliary obstruction	
Bile stones	<input type="checkbox"/> Ultrasound
Choledochal malformation	<input type="checkbox"/> Ultrasound
Vascular liver disease	
Portal or hepatic vein thrombosis	<input type="checkbox"/> Doppler-ultrasound
Other	
Celiac disease	<input type="checkbox"/> Celiac antibodies
Wilson disease	<input type="checkbox"/> Bloodmarkers (ceruloplasmin, free copper, Coomb's test) <input type="checkbox"/> Urine (24 h copper excretion) <input type="checkbox"/> Liver biopsy (copper content) <input type="checkbox"/> Ophthalmologist (Kayser–Fleischer rings) <input type="checkbox"/> Genetic testing (ATP7B variants)
Alpha-1-antitrypsin deficiency	<input type="checkbox"/> Alpha-1-antitrypsin in serum <input type="checkbox"/> Alpha-1-antitrypsin phenotyping <input type="checkbox"/> Genetic testing (SERPINA1 variants)

hypergammaglobulinaemia and presence of auto-antibodies. The disease generally responds well to immunosuppressants [23]. 'Watchful waiting' without medication is, therefore, not an option. The goal is to strive for disease remission, which is defined as absence of symptoms; normalization of transaminases; and normalization of the immunoglobulin G level. The disappearance of

autoantibodies is not a treatment goal in itself but is associated with long-term remission [24]. The long-term prognosis is good for those who achieve and maintain remission. In the paediatric age group, end-stage liver disease is only seen in less than 10% of the affected children, with liver transplantation being the only therapeutic option left.

Primary sclerosing cholangitis (PSC) is a progressive cholestatic liver disease. In a prospective Canadian registry of children diagnosed with ulcerative colitis or IBD-unclassified, the risk of developing PSC before the age of 18 was around 9% [25[¶]]. Children with serum GGT greater than 50 U/l at the time of IBD diagnosis were more likely to develop PSC than those with normal GGT levels at baseline. Patients with the PSC-IBD combination often have a unique distribution of intestinal inflammation that can be characterized as pancolitis with rectal sparing and backwash ileitis [26]. PSC is characterized by inflammation and fibrosis of the entire bile tree, which leads to multifocal bile duct strictures and dilations. Patients with histologically confirmed bile duct disease and a normal MR cholangiopancreatography have small duct PSC (sdPSC). There is no agreement among experts whether patients with sdPSC have a more favourable prognosis than patients with large duct (ld)PSC [27]. More than half of the patients who initially presented with sdPSC eventually develop visible abnormalities on cholangiography, which suggests that sdPSC is rather a preliminary stage of ldPSC then being its own entity [28]. An estimated 25–33% of patients with childhood-onset PSC develop biliary complications, portal hypertension or chronic liver failure prior to transfer to adult-oriented care [29]. Fourteen per cent of this group require liver transplantation before the age of 18. Patients with PSC have a greater lifetime risk of developing malignancies than the general population, especially cholangiocarcinoma [odds ratio (OR) 400–1500], gallbladder carcinoma (OR 10) and colorectal carcinoma (OR 10) [30].

The overlap syndrome between AIH and PSC (aka autoimmune sclerosing cholangitis, ASC) is recognized more often in children than in adults. Perhaps the immune-mediated inflammation of the liver parenchyma gradually fades out into adulthood, and as a consequence, only the bile duct damage is still identifiable.

Viral hepatitis

Immunosuppressants, in particular, corticosteroids and anti-TNF drugs, can cause reactivation of hepatitis B. To prevent this potentially life-threatening condition, it is advised to evaluate hepatitis B serology immediately after the diagnosis of IBD [31]. Any new patient with a negative serology should receive a hepatitis B vaccination. Chronic hepatitis B carriers should start antiviral therapy irrespective of the level of viraemia, preferably at least 2 weeks prior to treatment with corticosteroids, azathioprine, or anti-TNF agents [31].

In case of an acute cytomegalovirus or Epstein–Bar virus hepatitis, it is recommended to temporarily stop immunosuppressive medication [31]. During the drug holiday, faecal calprotectin could be monitored on a monthly basis to recognize a flare at an early stage and adjust the treatment plan before symptoms appear [32].

Thiopurine-induced hepatotoxicity

Thiopurine metabolites [6-thioguanine nucleotides (6-TGN) and 6-methylmercaptopurine (6-MMP)] should be measured in patients on thiopurines who have liver test abnormalities.

Thiopurine hypermethylation, which occurs in up to 20% of the population and leads to higher levels of 6-MMP and lower levels of 6-TGN, may resolve when the thiopurine is reduced to 25–33% of the original dose and allopurinol co-administration is initiated [33,34^{¶¶}].

Hepatic steatosis

After an extended period of nutrition deprivation, re-introduction of calories may lead to refeeding syndrome and hepatic steatosis [35]. Although calorie restriction is considered an effective tool to induce NAFLD resolution in obese patients, chronic undernutrition is also detrimental to the liver but the underlying pathophysiology is far from being well understood [36].

Biliary obstruction

Elevated levels of GGT and conjugated bilirubin imply biliary obstruction. Cholelithiasis in Crohn's disease reflects malabsorption of bile acids with impaired enterohepatic circulation, depletion of bile salts, and consequently formation of cholesterol gallstones [37]. Choledochal cyst is a rare and benign congenital cystic dilation of the biliary tree, and is mostly diagnosed during childhood. Clinical presentation varies and most often consists of non-specific abdominal pain. The classic triad of jaundice, abdominal pain, and right upper quadrant mass is rarely seen [38].

Vascular liver disease

During acute flares and infectious complications, the thrombotic tendency is at its greatest, which can result in splanchnic vein thrombosis [39]. Portal and hepatic vein thrombosis usually present with nonspecific symptoms (such as abdominal pain), which explains that the diagnosis is often made incidentally during abdominal imaging [40[¶]].

STEP 6: WHEN TO REFER TO A PAEDIATRIC HEPATOLOGY CENTER

A referral to an expert paediatric hepatologist is warranted when there is evidence of advanced liver disease. This includes portal hypertension (defined as the presence of ascites, oesophageal or gastric varices, splenomegaly, and thrombocytopenia), advanced synthetic dysfunction (defined as a prolonged INR and hypoalbuminaemia) or the presence of bile duct irregularities on cholangiography matching the diagnosis of PSC. Persistent liver test elevation of unknown origin is another reason for referral to a paediatric hepatology centre [41].

CONCLUSION

The purpose of this review was to provide guidance for the situation that a child with IBD has an asymptomatic elevation of liver biochemistry. Prompt identification of the aetiology permits instituting specific interventions to ameliorate hepatic injury or, in the case of PSC, to establish a surveillance program for the early recognition of complications.

Acknowledgements

None.

Financial support and sponsorship

None.

Conflicts of interest

There are no conflicts of interest.

REFERENCES AND RECOMMENDED READING

Papers of particular interest, published within the annual period of review, have been highlighted as:

- of special interest
- of outstanding interest

1. Squires JE, McKiernan P, Squires RH. Acute liver failure: an update. *Clin Liver Dis* 2018; 22:773–805.
2. Rahim MN, Liberal R, Miquel R, *et al*. Acute severe autoimmune hepatitis: ■ corticosteroids or liver transplantation? *Liver Transpl* 2019; 25:946–959. This review explains how to predict steroid resistant acute severe autoimmune hepatitis to distinguish patients who should immediately proceed to liver transplantation (20%) from those who reach remission (80%).
3. Koch DG, Speiser JL, Durkalski V, *et al*. The natural history of severe acute liver injury. *Am J Gastroenterol* 2017; 112:1389–1396.
4. Maaser C, Sturm A, Vavricka SR, *et al*. European Crohn's and Colitis Organisation (ECCO) and the European Society of Gastrointestinal and Abdominal Radiology [ESGAR]. ECCO-ESGAR guideline for diagnostic assessment in IBD Part 1: initial diagnosis, monitoring of known IBD, detection of complications. *J Crohns Colitis* 2019; 13:144–164.
5. Oliveira SB, Monteiro IM. Diagnosis and management of inflammatory bowel disease in children. *BMJ* 2017; 357:j2083.
6. Saich R, Chapman R. Primary sclerosing cholangitis, autoimmune hepatitis and overlap syndromes in inflammatory bowel disease. *World J Gastroenterol* 2008; 14:331–337.
7. Pan XB, Lu YQ, Lin SZ, *et al*. An assessment of upper limits of normal for ALT and the impact on evaluating natural course of chronic hepatitis B virus infection in Chinese children. *Am J Gastroenterol* 2018; 113:1660–1668.
8. Kwo PY, Cohen SM, Lim JK, Clinical ACG. Guideline: evaluation of abnormal liver chemistries. *Am J Gastroenterol* 2017; 112:18–35.

9. Newsome PN, Cramb R, Davison SM, *et al*. Guidelines on the management of abnormal liver blood tests. *Gut* 2018; 67:6–19.
10. Bussler S, Vogel M, Pietzner D, *et al*. New pediatric percentiles of liver enzyme serum levels (alanine aminotransferase, aspartate aminotransferase, gamma-glutamyltransferase): effects of age, sex, body mass index, and pubertal stage. *Hepatology* 2018; 68:1319–1330.
11. Li X, Wang D, Yang C, *et al*. Establishment of age- and gender-specific pediatric reference intervals for liver function tests in healthy Han children. *World J Pediatr* 2018; 14:151–159.
12. Liu J, Dai Y, Lee Y, *et al*. Pediatric reference intervals of liver and renal function tests from birth to adolescence in Chinese children as performed on the Olympus AU5400. *Clin Chim Acta* 2019; 490:142–146.
13. Zierk J, Ganslandt T, Rauh M, *et al*. Data mining of reference intervals for coagulation screening tests in adult patients. *Clin Chim Acta* 2019; 499:108–114.
14. Common Terminology Criteria for Adverse Events (CTCAE), Version 5.0: U.S. Department of Health and Human Services; 2017. Available at: https://ctep.cancer.gov/protocoldevelopment/electronic_applications/docs/CTCAE_v5_Quick_Reference_5x7.pdf. [Accessed 17 May 2021].
15. LiverTox: Clinical and Research Information on Drug-Induced Liver Injury [Internet]. Bethesda (MD): National Institute of Diabetes and Digestive and Kidney Diseases; 2012 Available at: <https://www.ncbi.nlm.nih.gov/books/NBK547852/>. [Accessed 17 May 2021].
16. Shamberg L, Vaziri H. Hepatotoxicity of inflammatory bowel disease medications. *J Clin Gastroenterol* 2018; 52:674–684.
17. Danan G, Teschke R. Roussel Uclaf Causality Assessment Method for drug-induced liver injury: present and future. *Front Pharmacol* 2019; 10:853.
18. Hoofnagle JH, Bjornsson ES. Drug-induced liver injury - types and phenotypes. *N Engl J Med* 2019; 381:264–273. This well written review gives a comprehensive explanation of the DILI types (intrinsic, idiosyncratic, and indirect) and phenotypes.
19. Tillmann HL, Rockey DC. Signatures in drug-induced liver injury. *Curr Opin Gastroenterol* 2020; 36:199–205.
20. Lewis JH. The art and science of diagnosing and managing drug-induced liver injury in 2015 and beyond. *Clin Gastroenterol Hepatol* 2015; 13:2173.e8–2189.e8.
21. European Association for the Study of the Liver. EASL Clinical Practice Guidelines: drug-induced liver injury. *J Hepatol* 2019; 70:1222–1261.
22. Porcino AJ, Shamseer L, Chan AW, *et al*. SPIRIT extension and elaboration for ■ n-of-1 trials: SPENT 2019 checklist. *BMJ* 2020; 368:m122. Drug rechallenge and dechallenge are planned, prospective experiments, comparable with an n-of-1 trial. This article presents the minimum requirements for complete and transparent reporting of such an n-of-1 trial protocol.
23. Mieli-Vergani G, Vergani D, Baumann U, *et al*. Diagnosis and management of pediatric autoimmune liver disease: ESPGHAN Hepatology Committee Position Statement. *J Pediatr Gastroenterol Nutr* 2018; 66:345–360.
24. Gregorio GV, McFarlane B, Bracken P, *et al*. Organ and nonorgan specific autoantibody titres and IgG levels as markers of disease activity: a longitudinal study in childhood autoimmune liver disease. *Autoimmunity* 2002; 35:515–519. This prospective cohort study investigated progression to PSC in children with IBD and elevated GGT levels at baseline. Their finding support periodic GGT level assessment during follow-up.
25. Chandrakumar A, Loeppky R, Deneau M, El-Matary W. Inflammatory bowel ■ disease in children with elevated serum gamma glutamyltransferase levels. *J Pediatr* 2019; 215:144.e3–151.e3.
26. Karlsen TH, Folseraas T, Thorburn D, Vesterhus M. Primary sclerosing cholangitis - a comprehensive review. *J Hepatol* 2017; 67:1298–1323.
27. Weismuller TJ, Trivedi PJ, Bergquist A, *et al*. International PSC Study Group. Patient age, sex, and inflammatory bowel disease phenotype associate with course of primary sclerosing cholangitis. *Gastroenterology* 2017; 152:1975–1984.e8.
28. Ringe KI, Bergquist A, Lenzen H, *et al*. Clinical features and MRI progression of small duct primary sclerosing cholangitis (PSC). *Eur J Radiol* 2020; 129:109101.
29. Deneau MR, El-Matary W, Valentino PL, *et al*. The natural history of primary sclerosing cholangitis in 781 children: A multicenter, international collaboration. *Hepatology* 2017; 66:518–527.
30. Fung BM, Lindor KD, Tabibian JH. Cancer risk in primary sclerosing cholangitis: epidemiology, prevention, and surveillance strategies. *World J Gastroenterol* 2019; 25:659–671.
31. Rahier JF, Magro F, Abreu C, *et al*. European Crohn's and Colitis Organisation (ECCO). Second European evidence-based consensus on the prevention, diagnosis and management of opportunistic infections in inflammatory bowel disease. *J Crohns Colitis* 2014; 8:443–468.
32. Higgins PD. Who wants to take a thiopurine holiday? *Am J Gastroenterol* 2011; 106:556–558.
33. van Rheenen PF, Aloi M, Assa A, *et al*. The medical management of paediatric Crohn's disease: an ECCO-ESPGHAN guideline update. *J Crohns Colitis* 2021; 15:171–194.
34. Barnhill MS, Steinberg JM, Jennings JJ, Lewis JH. Hepatotoxicity of agents ■ used in the management of inflammatory bowel disease: a 2020 update. *Curr Gastroenterol Rep* 2020; 22:47. This is an extensive literature review on currently used medications to treat IBD and their liver-related side effects.

35. da Silva JSV, Seres DS, Sabino K, *et al.*, Parenteral Nutrition Safety and Clinical Practice Committees, American Society for Parenteral and Enteral Nutrition. ASPEN consensus recommendations for refeeding syndrome. *Nutr Clin Pract* 2020; 35:178–195.
36. Risi R, Tuccinardi D, Mariani S, *et al.* Liver disease in obesity and underweight: the two sides of the coin. A narrative review. *Eat Weight Disord* 2020. [Epub ahead of print]
37. Mahfouz M, Martin P, Carrion AF. Hepatic complications of inflammatory bowel disease. *Clin Liver Dis* 2019; 23:191–208.
38. Soares KC, Goldstein SD, Ghaseb MA, *et al.* Pediatric choledochal cysts: diagnosis and current management. *Pediatr Surg Int* 2017; 33:637–650.
39. Connors JM. Thrombophilia testing and venous thrombosis. *N Engl J Med* 2017; 377:1177–1187.
40. Naymagon L, Tremblay D, Zubizarreta N, *et al.* The natural history, treatments, and outcomes of portal vein thrombosis in patients with inflammatory bowel disease. *Inflamm Bowel Dis* 2021; 27:215–223. This retrospective study is currently the largest reported cohort of IBD-associated portal vein thrombosis, which is an underrecognized and poorly described complication of IBD.
41. Yaccob A, Mari A. Practical clinical approach to the evaluation of hepatobiliary disorders in inflammatory bowel disease. *Frontline Gastroenterol* 2019; 10:309–315.