

# Anterior Chamber Paracentesis Offers a Less Painful Experience During Intravitreal Anti-vascular Endothelial Growth Factor Administration: An Intraindividual Study

Review began 11/18/2021  
Review ended 11/29/2021  
Published 11/30/2021

© Copyright 2021  
Karakahya. This is an open access article distributed under the terms of the Creative Commons Attribution License CC-BY 4.0., which permits unrestricted use, distribution, and reproduction in any medium, provided the original author and source are credited.

Refika Hande Karakahya<sup>1</sup>

1. Ophthalmology, Lösante Hospital, Ankara, TUR

**Corresponding author:** Refika Hande Karakahya, handekarakahya@gmail.com

---

---

## Abstract

**Introduction:** In order to improve comfort and compliance to treatment of the patient during the intravitreal injections (IVIs), relieving pain may help and provide getting better results. The purpose of the study was to evaluate the efficacy of anterior chamber paracentesis on pain perception and the factors related to pain perception during intravitreal injection procedures.

**Material and methods:** This prospective randomized study includes 212 eyes of 106 patients scheduled for bilateral IVI of ranibizumab 0.5 mg/0.05 cc under topical anesthesia. All patients underwent full ophthalmologic examination, including intraocular pressure (IOP), anterior chamber depth (ACD), and axial length (AL) measurements. Group 1 received IVI following anterior chamber paracentesis (ACP) and group 2 received IVI without ACP. Intraocular pressure was measured five minutes and 30 minutes after the procedure. Pain perception was assessed by visual analogue scale (VAS) grading from 0 to 10.

**Results:** Mean VAS score for groups 1 and 2 was recorded as  $0.51 \pm 1.00$  and  $1.32 \pm 1.50$ , respectively. Correlation analysis revealed a positive correlation between VAS score and history of previous IVI, preinjection IOP values, and an inverse correlation with the presence of reflux in both groups, in addition to inverse correlation with ACD in group 2.

**Conclusions:** ACP may offer a comfortable, effective, and less painful alternative to prevent the acute rise in IOP after IVI, especially in patients with small anterior chambers, small vitreous volumes, with a history of multiple injections, and in patients with advanced glaucomatous optic neuropathy.

---

**Categories:** Ophthalmology, Pain Management

**Keywords:** anti-vegf, visual analogue scale, pain, intravitreal injection, anterior chamber paracentesis

## Introduction

Intravitreal injections (IVI), maximizing the intraocular concentrations while minimizing the systemic exposure, has become the standard procedure in ophthalmologic conditions such as endophthalmitis, viral retinitis, age-related macular degeneration, cystoid macular edema, diabetic retinopathy, uveitis, retinal vascular occlusions, retinal detachment to deliver several therapeutics such as anti-infective and anti-inflammatory medications, immunomodulators, anticancer agents, gas and anti-vascular endothelial growth factor (anti-VEGF) [1].

After the introduction of anti-VEGF agents, IVI has become one of the most common procedures in ophthalmology in the treatment of conditions like exudative age-related macular degeneration, macular edema due to retinal vein occlusion, diabetic retinopathy, other types of choroidal neovascularization, vascular proliferative retinal diseases such as retinopathy of prematurity [2,3].

Nevertheless, the treatment protocols for anti-VEGF agents in the majority of conditions require repeated injections [2]. The most frequent complaint during IVI is the varying degrees of pain which causes severe anxiety in one-quarter of patients [4]. In addition to the probability of damage to intraocular structures owing to inadvertent eye movements, the patient's discomfort and pain associated with the IVI may even cause discontinuation of the treatment [5]. Therefore, it is important to improve the patient's comfort as much as possible in order to achieve a safer and more durable treatment for best results.

To the best of our knowledge, there is no consensus on the anesthetic agent [6-8], route of anesthetic administration [9-11], pre and post-injection protocols [12-16] for relieving pain, and discomfort related to IVI. Currently, topical anesthesia is the most commonly preferred protocol for IVI due to its safety, cost-effectiveness, and facility [9-11].

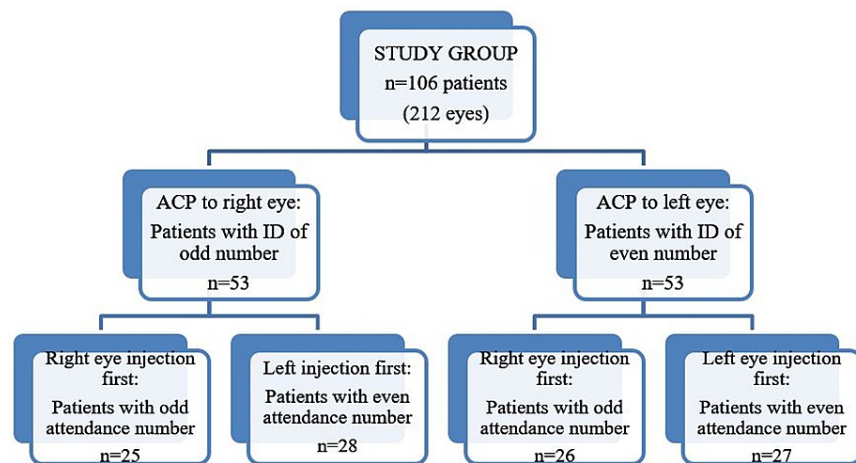
### How to cite this article

Karakahya R (November 30, 2021) Anterior Chamber Paracentesis Offers a Less Painful Experience During Intravitreal Anti-vascular Endothelial Growth Factor Administration: An Intraindividual Study. Cureus 13(11): e20051. DOI 10.7759/cureus.20051

The intensity of pain associated with intravitreal injections has been widely investigated in the literature [6,12,17,18], however, there is little and conflicting information about the factors affecting the pain sensation during IVI. Sudden rise in intraocular pressure (IOP), the size of the needle, and the injection technique have been found to be related to pain [19-21]. In the context of these, we aimed to evaluate the effect of anterior chamber paracentesis (ACP) on pain perception and the factors related to pain perception during IVI procedures in this study.

## Materials And Methods

This prospective randomized controlled study conducted in the ophthalmology department of a tertiary university hospital included 212 eyes of 106 patients scheduled for bilateral intravitreal injection of ranibizumab 0.5 mg/0.05 cc (Lucentis®; Novartis Pharma AG, Basel, Switzerland; Genentech, Inc., South San Francisco, CA, USA) under topical anesthesia. Patients' right and left eyes were randomized to have an IVI with (group 1, n=53) and without ACP (group 2, n=53), according to the personal identification number. The patients with a citizenship identification number ending with an odd number were randomized to group 1, and the patients with an identification number ending with an even number were randomized to group 2. In order to eliminate the possible contribution of the order of the procedure to the perception of pain, patients were randomized again according to the hospital attendance number (Figure 1). IVI with ACP was applied first to the patients with an attendance number ending with an odd number; IVI without ACP was applied first to the patients with an attendance number ending with an even number. This study was conducted in accordance with the Declaration of Helsinki and was given approval by Ordu University Ethics Committee (Approval number: 2018-108). Written informed consents were obtained from all participants. The ocular pain, trigeminal neuralgia, analgesic or sedative use seven days prior to IVI, severe dry eye disease, history of keratopathy or keratitis, history of glaucoma, presence of proliferative retinopathy, active ocular inflammation or infection, nystagmus, allergy to povidone-iodine or ranibizumab or proparacaine hydrochloride, history of ocular surgery and dementia or any other cognitive disease preventing to score VAS were the exclusion criteria. Inclusion criteria were indications for bilateral IVT injection and agreement in taking part in the trial.



**FIGURE 1: Randomization flow chart**

ACP: anterior chamber paracentesis

A complete medical history was obtained from each patient. Patients underwent a full ophthalmologic examination. Status of the lens, indication for IVI, and laterality were recorded. Axial length (AL) and anterior chamber depth (ACD) were measured with a combined biometric pachymeter (PacScan 300AP Digital Biometric Ruler; SonoMed, Lake Success, NY, USA).

### Anesthesia administration

All patients received topical anesthesia with 0.5% proparacaine hydrochloride (Alcaine 0.5%, Alcon Pharmaceuticals, Puurs, Belgium) drops applied to the ocular surface up to two times five minutes apart before the injection.

### Injection technique

All of the injections were performed by a single right-handed surgeon while the patient was in the supine position. Following cleaning the area with 10% povidone-iodine and placement of a single-use sterile

adhesive surgical ocular drape, a disposable lid speculum was inserted. Povidone-iodine 5% was instilled in the conjunctival cul-de-sacs three minutes before the injection. After the prophylactic slow free-flow ACP with a 1 ml insulin syringe needle (26-gauge), the injection was performed in two seconds via a 30-gauge needle perpendicularly in the inferior temporal quadrant, 3.5 mm from the limbus in aphakic/pseudophakic patients and 4.0 mm in phakic patients with the guidance of a sterile caliper. A sterile cotton-tipped applicator was used after removing the needle for a gentle pressure to prevent reflux. Reflux and subconjunctival hemorrhage (SCH) were recorded if present. Following hand-motion control, a drop of antibiotic was instilled. The same procedure was executed in the contralateral eye in the same order except for anterior chamber ACP. Patients were invited to rest for half an hour for IOP measurement at 5 and 30 minutes. The patients were instructed to self-administer 0.5% moxifloxacin (Vigamox; Alcon Laboratories, Inc., Fort Worth, TX, USA) four times a day during the following five days.

### Assessment of pain perception

After the operation, the patients were asked to grade the pain they experienced by a Visual Analogue Scale (VAS) from 0 (no pain) to 10 (unbearable pain).

### Statistical analysis

Data analyses were performed by using SPSS for Windows, version 22.0 (SPSS Inc., Chicago, IL, USA). Whether the distributions of continuous variables were normal or not was determined by the Kolmogorov Smirnov test. Levene test was used for the evaluation of homogeneity of variances. Data are expressed as mean±standard deviation for continuous variables and number (percentage) for categorical variables. The Wilcoxon test was applied for independent data. Categorical dependent variables were evaluated with the McNemar test. It was evaluated the degree of relationship between variables with Pearson or Spearman correlation analysis. A p-value < 0.05 was accepted as a significant level on all statistical analyses.

## Results

A total of 212 eyes of 106 patients who met the inclusion criteria were enrolled and randomized to have an IVI with (group 1) and without anterior chamber ACP (group 2). The study group consisted of 55 females (51.9%) and 51 males (48.1%) and the mean age was 67.20±11.72 (mean ± SD) with a median of 68 years. The indication for IVI was bilateral diabetic macular edema in 48 (45.3%) and neovascular age-related macular degeneration in 58 (54.7%) patients.

Ninety-eight (46.2%) eyes were IVI-naïve. The mean number of injections in eyes with a history of previous injections in groups 1 and 2 were 3.44±1.92 and 3.29±2.02, respectively (p:0.703).

Group 1 consisted of 75 (70.7%) phakic and 31 (29.2%) pseudophakic eyes whereas group 2 consisted of 76 (71.7%) phakic and 30 (28.3%) pseudophakic eyes at the time of IVI (p:1.00).

Mean ACD and AL were measured as 3.23±0.44 mm and 23.31±1.36 mm in group 1, respectively, and mean ACD and AL were measured as 3.24±0.42 mm and 23.43±1.34 mm in group 2, respectively (p:0.008, p<0.001).

Two (1.9%) eyes in group 1 and 17 (16%) eyes in group 2 experienced reflux (p<0.001) and SCH was detected in two (1.9%) eyes in group 1 and seven (6.6%) eyes in group 2 (p:0.059). Characteristics of the patients for the groups are shown in Table 1.

	Group 1		Group 2		P-value
Prior IVI <sup>β</sup>	59	(55.7)	55	(51.9)	0.344
Number of IVI <sup>†</sup>	3.44	±192	3.29	±2.02	0.703
Pseudophakia <sup>β</sup>	31	(29.2)	30	(28.3)	1.000
ACD <sup>†</sup>	3.23	±0.44	3.24	±0.42	<b>0.008</b>
AL <sup>†</sup>	23.31	±1.36	23.43	±1.34	<b>&lt;0.001</b>
Pre-IOP <sup>†</sup>	13.30	±2.85	13.15	±2.45	0.272
Post-IOP 5 min <sup>†</sup>	12.21	±2.66	24.15	±6.82	<b>&lt;0.001</b>
Post-IOP 30 min <sup>†</sup>	12.99	±2.66	18.89	±3.06	<b>&lt;0.001</b>
Pain <sup>†</sup>	0	(6.00)	1.00	(8.00)	<b>&lt;0.001</b>
Reflux <sup>β</sup>	2	(1.9)	17	(16)	<b>&lt;0.001</b>
SCH <sup>β</sup>	2	(1.9)	7	(6.6)	0.059

**TABLE 1: Characteristics of the patients**

Data are expressed as mean ± SD for continuous variables and number (percentage) for categorical variables.

\*Wilcoxon test, <sup>β</sup>Mc-Nemar test.

Statistically significant p-values are in bold.

IVI: intravitreal injection, ACD: anterior chamber depth, AL: axial length, SCH: subconjunctival hemorrhage, Pre-IOP: pre-injection intraocular pressure, Post-IOP 5 min: post-injection 5 minutes intraocular pressure, Post-IOP 30 min: post-injection 30 minutes intraocular pressure.

Mean pre-injection IOP values in groups 1 and 2 were measured as 13.30±2.85 mmHg and 13.15±2.45 mmHg, respectively (p:0.272). Mean IOP values measured five minutes post-injection were 12.21±2.66 mmHg and 24.15±6.82 mmHg in groups 1 and 2, respectively (p<0.001). In addition, mean IOP values measured 30 minutes post-injection were 12.99±2.66 mmHg and 18.89±3.06 mmHg in groups 1 and 2, respectively (p<0.001).

Pre-injection IOP values and 30 minutes post-injection IOP values for group 1 were not statistically different, in fact, there was a significant decrease in IOP values at five minutes post-injection IOP values compared to pre-injection IOP (p<0.001). Whereas there was a significant rise in post-injection IOP values at 5 minutes and 30 minutes compared to pre-injection IOP values for group 2 (p<0.001) with a median increase of 9.5 mmHg (Table 2).

	Pre-IOP	Post-IOP 5 Min	Post-IOP 30 Min	P-value	Post hoc test
Group 1	13 (13)	12 (10)	13 (12)	<b>&lt;0.001</b>	p1<0.001; p2:0.320
Group 2	13 (12)	22.5 (40)	18.5 (20)	<b>&lt;0.001</b>	p1<0.001; p2<0.001

**TABLE 2: Median pre-injection IOP and change in IOP at post-injection 5 and 30 minutes**

Data are expressed as median (range) for continuous variables.

\*Friedman test, <sup>β</sup>Chi-square.

Significant differences were found between; p1: pre vs post 5 min, p2: pre vs post 30 min. Statistically significant p-values are in bold. Pre-IOP: pre-injection intraocular pressure, Post-IOP 5 min: post-injection five minutes intraocular pressure, Post-IOP 30 min: post-injection 30 minutes intraocular pressure.

The mean VAS score for groups 1 and 2 was recorded as  $0.51 \pm 1.00$  and  $1.32 \pm 1.50$ , respectively ( $p < 0.001$ ). Reflux was observed significantly more often in group 2 when compared to group 1 ( $p < 0.001$ ).

The correlations of VAS score with the age, gender, indication for IVI, presence of DM, history of previous IVI, number of previous injections, lens status, pre-injection IOP, AL, ACD values, presence of reflux, and SCH for both groups are shown in Table 3. VAS score was correlated with a history of previous IVI, preinjection IOP in both group 1 ( $p:0.001$ ,  $p:0.007$ ) and group 2 ( $p:0.046$ ,  $p:0.009$ ), whereas inversely correlated with the presence of reflux in both groups ( $p:0.018$ ;  $p:0.038$ ) and ACD ( $p:0.032$ ) in group 2.

		VAS score group 1	VAS score group 2
Age	r	-0.065	-0.072
	p	0.511	0.466
Gender	r	0.056	0.025
	p	0.571	0.800
Indication	r	-0.113	-0.246
	p	0.249	0.011
Prior IVI	r	0.321	0.194
	p	0.001	0.046
Number of IVI	r	0.103	0.257
	p	0.438	0.058
Lens status	r	-0.044	0.139
	p	0.658	0.157
ACD	r	-0.185	-0.208
	p	0.058	0.032
AL	r	-0.184	-0.156
	p	0.060	0.110
PRE-IOP	r	0.261	0.254
	p	0.007	0.009
REFLUX	r	-0.229	-0.202
	p	0.018	0.038
SCH	r	0.094	0.073
	p	0.338	0.455

**TABLE 3: Correlation analysis for pain**

The degree of relationship between variables was evaluated with Spearman's rho correlation and point biserial correlation analysis. IVI: intravitreal injection, ACD: anterior chamber depth, AL: axial Length, SCH: subconjunctival hemorrhage, Pre-IOP: pre-injection intraocular pressure.

No ocular or systemic adverse events owing to paracentesis or IVI were encountered in both groups except SCH.

## Discussion

VEGF-targetted intravitreal drug injections in the treatment of retinal diseases, where overexpression of VEGF leads to vascular leakage and neovascularization, constitute one of the most frequently practiced procedures in ophthalmology. Although therapies with anti-VEGF agents were shown to be effective and safe, frequent injection need warrants long-term follow-up and compliance of patients. The most frequent complaint during IVI is the varying degrees of pain which cause severe anxiety [4] and even discontinuation of the treatment [5]. We, therefore, aimed to evaluate the effect of ACP on pain perception and assess the

factors related to pain perception during IVI procedures.

Demographic factors such as age and gender do not seem to affect the perception of pain during IVI [12,18,22], as well as the side of the injected eye and or indication of treatment [6], in concordance with the results of this study. However, Haas et al. reported that older patients, female patients, and patients having previous IVI had higher pain scores [21]. Massamba et al. suggested that injections of the left eye and temporal superior quadrant yielded significantly greater pain scores [22]. In this study, the history of multiple IVI was found to be associated with greater pain perception in our patients in both groups 1 and 2 resembling the results of Haas et al. [21] and in contrast to Rifkin and Schaal [7] which may reflect the scleral wound healing with the shrinkage of the collagen and increased rigidity.

The impact of needle size on pain perception during IVI has been investigated by various authors. While some studies reported lower pain with 30-gauge needle injections than 27-gauge needles [19,23], others found no significant difference in pain scores when compared to the 27- and 30-gauge needles [7,20,21]. However, many ophthalmologists favor smaller-sized needles [24], owing to the belief that it induces less pain. So, in this study, all of the injections were applied via a 30-gauge needle in the same quadrant. In addition, the right and left eyes of the same patients were randomized to eliminate the interindividual variability in pain perception.

In this study, ocular biometrics were found to be significantly related to pain perception in accordance with the report by Gismondi et al. [25]. Shorter ACD in group 2 was associated with greater pain which may be explained by greater scleral thickness and rigidity and decreased outflow capacity. AL and ACD values had no impact on pain perception in group 1 patients where ACP was performed, despite the significantly lower values compared to group 2.

It is known that depending on the volume effect, transient but significant IOP rise occurs immediately after the intravitreal anti-VEGF injection. Bracha et al. demonstrated an average of 46 mmHg IOP rise which returns to baseline within one hour in healthy eyes [26]. This sudden rise in IOP may contribute to pain sensation. In this prospective randomized study, the VAS score was significantly lower in the paracentesis group (group 1) which may reflect the absence of postinjection hyperacute IOP rise. Post-injection IOP measurements both at 5 minutes and 30 minutes were significantly higher in group 2 than in group 1. Eyes in group 2 experienced an acute IOP rise of median 9.5 mmHg five minutes after injections, but no rise in group 1. Moreover, patients in group 1 experienced lower IOPs than baseline in measurements five minutes after the injections. Risk factors for acute IOP rise were defined by Bracha et al. as the absence of subconjunctival reflux, prior history of glaucoma, smaller vitreous volume manifested by a short AL, and possibly volume of the injected drug [26]. Knip and Välimäki demonstrated the effectiveness of an ACP over an IOP spike (postinjection IOP was 15.3 mmHg versus 47.1 mmHg in the paracentesis and control group, respectively) [27]. It was suggested that ACP may prevent sustained IOP elevation [28] and also retinal nerve fiber loss [29], however, definitive evidence is lacking.

Although there is no consensus regarding its necessity, an ACP seems to offer a more effective, however, riskier method for the prevention of acute ocular hypertension following IVI [26]. Despite we did not encounter any adverse event owing to the ACP in this study, there are reported complications in 0.7% of patients such as inadvertent injection of sterile air into the anterior chamber, anterior lens capsule laceration, allergic reaction to povidone-iodine in a large series as well as hyphema, lens damage, and infection [30].

The main limitation of the current study was the small sample size of a single center. Further large-scale studies are needed to achieve patient comfort and compliance to the treatment of IVI therapies.

## Conclusions

Intravitreal administration of pharmaceutical agents offered an effective route for reaching high concentrations at the target tissue. However, the regimens for retinal diseases treated with anti-VEGFs require more than a single injection. These therapies with frequent injections of anti-VEGF agents warrant long-term follow-up and compliance of patients. Pain may interfere with compliance with treatment. Although it possesses some potential bothersome risks such as infection and iatrogenic lens damage, ACP offers a comfortable, effective, and less painful step in IVI by preventing an acute rise in IOP experienced immediately after IVI, especially in patients with small anterior chambers, small vitreous volumes, history of previous IVIs and in patients at risk of optic disc hypoperfusion with advanced glaucomatous optic neuropathy.

## Additional Information

### Disclosures

**Human subjects:** Consent was obtained or waived by all participants in this study. Ordu University Ethics Committee issued approval 2018-108. **Animal subjects:** All authors have confirmed that this study did not involve animal subjects or tissue. **Conflicts of interest:** In compliance with the ICMJE uniform disclosure

form, all authors declare the following: **Payment/services info:** All authors have declared that no financial support was received from any organization for the submitted work. **Financial relationships:** All authors have declared that they have no financial relationships at present or within the previous three years with any organizations that might have an interest in the submitted work. **Other relationships:** All authors have declared that there are no other relationships or activities that could appear to have influenced the submitted work.

## References

1. Peyman GA, Lad EM, Moshfeghi DM: Intravitreal injection of therapeutic agents . *Retina*. 2009, 29:875-912. [10.1097/IAE.0b013e3181a94f01](https://doi.org/10.1097/IAE.0b013e3181a94f01)
2. Tah V, Orlans HO, Hyer J, et al.: Anti-VEGF therapy and the retina: an update . *J Ophthalmol*. 2015, 2015:627674. [10.1155/2015/627674](https://doi.org/10.1155/2015/627674)
3. Avery RL, Bakri SJ, Blumenkranz MS, et al.: Intravitreal injection technique and monitoring: updated guidelines of an expert panel. *Retina*. 2014, 34 Suppl 12:S1-S18. [10.1097/IAE.0000000000000399](https://doi.org/10.1097/IAE.0000000000000399)
4. Segal O, Segal-Trivitz Y, Nemet AY, Cohen P, Geffen N, Mimouni M: Anxiety levels and perceived pain intensity during intravitreal injections. *Acta Ophthalmol*. 2016, 94:203-4. [10.1111/aos.12802](https://doi.org/10.1111/aos.12802)
5. Vaze A, Fraser-Bell S, Gillies M: Reasons for discontinuation of intravitreal vascular endothelial growth factor inhibitors in neovascular age-related macular degeneration. *Retina*. 2014, 34:1774-8. [10.1097/IAE.0000000000000173](https://doi.org/10.1097/IAE.0000000000000173)
6. Sanabria MR, Montero JA, Losada MV, et al.: Ocular pain after intravitreal injection . *Curr Eye Res*. 2013, 38:278-82. [10.3109/02713683.2012.758290](https://doi.org/10.3109/02713683.2012.758290)
7. Rifkin L, Schaal S: Factors affecting patients' pain intensity during in office intravitreal injection procedure . *Retina*. 2012, 32:696-700. [10.1097/IAE.0b013e318252ad5](https://doi.org/10.1097/IAE.0b013e318252ad5)
8. Yau GL, Jackman CS, Hooper PL, Sheidow TG: Intravitreal injection anesthesia - comparison of different topical agents: a prospective randomized controlled trial. *Am J Ophthalmol*. 2011, 151:333-7.e2. [10.1016/j.ajo.2010.08.031](https://doi.org/10.1016/j.ajo.2010.08.031)
9. Cintra LP, Lucena LR, Da Silva JA, Costa RA, Scott IU, Jorge R: Comparative study of analgesic effectiveness using three different anesthetic techniques for intravitreal injection of bevacizumab. *Ophthalmic Surg Lasers Imaging*. 2009, 40:13-8. [10.3928/15428877-20090101-05](https://doi.org/10.3928/15428877-20090101-05)
10. Blaha GR, Tilton EP, Barouch FC, Marx JL: Randomized trial of anesthetic methods for intravitreal injections. *Retina*. 2011, 31:535-9. [10.1097/IAE.0b013e3181eac724](https://doi.org/10.1097/IAE.0b013e3181eac724)
11. Davis MJ, Pollack JS, Shott S: Comparison of topical anesthetics for intravitreal injections: a randomized clinical trial. *Retina*. 2012, 32:701-5. [10.1097/IAE.0b013e31822f27ca](https://doi.org/10.1097/IAE.0b013e31822f27ca)
12. Rifkin L, Schaal S: Shortening ocular pain duration following intravitreal injections. *Eur J Ophthalmol*. 2012, 22:1008-12. [10.5301/ejo.5000147](https://doi.org/10.5301/ejo.5000147)
13. Georgakopoulos CD, Vasilakis PT, Makri OE, Beredima E, Pharmakakis NM: Effect of ketorolac 0.5% drops on patients' pain perception during intravitreal injection procedure. *J Ocul Pharmacol Ther*. 2012, 28:455-8. [10.1089/jop.2012.0023](https://doi.org/10.1089/jop.2012.0023)
14. Ulrich JN: Topical nepafenac after intravitreal injection: a prospective double-masked randomized controlled trial. *Retina*. 2014, 34:509-11. [10.1097/IAE.0b013e3182a0e611](https://doi.org/10.1097/IAE.0b013e3182a0e611)
15. Georgakopoulos CD, Tsapardoni F, Makri OE: Effect of Bromfenac on pain related to intravitreal injections: a randomized cross-over study. *Retina*. 2017, 37:388-95. [10.1097/IAE.0000000000001137](https://doi.org/10.1097/IAE.0000000000001137)
16. Lagstein O, Ben-Artzi N, Achiron A, Nemet A, Khreish M, Bartov E, Burgansky-Eliash Z: Topical apraclonidine reduces pain after intravitreal injections: a double-blind randomized controlled trial. *Retina*. 2017, 37:1575-80. [10.1097/IAE.0000000000001397](https://doi.org/10.1097/IAE.0000000000001397)
17. Moisseiev E, Regenbogen M, Bartfeld Y, Barak A: Evaluation of pain in intravitreal bevacizumab injections . *Curr Eye Res*. 2012, 37:813-7. [10.3109/02713683.2012.681335](https://doi.org/10.3109/02713683.2012.681335)
18. Doguizi S, Sekeroglu MA, Inanc M, Anayol MA, Yilmazbas P: Evaluation of pain during intravitreal aflibercept injections. *Eur J Ophthalmol*. 2018, 28:63-7. [10.5301/ejo.5001001](https://doi.org/10.5301/ejo.5001001)
19. Rodrigues EB, Grumann A Jr, Penha FM, et al.: Effect of needle type and injection technique on pain level and vitreal reflux in intravitreal injection. *J Ocul Pharmacol Ther*. 2011, 27:197-203. [10.1089/jop.2010.0082](https://doi.org/10.1089/jop.2010.0082)
20. Loureiro M, Matos R, Sepulveda P, Meira D: Intravitreal injections of bevacizumab: the impact of needle size in intraocular pressure and pain. *J Curr Glaucoma Pract*. 2017, 11:38-41. [10.5005/jp-journals-10028-1220](https://doi.org/10.5005/jp-journals-10028-1220)
21. Haas P, Falkner-Radler C, Wimpfing B, Malina M, Binder S: Needle size in intravitreal injections - pain evaluation of a randomized clinical trial. *Acta Ophthalmol*. 2016, 94:198-202. [10.1111/aos.12901](https://doi.org/10.1111/aos.12901)
22. Massamba N, Elluard M, Agoune W, Guyader V, Ingram A, Pasquier B, Knoeri J: Assessment of ocular pain following ranibizumab intravitreal injection. *Acta Ophthalmol*. 2015, 93:e231-2. [10.1111/aos.12531](https://doi.org/10.1111/aos.12531)
23. Güler M, Bilgin B, Çapkın M, Şimşek A, Bilak Ş: Assessment of patient pain experience during intravitreal 27-gauge bevacizumab and 30-gauge ranibizumab injection. *Korean J Ophthalmol*. 2015, 29:190-4. [10.3341/kjo.2015.29.3.190](https://doi.org/10.3341/kjo.2015.29.3.190)
24. Yannuzzi NA, Patel SN, Bhavsar KV, Sugiguchi F, Freund KB: Predictors of sustained intraocular pressure elevation in eyes receiving intravitreal anti-vascular endothelial growth factor therapy. *Am J Ophthalmol*. 2014, 158:319-327.e2. [10.1016/j.ajo.2014.04.029](https://doi.org/10.1016/j.ajo.2014.04.029)
25. Gismondi M, Salati C, Salvat ML, Zeppieri M, Brusini P: Short-term effect of intravitreal injection of Ranibizumab (Lucentis) on intraocular pressure. *J Glaucoma*. 2009, 18:658-61. [10.1097/IJG.0b013e31819c4893](https://doi.org/10.1097/IJG.0b013e31819c4893)
26. Bracha P, Moore NA, Ciulla TA, WuDunn D, Cantor LB: The acute and chronic effects of intravitreal anti-vascular endothelial growth factor injections on intraocular pressure: A review. *Surv Ophthalmol*. 2018, 63:281-95. [10.1016/j.survophthal.2017.08.008](https://doi.org/10.1016/j.survophthal.2017.08.008)
27. Knip MM, Välimäki J: Effects of pegaptanib injections on intraocular pressure with and without anterior chamber paracentesis: a prospective study. *Acta Ophthalmol*. 2012, 90:254-8. [10.1111/j.1755-3768.2010.01904.x](https://doi.org/10.1111/j.1755-3768.2010.01904.x)

28. Ichiyama Y, Sawada T, Kakinoki M, et al.: Anterior chamber paracentesis might prevent sustained intraocular pressure elevation after intravitreal injections of ranibizumab for age-related macular degeneration. *Ophthalmic Res.* 2014, 52:234-8. [10.1159/000365253](https://doi.org/10.1159/000365253)
29. Soheilian M, Karimi S, Montahae T, Nikkhah H, Mosavi SA: Effects of intravitreal injection of bevacizumab with or without anterior chamber paracentesis on intraocular pressure and peripapillary retinal nerve fiber layer thickness: a prospective study. *Graefes Arch Clin Exp Ophthalmol.* 2017, 255:1705-12. [10.1007/s00417-017-3702-1](https://doi.org/10.1007/s00417-017-3702-1)
30. Trivedi D, Denniston AK, Murray PI: Safety profile of anterior chamber paracentesis performed at the slit lamp. *Clin Exp Ophthalmol.* 2011, 39:725-8. [10.1111/j.1442-9071.2011.02565.x](https://doi.org/10.1111/j.1442-9071.2011.02565.x)