



Open Access

REVIEW

Male Fertility

Regulation of anti-Müllerian hormone (AMH) in males and the associations of serum AMH with the disorders of male fertility

Hui-Yu Xu^{1,2,3,4,*}, Hong-Xian Zhang^{5,*}, Zhen Xiao⁶, Jie Qiao^{1,2,3,4}, Rong Li^{1,2,3,4}

Anti-Müllerian hormone (AMH) is a functional marker of fetal Sertoli cells. The germ cell number in adults depends on the number of Sertoli cells produced during perinatal development. Recently, AMH has received increasing attention in research of disorders related to male fertility. This paper reviews and summarizes the articles on the regulation of AMH in males and the serum levels of AMH in male fertility-related disorders. We have determined that follicle-stimulating hormone (FSH) promotes *AMH* transcription in the absence of androgen signaling. Testosterone inhibits the transcriptional activation of *AMH*. The undetectable levels of serum AMH and testosterone levels indicate a lack of functional testicular tissue, for example, that in patients with anorchia or severe Klinefelter syndrome suffering from impaired spermatogenesis. The normal serum testosterone level and undetectable AMH are highly suggestive of persistent Müllerian duct syndrome (PMDS), combined with clinical manifestations. The levels of both AMH and testosterone are always subnormal in patients with mixed disorders of sex development (DSD). Mixed DSD is an early-onset complete type of disorder with fetal hypogonadism resulting from the dysfunction of both Leydig and Sertoli cells. Serum AMH levels are varying in patients with male fertility-related disorders, including pubertal delay, severe congenital hypogonadotropic hypogonadism, nonobstructive azoospermia, Klinefelter syndrome, varicocele, McCune-Albright syndrome, and male senescence. *Asian Journal of Andrology* (2019) 21, 109–114; doi: 10.4103/aja.aja_83_18; published online: 26 October 2018

Keywords: anti-Müllerian hormone; disorders related to male fertility; follicle-stimulating hormone; testosterone

INTRODUCTION TO AMH

Anti-Müllerian hormone (AMH), also known as Müllerian-inhibiting substance (MIS), is a Sertoli cell-secreted protein that plays a major role in the development of internal male genitalia.¹ High expression of AMH in male gonads at the critical stage of embryonic genital development, *i.e.*, 7 weeks of gestation,^{2,3} promotes regression of the Müllerian duct. In the absence of AMH, Müllerian ducts develop into female internal sex organs. Anti-Müllerian hormone is named based on these processes. AMH is a dimeric glycoprotein consisting of two identical 70-kDa subunits and constitutes the transforming growth factor-beta (TGF- β) superfamily together with inhibins, activins, bone morphogenetic proteins (BMPs), and growth differentiation factors (GDFs). TGF- β family members play important roles in the regulation of cell proliferation and apoptosis in many biological processes, including folliculogenesis and spermatogenesis.

ROLE OF AMH IN SERTOLI CELL PHYSIOLOGY

Sertoli cells are the earliest cell type that appear in the embryonic testis.^{4,5} More than 75% of the gonadal mass in the prepubertal testis is composed of Sertoli cells.^{6,7} Dysfunction of Sertoli cell proliferation or maturation may lead to secretory dysfunction via endocrine and

paracrine signaling, leading to an inability to support spermatogenesis. During fetal life, AMH is exclusively secreted by Sertoli cells and can be used as a functional marker of fetal Sertoli cells.¹ Sertoli cells secrete other proteins that include (1) inhibins and activins, which are secreted by adult Sertoli cells to regulate follicle-stimulating hormone (FSH) production; (2) androgen-binding proteins (ABPs), which act as carrier proteins of testosterone and are responsible for the high concentration of intratesticular testosterone necessary for spermatogenesis;⁸ (3) estradiol, which is transformed from testosterone catalyzed by aromatases in Sertoli cells; and (4) glial cell line-derived neurotrophic factors (GDNFs), which contribute to the self-renewal of spermatogonial stem cells. All of these factors secreted by Sertoli cells are involved in spermatogenesis.^{9–11} Furthermore, Sertoli cells, rather than germ cells, express the androgen receptor,¹¹ which is critical for the regulation of spermatogenesis induced by high concentrations of intratesticular testosterone.¹²

FSH is responsible for AMH transcriptional activation and the increase of Sertoli cell number in the absence of androgen signaling
The germ cell number in adult men depends on the number of Sertoli cells produced during perinatal development.^{5,13} FSH has

¹Center for Reproductive Medicine, Department of Obstetrics and Gynecology, Peking University Third Hospital, Beijing 100191, China; ²Key Laboratory of Assisted Reproduction, Ministry of Education, Beijing 100191, China; ³National Clinical Research Center for Obstetrics and Gynecology, Beijing 100191, China; ⁴Beijing Key Laboratory of Reproductive Endocrinology and Assisted Reproductive Technology, Beijing 100191, China; ⁵Department of Urology, Peking University Third Hospital, Beijing 100191, China; ⁶Department of Reproductive Endocrinology, Zhejiang Provincial People's Hospital, Hangzhou Medical College, Hangzhou 310014, China.

*These authors contributed equally to this work.

Correspondence: Dr. R Li (roseli001@sina.com)

Received: 01 February 2018; Accepted: 20 August 2018

been recognized as a regulator of Sertoli cell number in developing testes.^{14,15} The hypothalamic–pituitary–gonadal (HPG) axis is inactive in prepuberty, as demonstrated by low levels of both testosterone and gonadotropins.^{1,16–19} Lukas-Croisier *et al.*²⁰ used a prepubertal FSH-deficient (FSH^{-/-}) transgenic male mouse model to demonstrate that FSH transcriptionally activates AMH production in the absence of androgen signaling. They showed that serum AMH concentration, Sertoli cell number, and testicular volume were decreased in FSH knockout mice and returned to normal after administration of recombinant FSH and transfection of FSH receptor plasmid. They next transfected different fragments of AMH promoter regions, together with the FSH receptor gene, into a prepubertal Sertoli cell line and added recombinant FSH protein to activate AMH transcription. The results showed that FSH transcriptionally activates AMH through a nonclassical cyclic adenosine monophosphate (cAMP) pathway by binding to the AMH promoter region located more than -1.9 kb away from the transcription initiation site at nuclear factor kappa-B (NF-κB) and transcription factor AP2-binding sites.²⁰ Unlike the distal regulation of the AMH promoter region by NF-κB, regulation of the proximal promoter of AMH has been extensively studied. Sex-determining region Y box 9 (Sox9),^{21,22} steroidogenic factor-1 (SF1),^{23–25} and GATA factors^{25–27} are implicated in the transcriptional activation of AMH within -220 bp of the transcriptional start site independent of gonadotropic control.^{28,29} A schematic diagram of FSH-regulated AMH transcriptional activation is shown in **Figure 1**. Another study using Tfm mice with a mutation in the androgen receptor gene that made the XY mouse insensitive to androgens^{30,31} showed that FSH administration resulted in the elevation of serum AMH levels in the absence of androgen signaling.³² FSH-induced AMH transcription and an increase in Sertoli cell number were also observed in neonates and adult humans suffering from hypogonadotropic hypogonadism (HH).^{6,16,33} The androgen signaling pathway of these individuals is not functional, and their decreased AMH levels return to normal after the administration of recombinant FSH.

Testosterone downregulates AMH expression

The most obvious example of negative regulation of AMH by testosterone is that when boys enter puberty, a sudden increase in their testosterone levels results in decreased levels of AMH, indicating that testosterone has an inhibitory effect on AMH;³⁴ the increase in intratesticular testosterone levels is responsible for the inhibition of

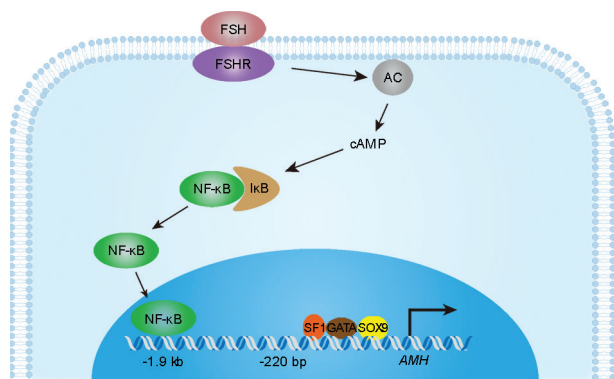


Figure 1: Schematic diagram of FSH-regulated AMH transcriptional activation. FSH: follicle-stimulating hormone; FSHR: FSH receptor; AC: adenylate cyclase; NF-κB: nuclear factor kappa-B; IκB: NF-κB inhibitor; SP1: transcription factor Sp1; GATA: GATA-binding proteins; SOX9: sex-determining region Y box 9; AMH: anti-Müllerian hormone; cAMP: cyclic adenosine monophosphate.

AMH levels.^{32,35–37} Another example is the increase in testosterone levels in precocious children, which is always accompanied by a decrease in AMH levels regardless of gonadotropin dependence or independence.¹⁸ This negative regulatory pattern can also explain hormone levels in patients with androgen insensitivity syndrome (AIS) caused by mutations in the androgen receptor gene. The diagnosis of AIS is made by detecting normal-to-high testosterone and AMH levels and the absence of Müllerian derivatives in 46,XY males;^{28,38–40} the high levels of testosterone do not induce a decrease in AMH levels due to androgen signaling dysfunction.

Animal experiments also revealed a pattern of negative regulation between testosterone and AMH. The knockout of androgen receptors in Sertoli cells in mice induces a significant decrease in testosterone levels and thus gives rise to transiently elevated expression of AMH at both the mRNA and protein levels in Sertoli cells.⁴¹ How does testosterone inhibit the expression of AMH? Another study performed the following mechanistic investigation to show that binding at the NF-κB-binding site in the distal promoter region of AMH provides transcriptional activity levels higher than those produced by binding at the SP1-, GATA-, and Sox9-binding sites in the proximal promoter regions.²⁰ Although there are no androgen receptor-binding sites in the AMH promoter region,⁴² there are NF-κB binding sites, and NF-κB is negatively regulated by androgen receptors;^{43,44} therefore, although testosterone cannot directly regulate AMH transcription, it can fulfill its function by inhibiting the transcription of NF-κB and thus suppress the transcriptional activation of AMH.

However, AMH levels are not always negatively regulated by testosterone because of defects in androgen signaling. For instance, a synchronous increase in AMH and testosterone levels was discovered in neonates.^{36,45} It was discovered that the androgen receptor is present in fetal and neonatal Leydig and peritubular cells but not in Sertoli cells.^{46,47} The absence of androgen receptor expression in fetal and neonatal Sertoli cells may contribute to the lack of transcriptional suppression of AMH. Thus, FSH-induced AMH transcriptional activation and luteinizing hormone (LH)-induced testosterone activation account for the main biological events in fetal and neonate boys.

ASSOCIATIONS BETWEEN SERUM AMH AND DISORDERS RELATED TO MALE FERTILITY

Diagnosis and differential diagnosis of disorders of sex development (DSD)

Male genital differentiation is driven by two hormones: testosterone, which is produced by fetal Leydig cells, maintains Wolffian ducts, and contributes to the virilization of external genitalia, and AMH, which is produced by fetal Sertoli cells and is responsible for the regression of fetal Müllerian ducts.⁴⁸ DSD in males may result from defects in the signaling of one or both of these hormones. Dysfunction of secretion or an inactive state of AMH, caused by mutations in AMH or its receptor AMHR2, leads to persistent Müllerian duct syndrome (PMDS). Patients with PMDS are born male according to the general human standard at birth, but the Müllerian duct derivatives persist, manifested as undescended testes (cryptorchidism) and the presence of a small, underdeveloped uterus in an XY infant or adult. Notably, fertility in PMDS patients is rare but possible if at least one testis descends to the scrotum with its excretory ducts intact.⁴⁹ No external genital ambiguity, especially without hypospadias, is the main feature of PMDS that distinguishes it from mixed gonadal dysgenesis, which is an early-onset complete type of DSD with fetal hypogonadism resulting from the dysfunction of both Leydig and Sertoli cells.²⁸

Recently, mutations in the *AMH* and its receptor gene were found to account for 88% of PMDS cases in which undescended testes (UDTs) are the clinical manifestation.⁴⁹ The remaining 12% of PMDS cases are idiopathic, and no mutations in *AMH* or *AMHR II* have been detected. However, we cannot rule out the possibility of *AMH* or *AMHR II* mutations, as some studies have shown that the diversity of *AMH* or *AMHR II* mutations might be underrecognized and that the sensitivity and specificity of sequencing can be limited,⁴⁹ leading to unidentified mutations in the distal promoter or introns of *AMH* or *AMHR II*. Furthermore, we cannot rule out the possibility of mutations in other molecules in the AMH signaling pathway.

PMDS should be distinguished from other types of UDT. Leydig cell function in patients with PMDS is generally normal,⁴⁹ as indicated by normal levels of serum testosterone and LH.^{17,49} The levels of inhibin B, secreted by Sertoli cells,^{50–52} are normal in boys with *AMH* mutations but undetectable in boys with *AMHR II* mutations.¹⁷ Serum AMH levels depend on the molecular origin of *AMH* or *AMHR II* mutations. Very low or undetectable circulating AMH levels in prepubertal boys or adults with PMDS are characteristics of mutations in *AMH*, resulting in a lack of AMH protein secretion. Meanwhile, normal serum AMH levels are detected in boys with *AMHR II* mutations. Congenital adrenal hyperplasia (CAH) in females (46,XX) with a male phallus and bilateral nonpalpable gonads should first be differentially diagnosed from UDT via its severe complications, such as hyponatremia, hyperkalemia, and shock. When increasing severity of hypospadias with UDT is discovered, the possibility of a mixed DSD should be considered.⁵³ In patients with mixed types of DSD accompanied by low serum levels of both AMH and testosterone and external genital malformations, low AMH reflects severe testicular dysgenesis and should not be confused with PMDS. If an infant with bilateral nonpalpable testes has a 46,XY karyotype, an evaluation to distinguish anorchia from bilateral abdominal testes is needed to avoid surgical exploration. To assess the presence of testicular tissue, serum AMH should first be considered;⁵³ other hormone tests include those that detect FSH, LH, inhibin B, and testosterone levels.⁵³ A flowchart indicating the differential diagnosis of DSD is shown in **Figure 2**.

Studies of unilateral UDT revealed that UDTs in children are smaller than their descended counterparts ($P < 0.001$).^{54,55} Given that Sertoli cells account for 75% of testis mass in prepubertal males,^{6,7} there may be varying degrees of decline in the number of Sertoli cells in UDT, which may result from increased temperature around the UDT. The degree of AMH decrease in boys bearing cryptorchidism is related to the severity of UDT injury,^{56–58} suggesting that deteriorated Sertoli cell function may be an early example of damage from UDT. Moreover, infertility is the major long-term concern of patients with a history of UDT.⁵³ Infertility risks of 30% and 54% were discovered in unilateral and bilateral UDT, respectively,^{59–63} in accordance with the duration for which UDT is exposed to abdominal temperature. A 75%–100% risk of infertility was found in boys with bilateral UDT in whom no germ cells were found on biopsy.⁶⁴ In conclusion, the degree of male infertility caused by UDT is related to the severity of injury to Sertoli cells; thus, a higher degree of serum decline in AMH in boys may suggest a greater risk of infertility when they become adults.

Distinguishing pubertal delay from congenital hypogonadotropic hypogonadism

Constitutional pubertal delay and congenital HH share the same clinical manifestation of delayed sexual maturation in prepubertal boys. Levels of gonadotropin and testosterone are very low in prepubertal boys and therefore have little clinical significance; thus, AMH, the

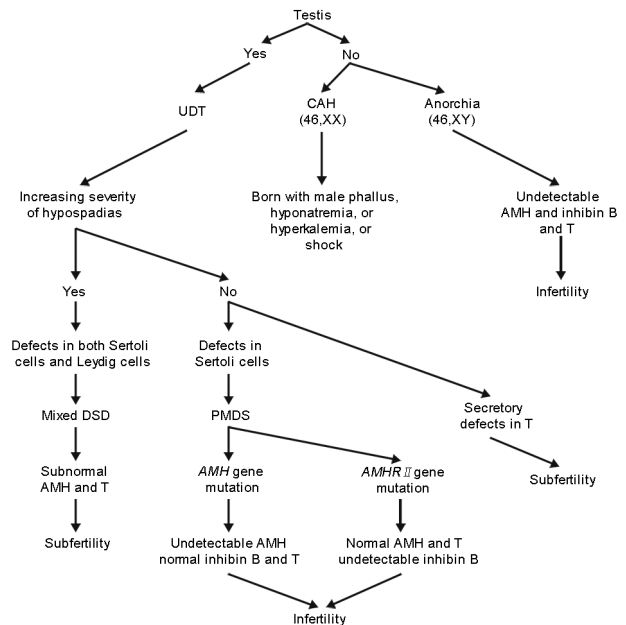


Figure 2: AMH contributes to the differential diagnosis of DSD. UDT: undescended testis; CAH: congenital adrenal hyperplasia; DSD: disorders of sex development; PMDS: persistent Müllerian duct syndrome; AMH: anti-Müllerian hormone; T: testosterone; AMHR: AMH receptor.

marker of Sertoli cells, is of great importance in the differential diagnosis of constitutional pubertal delay and congenital HH.^{18,46}

Congenital HH is often accompanied by Sertoli cell dysfunction.⁶⁵ Severe deficiency in gonadotropin levels in congenital HH patients results in a decreased number of Sertoli cells and correspondingly low levels of AMH and inhibin B.^{65–67} The constitutional delay of puberty reflects a eugonadal state of Sertoli cells, and serum AMH is within the normal level for prepubertal boys.⁶⁸ In patients with untreated congenital HH, the AMH level is increased upon administration of recombinant FSH due to FSH-induced proliferation of Sertoli cells, whereas further treatment with human chorionic gonadotropin (hCG) gives rise to a decline in AMH levels due to the hCG-induced increased levels of testosterone, which induces inhibition of *AMH* that overrides FSH-initiated *AMH* transcription. However, the administration of exogenous testosterone did not result in a decrease in AMH concentrations, which may be caused by low intratesticular testosterone levels in congenital HH patients.

Nonobstructive azoospermia and Klinefelter syndrome (47,XXY)

Nonobstructive azoospermia (NOA) is the most severe type of male infertility, characterized by a lack of sperm in semen induced by impaired spermatogenesis.⁶⁹ Increased serum FSH, decreased serum AMH and inhibin B, have been discovered in men with NOA.^{70–72} With the advent of intracytoplasmic sperm injection (ICSI) technology, these NOA patients also have the opportunity to have their own children through testicular sperm extraction (TESE) or microdissection-testicular sperm extraction (MD-TESE), with sperm recovery rates (SRRs) of only 40%–60%.^{69,73} Currently, there are no acknowledged markers of SRR with good sensitivity and specificity. FSH, inhibin B, AMH, and testosterone, although differentially expressed in NOA, are not good predictors of SRR. Higher baseline testosterone,⁷⁴ lower FSH,⁷⁵ higher AMH,⁷⁶ or higher inhibin B⁷⁷ levels do not guarantee a better SRR in NOA patients. The underlying mechanism may be the following: the function of the Sertoli cells

and interstitial cells is impaired, as indicated by abnormal hormone levels, but not completely lost in a large number of NOA patients; spermatogenesis is only present in small areas, if any.⁷⁸ In our clinical practice, we have identified a certain number of NOA patients whose serum AMH levels are below the lower limit of the male reference interval or even undetectable and whose serum testosterone levels are normal or subnormal yet obtain good pregnancy outcomes using their own sperm retrieved via TESE or MD-TESE. These serum markers may be useful when combined with testicular volume, age and other markers to predict SRR before TESE or MD-TESE using a multivariable regression method.^{77,79}

Klinefelter syndrome is characterized by accelerated germ cell depletion⁸⁰ and occurs in approximately 10%–12% of NOA men.⁸¹ In patients with Klinefelter syndrome, circulating AMH levels are within the reference range until puberty; thereafter, AMH declines to subnormal concentrations in adults.^{82,83} In a 12.3-year follow-up study of 29 patients with Klinefelter syndrome, an early increase in FSH was detected, accompanied by abnormally low or undetectable levels of AMH and inhibin B in advanced pubertal stages, which may be explained by progressive impairment of endocrine function during childhood and puberty.⁸³ However, a delay in the puberty-related decline of AMH was observed in patients with Klinefelter syndrome, finally leading to decreased AMH levels in adulthood,⁸² which may be caused by temporary functional compensation of Sertoli cells. Furthermore, in our clinical practice, we identified a few severe NOA patients, including severe Klinefelter syndrome patients, whose serum AMH and testosterone levels were both undetectable and with no sperm retrieved via MD-TESE, indicating that their germ cells were completely depleted. Undetectable AMH and testosterone were also used to distinguish anorchia from UDT,^{84–86} as shown in **Figure 2**, implying that in male adults, undetectable serum AMH and testosterone can be used to assess whether any functional testicular tissue or, specifically, functional germ cells exist.

Varicocele

Varicocele is an abnormal enlargement and bending of the pampiniform venous plexus in the scrotum. The adverse effects of varicocele on spermatogenesis are progressive and therefore decrease male fertility with time. Expansion of the veins impairs the testicular blood supply, resulting in a reduction in the oxygenated blood and nutrient supply to the local testis, which leads to a decline in the quality and quantity of sperm; on the other hand, it also induces dysfunction of the testicular nervous plexus, the main function of which is to regulate testicular temperature. Higher testicular temperatures can lead to testicular atrophy and infertility. Indeed, varicocele is the main cause of male infertility,⁸⁷ and it was found in approximately 35% of primary infertile men and 81% of secondary infertile men.⁸⁸

The severe damage caused by varicocele is correlated with impaired function of Sertoli cells. According to the study from Li *et al.*,⁸⁹ the levels of transferrins and androgen-binding proteins secreted by Sertoli cells were reported to be downregulated in patients suffering from varicocele, suggesting that decreased testicular blood flow may lead to impaired function of Sertoli cells. Furthermore, testicular biopsies in patients with varicocele showed that the germ cells in the seminiferous tubule were sloughed, and this phenomenon was often associated with impaired Sertoli cell function.⁹⁰

An analysis of serum AMH levels in varicocele-bearing patients was inconclusive. A study in adult subfertility men including varicocele, idiopathic NOA, idiopathic nonobstructive dyspermia,

Table 1: Anti-Müllerian hormone levels in disorders related to male fertility

Categories	AMH level
Pubertal delay	Normal prepubertal level in puberty
Severe congenital HH	Decreased in puberty
Klinefelter syndrome (47,XXY)	Within the reference range until puberty; a delay in puberty-related decline; thereafter, declined to subnormal concentrations in adults
NOA	Decreased AMH level
Varicocele	Elevated in early-onset varicocele in prepubertal and pubertal boys, and decreased in adults with severe varicocele
McCune-Albright syndrome	Increased AMH level in boys
Male senescence	Age-related decrease

HH: hypogonadotropic hypogonadism; NOA: nonobstructive azoospermia; AMH: anti-Müllerian hormone

cryptorchidism, and other diagnoses indicated that circulating AMH levels in subfertile men were 60% lower than those in corresponding controls, accompanied by a decreased level of inhibin B, indicating the decreased function of Sertoli cells in varicocele-bearing adult patients.⁹¹ In prepubertal and pubertal boys with varicocele, AMH concentrations were elevated, accompanied by an increase in inhibin B levels, suggesting a compensatory increase in Sertoli cell function in the early-onset varicocele.⁹² There was also an article reporting a lower concentration of AMH in the local spermatic vein than in the peripheral blood, suggesting that poor blood supply in patients with varicocele causes the deterioration of Sertoli cell function.⁹³

McCune-Albright syndrome in boys

As we mentioned previously, normal puberty is accompanied by decreased serum levels of AMH. However, in boys with McCune-Albright syndrome, precocious puberty is observed, but abnormal increased instead of decreased levels of AMH are detected,^{94–96} accompanied by macro-orchidism and androgen-dependent secondary sexual defects. Hyperfunction of Sertoli cells without Leydig cell activation was reported to be responsible for the onset of this disease.⁹⁷

Male senescence

Testes, hormone production, and spermatogenesis undergo senescence as a man ages.⁹⁸ Johnson *et al.*⁹⁹ identified an age-related decrease in Sertoli cell number; consistent with this, AMH, as a marker of immature Sertoli cells, was also found to be reduced with increasing age^{36,100,101} and negatively correlated with FSH and LH, which indicates that decreased AMH levels as a man ages represent age-related reduced Sertoli cell function.

CONCLUSION

In the absence of androgen signaling, FSH promotes *AMH* transcription by activating the -1.9 kb *AMH* promoter region, where NF- κ B has the highest level of transcriptional activation activity, and the proximal within -220 bp²⁰ *AMH* promoter region, where Sox9,^{21,22} SF1,^{23–25} and GATA factors^{25–27} reside. Testosterone inhibits the transcriptional activation of *AMH*, hypothetically through transcriptional inhibition of NF- κ B. Regarding the associations between serum AMH and disorders related to male fertility, undetectable serum AMH and testosterone indicate a lack of functional testicular tissue, for example, that in patients with anorchia or severe Klinefelter syndrome suffering from impaired spermatogenesis. Normal serum testosterone levels and

undetectable AMH are highly suggestive of PMDS. The levels of both AMH and testosterone are always subnormal in patients with mixed DSD (as shown in **Figure 2**). The usefulness of AMH levels in these conditions (pubertal delay, severe congenital HH, NOA, Klinefelter, varicocele, McCune-Albright syndrome, and male senescence) is also summarized, as indicated in **Table 1**.

AUTHOR CONTRIBUTIONS

HYX and HXZ participated in the study design and references collection, and most of the manuscript writing. ZX participated in Figures drawing. JQ conceived the study. RL conceived and designed the study, edited the manuscript, and finally approved the final version. All authors read and approved the final manuscript.

COMPETING INTERESTS

The authors declare no competing interests.

REFERENCES

- Tran D, Muesy-Dessole N, Josso N. Anti-Müllerian hormone is a functional marker of foetal sertoli cells. *Nature* 1977; 269: 411–2.
- Damiani D, Mascolli MA, Almeida MJ, Jaubert F, Fellous M, *et al*. Persistence of Müllerian remnants in complete androgen insensitivity syndrome. *J Pediatr Endocrinol Metab* 2002; 15: 1553–6.
- Josso N, Lamarre I, Picard JY, Berta P, Davies N, *et al*. Anti-Müllerian hormone in early human development. *Early Hum Dev* 1993; 33: 91–9.
- Palmer SJ, Burgoyne PS. *In situ* analysis of fetal, prepubertal and adult XX–XY chimaeric mouse testes: Sertoli cells are predominantly, but not exclusively, XY. *Development* 1991; 112: 265–8.
- Griswold MD. The central role of sertoli cells in spermatogenesis. *Semin Cell Dev Biol* 1998; 9: 411–6.
- Young J, Chanson P, Salenave S, Noel M, Brailly S, *et al*. Testicular anti-Müllerian hormone secretion is stimulated by recombinant human FSH in patients with congenital hypogonadotropic hypogonadism. *J Clin Endocrinol Metab* 2005; 90: 724–8.
- Nistal M, Abaurrea MA, Paniagua R. Morphological and histometric study on the human sertoli cell from birth to the onset of puberty. *J Anat* 1982; 134: 351–63.
- Neto FT, Bach PV, Najari BB, Li PS, Goldstein M. Spermatogenesis in humans and its affecting factors. *Semin Cell Dev Biol* 2016; 59: 10–26.
- Correia S, Cardoso HJ, Cavaco JE, Socorro S. Oestrogens as apoptosis regulators in mammalian testis: angels or devils? *Expert Rev Mol Med* 2015; 17: e2.
- Robertson DM. Inhibin and male. In: Reference Module in Biomedical Sciences. Cambridge: Elsevier; 2018.
- Erwin Goldberg BR. Spermatogenesis: overview. In: Reference Module in Biomedical Sciences. Massachusetts: Elsevier; 2018.
- Ohlander SJ, Lindgren MC, Lipshultz LI. Testosterone and male infertility. *Urol Clin North Am* 2016; 43: 195–202.
- Orth JM, Gonsalvus GL, Lamperti AA. Evidence from sertoli cell-depleted rats indicates that spermatid number in adults depends on numbers of sertoli cells produced during perinatal development. *Endocrinology* 1988; 122: 787–94.
- Orth JM. FSH-induced Sertoli cell proliferation in the developing rat is modified by beta-endorphin produced in the testis. *Endocrinology* 1986; 119: 1876–8.
- Johnston H, Baker PJ, Abel M, Charlton HM, Jackson G, *et al*. Regulation of sertoli cell number and activity by follicle-stimulating hormone and androgen during postnatal development in the mouse. *Endocrinology* 2004; 145: 318–29.
- Grinspon RP, Rey RA. Anti-Müllerian hormone and sertoli cell function in paediatric male hypogonadism. *Horm Res Paediatr* 2010; 73: 81–92.
- Lindhardt Johansen M, Hagen CP, Johannsen TH, Main KM, Picard JY, *et al*. Anti-Müllerian hormone and its clinical use in pediatrics with special emphasis on disorders of sex development. *Int J Endocrinol* 2013; 2013: 198698.
- Edelstein NY, Grinspon RP, Scheingart HF, Rey RA. Anti-Müllerian hormone as a marker of steroid and gonadotropin action in the testis of children and adolescents with disorders of the gonadal axis. *Int J Pediatr Endocrinol* 2016; 2016: 20.
- Grinspon RP, Ropelato MG, Bedecarras P, Loreti N, Ballerini MG, *et al*. Gonadotrophin secretion pattern in anorchid boys from birth to pubertal age: pathophysiological aspects and diagnostic usefulness. *Clin Endocrinol (Oxf)* 2012; 76: 698–705.
- Lukas-Croisier C, Lasala C, Nicaud J, Bedecarras P, Kumar TR, *et al*. Follicle-stimulating hormone increases testicular anti-Müllerian hormone (AMH) production through sertoli cell proliferation and a nonclassical cyclic adenosine 5'-monophosphate-mediated activation of the AMH gene. *Mol Endocrinol* 2003; 17: 550–61.
- De Santa Barbara P, Bonneaud N, Boizet B, Desclozeaux M, Moniot B, *et al*. Direct interaction of SRY-related protein SOX9 and steroidogenic factor 1 regulates transcription of the human anti-Müllerian hormone gene. *Mol Cell Biol* 1998; 18: 6653–65.
- Arango NA, Lovell-Badge R, Behringer RR. Targeted mutagenesis of the endogenous mouse *Mis* gene promoter: *in vivo* definition of genetic pathways of vertebrate sexual development. *Cell* 1999; 99: 409–19.
- Shen WH, Moore CC, Ikeda Y, Parker KL, Ingraham HA. Nuclear receptor steroidogenic factor 1 regulates the Müllerian inhibiting substance gene: a link to the sex determination cascade. *Cell* 1994; 77: 651–61.
- Giulii G, Shen WH, Ingraham HA. The nuclear receptor SF-1 mediates sexually dimorphic expression of Müllerian inhibiting substance, *in vivo*. *Development* 1997; 124: 1799–807.
- Watanabe K, Clarke TR, Lane AH, Wang X, Donahoe PK. Endogenous expression of Müllerian inhibiting substance in early postnatal rat sertoli cells requires multiple steroidogenic factor-1 and GATA-4-binding sites. *Proc Natl Acad Sci U S A* 2000; 97: 1624–9.
- Tremblay JJ, Viger RS. Transcription factor GATA-4 enhances Müllerian inhibiting substance gene transcription through a direct interaction with the nuclear receptor SF-1. *Mol Endocrinol* 1999; 13: 1388–401.
- Beau C, Rauch M, Joulin V, Jegou B, Guerrier D. GATA-1 is a potential repressor of anti-Müllerian hormone expression during the establishment of puberty in the mouse. *Mol Reprod Dev* 2000; 56: 124–38.
- Rey RA, Grinspon RP. Normal male sexual differentiation and aetiology of disorders of sex development. *Best Pract Res Clin Endocrinol Metab* 2011; 25: 221–38.
- Rey R, Lukas-Croisier C, Lasala C, Bedecarras P. AMH/MIS: what we know already about the gene, the protein and its regulation. *Mol Cell Endocrinol* 2003; 211: 21–31.
- Lyon MF, Hawkes SG. X-linked gene for testicular feminization in the mouse. *Nature* 1970; 227: 1217–9.
- Charest NJ, Zhou ZX, Lubahn DB, Olsen KL, Wilson EM, *et al*. A frameshift mutation destabilizes androgen receptor messenger RNA in the Tfm mouse. *Mol Endocrinol* 1991; 5: 573–81.
- Al-Attar L, Noel K, Dutertre M, Belville C, Forest MG, *et al*. Hormonal and cellular regulation of sertoli cell anti-Müllerian hormone production in the postnatal mouse. *J Clin Invest* 1997; 100: 1335–43.
- Bougneres P, Francois M, Pantalone L, Rodrigue D, Bouvattier C, *et al*. Effects of an early postnatal treatment of hypogonadotropic hypogonadism with a continuous subcutaneous infusion of recombinant follicle-stimulating hormone and luteinizing hormone. *J Clin Endocrinol Metab* 2008; 93: 2202–5.
- Rey R, Lordereau-Richard I, Carel JG, Barbet P, Cate RL, *et al*. Anti-mullerian hormone and testosterone serum levels are inversely during normal and precocious pubertal development. *J Clin Endocrinol Metab* 1993; 77: 1220–6.
- Young J, Rey R, Couzinet B, Chanson P, Josso N, *et al*. Anti-Müllerian hormone in patients with hypogonadotropic hypogonadism. *J Clin Endocrinol Metab* 1999; 84: 2696–9.
- Aksglaede L, Sorensen K, Boas M, Mouritsen A, Hagen CP, *et al*. Changes in anti-Müllerian hormone (AMH) throughout the life span: a population-based study of 1027 healthy males from birth (cord blood) to the age of 69 years. *J Clin Endocrinol Metab* 2010; 95: 5357–64.
- Grinspon RP, Bedecarras P, Ballerini MG, Iniguez G, Rocha A, *et al*. Early onset of primary hypogonadism revealed by serum anti-Müllerian hormone determination during infancy and childhood in trisomy 21. *Int J Androl* 2011; 34: e487–98.
- Josso N, Rey R, Picard JY. Testicular anti-Müllerian hormone: clinical applications in DSD. *Semin Reprod Med* 2012; 30: 364–73.
- Werner R, Grottsch H, Hiort O. 46,XY disorders of sex development – the undermasculinised male with disorders of androgen action. *Best Pract Res Clin Endocrinol Metab* 2010; 24: 263–77.
- Bukhari I, Li G, Wang L, Iqbal F, Zhang H, *et al*. Effects of androgen receptor mutation on testicular histopathology of patient having complete androgen insensitivity. *J Mol Histol* 2017; 48: 159–67.
- Chang C, Chen YT, Yeh SD, Xu Q, Wang RS, *et al*. Infertility with defective spermatogenesis and hypotestosteronemia in male mice lacking the androgen receptor in sertoli cells. *Proc Natl Acad Sci U S A* 2004; 101: 6876–81.
- Rey R, Josso N. Regulation of testicular anti-Müllerian hormone secretion. *Eur J Endocrinol* 1996; 135: 144–52.
- McKay LI, Cidlowski JA. Molecular control of immune/inflammatory responses: interactions between nuclear factor-kappa B and steroid receptor-signaling pathways. *Endocr Rev* 1999; 20: 435–59.
- McKay LI, Cidlowski JA. Cross-talk between nuclear factor-kappa B and the steroid hormone receptors: mechanisms of mutual antagonism. *Mol Endocrinol* 1998; 12: 45–56.
- Corbier P, Edwards DA, Roffi J. The neonatal testosterone surge: a comparative study. *Arch Int Physiol Biochim Biophys* 1992; 100: 127–31.
- Matuszczak E, Hermanowicz A, Komarowska M, Debek W. Serum AMH in physiology and pathology of male gonads. *Int J Endocrinol* 2013; 2013: 128907.
- Chemes HE, Rey RA, Nistal M, Regadera J, Musse M, *et al*. Physiological androgen insensitivity of the fetal, neonatal, and early infantile testis is explained by the ontogeny of the androgen receptor expression in sertoli cells. *J Clin Endocrinol Metab* 2008; 93: 4408–12.
- Jost A. Problems of fetal endocrinology: the gonadal and hypophyseal hormones. *Recent Prog Horm Res* 1953; 8: 379–418.

- 49 Picard JY, Cate RL, Racine C, Josso N. The persistent Müllerian duct syndrome: an update based upon a personal experience of 157 cases. *Sex Dev* 2017; 11: 109–25.
- 50 Anawalt BD, Bebb RA, Matsumoto AM, Groome NP, Illingworth PJ, *et al*. Serum inhibin B levels reflect sertoli cell function in normal men and men with testicular dysfunction. *J Clin Endocrinol Metab* 1996; 81: 3341–5.
- 51 Iliadou PK, Tsametsis C, Kaprara A, Papadimas I, Goulis DG. The sertoli cell: novel clinical potentiality. *Hormones (Athens)* 2015; 14: 504–14.
- 52 Hipler UC, Hochheim B, Knoll B, Tittelbach J, Schreiber G. Serum inhibin B as a marker for spermatogenesis. *Arch Androl* 2001; 46: 217–22.
- 53 Kolon TF, Herndon CD, Baker LA, Baskin LS, Baxter CG, *et al*. Evaluation and treatment of cryptorchidism: AUA guideline. *J Urol* 2014; 192: 337–45.
- 54 Kollin C, Granholm T, Nordenskjold A, Ritzen EM. Growth of spontaneously descended and surgically treated testes during early childhood. *Pediatrics* 2014; 131: e1174–80.
- 55 van der Plas EM, Zijk GW, Froeling FM, van der Voort-Doedens LM, Meij-de Vries A, *et al*. Long-term testicular volume after orchiopexy at diagnosis of acquired undescended testis. *J Urol* 2013; 190: 257–62.
- 56 Matuszczak E, Hermanowicz A, Debek W, Oksiuta M, Dzienis-Koronkiewicz E, *et al*. Serum AMH concentration as a marker evaluating gonadal function in boys operated on for unilateral cryptorchidism between 1st and 4th year of life. *Endocrine* 2012; 41: 334–7.
- 57 Demircan M, Akinci A, Mutus M. The effects of orchiopexy on serum anti-Müllerian hormone levels in unilateral cryptorchid infants. *Pediatr Surg Int* 2006; 22: 271–3.
- 58 Guibourdenche J, Lucidarme N, Chevenne D, Rigal O, Nicolas M, *et al*. Anti-Müllerian hormone levels in serum from human foetuses and children: pattern and clinical interest. *Mol Cell Endocrinol* 2003; 211: 55–63.
- 59 Cortes D. Cryptorchidism—aspects of pathogenesis, histology and treatment. *Scand J Urol Nephrol Suppl* 1998; 196: 1–54.
- 60 Engeler DS, Hosli PO, John H, Bannwart F, Sulser T, *et al*. Early orchiopexy: prepubertal intratubular germ cell neoplasia and fertility outcome. *Urology* 2000; 56: 144–8.
- 61 Lee PA, O'Leary LA, Songer NJ, Coughlin MT, Bellinger MF, *et al*. Paternity after unilateral cryptorchidism: a controlled study. *Pediatrics* 1996; 98: 676–9.
- 62 Thorup J, McLachlan R, Cortes D, Nation TR, Balic A, *et al*. What is new in cryptorchidism and hypospadias – a critical review on the testicular dysgenesis hypothesis. *J Pediatr Surg* 2010; 45: 2074–86.
- 63 Lee PA, Coughlin MT. Fertility after bilateral cryptorchidism. Evaluation by paternity, hormone, and semen data. *Horm Res* 2001; 55: 28–32.
- 64 Cortes D, Thorup JM, Beck BL. Quantitative histology of germ cells in the undescended testes of human fetuses, neonates and infants. *J Urol* 1995; 154: 1188–92.
- 65 Hero M, Tommiska J, Vaaralahti K, Laitinen EM, Sipilä I, *et al*. Circulating antimüllerian hormone levels in boys decline during early puberty and correlate with inhibin B. *Fertil Steril* 2012; 97: 1242–7.
- 66 Rey RA, Grinspon RP, Gottlieb S, Pasqualini T, Knoblovits P, *et al*. Male hypogonadism: an extended classification based on a developmental, endocrine physiology-based approach. *Andrology* 2013; 1: 3–16.
- 67 Coutant R, Biette-Demeneix E, Bouvattier C, Bouhours-Nouet N, Gatelais F, *et al*. Baseline inhibin B and anti-Müllerian hormone measurements for diagnosis of hypogonadotropic hypogonadism (HH) in boys with delayed puberty. *J Clin Endocrinol Metab* 2010; 95: 5225–32.
- 68 Adan L, Lechevalier P, Couto-Silva AC, Boissan M, Trivin C, *et al*. Plasma inhibin B and antimüllerian hormone concentrations in boys: discriminating between congenital hypogonadotropic hypogonadism and constitutional pubertal delay. *Med Sci Monit* 2010; 16: CR511–7.
- 69 Klami R, Mankonen H, Perheentupa A. Successful microdissection testicular sperm extraction for men with non-obstructive azoospermia. *Reprod Bio* 2018; 18: 137–42.
- 70 Madani AH, Falahatkar S, Heidarzadeh A, Roshan ZA, Sazgari E, *et al*. Sensitivity and specificity of serum FSH and testis size in predicting the existence of spermatogenesis in azoospermic infertile men. *Andrologia* 2012; 44: 205–9.
- 71 Esteves SC, Miyaoka R, Agarwal A. An update on the clinical assessment of the infertile male. [corrected]. *Clinics (Sao Paulo)* 2011; 66: 691–700.
- 72 La Marca A, Pati M, Orvieto R, Stabile G, Carducci Artensio A, *et al*. Serum anti-Müllerian hormone levels in women with secondary amenorrhea. *Fertil Steril* 2006; 85: 1547–9.
- 73 Dabaja AA, Schlegel PN. Microdissection testicular sperm extraction: an update. *Asian J Androl* 2013; 15: 35–9.
- 74 Althakafi SA, Mustafa OM, Seyam RM, Al-Hathal N, Kattan S. Serum testosterone levels and other determinants of sperm retrieval in microdissection testicular sperm extraction. *Transl Androl Urol* 2017; 6: 282–7.
- 75 Li H, Chen LP, Yang J, Li MC, Chen RB, *et al*. Predictive value of FSH, testicular volume, and histopathological findings for the sperm retrieval rate of microdissection TESE in nonobstructive azoospermia: a meta-analysis. *Asian J Androl* 2018; 20: 30–6.
- 76 Isikoglu M, Ozgur K, Oehninger S, Ozdem S, Seleker M. Serum anti-Müllerian hormone levels do not predict the efficiency of testicular sperm retrieval in men with non-obstructive azoospermia. *Gynecol Endocrinol* 2006; 22: 256–60.
- 77 Cissen M, Meijerink AM, D'Hauwers KW, Meissner A, van der Weide N, *et al*. Prediction model for obtaining spermatozoa with testicular sperm extraction in men with non-obstructive azoospermia. *Hum Reprod* 2016; 31: 1934–41.
- 78 Schlegel PN. Testicular sperm extraction: microdissection improves sperm yield with minimal tissue excision. *Hum Reprod* 1999; 14: 131–5.
- 79 Ramasamy R, Padilla WO, Osterberg EC, Srivastava A, Reifsnnyder JE, *et al*. A comparison of models for predicting sperm retrieval before microdissection testicular sperm extraction in men with nonobstructive azoospermia. *J Urol* 2013; 189: 638–42.
- 80 Wikstrom AM, Raivio T, Hadziselimovic F, Wikstrom S, Tuuri T, *et al*. Klinefelter syndrome in adolescence: onset of puberty is associated with accelerated germ cell depletion. *J Clin Endocrinol Metab* 2004; 89: 2263–70.
- 81 Forti G, Corona G, Vignozzi L, Krausz C, Maggi M. Klinefelter's syndrome: a clinical and therapeutical update. *Sex Dev* 2010; 4: 249–58.
- 82 Aksglaede L, Christiansen P, Sorensen K, Boas M, Linneberg A, *et al*. Serum concentrations of anti-Müllerian hormone (AMH) in 95 patients with Klinefelter syndrome with or without cryptorchidism. *Acta Paediatr* 2011; 100: 839–45.
- 83 Bastida MG, Rey RA, Bergada I, Bedecarras P, Andreone L, *et al*. Establishment of testicular endocrine function impairment during childhood and puberty in boys with Klinefelter syndrome. *Clin Endocrinol (Oxf)* 2007; 67: 863–70.
- 84 Lee MM, Misra M, Donahoe PK, MacLaughlin DT. MIS/AMH in the assessment of cryptorchidism and intersex conditions. *Mol Cell Endocrinol* 2003; 211: 91–8.
- 85 Stoppa-Vaucher S, Djemli A, Van Vliet G. Undetectable AMH at 3 days of age: a clue to bilateral anorchia. *Clin Biochem* 2010; 43: 1373–4.
- 86 Szarras-Czapnik M, Gajewska M, Książyk J, Janas R, Ginalska-Malinowska M. [Anti-Müllerian hormone (AMH) measurements in the assessment of testicular function in prepubertal boys and in sexual differentiation disorders]. *Endokrynol Diabetol Chor Przemiany Materii Wieku Rozw* 2006; 12: 195–9. [Article in Polish].
- 87 Redmon JB, Carey P, Pryor JL. Varicocele—the most common cause of male factor infertility? *Hum Reprod Update* 2002; 8: 53–8.
- 88 Gorelick JJ, Goldstein M. Loss of fertility in men with varicocele. *Fertil Steril* 1993; 59: 613–6.
- 89 Li H, Dubocq F, Jiang Y, Tiguert R, Gheiler EL, *et al*. Effect of surgically induced varicocele on testicular blood flow and sertoli cell function. *Urology* 1999; 53: 1258–62.
- 90 Cameron DF, Snyder FE, Ross MH, Drylie DM. Ultrastructural alterations in the adluminal testicular spermiation in men with varicocele. *Fertil Steril* 1980; 33: 526–33.
- 91 Goulis DG, Iliadou PK, Tsametsis C, Gerou S, Tarlatzis BC, *et al*. Serum anti-Müllerian hormone levels differentiate control from subfertile men but not men with different causes of subfertility. *Gynecol Endocrinol* 2008; 24: 158–60.
- 92 Trigo RV, Bergada I, Rey R, Ballerini MG, Bedecarras P, *et al*. Altered serum profile of inhibin B, Pro-alphaC and anti-Müllerian hormone in prepubertal and pubertal boys with varicocele. *Clin Endocrinol (Oxf)* 2004; 60: 758–64.
- 93 Goulis D, Mirtziori G, Koliakos N, Hatzichristou D, Papadimas I, *et al*. Inhibin B and anti-Müllerian hormone in spermatic vein of subfertile men with varicocele. *Reprod Sci* 2011; 18: 551–5.
- 94 Volkl TM, Dorr HG, McCune-Albright syndrome: clinical picture and natural history in children and adolescents. *J Pediatr Endocrinol Metab* 2006; 19 Suppl 2: 551–9.
- 95 Coutant R, Lumbroso S, Rey R, Lahlou N, Venara M, *et al*. Macroorchidism due to autonomous hyperfunction of sertoli cells and G(s)alpha gene mutation: an unusual expression of McCune-Albright syndrome in a prepubertal boy. *J Clin Endocrinol Metab* 2001; 86: 1778–81.
- 96 Mamkin I, Philibert P, Anhalt H, Ten S, Sultan C. Unusual phenotypical variations in a boy with McCune-Albright syndrome. *Horm Res Paediatr* 2010; 73: 215–22.
- 97 Rey RA, Venara M, Coutant R, Trabut JB, Rouleau S, *et al*. Unexpected mosaicism of R201H-GNAS1 mutant-bearing cells in the testes underlie macro-orchidism without sexual precocity in McCune-Albright syndrome. *Hum Mol Genet* 2006; 15: 3538–43.
- 98 Gunes S, Hekim GN, Arslan MA, Ascı R. Effects of aging on the male reproductive system. *J Assist Reprod Genet* 2016; 33: 441–54.
- 99 Johnson L, Petty CS, Neaves WB. Age-related variation in seminiferous tubules in men. A stereologic evaluation. *J Androl* 1986; 7: 316–22.
- 100 Chong YH, Dennis NA, Connolly MJ, Teh R, Jones GT, *et al*. Elderly men have low levels of anti-Müllerian hormone and inhibin B, but with high interpersonal variation: a cross-sectional study of the sertoli cell hormones in 615 community-dwelling men. *PLoS One* 2013; 8: e70967.
- 101 Ramezani Tehrani F, Mansournia MA, Solaymani-Dodaran M, Minooe S, Azizi F. Serum variations of anti-Müllerian hormone and total testosterone with aging in healthy adult Iranian men: a population-based study. *PLoS One* 2017; 12: e0179634.

This is an open access journal, and articles are distributed under the terms of the Creative Commons Attribution-NonCommercial-ShareAlike 4.0 License, which allows others to remix, tweak, and build upon the work non-commercially, as long as appropriate credit is given and the new creations are licensed under the identical terms.

©The Author(s) (2018)

