

## Rapidly Progressive Gas-containing Lumbar Spinal Epidural Abscess

Jin Hyuk Bang, Keun-Tae Cho

Department of Neurosurgery, Dongguk University Ilsan Hospital, Goyang, Korea and Dongguk University, Seoul, Korea

Gas-containing (emphysematous) infections of the abdomen, pelvis, and extremities are well-known disease entities, which can potentially be life-threatening. They require aggressive medical and often surgical treatment. In the neurosurgical field, some cases of gas-containing brain abscess and subdural empyema have been reported. Sometimes they progress rapidly and even can cause fatal outcome. However, gas-containing spinal epidural abscess has been rarely reported and clinical course is unknown. We report on a case of rapidly progressive gas-containing lumbar spinal epidural abscess due to *Enterococcus faecalis* in a 72-year-old male patient with diabetes mellitus.

**Key Words:** Epidural abscess · Spine · *Enterococcus faecalis*

### INTRODUCTION

Emphysematous (gas-containing or gas-forming) infections of the body, especially in the abdomen and pelvis, are potentially life-threatening conditions that require prompt diagnostic work-up and aggressive medical and/or surgical treatment<sup>8)</sup>. In the neurosurgical field, although rare, cases of gas-containing brain abscess, subdural empyema, discitis, and spinal intradural abscess have been reported, and sometimes rapid clinical deterioration and even death occurred<sup>1,3,4,15)</sup>. Gas-containing spinal epidural abscess (SEA) is also very rare and only a few cases have been reported<sup>10,12-14)</sup>. In one of the reported cases of gas-containing SEA, the patient developed septic shock and died within 3 days after the onset of symptoms<sup>13)</sup>.

*Enterococcus faecalis* is an anaerobic Gram positive coccus and commensally inhabits the gastrointestinal tract<sup>19)</sup>. While this normally does not cause disease in the intestine, it can be pathogenic when infecting sites outside of the gut<sup>19)</sup>. In the neurosurgical field, although rare, it can cause brain abscess, subdural empyema, discitis, osteomyelitis, and SEA<sup>2,5,11,16,18,20)</sup>. They are one of the pathogens of gas-containing infections in the extremities, such as non-clostridial gas gangrene and necrotizing fasciitis<sup>6)</sup>. However, gas-containing SEA due to *E. faecalis*

was rarely reported. Here, we report on a case of rapidly progressive gas-containing lumbar SEA due to *E. faecalis* in a 72-year-old male patient with diabetes mellitus (DM).

### CASE REPORT

A 72-year-old man presented to the emergency department with a 3-day history of increasing low back pain (LBP). He was receiving medication for DM and hypertension for 2 years. He had no recent history of febrile illness and had not received any spinal procedure or intervention. On examination, he was afebrile, had no pain in the legs, and no neurological deficit. Magnetic resonance imaging (MRI) of the lumbar spine in the emergency department showed abnormal signal intensity in the L4-L5 intervertebral disc and in the L4 and L5 vertebral bodies. Gas was evident in the lumbar spinal canal. Thecal sac compression from a posterior epidural lesion was demonstrated from L4 to S1 level (Fig. 1A, B). Under the suspicion of lumbar SEA, he was admitted to the neurosurgical department. On admission, blood lab and blood culture were done. The laboratory findings showed a white blood cell (WBC) count of 10,890 cells/mm<sup>3</sup> (normal: 4,000-10,000 cells/mm<sup>3</sup>), an erythrocyte sedimentation rate (ESR) of 129 mm/h (normal: 0-9 mm/h), and a C-reactive protein (CRP) level of 15.79 mg/dL (normal: <0.5 mg/dL). Hemoglobin A1c (HbA1c) was 8.1% (normal: 4.0-5.6%).

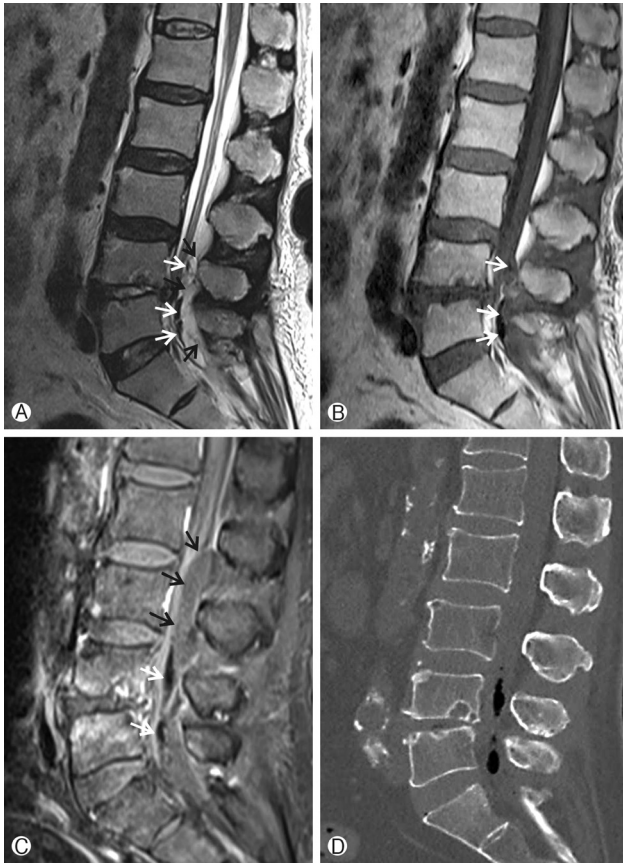
He was febrile from the night of the day of admission. LBP worsened and numbness in the legs developed. Gadolinium-enhanced MRI performed the next day revealed markedly increased extent of the epidural abscess from lower L2, increased amount of gas, and anteriorly displaced cauda equina (Fig. 1C). Gas was clearly demonstrated in non-enhanced compu-

• Received: June 17, 2015 • Revised: July 28, 2015

• Accepted: July 31, 2015

Corresponding Author: Keun-Tae Cho, MD, PhD  
Department of Neurosurgery, Dongguk University Ilsan Hospital, 27,  
Dongguk-ro, Ilsandong-gu, Goyang-si, Gyeonggi-do 10326, Korea  
Tel: +82-31-961-7322, Fax: +82-31-961-7327  
E-mail: ktcho21@naver.com

©This is an Open Access article distributed under the terms of the Creative Commons Attribution Non-Commercial License (<http://creativecommons.org/licenses/by-nc/3.0/>) which permits unrestricted non-commercial use, distribution, and reproduction in any medium, provided the original work is properly cited.



**Fig. 1.** Magnetic resonance imaging of the lumbar spine. (A) Sagittal T2-weighted image and (B) sagittal T1-weighted image show abnormal signal intensity in the L4-L5 intervertebral disc and in the L4 and L5 vertebral bodies, air (white arrows) within the spinal canal at L5 level, and posterior epidural mass (black arrows) from L4 to S1 level. (C) Gadolinium-enhanced magnetic resonance image on the following day shows markedly increased extent of epidural abscess (black arrows) from lower L2 to S1 level and anteriorly displaced cauda equina. Increased amount of gas (white arrows) is also evident. (D) Non-enhanced computed tomography scan shows gas within the spinal canal.

ted tomography (CT) scan of the lumbar spine (Fig. 1D).

Under the impression of lumbar SEA, he was brought to the operating room for an emergent operation. Just before starting to the operating room, he complained of residual urine sensation after voiding. He underwent multilevel laminectomy from L3 to S1 and evacuation of the abscess. Frank pus was identified in the epidural space. Cultures from the epidural abscess and the L4-L5 disc grew *E. faecalis*. Blood cultures performed on the day of admission also grew *E. faecalis*. The pathogen was sensitive to ampicillin and antibiotic treatment with intravenous ampicillin was begun. Intravenous ampicillin was administered for 6 weeks and discontinued without additional oral antibiotic treatment. On discharge, his pain and

clinical condition improved greatly and the WBC count, ESR, and CRP levels were within normal limits.

## DISCUSSION

Gas-containing infection can occur in many regions and organs in the body. Gas-containing infections of the abdomen, pelvis, and extremities are well-known<sup>6,8</sup>. Gas-formation infections can occur with both aerobic and anaerobic microorganisms<sup>15</sup>. Carbon dioxide and water are the end products of aerobic metabolism<sup>15</sup>. Hydrogen, nitrogen, hydrogen sulfide and methane are produced from the combination of aerobic metabolism and anaerobic fermentation<sup>15</sup>. Of these gases, carbon dioxide diffuses rapidly into the surrounding tissues and is quickly absorbed because of its water solubility<sup>15</sup>. Other gases, except carbon dioxide, accumulate in tissues because of their reduced solubility in water<sup>1,15</sup>. The most common predisposing factor for gas-containing infections is reported to be DM<sup>6</sup>. High blood glucose from poorly controlled DM and poor glycolysis at the tissue level in diabetic patients may contribute to increased glucose concentrations within the interstitial fluid<sup>1,8</sup>. Organisms then use the accumulated glucose to produce gases including carbon dioxide and hydrogen by means of anaerobic fermentation<sup>8</sup>. In the present case, HbA1c measured on the day of admission was 8.1%. HbA1c measures long-term glycemic control, reflecting a time-weighted mean over the previous 3 to 4 months<sup>17</sup>. A direct relationship exists between HbA1c and mean glycemia because erythrocytes are continuously glycated during their 120-day lifespan and the rate of glycohemoglobin formation is proportional to the ambient glucose concentration<sup>17</sup>. In the Diabetes Control and Complications Trial, a HbA1c of 6% corresponded to a mean plasma glucose level of 135 mg/dL, and each 1% increase in HbA1c corresponded to an increase in mean plasma glucose level of approximately 35 mg/dL<sup>17</sup>. Therefore, mean glucose level over recent 3 to 4 months of the patient was more than 200 mg/dL in the present case. This suggested that the poorly controlled blood glucose of the patient rendered him susceptible to gas-containing infections and to increased gas production.

Gas-forming infections can cause potentially life-threatening conditions<sup>8</sup>. In infections of the abdomen and pelvis, the initial clinical manifestation may be insidious, but rapid progression to sepsis and even death can occur<sup>8</sup>. In cases of gas-containing brain abscess, subdural empyema, discitis, and spinal intradural abscess, rapid deterioration of the clinical status and death have been reported<sup>1,3,4,15</sup>. In a case of gas-containing SEA, fatal outcome due to rapid progression was reported<sup>13</sup>. Kökeş et al.<sup>13</sup> reported that a 52-year-old man with DM developed septic shock and died on the third postopera-

tive day despite emergent laminectomy and evacuation of abscess. Although the final outcome was favorable, the patient's initial symptom was only LBP, but pain worsened, and numbness in the legs and residual urine sensation after voiding developed in a short time in the present case.

*Enterococcus* is fast emerging as a major pathogen causing serious and life threatening bacteremia and endocarditis<sup>18</sup>. It is also increasingly being implicated in spine infections<sup>18</sup>. In 2004, Tarr et al.<sup>18</sup> reviewed 12 cases of enterococcal vertebral osteomyelitis and they noted 9 cases were reported since 1995, which may reflect the emergence of the enterococcus as a clinically important pathogen in the recent decades. In a recently published large series of SEA, the incidence of enterococcal infection was about 2.6% (2 out of 77 cases) and 4% (3 out of 82 cases)<sup>2</sup>. This emergence may be the result of the increased clinical application of broad-spectrum antimicrobial therapy without significant activity against enterococci, such as cephalosporins, quinolones, and macrolides<sup>18</sup>. Exposure to such antibiotics has been identified as a risk factor for colonization and infection by enterococci<sup>18</sup>.

*E. faecalis* is a major (80-90%) pathogen of human enterococcal infection<sup>19</sup>. Although rare, it can cause brain abscess and subdural empyema<sup>5,11</sup>. Also it can cause discitis, vertebral osteomyelitis, and SEA<sup>2,16,18,20</sup>. We could not find any exclusive case report or case series of SEA due to *E. faecalis* in MEDLINE search. Therefore, characteristic radiologic findings such as formation of gas, and clinical course are unknown. In cases of brain abscess and subdural empyema, no fatal case has been reported. In a case of brain abscess following ischemic stroke, multiple punctuate lesion of low signal intensity was found in MRI<sup>5</sup>. However, the causative organisms were *Escherichia coli* and *E. faecalis*, so it was uncertain which organism was responsible for gas formation<sup>5</sup>. In a case of osteomyelitis with paravertebral abscess due to *E. faecalis*, the presence of gas in the retroperitoneum adjacent to the infected vertebra was found in CT scan, the condition of the patient deteriorated quickly, and subsequently died<sup>20</sup>. In the previously reported cases of gas-containing SEA, the pathogens were *Staphylococcus aureus*, *E. coli*, a mixed *Streptococcus*, *Peptostreptococcus*, and *Bacteroides*, and *Aeromonas hydrophila*<sup>12-14</sup>. However, in our opinion, *E. faecalis* can cause gas-containing SEA. *E. faecalis* ferments some sugars with gas production<sup>9</sup>. Although *E. faecalis* typically ferments glucose without gas formation, but some strains produce sufficient gas from glucose<sup>7</sup>. In the above mentioned case of osteomyelitis due to *E. faecalis*, gas was found in CT scan<sup>20</sup>. *E. faecalis* is one of the pathogens of gas-containing infections in the extremities, such as gas gangrene and necrotizing fasciitis<sup>6</sup>. *Clostridium* is a major cause of gas gangrene in the extremities, however, in non-clostridial gas gangrene, *E. faecalis* is one of the pathogens<sup>6</sup>. *E. faecalis*

was reported to be the most common organism in necrotizing fasciitis, in which the presence of gas in tissues is an important radiological finding<sup>6</sup>. In the present case, only *E. faecalis* grew from the disc aspirates and epidural abscess. Gas within the spinal canal might be produced from anaerobic fermentation by *E. faecalis*. *E. faecalis* might have spread hematogenously to the lumbar spine; this is plausible, given its recovery from the blood culture.

## CONCLUSION

Gas-containing SEA can rapidly progress and result in clinical deterioration, especially in patients with DM. Therefore, close monitoring of the patient, prompt diagnostic work-up, initiation of appropriate use of antibiotics, and surgical treatment should be done to obtain a favorable outcome.

## REFERENCES

1. Adamides AA, Goldschlager T, Tulloch SJ, McMahon JH: Pneumocephalus from gas-forming *Escherichia coli* subdural empyema. **Br J Neurosurg** 21:299-300, 2007
2. Adogwa O, Karikari IO, Carr KR, Krucoff M, Ajay D, Fatemi P, et al: Spontaneous spinal epidural abscess in patients 50 years of age and older: a 15-year institutional perspective and review of the literature: clinical article. **J Neurosurg Spine** 20:344-349, 2014
3. Aghaei Lasboo A, Walker MT, Hijaz TA: An unusual appearance of discitis due to gas-forming *Escherichia coli* with associated pneumocephalus. **Spine (Phila Pa 1976)** 35:E257-259, 2010
4. Cho KT, Park BJ: Gas-forming brain abscess caused by *Klebsiella pneumoniae*. **J Korean Neurosurg Soc** 44:382-384, 2008
5. Davenport RJ, Gibson R, Mumford CJ, Will RG: Brain abscess complicating ischemic stroke. **Stroke** 26:1501-1503, 1995
6. Fazeli MS, Keramati MR: Necrotizing fasciitis: an epidemiologic study of 102 cases. **Indian J Surg** 69:136-139, 2007
7. Gillespie SH, Hawkey PM: Principles and Practice of Clinical Bacteriology, ed 2. West Sussex: **John Wiley & Sons**, pp59-60, 2006
8. Grayson DE, Abbott RM, Levy AD, Sherman PM: Emphysematous infections of the abdomen and pelvis: a pictorial review. **Radiographics** 22:543-561, 2002
9. Gupte S: The Short Textbook of Medical Microbiology for Dental Students, New Delhi: **Jaypee Brothers Medical Publishers**, pp136-137, 2012
10. Hur JW, Lee JB, Kim JH, Kim SH, Cho TH, Suh JK, et al: Unusual fatal infections after anterior cervical spine surgeries. **Korean J Spine** 9:304-308, 2012
11. Jones BL, Wilcox MH: Subdural empyema due to *Enterococcus faecalis*. **Scand J Infect Dis** 29:627-628, 1997
12. Kirzner H, Oh YK, Lee SH: Intraspinal air: a CT finding of epidural abscess. **Am J Roentgenol** 151:1217-1218, 1988
13. Kökeş F, Iplikçioğlu AC, Camurdanoğlu M, Bayar MA, Gökçek

- C: Epidural spinal abscess containing gas: MRI demonstration. **Neuroradiology** 35:497-498, 1993
14. Lee JS, Choi SM, Kim KW: Tripareisis caused by gas-containing extensive epidural abscess secondary to *Aeromonas hydrophila* infection of a thoracic vertebroplasty: a case report. **Spine J** 50:e9-e14, 2013
  15. Nadkarni T, Shah A, Kansal R, Goel A: An intradural-extradural gas-forming spinal abscess in a patient with diabetes mellitus. **J Clin Neurosci** 17:263-265, 2010
  16. Pascaretti C, Legrand E, Laporte J, Fromont P, Masson C, Brégeon C, et al: Bacterial endocarditis revealed by infectious discitis. **Rev Rhum Engl Ed** 63:119-123, 1996
  17. Saudek CD, Derr RL, Kalyani RR: Assessing glycemia in diabetes using self-monitoring blood glucose and hemoglobin A1c. **JAMA** 295:1688-1697, 2006
  18. Tarr PE, Sakoulas G, Ganesan A, Smith MA, Lucey DR: Hematogenous enterococcal vertebral osteomyelitis: report of 2 cases and review of the literature. **J Infect** 48:354-362, 2004
  19. Yuen GJ, Ausubel FM: *Enterococcus* infection biology: lessons from invertebrate host models. **J Microbiol** 52:200-210, 2014
  20. Zamora A, Florez J, Vidal F, Richart C: More on enterococcal osteoarticular infections: vertebral osteomyelitis. **Br J Rheumatol** 36:1132-1133, 1997