



## Case report

## Medial talonavicular dislocation with nondisplaced navicular fracture: A case report

Alanoud Algouaiz<sup>a,\*</sup>, Jawaher Alharbi<sup>b</sup>, Abdulmajeed Alwayil<sup>a</sup>, Mohammed Alattas<sup>a</sup><sup>a</sup> Security Forces Hospital, Riyadh, Saudi Arabia<sup>b</sup> King Khalid University Hospital, Riyadh, Saudi Arabia

## ARTICLE INFO

## Keywords:

Case report

Talonavicular dislocation

Navicular fracture

Medial swivel dislocation

## ABSTRACT

**Introduction:** Talonavicular dislocation is a rare injury that usually occurs following high-energy trauma. The mechanism of injury is a force of abduction or adduction applied to the forefoot. In this article, we present a rare case of medial talonavicular dislocation with a fracture of the navicular following low-energy trauma.

**Presentation of case:** We report a case of talonavicular dislocation with a navicular fracture in a 25-year-old male. He presented at the emergency department with a history of twisting injury to his left foot. Physical examination revealed an obvious deformity of his foot associated with tenderness. No neurological deficit was present. Radiograph and CT scan showed medial talonavicular dislocation and postero-lateral navicular fracture. Closed reduction was done followed by six weeks in a cast. The patient was followed up for six months and no complications were reported.

**Discussion:** Talonavicular dislocation is commonly associated with ligamentous disruption and midfoot fractures. Most studies reported this type of dislocation in association with a fracture of the navicular, cuboid, talus, calcaneus or metatarsal bones as a result of high-energy trauma. However, in our case, the dislocation resulted from low-energy trauma and was associated with a nondisplaced fracture of the navicular and a minimally impacted fracture of the talus that was treated conservatively.

**Conclusion:** Since this type of dislocation is rare, it is important to recognize it early to avoid complications such as painful equinovarus deformity. Early reduction and immobilization is the ideal treatment for this injury.

## 1. Introduction and importance

Talonavicular joint (TNJ) dislocation is a rare injury of the foot and ankle. It usually occurs after major trauma and is generally associated with a fracture rather than an isolated dislocation. We report a case of medial swivel dislocation of the TNJ associated with a minimally impacted fracture of the talus and a non-displaced posterolateral wall of the navicular caused by a low-energy trauma and its management. There are a few studies that discuss the outcome of the closed reduction for this subtype. This case was reported in line with the SCARE criteria [1].

## 2. Case presentation

A 25-year-old Saudi gentleman was brought to the emergency department in a wheelchair with a history of trauma to his left foot. He described that he twisted his foot and fell directly on it; his ankle was inverted and internally rotated while he was playing football. He could

not continue the game and was unable to bear weight. His past medical history was unremarkable. On examination, the patient was alert, conscious and oriented. He had a normal BMI. His vital signs were stable but he complained of a painful left foot. On local examination, there was an obvious swelling over the dorsal aspect of his left foot associated with tenderness. No open wounds were seen. The function of the ankle joint and the toes was normal. His neurovascular status was intact. Radiograph was done and it showed a left medial talonavicular dislocation (Fig. 1A, B and C). A CT scan was done to detect any associated fracture and it showed medial talonavicular dislocation with small bony fragments in the medial border of the talus and a fracture of the postero-lateral aspect of the navicular (Fig. 2A, B and C). The closed reduction was done in the emergency department by a senior resident under conscious sedation and it was achieved through traction and laterally directed force. Post-reduction radiograph showed good alignment of the joint (Fig. 3A, B and C), and for that reason there was no need to intervene surgically. A below-knee non-weight-bearing cast was

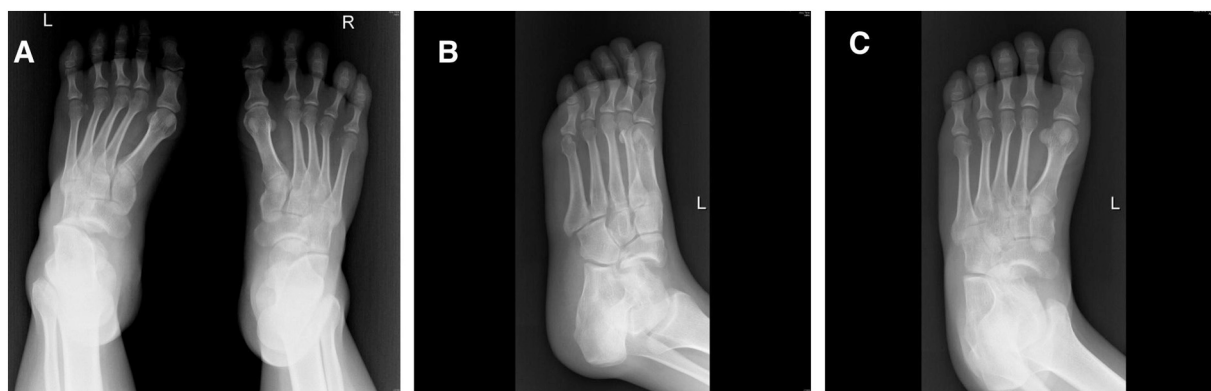\* Corresponding author.

E-mail address: [alanoud.algouaiz@hotmail.com](mailto:alanoud.algouaiz@hotmail.com) (A. Algouaiz).<https://doi.org/10.1016/j.ijscr.2021.106276>

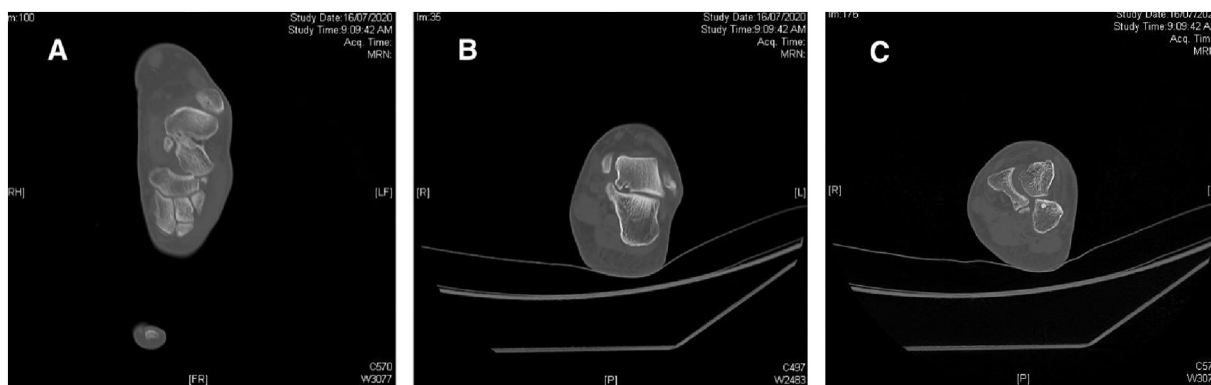
Received 30 June 2021; Received in revised form 1 August 2021; Accepted 1 August 2021

2210-2612/© 2021 Published by Elsevier Ltd on behalf of IJS Publishing Group Ltd. This is an open access article under the CC BY-NC-ND license

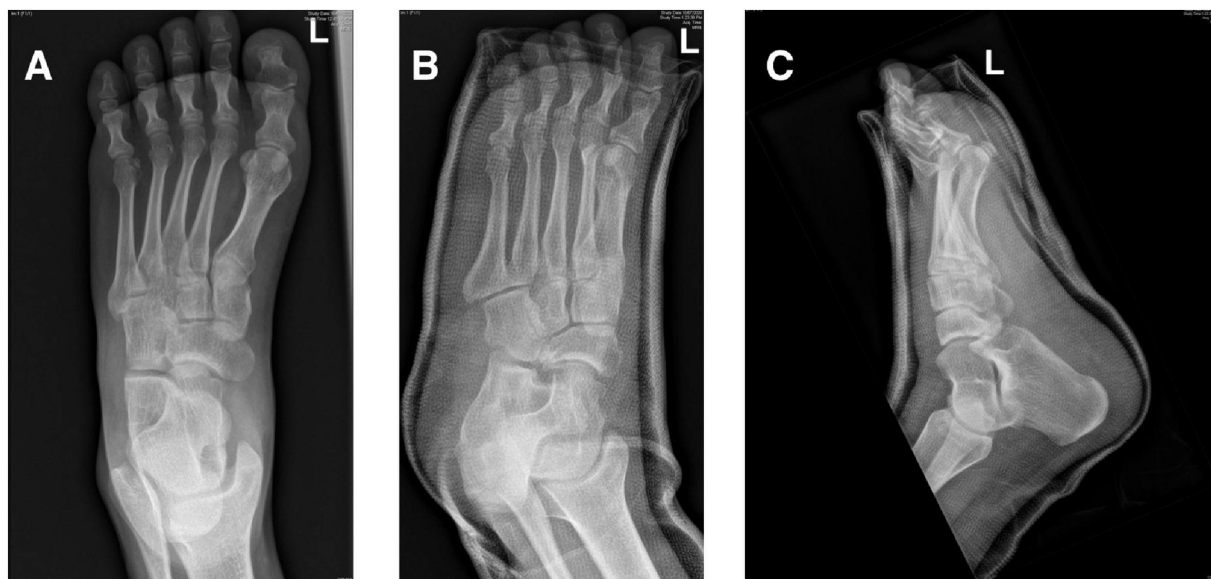
<http://creativecommons.org/licenses/by-nc-nd/4.0/>.



**Fig. 1.** A, B and C: X-ray of left foot (AP, Oblique, and standing views) showing medial dislocation of navicular.



**Fig. 2.** A, B and C: Computed tomography scan of left foot showing medial dislocation of navicular with postero-lateral navicular fracture and small bony fragments medial of the talus.



**Fig. 3.** A, B and C: Post closed reduction x-rays showing maintained alignment of the talonavicular joint.

applied. He was instructed to not bear weight on the injured limb for 6 weeks and discharged with a standard analgesia. Symptoms and signs of compartment syndrome were explained to the patient. The patient continued to be followed up in our hospital; he was seen in the outpatient clinic after three days. The cast was intact and the pain was controlled. A radiograph was done and it showed good alignment with

no displacement. He was followed up in the clinic at two weeks and one month post-closed reduction and on examination at that time, the foot was normal without any signs of instability with a good alignment on radiograph. After that the cast was removed and the patient commenced physiotherapy. At six months post-closed reduction follow up, he did physiotherapy and the pain had reduced. He regained full weight-

bearing and returned to his daily activities, however he was not able to do strenuous exercises like running and playing football due to severe pain. On examination, the patient had normal passive and active range of motion of the left ankle compared to the other side. Radiograph showed a good alignment with no signs of arthritis or instability.

### 3. Clinical discussion

Dislocation of the midtarsal joint—which is composed of the talonavicular and calcaneocuboid articulations— is a relatively rare injury of the foot and ankle due to the strong periarticular ligamentous support at this joint. The incidence of this injury is estimated at 3.6/100.000/year [2].

Isolated TNJ dislocation requires the disruption of both medial and lateral longitudinal columns of the foot, which usually occurs following high-energy trauma as reported in the literature. However, many case reports concluded that low energy trauma can also cause such an injury [3]. This unusual case shows that low-energy trauma can cause dislocations of the TNJ.

The rigid bony and ligamentous support surrounding the midtarsal joints are responsible for fracture associated with dislocation rather than a pure dislocation involving these joints [4]. The prevalence of concomitant injury with dislocation of the TNJ ranges from 75% to 90% [2]. A pure isolated TNJ dislocation without any associated subtalar joint dislocations or surrounding bone fractures is rare.

Williams et al. explained in their report that a fracture of the medial head of the talus could occur secondary to capsular avulsion of the talus during dislocation and possible navicular impaction into the medial talar head as the navicular is displaced medially [5]. We think the mechanism of injury, in this case, was similar to that in the case reported by Williams et al.

Main and Jowett classified midtarsal injuries according to the direction of deforming force and displacement into five groups (medial, longitudinal compression, lateral, plantar, and crush). A subtype pattern of injury is the swivel dislocation at the talonavicular joint [6]. Based on radiographic and CT findings, our case was classified as a medial swivel dislocation in which medially directed force dislocates the talonavicular joint, leaving the calcaneocuboid joint intact.

Up to 80% of the TNJ dislocations are medial and 17% are lateral [7]. Lateral swivel dislocation is usually associated with impacted fracture of calcaneocuboid joint [8], while medial swivel dislocation is not associated with such injuries. Williams et al. reported the first case of medial swivel dislocation associated with a fracture to the body of the cuboid [5]. Nondisplaced fracture of the navicular and a minimally impacted fracture of the talus were detected in this case report.

In one study, the authors recommended an early CT scan or proper radiographic views to evaluate for concomitant injuries associated with TNJ dislocation [9]. CT scan was done in this case for the same reason.

Richter et al. categorized the dislocations according to the treatment method as follows: closed reduction, no internal fixation; open reduction with internal fixation; optional additional external fixation; and amputation. An initial anatomical reduction was essential for good results in all groups [10].

In the Main and Jowett series, four patients with the medial-type dislocations were treated conservatively with a good outcome in one case and poor outcomes in three of them. When an open reduction was performed in three cases with poor outcomes it showed a good outcome in two cases and fair in one. For lateral-type dislocation one patient was involved that was treated with a closed reduction and plaster immobilization and it showed a good outcome [6].

Ritcher et al. concluded that a closed reduction yielded good results only with pure dislocations, when anatomic conditions could be restored and that an initial open reduction yields significantly better results than a closed reduction in all other cases [10].

In another series by Garofalo et al., they concluded that low-energy, medial dislocations are most amenable to closed reduction with a poorer

prognosis for either open dislocations or lateral dislocations [11].

Pehlivan described a case of medial TNJ dislocation requiring open reduction as the initial closed reduction was unsuccessful. The pathological findings that prevent the closed reaction determined during surgery and it included buttonholing of the head of the talus through the extensor retinaculum and fracture of the medial aspect of the talar head [12].

Nondisplaced fractures of the tarsal navicular can be treated in a cast with protected weight-bearing as long as the fracture's displacement is minimal [13]. Open reduction and internal fixation were performed in many cases of TNJ dislocation associated with talus fracture with a good outcome [4,9].

Closed reduction was achieved in another case of a 24-year-old man with a talonavicular dislocation associated with a nondisplaced fracture of the navicular, the patient was successfully employed as a manual worker two years after injury, and clinical examination did not reveal any pain or loss of movement range [11]. Similarly, the patient, in this case, was treated with closed reduction and he was able to achieve full weight-bearing after three months.

Regarding the postreduction immobilization protocol, there is a wide variety of suggestions. A splint is used until edema subsides and then replaced by a short leg cast or inflatable boot for 3 to 6 weeks. Thereafter, the patient is allowed full weight bearing ambulation [16].

### 4. Strengths and limitations

We believe that our case report will make a significant contribution to the literature because there are a few studies that discuss the outcome of the closed reduction for this subtype of dislocation and the illustration of our case will help orthopedic surgeon who encounter a similar case in the future. Nevertheless, more studies with a higher level of evidence and higher number of patients are needed to gain a better understanding and treatment protocol of TNJ dislocation.

### 5. Conclusion

Swivel type dislocation of the foot is a rare type of injury [2]. This injury can be caused by either medially or laterally directed force. It is usually caused by a high-energy trauma but in this case, it was caused by low-energy trauma. Proper diagnosis of this injury is necessary to determine the right treatment and achieve a good prognosis. The injury can be treated through early closed or open anatomical reduction. It also should be accompanied by a period of immobilization followed by rehabilitation.

### Ethical approval

The Security Forces Hospital Program Medical Affairs Research Committee has been requested to exempt the study from ethical approval.

### Sources of funding

None

### CRediT authorship contribution statement

1. Alanoud Algouaiz: Data collection, literature review, manuscript writing.
2. Jawaher Alharbi: Literature review, manuscript writing.
3. Abdulmajeed Alwayil: Data collection, manuscript review.
4. Mohammed Alattas: Manuscript writing and review.

### Guarantor

Mohammed Alattas

Orthopedic Surgery Consultant, Security Forces Hospital, Riyadh, Saudi Arabia.

## Research registration

None

## Consent

Written informed consent was obtained from the patient for publication of this case report and accompanying images. A copy of the written consent is available for review by the Editor-in-Chief of this journal on request.

## Provenance and peer review

Not commissioned, externally peer-reviewed.

## Declaration of competing interest

None

## References

- [1] for the SCARE Group, R.A. Agha, T. Franchi, C. Sohrabi, G. Mathew, The SCARE 2020 guideline: updating consensus Surgical CAse REport (SCARE) guidelines, *Int. J. Surg.* 84 (2020) 226–230.
- [2] K.B. van Dorp, M.R. de Vries, M. van der Elst, T. Schepers, Chopart joint injury: a study of outcome and morbidity, *J. Foot Ankle Surg.* 49 (6) (2010) 541–545, <https://doi.org/10.1053/j.jfas.2010.08.005>.
- [3] K.J. Jung, H.S. Lee, H.J. Chang, Y.K. Lee, E.D. Yeo, S.H. Won, H.K. Cho, A. Ryu, D. W. Lee, W.J. Kim, Pure isolated medial talonavicular joint dislocation following low-energy trauma: a case report, *J. Int. Med. Res.* 49 (4) (2021), 3000605211004697, <https://doi.org/10.1177/03000605211004697>.
- [4] P.M. Ross, D.C. Mitchell, Dislocation of the talonavicular joint: case report, *J. Trauma* 16 (5) (1976) 397–401, <https://doi.org/10.1097/00005373-197605000-00014>.
- [5] D.P. Williams, A. Hanoun, M. Hakimi, S. Ali, M. Khatri, Talonavicular dislocation with associated cuboid fracture following low-energy trauma, *Foot Ankle Surg.* 15 (3) (2009) 155–157, <https://doi.org/10.1016/j.fas.2008.10.001>.
- [6] B.J. Main, R.L. Jowett, Injuries of the midtarsal joint, *J. Bone Joint Surg.* 57 (1) (1975) 89–97. British.
- [7] D.J. Tucker, G. Burian, J.P. Boylan, Lateral subtalar dislocation: review of the literature and case presentation, *J. Foot Ankle Surg.* 37 (3) (1998) 239–262, [https://doi.org/10.1016/s1067-2516\(98\)80118-x](https://doi.org/10.1016/s1067-2516(98)80118-x).
- [8] M.B. Hermel, J. Gershon-Cohen, The nutcracker fracture of the cuboid by indirect violence, *Radiology* 60 (6) (1953) 850–854, <https://doi.org/10.1148/60.6.850>.
- [9] M.A. Hafez, M.A. Bawarish, R. Guvvala, Closed talar body fracture with talonavicular dislocation; a case report, *Foot Ankle Int.* 21 (7) (2000) 599–601, <https://doi.org/10.1177/107110070002100714>.
- [10] M. Richter, H. Thermann, T. Huefner, U. Schmidt, T. Goesling, C. Krettek, Chopart joint fracture-dislocation: initial open reduction provides better outcome than closed reduction, *Foot Ankle Int.* 25 (5) (2004) 340–348, <https://doi.org/10.1177/107110070402500512>.
- [11] R. Garofalo, B. Moretti, V. Ortolano, P. Cariola, G. Solarino, M. Wettstein, E. Mouhsine, Peritalar dislocations: a retrospective study of 18 cases, *J. Foot Ankle Surg.* 43 (3) (2004) 166–172, <https://doi.org/10.1053/j.jfas.2004.03.008>.
- [12] O. Pehlivan, I. Akmaz, C. Solakoglu, O. Rodop, Medial peritalar dislocation, *Arch. Orthop. Trauma Surg.* 122 (9–10) (2002) 541–543, <https://doi.org/10.1007/s00402-002-0448-x>.
- [13] G.A. Murphy, Fractures and dislocations of foot, in: S.T. Ca-nale (Ed.), *Campbell's Operative Orthopedics*, 9th edn., CV Mosby, St Louis, 1998, p. 1953.
- [16] I. Konstantinidis, P.D. Symeonidis, D. Polyzos, P. Antonarakos, P. Givissis, C. Dimitriou, Talonavicular dislocation-what lies beneath? *J. Am. Podiatr. Med. Assoc.* 108 (5) (2018) 397–404, <https://doi.org/10.7547/16-170>.