

ORIGINAL ARTICLE

Diagnostic utility of lung echography for congestive heart failure performed by junior resident doctors

Keiki Nagaharu MD¹  | Natsumi Tsumura MD² | Toshiyuki Itoh MD² | Tetsuya Murata MD³

¹Department of Hematology and Oncology, Suzuka General Hospital, Suzuka, Japan

²Department of Internal medicine, Suzuka General Hospital, Suzuka, Japan

³Department of Pathology, Suzuka General Hospital, Suzuka, Japan

Correspondence

Keiki Nagaharu, Department of Hematology and Oncology, Suzuka General Hospital, Suzuka, Japan.
Email: keiki-nagaharu@clin.mie-u.ac.jp

Abstract

Background: Dyspnea is a high priority symptom in the emergency department, with heart failure (HF) as one of its leading causes. Recently, the “comet tail sign (CTS),” a pulmonary ultrasonographic sign, has been proposed as an efficacious tool for detecting pulmonary edema. However, to the best of our knowledge, there have been no published data regarding its utility when performed by non-experts, including junior residents.

Methods: Between September 2017 and December 2018, patients with dyspnea, who were admitted to the ER, were enrolled. CTS was evaluated by junior residents at the ER. All patients were evaluated by cardiologists independently, and clinical HF was defined as requiring pharmacological intervention by a cardiologist. At the end of this study, we investigated the results of CTS, laboratory data, and available radiological images.

Results: A total of 95 patients were enrolled in the current study, wherein 42 patients were treated by cardiologists as those with clinical HF. Our results showed that CTS could identify clinical HF with a sensitivity of 71.4% and a specificity of 81.1%. The sensitivity of CTS against brain natriuretic peptide (BNP) (cut-off value, 100 pg/ml) was calculated at 92.5%. Furthermore, when evaluated together with peripheral edema, CTS identified clinical HF with a sensitivity of 96%. False positives for CTS included bilateral pneumonia, hypoalbuminemia, and interstitial pneumonitis.

Conclusions: Our results indicate that CTS is a simple and effective tool for the use of non-experts, including junior residents.

KEYWORDS

comet tail sign, dyspnea, heart failure, junior resident

1 | INTRODUCTION

Congestive heart failure (HF) is a leading cause of dyspnea in the emergency room (ER), and the number of patients with HF is increasing annually in Japan.¹ Although early diagnosis is necessary for

appropriate interventions of HF,² physical assessment requires skill, especially in auscultation.^{3,4} Recently, the use of ultrasound imaging for the detection of pulmonary edema—the BLUE (bedside lung ultrasound in emergency) protocol—has been reported to be a simple procedure, especially in emergency situations.⁵ The comet-tail sign

This is an open access article under the terms of the [Creative Commons Attribution-NonCommercial](https://creativecommons.org/licenses/by-nc/4.0/) License, which permits use, distribution and reproduction in any medium, provided the original work is properly cited and is not used for commercial purposes.

© 2022 The Authors. *Journal of General and Family Medicine* published by John Wiley & Sons Australia, Ltd on behalf of Japan Primary Care Association.

(CTS), one of the BLUE protocol items, is defined as hyperechoic reflections from the pleural line of the lung, which has shown clinical utility in several reports.⁶⁻¹⁴

However, to the best of our knowledge, no evidence has been published on the utility of the CTS among Japanese junior residents in real-world clinical situations. To examine this issue, we conducted a prospective observational study, which also explored the clinical factors associated with a false-positive CTS.

2 | METHODS

2.1 | Study design

We conducted a single-institute, prospective, observational study to identify whether CTS was effective for diagnosing HF in emergency settings when used by junior residents.

2.2 | Participants

We conducted a prospective study in Suzuka General Hospital. Three out of 12 junior residents, who were second-year doctors, voluntarily participated in this study and received brief instructions on the detection of CTS in accordance with a previous report.¹⁵ After oral informed consent, patients with dyspnea between September 2017 and December 2018, who were under the care of the three participating junior residents, were recruited for the study. Patients with the following criteria were excluded: age <18 years, having no consent, and requiring urgent interventions. Recruited patients were also evaluated using interstitial pulmonary ultrasound imaging as part of the physical evaluations at the ER. This research was approved by the Suzuka General Hospital ethical committee (no.170).

2.3 | Variables

All participants underwent physical examinations, brain natriuretic peptide (BNP) tests, and chest X-ray examinations. The CTS was visualized using Sonosite S (FUJIFILM Sonosite, Inc. Japan), and BNP was measured using architect® BNP-JP (Abbott Japan LLC, Japan) in accordance with the manufacturer's instructions. In patients who underwent echocardiography, early trans-mitral flow velocity to early diastolic annular velocity (E/e') was evaluated using doppler images of the mitral annular septal area, as described in the American Society of Echocardiography guidelines.¹⁶

2.4 | Pulmonary ultrasound

This procedure included the bilateral scanning of the anterior and lateral chest walls, with the patient in a supine or seated position. As shown in Figure 1, the chest wall was divided into eight areas (two anterior and two lateral areas per side), and a scan was performed

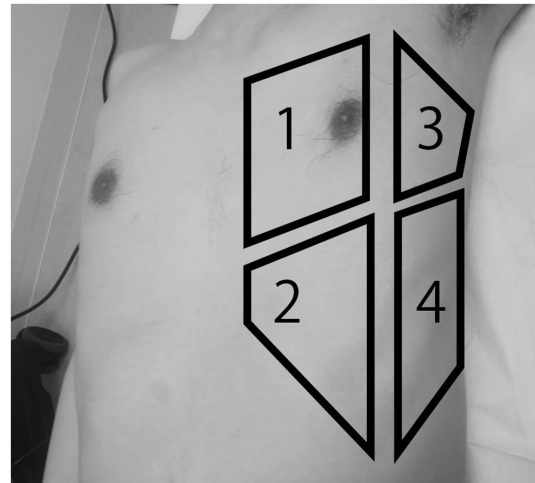


FIGURE 1 Comet-tail sign (CTS) evaluation site and example. CTS is evaluated bilaterally at four thoracic areas

for each area. A comet tail artifact was identified as a high echoic line, similar to its previous description.¹⁷ We defined CTS positive as multiple comet tail artifacts in at least one area bilaterally. To compare inter-rater differences in the CTS results, we calculated the sensitivity and specificity of the CTS for each investigator.

2.5 | Confirmation of diagnosis and definition

All enrolled patients were evaluated by cardiologists or doctors on duty by interview, physical assessments, BNP value, chest X-ray and, if necessary, additional examinations. Among them, HF-suspected patients were evaluated by two or more cardiologists independently. Clinical HF was defined by cardiologists when a patient required pharmacological intervention (including diuretics, vasodilators, natriuretic peptides, and/or inotropes).¹⁸ We calculated the matching ratio between the CTS results, laboratory data, and available radiological images.

2.6 | Statistical analyses

We compared BNP in CTS+ and CTS- participants by Student's *t*-test. We calculated C-statistics of BNP for HF-oriented medication using the receiver operating characteristic (ROC) curve analysis and determined the area under the receiver operating characteristic curve (AUC). All statistical analyses were performed using R (version 4.0.2).

3 | RESULTS

3.1 | Patient characteristics

During the research period, 95 patients with dyspnea were referred to the ER department of our institution. We obtained informed consent from all eligible patients, and no patient was excluded.

Table 1 displays the characteristics of the 95 patients enrolled in this study. All patients were evaluated by junior residents within only 2 min, and none of them were excluded. Among the 95 enrolled patients, 42 presented with clinical HF (**Table 1**). Other diagnoses included pneumonia ($n = 16$), chronic obstructive pulmonary disease (COPD) exacerbation ($n = 5$), asthma ($n = 4$), interstitial pneumonitis ($n = 4$), bronchitis ($n = 3$), hypoalbuminemia ($n = 3$), pulmonary embolism ($n = 2$), hyperventilation syndrome ($n = 2$), pneumothorax ($n = 2$), anemia ($n = 1$), mitochondrial disease ($n = 1$), pulmonary abscess ($n = 1$), arrhythmia ($n = 1$), polymyalgia rheumatica ($n = 1$), sleep apnea syndrome ($n = 1$), aneurysm ($n = 1$), and dehydration ($n = 1$). Notably, no diagnosis was made in four patients despite workup. Furthermore, there were no differences in sex or body mass index (BMI) between clinical HF patients and other patients.

3.2 | The clinical utility of CTS

The results showed that CTS had a sensitivity of 71.4% (30/42) and a specificity of 81.1% (43/53) for clinical HF. The sensitivity and specificity of CTS between the investigators were 66.7% and 69% (investigator A), and 73% and 86% (investigator B), respectively. **Figure 2A** presents a visual summary of the study sample. In addition, CTS had a good predictive value for radiograph-based pulmonary congestion, showing a sensitivity of 70.6% (24 CTS-positive patients out of 34 radiograph-positive patients) and a specificity of 73.3% (44 CTS-negative patients out of 60 radiograph-negative patients).

3.3 | The comparison between CTS and BNP

Then, we investigated the relationship between BNP and CTS (**Figure 2B**), showing that CTS-positive patients showed significantly higher BNP values than CTS-negative patients. To define the cut-off value for BNP against clinical HF diagnosis, ROC analysis was performed (**Figure 2C**), showing an area under the ROC curve of 0.918 (95% confidence interval, 0.859–0.978) for identifying clinical HF using BNP. Furthermore, a BNP value of 243.7 pg/ml had a sensitivity of 90.7% and specificity of 81.4% for clinical HF. When the cut-off value of BNP was set at 100pg/ml (institutional

upper limit) or 243.7 pg/ml (expected cut-off by ROC analysis), the sensitivity of CTS was calculated as 92.5% and 72.3%, respectively. Overall, our results implied that CTS scanning could be an effective predictor of higher BNP.

3.4 | The false-positive and false negatives in CTS

False-positive patients included CTS-positive non-HF ($n = 10$), pneumonia ($n = 7$), interstitial pneumonitis ($n = 1$), hypoalbuminemia ($n = 1$), and asthma ($n = 1$). Since bilateral pneumonia and interstitial pneumonitis could affect the precise diagnosis for pulmonary ultrasound, some previous reports excluded these cases.⁶

Moreover, we analyzed patients with false-positive and false-negative allocations in this study, and the 12 false-negative patients were described as “CTS-negative HF” patients. Interestingly, most of the CTS-negative HF patients had peripheral edema, which showed a sensitivity of 73.8% and a specificity of 66.0% for clinical HF in the entire analysis. However, when CTS was evaluated with peripheral edema, the sensitivity for HF was calculated at 96.0% (40/42 clinical HF patients, **Figure 2A**). Next, we compared the systolic blood pressure at diagnosis and the E/e' between the CTS-negative and CTS-positive HF patients (**Figure 2D**); no significant differences were observed.

4 | DISCUSSION

We investigated the diagnostic value of CTS performed by non-experts for the management of clinical HF. The key findings were followings; (1) Non-experts, such as clinical residents, can effectively evaluate CTS immediately. (2) CTS could detect the patients with significantly higher BNP. (3) As most of the CTS-negative HF patients accompanied peripheral edema, CTS with peripheral edema evaluation detected non-HF patients with a high probability.

The clinical utility of CTS has been reported by several studies. A review of the literature^{6–14} implied that our study had relatively low sensitivity for CTS (**Table 2**). This may be because previous studies were mainly performed by experts in emergency medical

TABLE 1 Patients' characteristics

	Total $n = 95$	HF (+) $n = 42$	HF (-) $n = 53$
Mean Age, year (range)	82 (25–103)	83 (48–101)	75 (25–103)
Sex, males/females	56/39	23/19	33/20
Median BMI (range)	20.5 (12–29)	20.8 (12.8–28.9)	20.2 (12.35–28.7)
Lower extremity edema, Y/N	44/51	11/31	18/35
Median BNP (pg/ml), (IQR)	270.5, (104–788)	115.35, (47–250)	739.2, (328–1327)
No. of chest X ray	64	39	51
Congestion sign based on chest X ray	35	32	3
CTS (positives/ negatives)	40/55	30/12	10/43

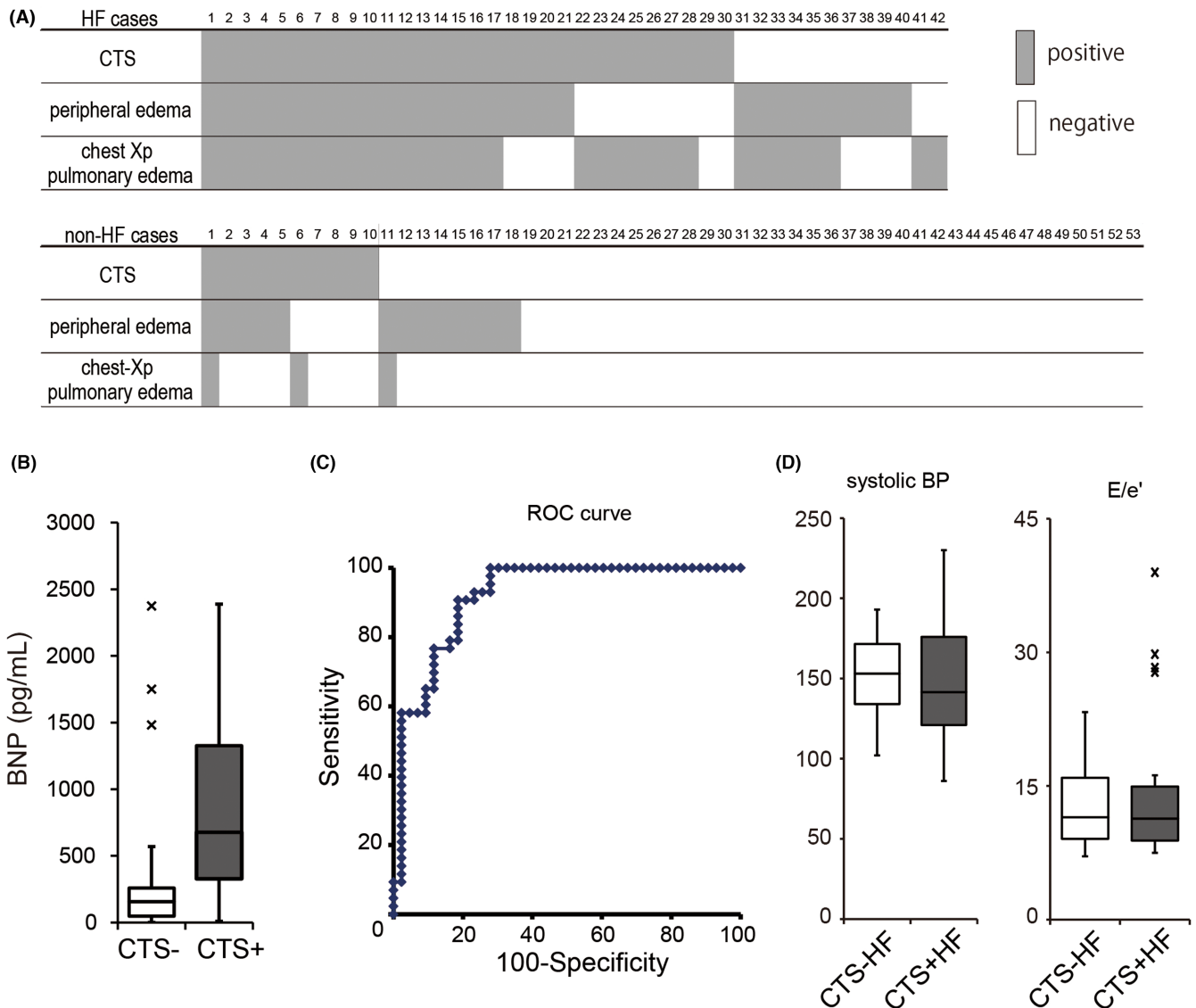


FIGURE 2 The utility of CTS for the diagnosis of congestive heart failure (HF). The summary of the current study is shown, with columns corresponding to the recruited patients (A). The box plot displays the differences in the brain natriuretic peptide (BNP) value between CTS-positive and CTS-negative patients (B). ROC analysis of BNP is used to predict the diagnosis of HF (C). The box plots display the differences in systolic BP and E/e' between CTS-positive HF and CTS-negative HF patients (D)

centers. Moreover, these studies excluded patients with other diagnoses,^{7,9,10,12-14} which might have not secluded selection bias completely. Besides, bilateral pneumonia and interstitial pneumonitis could affect the precise diagnosis.⁶ In contrast, our study recruited all patients with dyspnea during the study period, thus reflecting real clinical settings.

Our results showed that CTS positivity has good utility for identifying patients with high BNP levels. In CTS-negative HF, we considered that factors like HF with preserved ejection fraction or difficulty in depiction due to obesity might be related to CTS negativity. However, we did not find any significant differences in the E/e' and BMI between CTS-negative HF and CTS-positive HF. In contrast, peripheral edema was observed in most CTS-negative patients. Combinatory evaluation of peripheral edema and CTS can aid in the differential diagnosis of HF with high accuracy. The

efficacy of the CTS with physical examination has not been previously documented. These measures do not require blood tests or X-ray examinations, underlining the usefulness of the CTS in situations where laboratory and/or radiography studies are difficult to undertake.

Despite these findings, our study had several limitations. First, we could not completely exclude "cognitive bias," since the same investigator evaluated both imaging and physical assessments. For a more objective evaluation, we retrospectively validated these physical assessments using the nurse records, which were evaluated independently. Second, our study did not assess the accuracy between the investigators. Third, our study did not evaluate all items for the HF criteria, such as the Framingham criteria. This was because the circulation time, change in vital capacity, and precise central venous pressure were not routinely evaluated in clinical

TABLE 2 Literature review of the utility of CTS

Authors	Number	Sensitivity	Specificity	Conductor	Gold standard	Exclusion
Anderson ⁶	n = 101	70.5%	73.7%	Emergency sonologists	Chest Xp, BNP	Age (<18y.o.) Without consent
Chiem ⁷	n = 380	57.1%	84.0%	Emergency fellowship-residents	Chest Xp	Age (<18y.o.) Pregnancy During dialysis Language problem Other diagnosis
Cibinel ⁸	n = 56	92.6%	89.7%	Emergency physicians	Chest Xp	Not available
Gallard ⁹	n = 130	88.9%	88.5%	Emergency physicians	Chest Xp, BNP	Undiagnosed case Less Hospital stay <24h
Kajimoto ¹⁰	n = 90	96.2%	54.1%	No data	Chest Xp, BNP	ACS Trauma Other diagnosis
Liteplo ¹¹	n = 94	57.5%	85.2%	Emergency physicians	BNP	Without consent
Pivetta ¹²	n = 1005	90.5%	93.6%	Emergency physicians	Chest Xp, BNP	Other diagnosis
Mumoli ¹³	n = 226	95.3%	88.2%	Emergency physicians	expert diagnosis	Patientns who are not indicated for hospitalization Trauma Pneumothorax
Ünlüer ¹⁴	n = 96	95.50%	100%	Emergency nurses	Not available	<18 y.o. Acute chest pain Pregnant Hypotensive case (systolic BP <90 mmHg) Previous thoracic surgetry

practice. Alternatively, we focused on patients with HF who required intervention by cardiologists. Nevertheless, our study was novel, as it was able to report the clinical utility of CTS in real-world settings.

In summary, our data clarified the utility of the CTS, even when the ultrasonography is performed by junior residents. Through our results, it is suggested that CTS is a simple and effective tool for use by non-specialists, including junior residents.

ACKNOWLEDGMENTS

We acknowledged the kind support from the circulation department in Suzuka General Hospital. We thanked Dr. Akihiro Takasaki for supervise of current manuscript. We would like to thank Editage (www.editage.com) for English language editing.

CONFLICT OF INTEREST

The authors have stated explicitly that there are no conflicts of interest in connection with this article.

ORCID

Keiki Nagaharu  <https://orcid.org/0000-0002-6139-4256>

REFERENCES

- Okura Y, Ramadan MM, Ohno Y, Mitsuma W, Tanaka K, Ito M, et al. Impending epidemic: future projection of heart failure in Japan to the year 2055. *Circ J*. 2008;72(3):489-91.
- Parrinello G, Greene SJ, Torres D, Alderman M, Bonventre JV, Di Pasquale P, et al. Water and sodium in heart failure: a spotlight on congestion. *Heart Fail Rev*. 2015;20(1):13-24.
- Mangione S, Nieman LZ. Cardiac auscultatory skills of internal medicine and family practice trainees. A comparison of diagnostic proficiency. *JAMA*. 1997;278(9):717-22.
- St Clair EW, Oddone EZ, Waugh RA, Corey GR, Feussner JR. Assessing housestaff diagnostic skills using a cardiology patient simulator. *Ann Intern Med*. 1992;117(9):751-6.
- Lichtenstein DA, Mezière GA. Relevance of lung ultrasound in the diagnosis of acute respiratory failure: the BLUE protocol. *Chest*. 2008;134(1):117-25.
- Anderson KL, Jenq KY, Fields JM, Panebianco NL, Dean AJ. Diagnosing heart failure among acutely dyspneic patients with cardiac, inferior vena cava, and lung ultrasonography. *Am J Emerg Med*. 2013;31(8):1208-14.
- Chiem AT, Chan CH, Ander DS, Kobylivker AN, Manson WC. Comparison of expert and novice sonographers' performance in focused lung ultrasonography in dyspnea (FLUID) to diagnose patients with acute heart failure syndrome. *Acad Emerg Med*. 2015;22(5):564-73.

8. Cibinel GA, Casoli G, Elia F, Padoan M, Pivetta E, Lupia E, et al. Diagnostic accuracy and reproducibility of pleural and lung ultrasound in discriminating cardiogenic causes of acute dyspnea in the emergency department. *Intern Emerg Med*. 2012;7(1):65–70.
9. Gallard E, Redonnet JP, Bourcier JE, Deshaies D, Largeteau N, Amalric JM, et al. Diagnostic performance of cardiopulmonary ultrasound performed by the emergency physician in the management of acute dyspnea. *Am J Emerg Med*. 2015;33(3):352–8.
10. Kajimoto K, Madeen K, Nakayama T, Tsudo H, Kuroda T, Abe T. Rapid evaluation by lung-cardiac-inferior vena cava (LCI) integrated ultrasound for differentiating heart failure from pulmonary disease as the cause of acute dyspnea in the emergency setting. *J Cardiovasc Ultrasound*. 2012;10(1):49.
11. Liteplo AS, Marill KA, Villen T, Miller RM, Murray AF, Croft PE, et al. Emergency thoracic ultrasound in the differentiation of the etiology of shortness of breath (ETUDES): sonographic B-lines and N-terminal pro-brain-type natriuretic peptide in diagnosing congestive heart failure. *Acad Emerg Med*. 2009;16(3):201–10.
12. Pivetta E, Goffi A, Lupia E, Tizzani M, Porrino G, Ferreri E, et al. Lung ultrasound-implemented diagnosis of acute decompensated heart failure in the ED: a SIMEU multicenter study. *Chest*. 2015;148(1):202–10.
13. Mumoli N, Vitale J, Giorgi-Pierfranceschi M, Cresci A, Cei M, Basile V, et al. Accuracy of nurse-performed lung ultrasound in patients with acute dyspnea: a prospective observational study. *Medicine*. 2016;95(9):e2925.
14. Ünlüer EE, Karagöz A, Oyar O, Vandenberg N, Kiyancıçek S, Budak F. Lung ultrasound by emergency nursing as an aid for rapid triage of dyspneic patients: a pilot study. *Int Emerg Nurs*. 2014;22(4):226–31.
15. Volpicelli G, Mussa A, Garofalo G, Cardinale L, Casoli G, Perotto F, et al. Bedside lung ultrasound in the assessment of alveolar-interstitial syndrome. *Am J Emerg Med*. 2006;24(6):689–96.
16. Nagueh SF, Smiseth OA, Appleton CP, Byrd BF III, Dokainish H, Edvardsen T, et al. Recommendations for the evaluation of left ventricular diastolic function by echocardiography: an update from the American Society of Echocardiography and the European Association of Cardiovascular Imaging. *J Am Soc Echocardiogr*. 2016;29(4):277–314.
17. Lichtenstein D, Mézière G, Biderman P, Gepner A, Barré O. The comet-tail artifact. An ultrasound sign of alveolar-interstitial syndrome. *Am J Respir Crit Care Med*. 1997;156(5):1640–6.
18. Tanaka TD, Sawano M, Ramani R, Friedman M, Kohsaka S. Acute heart failure management in the USA and Japan: overview of practice patterns and review of evidence. *ESC Heart Fail*. 2018;5(5):931–47.

How to cite this article: Nagaharu K, Tsumura N, Itoh T & Murata T. Diagnostic utility of lung echography for congestive heart failure performed by junior resident doctors. *J Gen Fam Med*. 2022;23:401–406. <https://doi.org/10.1002/jgf2.575>