



Retained lens fragment presenting 32 years after cataract extraction

Thomas Tien^a, Marcos A. Crespo^a, Tatyana Milman^b, Zeba A. Syed^{a,*}

^a Cornea Service, Wills Eye Hospital, Sidney Kimmel Medical College at Thomas Jefferson University, Philadelphia, PA, USA

^b Department of Pathology, Wills Eye Hospital, Sidney Kimmel Medical College of Thomas Jefferson University, Philadelphia, PA, USA

ARTICLE INFO

Keywords:

Retained lens
Uveitis
Cataract surgery
Inflammation

ABSTRACT

Purpose: To report a patient with retained lens material presenting over three decades after initial cataract extraction with fluctuating corneal edema and intraocular inflammation.

Observations: A 66-year-old man presented with a first episode of decreased vision and photophobia 32 years after cataract extraction without intraocular lens implantation in the right eye. Slit lamp examination revealed a tan-colored oblong mass in the inferior angle, in addition to corneal edema and an anterior chamber reaction. The patient was aphakic with traumatic mydriasis, and accordingly it was noted that the mass shifted location between anterior and posterior chambers over subsequent evaluations. The anterior chamber inflammation resolved in the latter position. The patient was requested to remain prone prior to clinical evaluation, and an in-office anterior chamber aspiration was performed. Histopathologic evaluation confirmed the presence of lens material and a phacolytic response.

Conclusions And importance: Although unusual, retained lens material may manifest with ocular morbidity decades after cataract extraction. In patients with corneal edema and intraocular inflammation, retained lens material should be considered as a possible underlying cause even in patients with a remote history of cataract extraction. This case represents one of the longest reported time periods from cataract extraction to clinical presentation of retained lens material.

1. Introduction

Cataract surgery is among the most commonly performed procedures globally, and a rare complication of cataract surgery is retention of lens fragments.¹ Fragments of lens material may be found in the anterior chamber, posterior chamber, within the capsular bag, or in the vitreous, and this complication may lead to decreased visual acuity, corneal edema, intraocular inflammation, glaucoma, retinal detachment, or cystoid macular edema.^{2,3} Small retained lens fragments may be managed with topical medications, aimed to suppress intraocular inflammation and ocular hypertension as the lens material resorbs. Inflammation and ocular hypertension typically resolve upon absorption of the lens fragments.⁴ However, larger fragments customarily require surgical intervention.⁵

Retained lens fragments generally present in the early post-operative period, with most lens fragments identified on post-operative day one.⁶ Herein, we present a patient with retained lens material who manifested with symptoms from corneal edema and anterior chamber inflammation

32 years after initial cataract extraction.

2. Case report

A 66-year-old man presented for evaluation of decreased vision and photophobia of the right eye. He had a history of bilateral ocular trauma 32 years prior when a shotgun misfired, causing projectile gunpowder particulates to injure both eyes necessitating bilateral corneal laceration repair and cataract extraction without intraocular lens implantation. The patient had been wearing aphakic spectacles for decades with satisfactory vision until the preceding month, when he noticed that his vision in the right eye had significantly worsened. He described his vision as “looking through stained glass” with diurnal fluctuation and endorsed an occasional large, broad intermittent floater in his superior visual field. He also described photophobia in the right eye. The patient was referred from his local eye provider to our institution for evaluation.

Examination of the right eye demonstrated a best-corrected visual acuity of 20/200 and the intraocular pressure (IOP) was 26 mmHg.

* Corresponding author. Sidney Kimmel Medical College at Thomas Jefferson University, Cornea Service, Wills Eye Hospital, 840 Walnut Street, Suite 920, Philadelphia, 19107, PA, USA.

E-mail address: zsyed@willseye.org (Z.A. Syed).

<https://doi.org/10.1016/j.ajoc.2022.101546>

Received 16 August 2021; Received in revised form 11 April 2022; Accepted 18 April 2022

Available online 20 April 2022

2451-9936/© 2022 The Authors. Published by Elsevier Inc. This is an open access article under the CC BY-NC-ND license (<http://creativecommons.org/licenses/by-nc-nd/4.0/>).

Pachymetry revealed a central corneal thickness of 735 μm in the right eye. Slit lamp examination of the right eye revealed several areas of intrascleral and intrastromal degraded carbon deposits, corneal scarring, and 1+ stromal edema with folds in Descemet's membrane. The anterior chamber revealed 1+ cell, and evaluation of the inferior anterior chamber angle revealed a collection of tan material in an oblong shape measuring 1.0 mm in height and 5.5 mm in length (Figs. 1 and 2). The patient had traumatic mydriasis and was aphakic. There were no capsular remnants visualized on examination. Posterior segment evaluation was only notable for mild pigment in the anterior vitreous.

The patient was started on prednisolone acetate 1% four times daily as well as combined brimonidine/timolol twice daily in the right eye. He returned one week later for re-evaluation of his IOP, which had normalized to 18 mmHg. However, the tan material was no longer present in the anterior chamber. He was instructed to sleep face down the night prior to his next visit. On return the following week, the suspected lens material had again reappeared in the inferior angle. Given concern that the material would migrate out of the anterior chamber and taking into consideration the patient's hesitation to pursue any surgical intervention in the operating room, the decision was made with the patient to aspirate the anterior chamber material in the office. With the patient supine, a peripheral clear corneal incision was made with a sideport blade. A 27 gauge needle was used to gently aspirate the lens fragment into the lumen of the needle. Care was taken not to collapse the anterior chamber or encourage vitreous prolapse through the patient's mydriatic pupil. The material was sent for histopathologic evaluation, which demonstrated an acellular cataractous eosinophilic lens fragment (Fig. 3). Morphologically similar granular, eosinophilic material was also present within the cytoplasm of macrophages (Fig. 4). Immunohistochemically the lens fragment and intracytoplasmic degenerated lens material stained weakly for S100, compatible with crystalline lens material. The macrophages co-expressed macrophage marker CD68 and were negative for lens epithelial marker PAX8. The combined clinical, morphologic, and immunohistochemical findings supported a phacolytic anterior chamber response.

The corneal edema and anterior chamber inflammation subsequently resolved, and the patient was tapered off of topical corticosteroid and IOP-lowering medications. Best-corrected visual acuity improved to 20/40, and his IOP normalized to 16 mmHg. Nine months after aspiration of the lens material, the anterior chamber remained quiet off of topical steroids. Corneal pachymetry improved to 641 μm , although trace stromal edema persists. Given the visual insignificance of the latter finding, the patient has elected for continued monitoring.

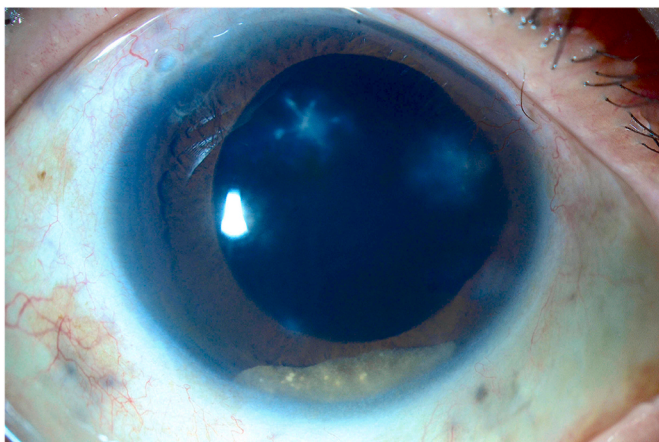


Fig. 1. Slit lamp photograph using diffuse illumination of the right eye showing a collection of tan material in the inferior angle.

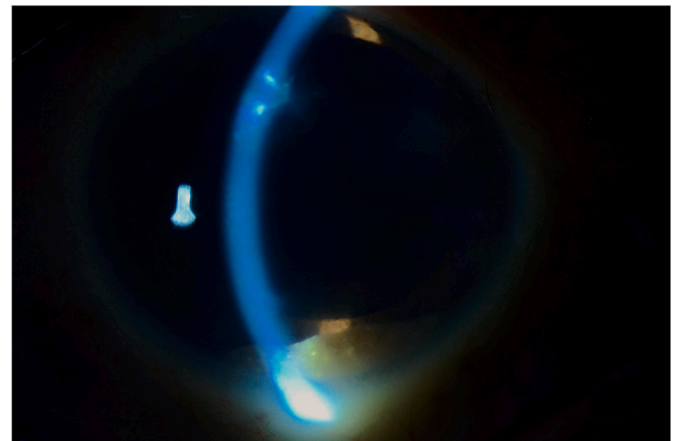


Fig. 2. Slit lamp photograph using focal illumination of the right eye showing a collection of tan material in the inferior angle.

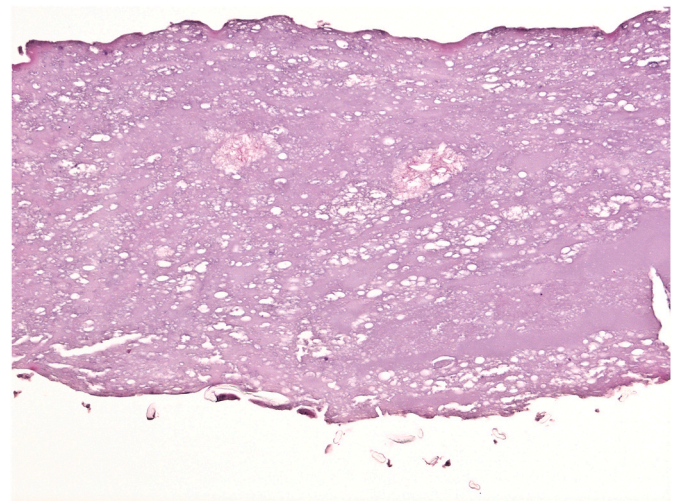


Fig. 3. Histopathology showing markedly degenerated acellular crystalline lens material (hematoxylin-eosin stain, x200).

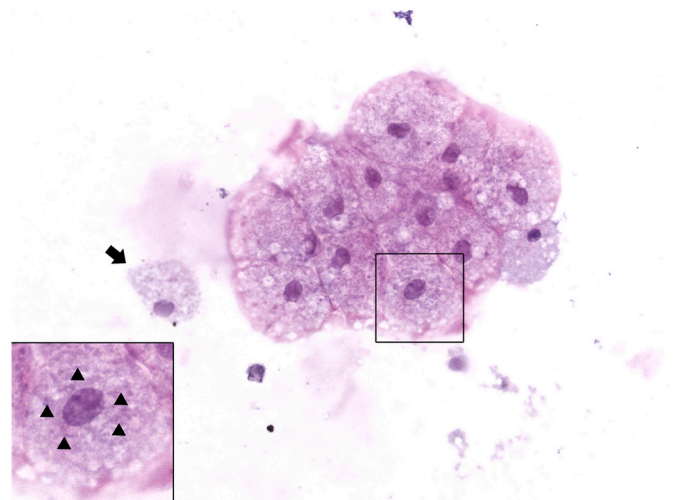


Fig. 4. Histopathology showing macrophages, singly (arrow) and in a cluster. Inset: the macrophages contain intracytoplasmic eosinophilic material (arrowheads), morphologically similar to the cataractous lens fragment in Fig. 3 (hematoxylin-eosin stain, x630; inset x1000).

3. Discussion

In this report, we describe the clinical course of a retained lens fragment in an aphakic patient whose symptom onset occurred in an extremely delayed fashion. Our case is among the longest delayed presentations of retained lens material after cataract surgery. To our knowledge, the single longest reported delay between cataract surgery and the presentation of retained lens material in the literature is 65 years, in which case the lens-induced glaucoma was successfully treated with pars plana vitrectomy to completely remove the residual lens particles.⁷

The incidence of retained lens fragments ranges from 0.1% to 1.5% in the ophthalmic literature.^{8–10} Retained lens material typically presents within the first few months after cataract surgery as focal corneal edema or persistent anterior chamber inflammation, and the lens fragment is typically found in the inferior angle on gonioscopy.^{11,12} Hui et al. reported a case series of 16 eyes with retained anterior chamber lens fragments, and in this article the average time from cataract extraction to identification of retained lens fragment was 38 days.⁵ A recent large investigation found that 0.18% of patients with cataract surgery returned to the operating room for anterior chamber removal of retained lens fragments, and that reoperations were performed at a mean of 30 ± 46.8 days after the initial cataract surgery.¹³

Retained lens fragments may result in persistent lens-induced uveitis, with ocular hypertension due to engorged macrophages obstructing the trabecular meshwork.¹⁴ Management with topical corticosteroids and IOP-lowering medications may be indicated. In cases where a lens fragment is difficult to visualize on examination alone, imaging modalities such as B-scan ultrasonography or ultrasound biomicroscopy may help localize the retained lens fragment.

Our patient's aphakic status and traumatic mydriasis presented a unique challenge, as the lens fragment was able to migrate freely between the anterior chamber and posterior cavity. Small nuclear fragments may become lodged in scleral and side port incisions, over iris crypts, or under the iris, and present in a delayed fashion after cataract surgery.¹⁵ Given the large size of the retained lens fragment in this case, we surmise that the lens material may have laid dormant for several decades in the posterior cavity until it migrated anteriorly, possibly in a setting of vitreous liquefaction, causing corneal edema and lens-induced uveitis. The inflammatory response in our patient may have been precipitated by lens protein degeneration with subsequent phagocytosis of degenerated lens material by macrophages.

In cases where the location of the lens fragment may fluctuate between visits, it may be advisable for patient undergoing planned removal from an anterior approach to maintain prone positioning before the procedure to increase the chances of visualizing the fragment for removal. The use of topical miotic agents may also be considered to sequester the fragment in the anterior chamber, however our patient had longstanding traumatic mydriasis that would not respond to topical miotics. Office-based anterior chamber aspiration, as was performed in this case, may provide valuable diagnostic information at a time when the lens fragment is in an accessible location and avoids a more invasive surgical intervention.

The definitive treatment for a posteriorly migrated retained lens fragment is pars plana vitrectomy. One study comparing early (less than 7 days after cataract surgery) versus late (7 or more days after cataract surgery) vitrectomy for retained posterior segment lens fragments found similar clinical outcomes between the two groups.¹⁶ Our patient deferred vitrectomy for removal of the lens fragment, and his intraocular inflammation resolved after aspiration of the material from the anterior chamber. In the context of retained lens fragments, corneal edema may result from a prolonged inflammatory reaction or mechanical damage to the endothelium and may require endothelial keratoplasty.^{17,18} We hypothesize that short duration of contact with the corneal endothelium in our case may have permitted improvement of the corneal edema, although the patient continues to have mild but visually insignificant

edema.

4. Conclusions

Although rare, retained lens material may present with corneal edema and anterior chamber inflammation even decades after cataract extraction. Aphakia and iris abnormalities may permit migration of the lens fragment to the posterior segment, complicating surgical removal from an anterior approach. To our knowledge, this case represents one of the longest reported delays from cataract extraction to clinical presentation of retained lens material.

Consent for publication

Consent to publish the case report was obtained from the patient.

Funding

None.

Authorship

All authors attest that they meet the current ICMJE criteria for authorship.

Financial disclosures

None.

Declaration of competing interest

The authors report no conflicts of interest.

Acknowledgements

None.

References

- Kim JE, Flynn Jr HW, Smiddy WE, et al. Retained lens fragments after phacoemulsification. *Ophthalmology*. 1994;101(11):1827–1832.
- Norton JC, Goyal S. Patient characteristics and outcomes of retained lens fragments in the anterior chamber after uneventful phacoemulsification. *J Cataract Refract Surg*. 2018;44(7):848–855.
- Ho LY, Doft BH, Wang L, Bunker CH. Clinical predictors and outcomes of pars plana vitrectomy for retained lens material after cataract extraction. *Am J Ophthalmol*. 2009;147(4):587–594.
- Schaal S, Barr CC. Management of retained lens fragments after cataract surgery with and without pars plana vitrectomy. *J Cataract Refract Surg*. 2009;35(5):863–867.
- Hui JI, Fishler J, Karp CL, Shuler MF, Gedde SJ. Retained nuclear fragments in the anterior chamber after phacoemulsification with an intact posterior capsule. *Ophthalmology*. 2006;113(11):1949–1953.
- Moshirfar M, Lewis AL, Ellis JH, McCabe SE, Ronquillo YC, Hoopes Sr PC. Anterior chamber retained lens fragments after cataract surgery: a case series and narrative review. *Clin Ophthalmol*. 2021;15:2625–2633.
- Barnhorst D, Meyers SM, Myers T. Lens-induced glaucoma 65 years after congenital cataract surgery. *Am J Ophthalmol*. 1994;118(6):807–808.
- Pande M, Dabbs TR. Incidence of lens matter dislocation during phacoemulsification. *J Cataract Refract Surg*. 1996;22(6):737–742.
- Ageyama T, Ayaki M, Ogasawara M, Asahiro C, Yaguchi S. Results of vitrectomy performed at the time of phacoemulsification complicated by intravitreal lens fragments. *Br J Ophthalmol*. 2001;85(9):1038–1040.
- Aasuri MK, Kompella VB, Majji AB. Risk factors for and management of dropped nucleus during phacoemulsification. *J Cataract Refract Surg*. 2001;27(9):1428–1432.
- Mokhtarzadeh A, Kaufman SC, Koozekanani DD, Meduri A. Delayed presentation of retained nuclear fragment following phacoemulsification cataract extraction. *J Cataract Refract Surg*. 2014;40(4):671–674.
- Pandit RT, Coburn AG. Sudden corneal edema due to retained lens nuclear fragment presenting 8.5 years after cataract surgery. *J Cataract Refract Surg*. 2011;37(6):1165–1167.
- Mahr MA, Lum F, Fujino D, Kelly SP, Erie JC. Return to the operating room for removal of retained lens fragments after cataract surgery: IRIS® Registry (Intelligent Research in Sight) Analysis. *Ophthalmology*. 2020;127(5):698–699.

14. Filipe JC, Palmares J, Delgado L, Lopes JM, Borges J, Castro-Correia J. Phacolytic glaucoma and lens-induced uveitis. *Int Ophthalmol*. 1993;17(5):289–293.
15. Dada VK, Sharma N, Dada T. Retained nuclear fragments. *J Cataract Refract Surg*. 2000;26(8):1106–1107.
16. Peck T, Park J, Bajwa A, Shildkrot Y. Timing of vitrectomy for retained lens fragments after cataract surgery. *Int Ophthalmol*. 2018;38(6):2699–2707.
17. Gedde SJ, Karp CL, Budenz DL. Retained nuclear fragment in the anterior segment. *Arch Ophthalmol*. 1998;116(11):1532–1533.
18. Giles GB, Reed D, Brewer JR, Evangelista C. Five-year-old sequestered retained lens fragment requiring keratoplasty. *Cureus*. 2020;12(7):e9428.