



Open reduction internal fixation of acromion fracture with open rotator cuff repair: a case report

Spencer M. Sims, BS ^{1,*}, Timothy S. Petsche, MD ²

¹ Fox Valley Orthopedics, Elgin, IL, USA

² Fox Valley Orthopedics, Geneva, IL, USA

ARTICLE INFO

Keywords:

Acromion fracture
rotator cuff repair
open reduction internal fixation
rotator cuff tear
precontoured acromion plate
open shoulder surgery

Acromion fractures are uncommonly reported, accounting for only 9% of scapular fractures.⁷ Traumatic acromion fractures reported in the literature involve high-energy trauma such as motor vehicle accidents.⁴ There is no widely accepted treatment protocol for traumatic acromion fractures. Techniques such as K-wire fixation or screw and plate fixation have been reported.⁶ The majority of research done on the treatment of acromion pathology deals with symptomatic os acromiale rather than traumatic acromion fractures. While acromion fracture repair is not well studied, even less has been reported on surgical techniques and approaches when dealing with both a traumatic acromion fracture and massive rotator cuff tear.

Here we present a case of concurrent traumatic acromion fracture and a massive rotator cuff tear. Surgical treatment involved a novel acromion-splitting approach for visualization and repair of the rotator cuff followed by open reduction internal fixation of the traumatic acromion fracture using a precontoured Acumed acromion plate (Acumed, Hillsboro, OR, USA).

Clinical case

A 59-year-old man was referred to our practice after slipping on ice and falling on his right shoulder. During the accident, the patient reported hearing a tearing noise in his right shoulder. The patient reported sharp pain with any palpation of the right shoulder.

No institutional review board approval was required for this case report.

* Corresponding author: Spencer M. Sims, BS, 503 Cornell Ave, East Lansing, MI 48823, USA.

E-mail address: simsspen@msu.edu (S.M. Sims).

<https://doi.org/10.1016/j.jseint.2020.03.004>

2666-6383/© 2020 The Author(s). Published by Elsevier Inc. on behalf of American Shoulder and Elbow Surgeons. This is an open access article under the CC BY-NC-ND license (<http://creativecommons.org/licenses/by-nc-nd/4.0/>).

On physical examination, ecchymosis about the acromion process was observed. Diffuse right shoulder tenderness was noted, nonlocalizable because of the significant pain. The patient was observed to have significantly limited active range of motion, with active abduction to only 15° and forward flexion to only 15°, compared with full active range of motion in the left shoulder.

Four-view radiographs of the right shoulder demonstrated findings suggestive of an acromial fracture. Three views from the preoperative radiographs are shown in Fig. 1.

Noncontrast magnetic resonance imaging of the right shoulder showed a displaced and comminuted acromion fracture that was likely acute in nature, full-thickness tears of the infraspinatus, supraspinatus, and subscapularis tendons with retraction, and partial tear of the posterior lateral deltoid muscle at the acromial attachment. A sagittal magnetic resonance image demonstrating the acute acromion fracture is shown in Fig. 2, a. Figure 2, b, provides axial visualization of the acute acromion fracture. Figure 2, c, shows a coronal view of the acute rotator cuff tear at the level of the supraspinatus tendon.

The patient elected to have right shoulder open surgery with open reduction and internal fixation of the comminuted acromion fracture along with an open repair of the rotator cuff and deltoid muscle.

Surgical procedure

The patient was positioned in a true beach chair position. The shoulder was prepped and draped in routine sterile fashion. An incision was made superiorly from the anterior to posterior aspect of the acromion. Careful dissection was carried out from the subcutaneous layer down to the fascia. The acromion fracture was visualized. By visualizing through the fracture, the bursa and

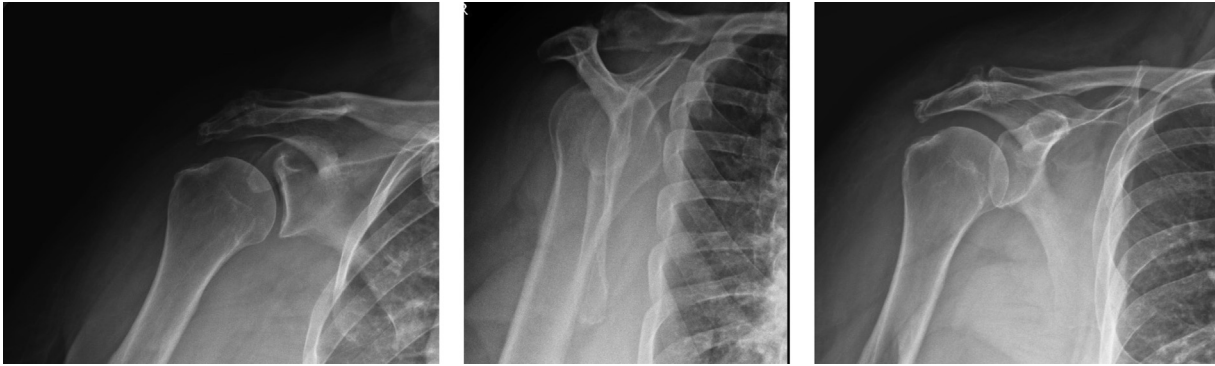


Figure 1 Preoperative radiographs of acromion fracture. Three views of the right shoulder. Imaging demonstrates a traumatic acromion fracture.

rotator cuff tendon tear was identified. A full-thickness tear involving the subscapularis, rotator interval, and supraspinatus and infraspinatus tendons with retraction was observed. The biceps tendon was partially torn with medial subluxation. The biceps tendon was tagged with a no. 2 FiberWire suture and cut to prepare for a biceps tenodesis. The biceps tendon was then located in the subdeltoid space and tenodesed using a Stryker ReelX anchor (Stryker, Kalamazoo, MI, USA) in the suprapectoral location. Excellent fixation was achieved.

With visualization through the acromion fracture space, the greater tuberosity and rotator cuff tendon were prepared for repair with standard technique. A Stryker IconiX double-loaded anchor was used to repair the upper subscapularis. Sutures were passed into the distal end of the upper subscapularis to repair it to its normal anatomic position.

The supraspinatus tear and infraspinatus tear were repaired using a standard 2-row suture-bridge technique as described in Park et al.⁸ Full greater tuberosity footprint coverage was obtained. On completion of the repair, no other cuff tears could be seen throughout a full arc of rotation.

The incision was then extended medially along the spine of the scapula to accommodate the precontoured acromion plate. The comminuted acromion fracture was reduced anatomically and held provisionally with a K-wire. The fracture was secured with an Acumed 7-hole precontoured acromion plate. This matched the anatomic contour nicely. After drilling and measuring for appropriate length, the plate was secured with 3 screws medially and 3 screws laterally. Five locking screws along with 1 nonlocking screw were used. The plate fixation medially was outstanding because of the very dense bone of the scapular spine. The comminuted

fractured fragments of the anterior acromion were secured to the plate with both screws and suture. Excellent fixation of the fracture was achieved. Intraoperative imaging as seen in Fig. 3 revealed anatomic alignment of the fracture, appropriate position of the plate, and appropriate length of the screws.

The partially torn posterolateral fibers of the deltoid muscle were repaired to the normal anatomic position using a combination of no. 5 FiberWire and no. 2 FiberWire suture.

Sketches of the initial pathology and subsequent rotator cuff repair and acromion fixation are seen in Fig. 4. Figure 4, a, shows the initial rotator cuff tear along with the acute acromion fracture. Figure 4, b, is a sketch of the completed rotator cuff tear as visualized through the acromion fracture. Figure 4, c, demonstrates the acromion fracture reduced to its normal anatomic position. Figure 4, d, shows the placement of the Acumed 7-hole precontoured acromion plate used for fixation of the fracture.

Postoperative treatment

Postoperative treatment involved immobilization of the shoulder with a sling and abduction pillow to minimize tension on the rotator cuff repair for 6 weeks, followed by standard physical therapy for rotator cuff repair 2-3 times weekly for a total of 10 weeks.

Long-term follow-up

Radiographs of the shoulder at 4.5 months postoperatively demonstrated no displacement of the acromion plate. The comminuted acromion fracture healed in an anatomic position. At 6

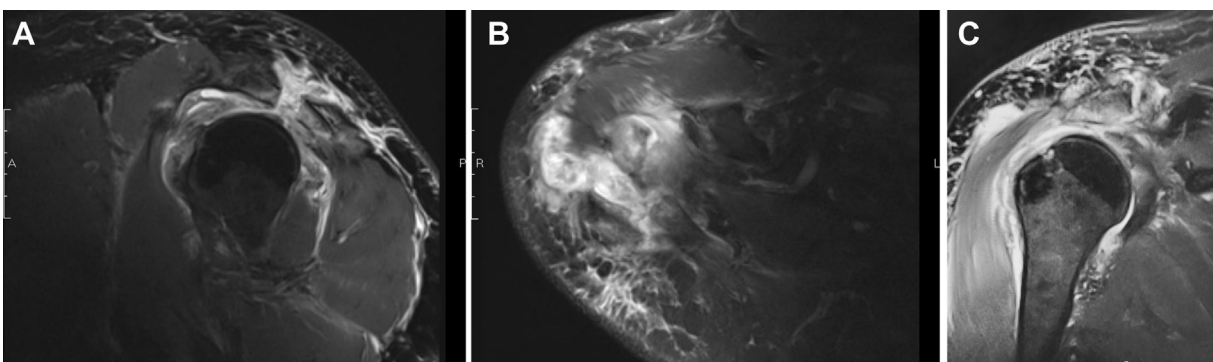


Figure 2 Preoperative MRIs. (A) Sagittal noncontrast MRI demonstrating acute acromion fracture. (B) Axial noncontrast MRI demonstrating acute acromion fracture. (C) Coronal noncontrast MRI demonstrating acute rotator cuff tear at the level of the supraspinatus tendon. MRI, magnetic resonance imaging.

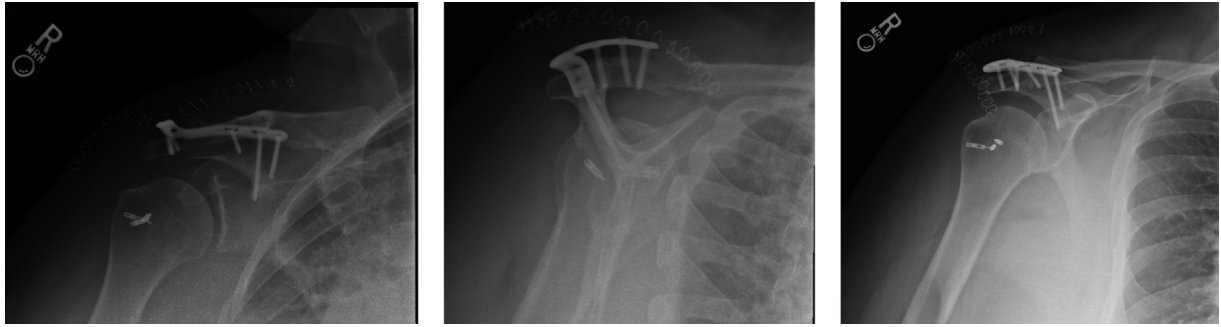


Figure 3 Intraoperative radiographs of plate fixation. Intraoperative images of acromion fracture plate fixation with a precontoured acromion plate.

months, the patient showed full range of motion and strength with abduction, external rotation, internal rotation, and forward flexion. The patient reported no symptoms from the hardware. At 18 months postoperatively, the patient was assessed using the University of California Los Angeles shoulder score. A score of 32/35 with almost full function of the shoulder was reported by the patient.

Discussion

We believe this to be the first case report describing an acromion-splitting approach to repair the rotator cuff with subsequent surgical plate fixation of a traumatic acromion fracture with a precontoured acromion plate.

Because of the rarity of acromion fractures, there is limited data on the efficacy of plate and screw fixation. Cases in the literature report using modified clavicular fracture plates for internal fixation of the acromion.⁶ Using a 3D model of a patient's acromion and prebending an osteosynthesis plate to fit the curvature of the acromion has also been reported.³

Research into rotator cuff repair specific to fixation of traumatic acromial fractures is also very limited. Peckett et al⁹ reported a review of performing rotator cuff repair along with fixation of symptomatic os acromiale fragments when indicated. However, they did not describe a deltoid-splitting approach or using a precontoured acromion plate for fixation. Abboud et al¹ researched surgical fixation of symptomatic os acromiale with coinciding rotator cuff pathology and reported poor outcomes. There is no universally accepted surgical technique for concurrent rotator cuff repair and traumatic acromion fracture with open reduction internal fixation. However, for the treatment of asymptomatic os acromiale, an acromion-splitting approach with deltoid splitting to achieve visualization of the rotator cuff has been reported.^{2,5,10} Richman et al¹⁰ described a procedure in which the deltoid was split along its fibers to achieve good visualization of the rotator cuff. After good bony coverage had been achieved with the rotator cuff repair, the os acromiale fragment was fixated to the remainder of the acromion with a 4-0 cannulated screw. We believe this case report to be a unique combination of surgical techniques not previously reported in the literature. Our surgical technique involved

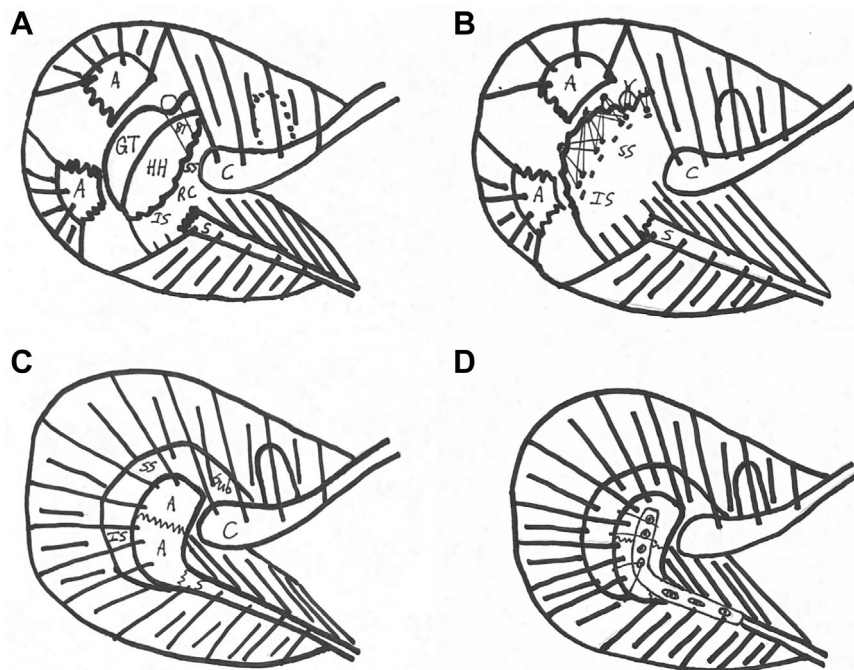


Figure 4 Fracture sketch. (A) Fracture sketch of the initial rotator cuff pathology and overlying acromion fracture. (B) Sketch of completed transosseous suture-bridge repair visualized through the overlying acromion fracture. (C) Sketch of the reduced acromion fracture with visualization through the deltoid attachment of the underlying rotator cuff anatomy. (D) Sketch of placement of the Acumed 7-hole precontoured acromion plate following fixation of the acromion fracture. A, acromion; BT, biceps tendon; C, coracoid process; GT, greater tuberosity; HH, humeral head; IS, infraspinatus; RC, rotator cuff; S, scapular spine; SS, supraspinatus; Sub, subscapularis.

visualizing and repairing the rotator cuff through the acromion fracture followed by fixation of the acromion fracture using a precontoured acromion plate.

The outcome of this patient was excellent. As a result, we believe this surgical and postoperative approach may have benefits in the future when treating traumatic acromion fractures with co-occurring rotator cuff pathology.

The excellent outcome of this single case report with postoperative follow-up of radiographs at 4.5 months, objective physical examination at 6 months, and University of California Los Angeles shoulder scoring at 18 months provides hope for future treatment of traumatic acromion fractures with rotator cuff pathology using an acromion-splitting approach for rotator cuff repair followed by use of a precontoured acromion plate for the fixation.

Conclusion

This case provides a novel approach to treatment for coinciding rotator cuff and acromion pathology using a combination of techniques not previously reported in the literature including using a precontoured acromion plate and approaching the rotator cuff through a fracture in the acromion. The excellent outcome in this patient is encouraging for further use of this treatment approach when dealing with traumatic acromion fractures.

Disclaimer

The authors, their immediate families, and any research foundations with which they are affiliated have not received any

financial payments or other benefits from any commercial entity related to the subject of this article.

References

1. Abboud JA, Silverberg D, Pepe M, Beredjiklian PK, Iannotti JP, Williams GR, et al. Surgical treatment of os acromiale with and without associated rotator cuff tears. *J Shoulder Elbow Surg* 2006;15:265–70. <https://doi.org/10.1016/j.jse.2005.08.024>.
2. Atinga M, Gregor R, Selvaraj KM, Hong TF. Os acromiale open reduction and internal fixation: a review of iliac crest autogenous bone grafting and local bone grafting. *J Shoulder Elbow Surg* 2018;27:1030–6. <https://doi.org/10.1016/j.jse.2017.11.023>.
3. Beliën H, Biesmans H, Steenwerckx A, Bijlens E, Dierickx C. Prebending of osteosynthesis plate using 3D printed models to treat symptomatic os acromiale and acromial fracture. *J Exp Orthop* 2017;4. <https://doi.org/10.1186/s40634-017-0111-7>.
4. Çiçekli Ö, Akar A, Topçu HN. Displaced acromion fracture: A rare injury, case report. *Int J Surg Case Rep* 2017;39:313–6. <https://doi.org/10.1016/j.ijscr.2017.08.051>.
5. Hertel R, Windisch W, Schuster A, Ballmer FT. Transacromial approach to obtain fusion of unstable os acromiale. *J Shoulder Elbow Surg* 1998;7:606–9.
6. Hess F, Zettl R, Welter J, Smolen D, Knoth C. The traumatic acromion fracture: review of the literature, clinical examples and proposal of a treatment algorithm. *Arch Orthop Trauma Surg* 2019;139:651–8. <https://doi.org/10.1007/s00402-019-03126-6>.
7. Kuhn JE, Blasler RB, Carpenter JE. Fractures of the acromion process: a proposed classification system. *J Orthop Trauma* 1994;8:6–13.
8. Park MC, Elattrache NS, Ahmad CS, Tibone JE. “Transosseous-equivalent” rotator cuff repair technique. *Arthroscopy* 2006;22. <https://doi.org/10.1016/j.arthro.2006.07.017>.
9. Peckett WR, Gunther SB, Harper GD, Hughes JS, Sonnabend DH. Internal fixation of symptomatic os acromiale: a series of twenty-six cases. *J Shoulder Elbow Surg* 2004;13:381–5. <https://doi.org/10.1016/j.jse.2004.01.023>.
10. Richman N, Curtis A, Hayman M. Acromion-splitting approach through an os acromiale for repair of a massive rotator cuff tear. *Arthroscopy* 1997;13:652–5.