



# Topical chemotherapy with mitomycin C in a feline corneal squamous cell carcinoma

Esmeralda Costa Delgado

*Journal of Feline Medicine and Surgery Open Reports*  
1–5

© The Author(s) 2020

Article reuse guidelines:

sagepub.com/journals-permissions

DOI: 10.1177/2055116920917833

journals.sagepub.com/home/jfmsopenreports

This paper was handled and processed by the European Editorial Office (ISFM) for publication in *JFMS Open Reports*



## Abstract

**Case summary** A 9-year-old cat was presented with a right globe lesion of 6 months' duration. A large pink elevated mass covering two-thirds of the right cornea was detected. The corneal mass was surgically removed by superficial keratectomy and diagnosed by histopathology as a squamous cell carcinoma (SCC). The surgical procedure led to a relatively transparent cornea, but recurrence was likely. To avoid relapse, 1 month after surgery three cycles of mitomycin C 0.04% eye drops were applied q8h for 15 days on/15 days off. No local or systemic side effects were seen, and no recurrence was detected after 1 year of follow-up. Topical mitomycin C was successfully used as adjuvant local chemotherapy agent and prevented relapses owing to its cytostatic effect.

**Relevance and novel information** SCCs are relatively common in feline patients, especially in the non-pigmented extremities of the nose, ears and eyelids, but with the cornea being a rare location. They rarely metastasise and they seldom relapse locally after surgical excision. Surgical-free margins of 2 cm are advisable to prevent relapses. Corneal tumours are rare, as the cornea is avascular; corneal transparency is essential to assure clear vision. In corneal SCC this margin is impossible to achieve without enucleation. In the present report, surgical removal of the neoplasm was combined with topical administration of the anticancer drug mitomycin C and a good prognosis was obtained. This combined treatment may be an appropriate therapeutic option for feline corneal SCC.

**Keywords:** Squamous cell carcinoma; mitomycin C; corneal neoplasia; recurrence

**Accepted:** 6 March 2020

## Introduction

Squamous cell carcinomas (SCCs) are relatively common in cats. They are frequently located in the ears, nose and eyelids, especially in non-pigmented regions, and actinic radiation is known to be a predisposing factor. The variability of presenting signs results from size, location, tissue destruction, the patient's general condition and the existence of metastases.<sup>1</sup>

Because the cornea needs to be transparent to allow vision, it is avascular and 90% of its structure is formed by collagen fibres. Corneal tumours are rare. Papillomas, melanomas and haemangiosarcomas are among some of the histopathological diagnoses after surgical excision of neoplasms.<sup>1</sup>

In the presence of pink elevated friable masses, the clinician usually suspects granulation tissue due to chronic keratitis. Medical treatment can be attempted

to clear the tissue. In non-responsive cases, there is a high index of suspicion of neoplasia and a surgical biopsy of the mass is mandatory,<sup>2</sup> with corneal surface cytology also being an important complementary examination. In SCC excision surgeries, 2 cm of neoplastic-free tissue margins are advisable. In ocular locations this would only be achieved through enucleation, which is usually the surgeon's choice to

CIISA (Centre for Interdisciplinary Research in Animal Health), Faculty of Veterinary Medicine, University of Lisbon, Lisbon, Portugal

### Corresponding author:

Esmeralda Costa Delgado DVM, MSc, PhD, Faculty of Veterinary Medicine of Lisbon, Alameda da Universidade Técnica, Lisbon 1300-477, Portugal  
Email: esmeralda@fmv.ulisboa.pt



Creative Commons Non Commercial CC BY-NC: This article is distributed under the terms of the Creative Commons

Attribution-NonCommercial 4.0 License (<https://creativecommons.org/licenses/by-nc/4.0/>) which permits non-commercial use, reproduction and distribution of the work without further permission provided the original work is attributed as specified on the SAGE and Open Access pages (<https://us.sagepub.com/en-us/nam/open-access-at-sage>).

attempt cure. As the eye is sometimes functional once the tumour is excised, more conservative surgery combined with adjunctive therapies could be attempted.

To avoid relapses, several therapies could be implemented, such as radiotherapy and cryotherapy, both inducing severe tissue damage and corneal scarring with vision deficits, frequently resulting in visual loss, if not loss of the eye itself.<sup>2</sup>

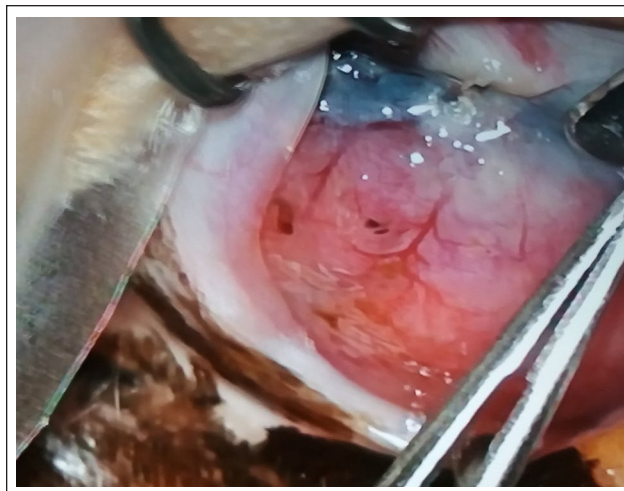
Mitomycin C is a cytostatic alkylating agent that can be used in chemotherapy protocols. It was discovered in the 1950s by Japanese scientists in cultures of the microorganism *Streptomyces caespitosus*.<sup>3</sup> Its topical use has already been described in human ophthalmic surgery,<sup>4</sup> and to avoid local relapses of corneal SCC in humans,<sup>5-9</sup> horses<sup>10</sup> and one canine patient.<sup>11</sup> To the author's knowledge, this is the first report of the use of topical mitomycin C as adjuvant local chemotherapy in a feline corneal SCC.

The clinical presentation, surgical treatment, local chemotherapy and therapeutic protocol in a case of extensive corneal SCC in a cat is described.

## Case description

A 9-year-old female domestic shorthair indoor-only cat was presented to the ophthalmology referral consultation at the Teaching Hospital of the Faculty of Veterinary Medicine, Lisbon University with a right globe lesion that had started 6 months ago. The cat had been undergoing long-term treatment for conjunctivitis by the referring veterinarian, and showed no improvement or change in the clinical appearance of the lesion. Oral and topical antibiotics and topical anti-inflammatory drugs, including steroids, had been prescribed. Complete physical examination revealed no other abnormalities.

On ophthalmic examination, the cat presented with an extensive elevated pink mass that covered two-thirds of the cornea of the right eye (OD) (Figure 1). The left eye (OS) had no clinical signs of disease. In the OD the dazzle reflex was positive, the menace response was absent and palpebral closure was impossible owing to the presence of the mass, leading to lagophthalmos. The corneal reflex was decreased, probably due to changes of the termination of corneal nerves. In the OD, direct and indirect pupillary light reflexes were impossible to evaluate owing to the large mass and grey opacity in the remaining cornea that rendered visualisation of the pupil impossible. In the OS, menace response and all the remaining ocular reflexes were present. In the OS both direct and indirect pupillary light reflexes were present, as light could pass through the opaque cornea, so a functional retina in the right eye could be expected.



**Figure 1** Cornea of the right eye showing an extensive elevated vascularised pink mass covering two-thirds of the epithelium, almost completely obstructing vision. Photograph taken under the surgical microscope, at the beginning of the superficial keratectomy. Ventral to the pink mass, the border of the nictitating membrane is visible in white

Schirmer tear test (Dina strips Schirmer-Plus; Luneau SAS) was 11 mm/min in the OD and 18 mm/min in the OS. Intraocular pressure measurement obtained by applanation tonometry (Tono-Pen XL; Medtronic Solan) following instillation of a topical anaesthetic (Oxibuprocaine, Anestocil; Laboratórios Edol) was 13 mmHg in the OD and 18 mmHg in the OS. The left cornea did not stain with fluorescein dye, while the right eye mass captured some stain.

Slit-lamp biomicroscopy (SL14 Kowa Company) of the OD allowed for better visualisation of the mass and showed no abnormalities in the OS. Two drops of a topical mydriatic drug corresponding to tropicamide in a 1% concentration (Tropicil Top; Laboratórios Edol) were applied in the OS. Indirect fundoscopic examination (Heine Omega 180) was impossible to perform in the OD owing to the mass, but was normal in the OS.

The differential diagnoses for the OD mass included eosinophilic keratitis, chronic keratitis, traumatic injury, corneal foreign body and neoplasia.

Complete blood count (CBC) and serum chemistry analysis were within normal limits. Triple-view thoracic x-rays were obtained to rule out thoracic lesions. Although corneal surface cytology is an important complementary examination, it could not be performed in this patient without heavy sedation or general anaesthesia, and so surgical biopsy was considered the best option.

The patient was premedicated with methadone (Semfortan; Dechra Veterinary Products) at a dosage of 0.2 mg/kg body weight subcutaneously and anaesthetised with propofol at a dose of 5 mg/kg body weight

intravenously (Propofol Lipuro; B Braun Medical). Endotracheal intubation was performed following topical anaesthesia of the larynx and volatile anaesthesia was maintained with isoflurane. On induction, cephalosporin (Cefazolina Labesfal; Labesfal – Laboratório Almiro) at a dosage of 22mg/kg body weight was administered intravenously to prevent bacterial contamination of the surgical site and meloxicam (Meloxidyl; Ceva) at a dosage of 0.1 mg/kg body weight was given subcutaneously for the control of postoperative pain.

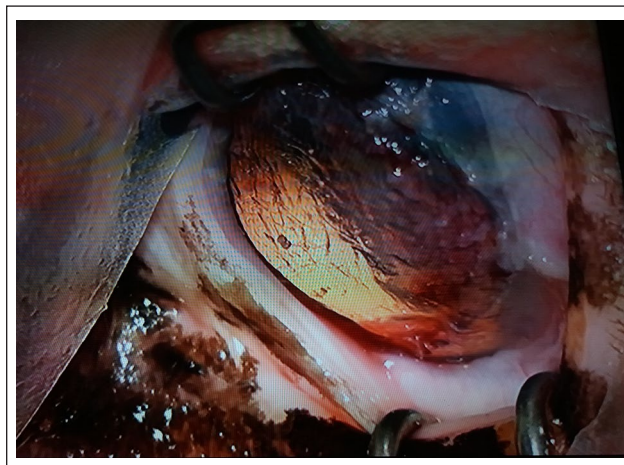
Periocular skin of the right eye was clipped and surgical asepsis was obtained with povidone-iodine 1:20 solution, followed by sterile saline. After completion of draping, a 5mm lateral canthotomy was performed to increase corneal exposure. Surgery was performed using a surgical microscope, a Collibri forceps to grasp the mass and the corneal lamellae, and a disposable crescent blade was used to carefully dissect between collagen stromal layers. This task was difficult to accomplish because the mass was friable and difficult to grasp without tearing the tissue. An attempt was made to achieve a surgical-free margin, sparing as much corneal stroma as possible (Figures 1–3). The excised tissue was sent for histopathology.

Lateral canthotomy was routinely closed in two layers with 5-0 simple interrupted absorbable sutures (Surgycril; B Braun Medical).

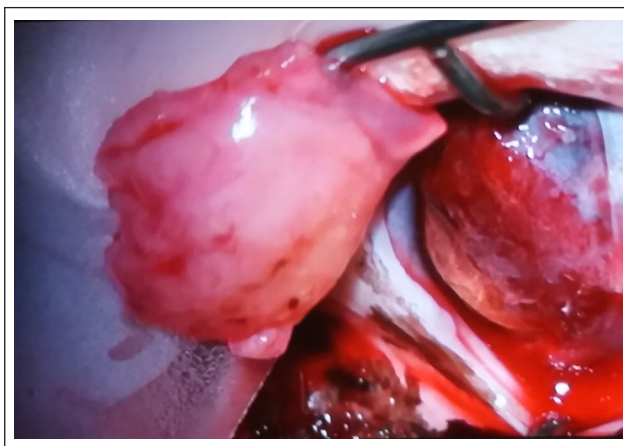
Histopathology revealed that the tissue corresponded to a corneal SCC (Figure 4).

Postoperatively, medical treatment consisted of oral meloxicam (Meloxidyl; Ceva) at a dosage of 0.05mg/kg body weight for 4 days, and doxycycline (Ronaxan; Pfizer) at a dosage of 10 mg/kg body weight for 7 days

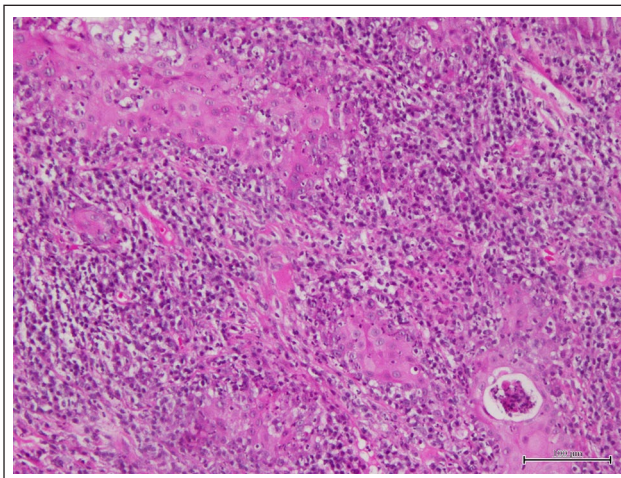
postoperatively. Additionally, topical tobramycin drops (Tobrex; Edol) were applied every 4 h for 14 days in the OD, along with ganciclovir 0.15% in gel form (Virgan; Laboratoires Thea) every 4h to prevent an eventual exacerbation of a latent feline herpesvirus infection, which is endemic in Portugal. An Elizabethan collar was advised to prevent self-mutilation of the surgical site. Ten days later, the canthotomy skin sutures were removed. The cornea healed with no complications, apart from a moderate superficial neovascularisation on the surgical site.



**Figure 3** After the completion of the microsurgical procedure, the mass was totally excised and a superficial corneal ulcer was created. The cornea regained its transparency and vision in the eye was restored



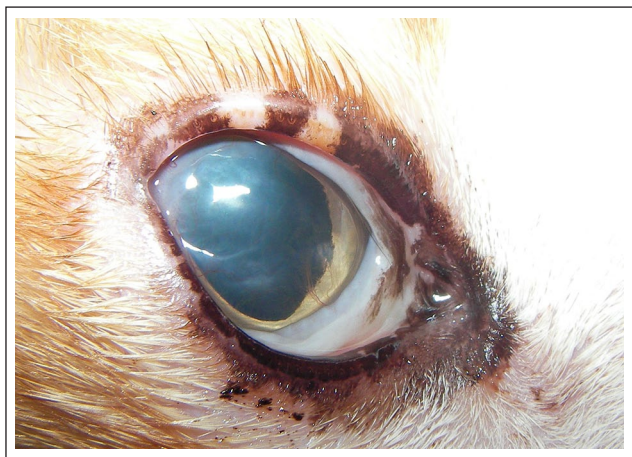**Figure 2** Image showing the surgical site at the end of superficial keratectomy. Under the surgical microscope, after exeresis of the lesion with a crescent blade disposable knife, the superficial stroma layers were carefully dissected to separate them from the middle ones. There was diffuse discrete bleeding coming from the corneal neovascularisation



**Figure 4** Photomicrograph of the mass corresponding to a squamous cell carcinoma. Neoplastic squamous cells show an infiltrative growth pattern, with moderate squamous differentiation. The surrounding desmoplastic stroma contains an abundant lymphocytic inflammatory infiltrate (haematoxylin and eosin, bar 100 µm)

One month postoperatively, a fluorescein test was negative, the cornea had completely healed and topical mitomycin C adjuvant treatment was initiated. The drug was diluted in sterile water at a concentration of 0.04% (0.4mg in 10ml of sterile water), placed in commercial sterile dry tubes; three tubes were prepared – one for each treatment. Tubes were protected from light (covered with Vet Wrap) and kept at 4°C. One drop was applied three times daily in the OD for a course of 15 days, followed by a 15-day interval with no other medication apart from artificial tear drops three times daily. Three treatment cycles were performed, one per month. The cytostatic agent was applied by the owner using chemotherapy gloves. There were no immunosuppressed owners or children at home and the cat was the sole pet and always kept indoors. There was no pruritus or signs of ocular discomfort throughout the treatment, and an Elizabethan collar was unnecessary.

No secondary side effects, either systemic or local, were observed with this topical chemotherapy. By the end of the chemotherapy protocol, CBC and biochemistry profiles were within normal limits. The patient was ophthalmically rechecked every 2 weeks and the cornea was clear throughout the treatment, showing no signs of inflammation, epiphora or ocular discharge. Fluorescein tests were negative. Over the course of treatment, the cornea regained transparency and decreased its neovascularisation (Figure 5). During follow-up evaluations, every 2 months after the end of treatment, an almost clear cornea was appreciated, with slight neovascularisation and discrete scarring. Symblepharon of the dorsal bulbar conjunctiva to



**Figure 5** During one follow-up evaluation, 6 months after surgery, an almost clear cornea was appreciated, with only one vessel left at 4 o'clock and a discrete scarring at 8 o'clock. Symblepharon of the dorsal bulbar conjunctiva to the third eyelid was present at 2 o'clock. There was no epiphora or ocular discomfort, and there was no recurrence of the neoplasm

the third eyelid was present at 2 o'clock. There was no epiphora or ocular discharge, signs of inflammation, pruritus or ocular discomfort. Intraocular pressure was normal. There was no recurrence of the neoplasm at the 1-year follow-up.

## Discussion

SCC has been reported as the most common eyelid tumour in cats aged 10 years or older.<sup>1</sup> The condition presents as a proliferative pink-to-white mass, which is normally ulcerated. White cats are predisposed and the medial canthal eyelid is primarily affected. In both dogs and cats, solar radiation exposure, lack of melanin and chronic irritative diseases are conditions that predispose to the development of this tumour.<sup>1</sup>

SCCs are usually superficial, but the actinic plaque may invade deeper tissues. Although it rarely occurs, there are reports of SCCs that have metastasised to distant organs.<sup>1</sup>

Mitomycin C is a cytostatic alkylating agent used in several chemotherapy protocols. In humans, mitomycin C 0.02% can be applied topically in the eye to prevent scarring during glaucoma filtering surgery and to prevent haze after laser treatments; it has also been shown to reduce fibrosis in strabismus surgery.<sup>4</sup> Its topical use has been described to avoid local relapses of SCC in corneal tumours in humans,<sup>5-9</sup> horses and dogs.<sup>10,11</sup>

In veterinary medicine, one study compared the complications and recurrence rate following topical mitomycin C therapy vs CO<sub>2</sub> laser ablation for treating equine corneolimbic SCC in 25 horses. The study concluded that horses receiving adjunctive topical mitomycin C therapy were less likely to experience tumour recurrence than horses undergoing CO<sub>2</sub> laser ablation.<sup>10</sup>

There was 1 month between surgical excision and the beginning of chemotherapy in the case reported here. In a previous study of horses, initiation of 2–3 rounds of mitomycin C following epithelialisation of the surgical site resulted in fewer major complications and achieved comparable disease resolution relative to treatment in the immediate postoperative period.<sup>10</sup>

Three cycles of topical 0.04% mitomycin C were performed in the cat's eye described in the present case. The same protocol was followed in previous cases in horses,<sup>10</sup> while in humans 2–4 cycles of postoperative mitomycin C has been shown to decrease the rate of recurrence.<sup>7,8</sup>

The majority of studies use a 1 week on, 1 week off protocol. In a previous case, topical mitomycin C was used 2 weeks on, 2 weeks off as the sole therapy for a canine corneal SCC owing to a very high anaesthetic risk and the inability to perform surgical removal. No adverse side effects were experienced, and this was the rationale for the 15-day protocol used in the present case.<sup>12</sup>

Regarding complications associated with mitomycin C in the treatment of ocular surface neoplasia, in the largest published human case series involving 100 eyes,

34% developed an allergic reaction to the drug and 14% of the eyes had epiphora secondary to punctal stenosis at a mean follow-up time of 26.5 months.<sup>13</sup>

In a case series of 10 humans with extensive recurrent conjunctival–corneal SCC, complete tumour regression was documented in all 10 cases (100%).<sup>14</sup>

In a previous study in 14 horses with corneal SCCs, 6/8 eyes treated topically alone and 7/9 treated both surgically and topically experienced clinical resolution.<sup>15</sup> In the present case, it is believed that the dimension of the mass justified surgical excision, in order to obtain a definitive histopathological diagnosis.

As with previous studies published on veterinary patients,<sup>10,11,14,15</sup> no adverse side effects were seen in the present patient, either topical or systemic.

Topical mitomycin C appears to offer a valid, safe alternative as an adjunctive therapy in the treatment of ocular SCC in cats.

## Conclusions

Surgical removal of the neoplasm was combined with topical administration of the anticancer drug mitomycin C and a good prognosis was obtained with no adverse reactions to the drug in this cat. These results suggest that a combination of a keratectomy followed by topical instillation of mitomycin C might be an effective therapy for extensive corneal SCC in the cat.

**Conflict of interest** The authors declared no potential conflicts of interest with respect to the research, authorship, and/or publication of this article.

**Funding** The author received no financial support for the research or authorship. The author received funding for the publication charges of this article from its institution Faculty of Veterinary Medicine, Lisbon University.

**Ethical approval** This work involved the use of non-experimental animals only (including owned or unowned animals and data from prospective or retrospective studies). Established internationally recognised high standards ('best practice') of individual veterinary clinical patient care were followed. Ethical approval from a committee was therefore not necessarily required.

**Informed consent** Informed consent (either verbal or written) was obtained from the owner or legal custodian of all animal(s) described in this work (either experimental or non-experimental animals) for the procedure(s) undertaken (either prospective or retrospective studies). No animals or humans are identifiable within this publication, and therefore additional informed consent for publication was not required.

## References

- Dubielzig R, Ketring K, McLellan G, et al. *Veterinary ocular pathology – a comparative review*. St Louis, MO: Saunders Elsevier, 2010.
- Maggs D, Miller P and Ofri R. *Slatter's fundamentals of veterinary ophthalmology*. 5th ed. St Louis, MO: Elsevier, 2017.
- Tomasz M. **Mitomycin C: small, fast and deadly (but very selective)**. *Chem Biol* 1995; 2: 575–579.
- Kersey JP and Vivian AJ. **Mitomycin and amniotic membrane: a new method of reducing adhesions and fibrosis in strabismus surgery**. *Strabismus* 2008; 16: 116–118.
- Sarici AM, Arvas S, Pazarli H, et al. **Combined excision, cryotherapy, and intraoperative mitomycin C (EXCRIM) for localized intraepithelial and squamous cell carcinoma of the conjunctiva**. *Arch Clin Exp Ophthalmol* 2013; 251: 2201–2204.
- Rudkin AK, Dempster L and Muecke JS. **Management of diffuse ocular surface squamous neoplasia: efficacy and complications of topical chemotherapy**. *Clin Experiment Ophthalmol* 2015; 43: 20–25.
- Kalamkar C, Radke N, Mukherjee A, et al. **Topical mitomycin-C chemotherapy in ocular surface squamous neoplasia**. *J Clin Diagn Res* 2016; 10: NJ01. DOI: 10.7860/JCDR/2016/22006.8427.
- Gupta A and Muecke J. **Treatment of ocular surface squamous neoplasia with mitomycin-C**. *Br J Ophthalmol* 2010; 94: 555–558.
- Besley J, Pappalardo J, Lee GA, et al. **Risk factors for ocular surface squamous neoplasia recurrence after treatment with topical mitomycin C and interferon alpha-2b**. *Am J Ophthalmol* 2014; 157: 287–293.
- Clode AB, Miller C, McMullen RJ Jr, et al. **A retrospective comparison of surgical removal and subsequent CO<sub>2</sub> laser ablation versus topical administration of mitomycin C as therapy for equine corneolimbic squamous cell carcinoma**. *Vet Ophthalmol* 2012; 15: 254–262.
- Karasawa K, Matsuda H and Tanaka A. **Superficial keratectomy and topical mitomycin C as therapy for a corneal squamous cell carcinoma in a dog**. *J Small Anim Pract* 2008; 49: 208–210.
- Almeida A, Delgado L, Oliveira J, et al. **Use of topical mitomycin C as an alternative treatment for corneal squamous cell carcinoma in a dog** [abstract]. *Vet Ophthalmol* 2016; 19: E4. DOI: 10.1111/vop.12336.
- Khong JJ and Muecke J. **Complications of mitomycin C therapy in 100 eyes with ocular surface neoplasia**. *Br J Ophthalmol* 2006; 90: 819–822.
- Shields CL, Naseripour M and Shields JA. **Topical mitomycin C for extensive, recurrent conjunctival–corneal squamous cell carcinoma**. *Am J Ophthalmol* 2002; 133: 601–606.
- Malalana F, Knottenbelt D and McKane S. **Mitomycin C, with or without surgery, for the treatment of ocular squamous cell carcinoma in horses**. *Vet Rec* 2010; 167: 373–376.