

Gastric Pneumatosis in a Premature Neonate

Yuk Joseph Ting, M.B.B.S., M.P.H., M.R.C.P.CH., F.H.K.A.M.,¹
Kwong-leung Chan, M.B.B.S., F.R.C.S.(Glasg.), F.A.C.S., F.H.K.A.M.,²
Siu-chun Mabel Wong, M.B.B.S., M.R.C.P., F.H.K.A.M.,¹
Stella Chim, M.B.B.S., M.R.C.P., F.H.K.A.M.,¹
and Kar-yin Wong, M.B.B.S., M.R.C.P., F.H.K.A.M.¹

ABSTRACT

Gastric pneumatosis is extremely rare during infancy. It has been reported in association with necrotizing enterocolitis or congenital abnormalities such as pyloric stenosis. Here, we report a case of gastric pneumatosis in a premature neonate on synchronized nasal intermittent positive pressure ventilation. No pneumatosis was noted in the rest of the bowel or esophagus. There could have been mild damage in the gastric mucosa, either related to the placement of the feeding tube or secondary to the use of indomethacin or both. The condition was further aggravated by noninvasive ventilation. An increase in intragastric pressure resulted in the submucosal dissection of air followed by the development of gastric pneumatosis. Conservative management strategies, including the use of a nasogastric tube for decompression and the withholding of feeding, successfully managed the gastric pneumatosis in our patient. An uneventful recovery was made after conservative management. Prompt recognition and evaluation of this condition were essential for making the diagnosis.

KEYWORDS: Gastric pneumatosis, preterm, neonate, synchronized nasal intermittent positive pressure ventilation

Gastric pneumatosis, defined as gas within the wall of the stomach, is an extremely rare condition. It was first reported in a pediatric patient by the Children's Hospital of Philadelphia in 1952.¹ Here, we describe the first case report of gastric pneumatosis associated with the use of indomethacin in a preterm neonate with synchronized nasal intermittent positive pressure ventilation (SNIPPV).

CASE REPORT

A female neonate was born at 29 weeks' gestation with a birth weight of 1310 g. The mother was Nepalese and suffered from severe gestational proteinuric hypertension.

An emergency lower-segment cesarean section was performed because of the maternal condition. One dose of antenatal steroid was given 2 hours prior to delivery. The neonate was delivered without difficulty with Apgar scores of 8 (1 minute) and 9 (5 minutes). She developed respiratory distress syndrome soon after birth and was treated with surfactant replacement. Empirical penicillin and cefuroxime were also administered. The surface swabs, gastric aspirate, and blood cultures taken at birth subsequently yielded no bacterial growth. Both umbilical artery and venous catheters were inserted. In view of her improved respiratory condition, she was extubated on day 3 of life. The SNIPPV was used for respiratory support to improve the chance of successful extubation. The Infant

¹Departments of Paediatrics and Adolescent Medicine, and ²Surgery, The University of Hong Kong, Queen Mary Hospital, Hong Kong.

Address for correspondence and reprint requests: Yuk Joseph Ting, M.B.B.S., M.P.H., M.R.C.P.CH., F.H.K.A.M., Division of Neonatology, Department of Pediatrics, University of British Columbia, Children's and Women's Health Centre of British Columbia, Room 1R47, 4480 Oak Street, Vancouver BC, V6H 3V4, Canada (e-mail: tingyukjoseph@yahoo.com.hk).

Am J Perinatol Rep 2011;1:11-14. Copyright © 2011 by Thieme Medical Publishers, Inc., 333 Seventh Avenue, New York, NY 10001, USA. Tel: +1(212) 584-4662.

Received: November 3, 2010. Accepted: November 3, 2010. Published online: January 24, 2011.

DOI: <http://dx.doi.org/10.1055/s-0030-1271218>.

ISSN 2157-6998.

Star ventilator with the StarSync module (Infrasonics, San Diego, CA) was used to deliver SNIPPV via the short binasal prongs, which provides thoracoabdominal synchronization via the Graseby capsule placed on the abdomen. An orogastric tube was placed. It was closed after each feed (at 2-hour intervals) and aspirated for air and gastric residuals before the next feed. Trophic feeding, mainly in the form of expressed breast milk, was commenced on day 2 of life and was increased gradually by not more than 20 mL/kg/d. Feeding was well tolerated. The meconium was passed at 42 hours of life.

She developed increasing dyspnea and tachypnea on day 5, such that the ventilator rate had to be increased from 30/min to 35/min. Peak inspiratory pressure was increased from 17 to 21 cm H₂O, and positive end-expiratory pressure was set at 5 cm H₂O. Maximum peak inspiratory pressure arrived, increased from 15 to 16 cm H₂O. The flow rate was kept at 8 to 10 L/min. A patent ductus arteriosus was subsequently confirmed by echocardiogram. In view of its significant hemodynamic impact, a course of indomethacin (0.2 mg/kg/dose for three doses) was started on day 7. A central venous catheter was inserted percutaneously to replace the umbilical line for parenteral nutrition. On the same day, she developed feeding intolerance and had gastric retention of 16 mL milk mixed with fresh blood. An urgent abdominal X-ray revealed gastric pneumatosis and portovenous gas. No pneumatosis was noted in the rest of the bowel or esophagus (Fig. 1). Using the necrotizing enterocolitis (NEC) classification by Bell et al, the presence of bloody gastric aspirates, gastric pneumatosis, and portal venous gas should constitute the diagnosis of definite necrotizing enterocolitis (modified Bell's staging II).²⁻⁴ The neonate was reintubated for repeated apnea. Empirical cloxacillin, ceftazidime, metronidazole, and an

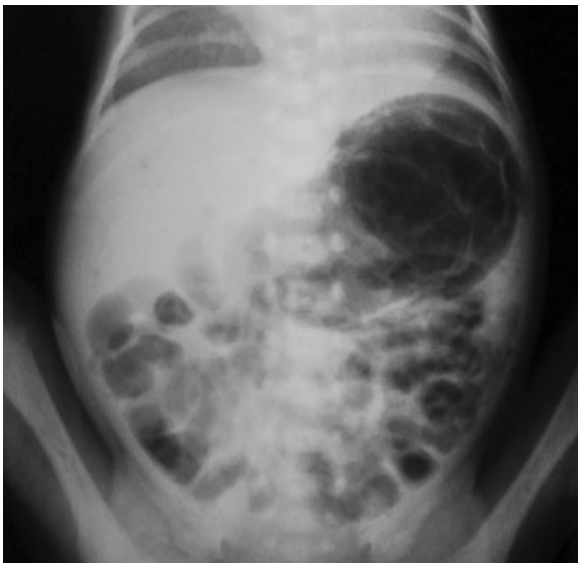


Figure 1 Abdominal X-ray of our patient showing gastric pneumatosis.

H₂-blocker were given to the neonate. A repeat septic workup showed sterile blood cultures and normal white cell counts. No fresh blood was yielded from the orogastric tube by the next day. Serial abdominal X-rays revealed spontaneous resolution of the mural gas in the stomach and the portal venous gas. She was extubated to nasal continuous positive airway pressure 4 days later and received nothing by mouth for 1 week. After the resumption of feeding, there was no feeding intolerance or recurrence of gastric pneumatosis.

Subsequently, the neonate underwent a smooth neonatal course, without intraventricular hemorrhage, retinopathy of prematurity, or chronic lung disease. She was ultimately discharged on day 53. We last saw her at 3 years of age at our outpatient clinic, and she was thriving. Apart from a mild language delay, her neurodevelopment was unremarkable.

DISCUSSION

Gastric pneumatosis is a rarely reported condition and is primarily a radiological diagnosis.⁵ It has been found to be associated with necrotizing enterocolitis, concomitant with pneumatosis intestinalis and hepatobiliary gas as detected by abdominal X-ray.^{6,7} The other reported associations include pyloric stenosis,^{1,8-10} duodenal obstruction,¹¹⁻¹³ and annular pancreas.¹⁴ It has also been reported in a premature infant developing gastric pneumatosis secondary to the placement of an intramural feeding catheter.¹⁵ Krueger et al reported gastric pneumatosis in a neonate with hypoplastic left heart syndrome on day 6 of life before cardiac operation.¹⁶ Taylor et al¹⁷ reported a neonate having this rare condition following a modified Norwood stage I operation for complex cyanotic heart disease.

Nelson¹⁸ summarized the possible mechanisms of the extraluminal gas collections in the gastrointestinal tract, including those of the stomach. These gas collections could either be related to infection of the visceral wall by gas-forming organisms or secondary to gastrointestinal tract obstructions. In the former case, the extraluminal gas collections were related to the direct inflammation and damage of the stomach wall. This inflammation is complicated by the diffusion of gas through breaks in the necrotic mucosa, resulting in gastric pneumatosis detected by X-ray. These observations of "emphysematous gastritis" were primarily reported in adults, especially in alcohol abusers. The more commonly involved bacterial pathogens include *Escherichia coli* and *Streptococcus* and *Enterobacter* species.¹⁹ The patients were usually critically ill, and the condition was associated with both high mortality and morbidity with gastric contractures.¹⁹ In the latter group, the mechanical obstruction of the proximal gastrointestinal tract resulted in elevated intragastric luminal pressure. These obstructions could result in an increase in diffusion

through the grossly intact mucosa or the escape of the intraluminal gas through minor tears in an otherwise normal mucosa.¹⁸ Unlike patients who develop gastric pneumatosis as a result of infection of the visceral wall, this latter group of patients generally enjoyed good prognosis after the prompt correction of the underlying obstruction.¹

SNIPPV use in infants has been associated with reduced incidences of extubation failure, bronchopulmonary dysplasia, neurodevelopmental impairment, and death, as compared with infants managed with nasal continuous positive airway pressure.²⁰⁻²² No recent studies have reported any association of nasal intermittent positive pressure ventilation use with necrotizing enterocolitis or gastric or other intestinal perforations.²⁰ Our center initiated the use of SNIPPV among very low-birth-weight infants in 2003.

In the case described in this report, the cause of the formation of gastric pneumatosis remains unclear. By definition, she had stage II NEC. There was no evidence of sepsis or an upper gastrointestinal tract obstruction in the neonate. We postulated that there could have been mild damage in the mucosa, either related to the placement of the feeding tube or secondary to the use of indomethacin or both. Indomethacin has been well known to exacerbate gastric mucosal injury. The condition was further aggravated by noninvasive ventilation, which introduced air into the stomach. An increase in intragastric pressure resulted in the submucosal dissection of air followed by the development of gastric pneumatosis detected by X-ray. This theory was also supported by the prompt resolution of the pneumatosis after conservative management.

CONCLUSION

Gastric pneumatosis is a rarely reported condition. In our patient, it was associated with the use of indomethacin and feeding tube and exacerbated with the use of non-invasive ventilation. Prompt recognition and evaluation of this condition were essential for making the diagnosis. The infant was also treated for NEC. Conservative management strategies, including the use of a nasogastric tube for decompression and the withholding of feeding, successfully managed the condition in our patient.

ACKNOWLEDGMENT

We would like to thank Dr. Y.Y. Chee for providing editorial assistance.

REFERENCES

- Holgerson LO, Borns PF, Srouji MN. Isolated gastric pneumatosis. *J Pediatr Surg* 1974;9:813-816
- Bell MJ, Ternberg JL, Feigin RD, et al. Neonatal necrotizing enterocolitis. Therapeutic decisions based upon clinical staging. *Ann Surg* 1978;187:1-7
- Sharma R, Tepas JJ III, Hudak ML, et al. Portal venous gas and surgical outcome of neonatal necrotizing enterocolitis. *J Pediatr Surg* 2005;40:371-376
- Duran R, Vatanever U, Aksu B, Acuna B. Gastric pneumatosis intestinalis: an indicator of intestinal perforation in preterm infants with necrotizing enterocolitis? *J Pediatr Gastroenterol Nutr* 2006;43:539-541
- Bajaj M, Ogilvy-Stuart AL. Gastric pneumatosis/interstitial emphysema of the stomach. *Arch Dis Child Fetal Neonatal Ed* 2004;89:F188
- Travadi JN, Patole SK, Simmer K. Gastric pneumatosis in neonates: revisited. *J Paediatr Child Health* 2003;39:560-562
- Khashu M, Rudman D, Osioviich H. Gastric pneumatosis in a preterm infant. *Lancet* 2005;366:1808
- Iñon A, Domínguez M, Rivarola A. Congenital pyloric stenosis: an unusual clinical presentation. *J Pediatr Surg* 1982;17:417-419
- Lester PD, Budge AF, Barnes JC, Kirks DR. Gastric emphysema in infants with hypertrophic pyloric stenosis. *AJR Am J Roentgenol* 1978;131:421-423
- Leonidas JC. Gastric pneumatosis in infancy. *Arch Dis Child* 1976;51:395-398
- Alvarez C, Rueda O, Vicente JM, Fraile E. Gastric emphysema in a child with congenital duodenal diaphragm. *Pediatr Radiol* 1997;27:915-917
- Kataria R, Bhatnagar V, Wadhwa S, Mitra DK. Gastric pneumatosis associated with preduodenal portal vein, duodenal atresia, and asplenia. *Pediatr Surg Int* 1998;14:100-101
- Kawano S, Tanaka H, Daimon Y, et al. Gastric pneumatosis associated with duodenal stenosis and malrotation. *Pediatr Radiol* 2001;31:656-658
- Franquet T, Gonzalez A. Gastric and duodenal pneumatosis in a child with annular pancreas. *Pediatr Radiol* 1987;17:262
- Mandell GA, Finkelstein M. Gastric pneumatosis secondary to an intramural feeding catheter. *Pediatr Radiol* 1988;18:418-420
- Krueger M, Ramsauer T, Dittrich S, Uhl M. Gastric pneumatosis in a neonate with hypoplastic left heart syndrome. *Pediatr Radiol* 2006;36:571
- Taylor DR, Tung JY, Baffa JM, Shaffer SE, Blecker U. Gastric pneumatosis following cardiac surgery. *Eur J Pediatr* 2000;159:553-554
- Nelson SW. Extraluminal gas collections due to diseases of the gastrointestinal tract. *Am J Roentgenol Radium Ther Nucl Med* 1972;115:225-248
- Moosvi AR, Saravolatz LD, Wong DH, Simms SM. Emphysematous gastritis: case report and review. *Rev Infect Dis* 1990;12:848-855
- Bhandari V. Nasal intermittent positive pressure ventilation in the newborn: review of literature and evidence-based guidelines. *J Perinatol* 2010;30:505-512
- Bhandari V, Finer NN, Ehrenkranz RA, et al; Eunice Kennedy Shriver National Institute of Child Health and Human Development Neonatal Research Network. Synchronized nasal intermittent positive-pressure ventilation and neonatal outcomes. *Pediatrics* 2009;124:517-526
- Davis PG, Lemyre B, de Paoli AG. Nasal intermittent positive pressure ventilation (NIPPV) versus nasal continuous positive airway pressure (NCPAP) for preterm neonates after extubation. *Cochrane Database Syst Rev* 2001;(3):CD003212