

# Orbital aperture morphometry in Indian population: A digital radiographic study

Laboni Ghorai,  
M. L. Asha, J. Lekshmy,  
Basetty Neelakantam  
Rajarithnam,  
H. M. Mahesh Kumar  
*Department of Oral Medicine  
and Radiology, Dr. Syamala  
Reddy Dental College, Hospital  
and Research Centre, Bengaluru,  
Karnataka, India*

**Address for correspondence:**  
*Dr. Laboni Ghorai,  
Dr. Syamala Reddy Dental  
College, Hospital and Research  
Centre, #111/1, SGR College  
Main Road, Munnekolala,  
Marathahalli (Post),  
Bengaluru - 560 037,  
Karnataka, India.  
E-mail: dr.labonidey@gmail.com*

## Introduction

The identification of human skeletal remains in forensic investigations is crucial for further analysis.<sup>[1]</sup> Sex determination of the adult skeleton is an important initial step as estimation of age and stature of individual is sex dependent.<sup>[2]</sup> Previous studies reveal that skull is the most dimorphic and easily sexed portion of skeleton after pelvis, with an accuracy up to 92%.<sup>[1]</sup> Human skulls have been used to measure the orbital aperture and morphological

## Abstract

**Background:** Morphological variations of the orbital aperture measurements may be used in forensic medicine as a parameter for determining sexual and ethnic identity of an individual. **Aim and Objective:** The aim and objective of this study was to evaluate the orbital aperture dimensions in Indian individuals and verify their relationship with gender. **Materials and Methods:** A retrospective study was conducted using digital posteroanterior view radiographs of 50 males and 51 females, which were taken using NEWTOM GIANO-CEFLA SC machine (81 kVp, 10 mA, and 6.6 s). The orbital aperture measurements were carried out using NEWTOM software NNT version 5.5. The maximum width and height of the orbits and the inter-orbital distance were measured. The obtained data were subjected to *t*-test and discriminant function analysis. **Results:** In the *t*-test, significant differences in orbital width and inter-orbital distance were obtained between the genders. On subjecting the data to discriminant function analysis, result was obtained with 86.1% accuracy rate in gender determination. **Conclusion:** If the discriminant score is >1.0365, the skull is likely to be of a male, and if it is <1.0365, it is likely to be of a female. Therefore, orbital aperture measurements can be used for gender determination in human identification.

**Key words:** Gender determination, morphometry, orbital aperture, posteroanterior view radiograph


variations of orbital aperture, and orbital bone may be used in forensic medicine as a parameter for sexual and ethnic determination in human identification.<sup>[3]</sup>

Dentomaxillofacial radiology is a valuable tool in forensic dentistry, and radiographs have been used to identify unknown human remains since the early 1900s.<sup>[4]</sup> Metric analyses on the radiographs are often found to be of superior value due to their objectivity, accuracy, and reproducibility. Several radiographic techniques are used

This is an open access article distributed under the terms of the Creative Commons Attribution-NonCommercial-ShareAlike 3.0 License, which allows others to remix, tweak, and build upon the work non-commercially, as long as the author is credited and the new creations are licensed under the identical terms.

**For reprints contact:** reprints@medknow.com

**How to cite this article:** Ghorai L, Asha ML, Lekshmy J, Rajarithnam BN, Mahesh Kumar HM. Orbital aperture morphometry in Indian population: A digital radiographic study. *J Forensic Dent Sci* 2017;9:61-4.

Access this article online	
<b>Website:</b> www.jfds.org	<b>Quick Response Code</b> 
<b>DOI:</b> 10.4103/jfo.jfds_65_16	

to determine the dimensions of the craniofacial structures.<sup>[5]</sup> Studies involving orbital aperture morphometry have been conducted on dry skulls for sex determination,<sup>[3,5-12]</sup> but literature search hardly revealed any study with regard to orbital aperture measurements in Indian population using a digital posteroanterior radiograph.

The present study was designed with the following aims and objectives:

1. To measure, compare, and evaluate the various measurements of orbital apertures as observed on digital posteroanterior radiographs
2. To assess the usefulness of orbital aperture morphometry as an aid in gender determination.

### Materials and Methods

A retrospective study was designed and conducted at Dr. Syamala Reddy Dental College, Hospital and Research Centre in Bengaluru, using digital posteroanterior radiographs of 50 males and 51 females of Indian population in the age group between 20 and 50 years. Ideal posteroanterior radiographs in respect to the anatomic integrity of the orbits were selected for the study. Radiographs revealing pathological, fractured, or deformed orbital morphology were excluded from the study. Radiographs taken by NEWTOM GIANO-CEFLA SC machine with NEWTOM TELERAD GIANO digital image receptor, using 81 kVp exposure and time of 6.6 s at 10 mA, were used for the study. Since this study was conducted on archived radiographs, ethical clearance was not applicable. Orbital aperture measurements were carried out using NEWTOM software NNT version 5.5 (IMOLA-BO, ITALY).

The maximum width (left and right) and maximum height (left and right) of the orbits and the inter-orbital distance (minimum distance between the medial walls of the orbits) were measured by a single observer using mouse-driven method (by moving the mouse and drawing lines using chosen points on the digital posteroanterior radiograph), enhancing the image contrast to 75% for all the radiographs to provide an accurate and reproducible method of measuring the chosen points [Figure 1]. The measurements were performed three times for each radiograph at different periods of time, and mean of the three measurements had been documented. All the linear measurements, obtained from each radiograph, were expressed in millimeters.

### Statistical analysis

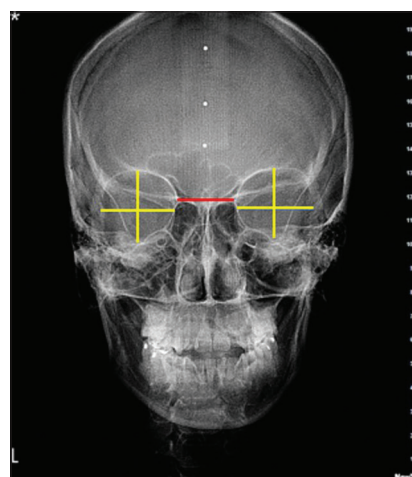
The data were collected, tabulated, and subjected to statistical analysis using statistical package SPSS version 16.0 (SPSS Inc., Chicago, Illinois).

### Results

The measurements obtained were subjected to t-test and discriminant functional analysis.

The *t*-test was applied to compare the different parameters between males and females. In our study, the orbital width (left and right) and inter-orbital distance were greater in males compared with females and were statistically significant [Table 1]. Mean comparisons between males and females have been depicted in Figure 2.

Wilk's lambda value was used to assess the variables' usability for gender determination. If its value is near to "0," that variable can clearly differentiate between genders. Based on this, it can be found that inter-orbital distance has the lowest value. Hence, inter-orbital distance is the best variable for predicting gender [Table 2 and Figure 3].



**Figure 1:** Measurements of orbital widths (horizontal yellow lines), orbital heights (vertical yellow lines), and inter-orbital distance (horizontal red line) on digital posteroanterior radiograph

**Table 1: Descriptive statistics for five orbital parameters and their correlation between genders**

Parameters	Gender	Group statistics				
		Number of samples	Mean	SD	SEM	P
Left orbital height (mm)	Males	50	28.51	1.91	0.27	0.666
	Females	51	28.69	2.16	0.30	
Left orbital width (mm)	Males	50	32.36	1.54	0.21	0.001*
	Females	51	30.81	1.44	0.20	
Right orbital height (mm)	Males	50	28.54	1.95	0.27	0.299
	Females	51	33.23	31.74	4.44	
Right orbital width (mm)	Males	50	32.79	1.40	0.19	0.001*
	Females	51	31.65	1.26	0.17	
Inter-orbital distance (mm)	Males	50	24.84	1.62	0.23	0.001*
	Females	51	22.25	1.54	0.21	

\*Statistically significant at  $P < 0.05$ . SD: Standard deviation, SEM: Standard error of mean

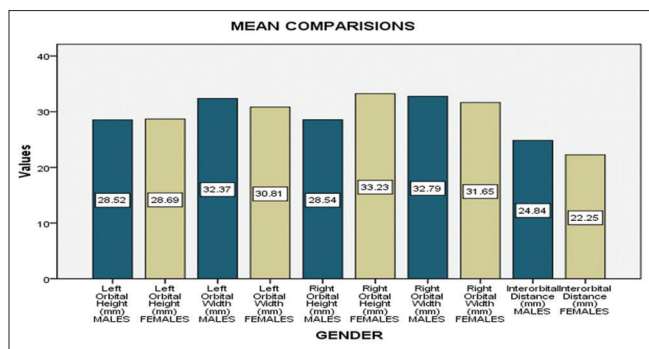


Figure 2: Mean comparisons between males and females

Using Fisher’s linear discriminant function, the coefficient of each parameter was determined [Table 3]. From the data presented in Table 3, a discriminant formula that is obtained for gender determination is as follows:

$$\text{Discriminant score} = -0.137 \times (\text{left orbital height}) + 0.400 \times (\text{left orbital width}) - 0.003 \times (\text{right orbital height}) + 0.081 \times (\text{right orbital width}) + 0.509 \times (\text{inter-orbital distance}) - 23.220.$$

For classifying a given sample as male or female, in this study, the cutoff value was found to be 1.0365. The discriminant scores greater than this cutoff value indicate the sample as male and scores lesser than this value indicate the sample as female [Table 4].

On application of discriminant function analysis to the data of the study, the discriminant model could correctly classify 86.1% of the original grouped cases [Table 5].

## Discussion

The skeleton plays an important role in sex determination in forensic anthropology. Two approaches, morphological (nonmetrical) and metrical, have been proposed by the researchers for the determination of sexual characteristics from the bones.<sup>[13]</sup> It is well known that several structures of the skull have the potential to positively identify an individual due to better retention of the morphological features.<sup>[6]</sup> Orbit is an important anatomical landmark, and morphological variations of the orbital aperture measurements can act as a parameter for sexual and ethnic determination.

The present study demonstrated that the gender difference was significant and that the orbital aperture width and the inter-orbital distance were larger in males than in females in Indian individuals. However, the maximum height of the orbital aperture showed no statistically significant differences between genders. These findings of our study have been found to be consistent with that of the study conducted by Nitek *et al.*<sup>[6]</sup> who evaluated the orbital aperture width and height in 100 Polish dry human skulls

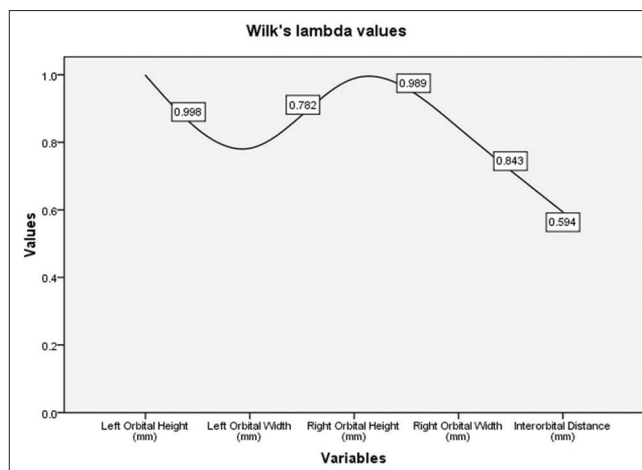


Figure 3: Wilk's Lambda values for different variables

Table 2: Identification of significant parameters in gender determination using discriminant analysis

Parameters	Wilks' Lambda	F	P
Left orbital height (mm)	0.998	0.188	0.666
Left orbital width (mm)	0.782	27.568	0.001*
Right orbital height (mm)	0.989	1.089	0.299
Right orbital width (mm)	0.843	18.471	0.001*
Inter-orbital distance (mm)	0.594	67.780	0.001*

\*Statistically significant at  $P < 0.05$

Table 3: Discriminant function coefficients (dF)

Parameters	dF
Left orbital height (mm)	-0.137
Left orbital width (mm)	0.400
Right orbital height (mm)	-0.003
Right orbital width (mm)	0.081
Inter-orbital distance (mm)	0.509
Constant	-23.220

Table 4: Centroids of the study

Gender	Functions at group centroids	
	Function	
Males	1.047	
Females	-1.026	

Cutoff value=1.0365, i.e., classified as males if discriminant score  $\geq 1.0365$ , classified as females if discriminant score  $\leq 1.0365$

Table 5: Prediction accuracy

Reliability of the obtained formula in gender determination				
Original	Gender	Predicted group membership		
		Males	Females	Total
Count	Males	43	7	50
	Females	7	44	51
Percentage	Males	86.0	14.0	100.0
	Females	13.7	86.3	100.0

86.1% of the original grouped cases correctly classified

and concluded that these dimensions were larger in males than in females.

Cheng *et al.*<sup>[9]</sup> performed several measurements in orbits of Chinese skulls and concluded that the measurements were significantly greater in males than in females. Similarly, Kumar *et al.*<sup>[10]</sup> performed morphometry of bony orbit related to gender in dry adult skulls of South Indian population, where the mean horizontal distance and vertical distance showed a significant increase in distance in males than females. In the present study, only the maximum height of the orbital aperture showed no statistically significant differences between the genders.

In the previous studies on Indian population by Rajangam *et al.*,<sup>[11]</sup> there was no significant difference in the height and breadth of the orbit between the two genders. However, in our study, the maximum width of the orbital aperture showed statistically significant differences between the genders. On the contrary, Sangvichien *et al.*<sup>[12]</sup> have reported that there was no significant difference in the height but a significant difference in the breadth of the orbit between the two genders, which is in accordance with the present study.

Rossi *et al.*<sup>[14]</sup> evaluated the dimensions of the orbital aperture in 97 Brazilian subjects by posteroanterior Caldwell radiographic technique to verify its relationship with gender and concluded that the gender difference was highly significant and that orbital aperture width, area, and inter-orbital distance were larger in males than in females in Brazilian individuals, but the maximum height of the orbital aperture showed no statistically significant differences between genders. These findings are found to be comparable with the present study results.

Pommier *et al.*<sup>[15]</sup> used orbital measurements for fetal age estimation. About 71 fetuses of 14–41 weeks of gestational age were included in the study, of which 48 fetuses were healthy and 23 fetuses had Down syndrome (trisomy 21). Six orbital and one facial computed tomographic scan measurements were taken on each fetus. The authors concluded that the measurements of orbital aperture were useful to identify the pathology when compared with measurements of healthy fetuses, and hence the dimensions of orbit may aid in clinical diagnosis and treatments.

Although it has been established that socio-environmental factors influence the development, and thus the appearance of bones,<sup>[1]</sup> researchers have affirmed that the dimensions of orbit may contribute in clinical, forensic, archaeological contexts, and clinical diagnosis and treatments.<sup>[15]</sup>

## Conclusion

The orbital aperture morphometry can be considered a valuable tool in gender determination since orbit possesses resistance to damage and disintegration processes. This study not only provides useful baseline orbital

morphometric data of Indian population, which are very important during plastic surgery, maxillofacial, and neurosurgeries, but the result of our study also establishes the reliability of orbital aperture morphometry using digital posteroanterior radiographs for gender determination in forensic analysis. In view of this finding, further studies on more diverse populations to assess the significance of these parameters are recommended.

## Financial support and sponsorship

Nil.

## Conflicts of interest

There are no conflicts of interest.

## References

- Saini V, Srivastava R, Rai RK, Shamal SN, Singh TB, Tripathi SK. Mandibular ramus: An indicator for sex in fragmentary mandible. *J Forensic Sci* 2011;56 Suppl 1:S13-6.
- Scheuer L. Application of osteology to forensic medicine. *Clin Anat* 2002;15:297-312.
- Weaver AA, Loftis KL, Tan JC, Duma SM, Stitzel JD. CT based three-dimensional measurement of orbit and eye anthropometry. *Invest Ophthalmol Vis Sci* 2010;51:4892-7.
- Besana JL, Rogers TL. Personal identification using the frontal sinus. *J Forensic Sci* 2010;55:584-9.
- Swan LK, Stephan CN. Estimating eyeball protrusion from body height, interpupillary distance, and inter-orbital distance in adults. *J Forensic Sci* 2005;50:774-6.
- Nitek S, Wysocki J, Reymond J, Piasecki K. Correlations between selected parameters of the human skull and orbit. *Med Sci Monit* 2009;15:BR370-7.
- Karakas P, Bozkir MG, Oguz O. Morphometric measurements from various reference points in the orbit of male Caucasians. *Surg Radiol Anat* 2003;24:358-62.
- Bakholdina VI. Morphometric characteristics and typology of the human orbit. *Morfologija* 2008;133:37-40.
- Cheng AC, Lucas PW, Yuen HK, Lam DS, So KF. Surgical anatomy of the Chinese orbit. *Ophthal Plast Reconstr Surg* 2008;24:136-41.
- Kumar SS, Gnanagurudasan E. Morphometry of bony orbit related to gender in dry adult skulls of South Indian population. *Int J Health Sci Res* 2015;5:207-14.
- Rajangam S, Kulkarni RN, Quadriolos Lydia S, Sreenivasulu S. Orbital dimensions. *Indian J Anat* 2012;1:5-9.
- Sangvichien S, Boonkaew K, Chuncharunee A, Komoltri PH, Piyawinitwong S, Wongsawut A. Sex determination in Thai skulls by using craniometry: Multiple logistic regression analysis. *Siriraj Med J* 2007;59:216-21.
- Hsiao TH, Tsai SM, Chou ST, Pan JY, Tseng YC, Chang HP, *et al.* Sex determination using discriminant function analysis in children and adolescents: A lateral cephalometric study. *Int J Legal Med* 2010;124:155-60.
- Rossi AC, de Souza Azevedo FH, Freire AR, Groppo FC, Júnior ED, Ferreira Caria PH, *et al.* Orbital aperture morphometry in Brazilian population by postero-anterior Caldwell radiographs. *J Forensic Leg Med* 2012;19:470-3.
- Pommier S, Adalian P, Gaudart J, Panuel M, Piercecchi-Marti MD, Leonetti G. Fetal age estimation using orbital measurements: 3D CT-scan study including the effects of trisomy 21. *J Forensic Sci* 2009;54:7-12.