

Atrial fibrillation cardioversion following acupuncture

Dario Dilber, MD, Jasna Čerkez-Habek, MD, PhD, Hrvoje Barić, MD, Marina Gradišer, MD, PhD.

ABSTRACT

الرجفان الأذيني (AF) هو عدم انتظام ضربات القلب الأكثر شيوعاً وهو عامل خطر مستقل للأحداث الحرجة. شعبية الوخز بالإبر في تزايد مستمر لدى الغرب، وتوجد تقارير عن فوائده في علاج AF. نبلغ عن رجل يبلغ من العمر 57 عاماً والذي تم ادخاله المستشفى بعد تعرضه لرد فعل من الحساسية من أخذه لأميودارون وذلك لعلاج AF الانتبائي مع استجابة البطين السريعة. كان تقويم نظم القلب مع بروبافينون الوريد هادئ. قبل محاولة تقويم نظم القلب الكهربائي، كان يعالج بالوخز بالإبر كعلاج إضافي لبروبافينون عن طريق الفم. بعد العلاج بالوخز بالإبر المتألف من 10 علاجاً خلال مدة 30 يوماً، تم تسجيل كل من نظم القلب الفوري والجيبى ماعدا AF الانتبائي.

Atrial fibrillation (AF) is the most common arrhythmia and it is an independent risk for serious events. Acupuncture has been growing in popularity in the West, and there are reports of its benefits in treating AF. We report a 57-year-old man who was admitted after having an allergic reaction to amiodarone administered to treat paroxysmal AF with fast ventricular response. Cardioversion with intravenous propafenone was uneventful. Before an attempt of electric cardioversion, he was treated with acupuncture as additional therapy to peroral propafenone. After acupuncture treatment consisting of 10 treatments during 30 days period, both immediate cardioversion to sinus rhythm and no paroxysmal AF during 30 days period were recorded.

*Saudi Med J 2015; Vol. 36 (11): 1351-1353
doi: 10.15537/smj.2015.11.12891*

From the Departments of Cardiology (Dilber), Endocrinology and Diabetes (Gradišer), County Hospital Čakovec, the Međimurje County Institute for Emergency Medicine (Barić), Čakovec, and the Department of Internal Medicine (Čerkez-Habek), University Hospital Sveti Duh, Zagreb, Croatia.

Received 13th July 2015. Accepted 2nd September 2015.

Address correspondence and reprint request to: Dr. Hrvoje Barić, the Međimurje County Institute for Emergency Medicine, Čakovec 40000, Croatia. E-mail: hrvojebaric00@gmail.com

Atrial fibrillation (AF) is the most common type of arrhythmia, occurring in 1-2% in the overall population.¹ It confers an independent risk for stroke and death, reduces quality of life, affects left ventricular function, and causes significant treatment costs.^{1,2} Therapeutic approaches are aimed at controlling ventricular response, preventing thromboembolic incidents, and restoration of sinus rhythm.¹ For the latter, they include pharmacologic and nonpharmacologic cardioversion.¹ Acupuncture has been used in Chinese traditional medicine for thousands of years in the management of numerous conditions. In recent decades, it has grown in popularity in Western countries, and its efficacy and safety is being researched.³ There have been reports of its efficiency in management of paroxysmal supraventricular tachycardia and hypertension, and reducing chest pain.⁴ A study published in 2011 indicated that acupuncture might be efficient in preventing recurrence after cardioversion of AF.⁴ A study protocol for a randomized controlled trial investigating antiarrhythmic effects of acupuncture in persistent AF has been published more recently.⁵ We report a case of sinus rhythm restoration in an episode of paroxysmal AF following acupuncture treatment. The objective in presenting this particular case is to prompt research into acupuncture safety and efficacy in atrial fibrillation management.

Case Report. A 57-year-old Caucasian male was brought to our emergency department (ED) following an allergic reaction (flushing, chest rash, and drop in blood pressure [BP] to 90/60 mm Hg) to intravenous (i.v.) amiodarone administered by the emergency medical service (EMS) to treat atrial fibrillation. Upon admission, he was anxious and complained of palpitations. He had a history of palpitations and experienced several episodes of irregular heart rhythm following lack of sleep, or periods of work-related stress.

Disclosure. Authors have no conflict of interest, and the work was not supported or funded by any drug company.

He had arterial hypertension for 2 years, and was regularly taking his prescribed medication (5 mg ramipril and 5 mg amlodipine). In his family history, there were no serious diseases and cardiovascular emergencies. His palpitations started 6 hours before presenting to the EMS. An electrocardiogram (ECG) at the EMS showed AF with fast ventricular response (125 bpm). Blood pressure was 180/110 mm Hg and physical examination showed no abnormalities other than irregular heart rhythm on auscultation. He was administered 300 mg amiodarone in 250 mL 5% dextrose solution, and in a matter of minutes had a drop in BP, a rash appeared on his chest, and he complained of flushing. Amiodarone was stopped, and 150 mg propafenone in 250 mL 5% dextrose solution i.v. was administered as an alternative. This attempt at cardioversion was unsuccessful, and he was transferred to our ED.

Clinical findings. Upon arrival to our ED he was agitated and complained of palpitations. His physical examination findings were unremarkable other than irregular heart rhythm on heart auscultation.

Diagnostic assesment. His BP was 130/80 mm Hg, pulse above 125 bpm, pulse oximeter showed 98% oxygenation. His body mass index was 29.2 kg/m², body temperature 36.7°C. The ECG showed atrial fibrillation with an average ventricular response of 107 bpm. He had left electrical axis and left anterior fascicular block. There were no signs of accessory electrical conduction pathway in ECG. There were no radiological or clinical signs of cardiac decompensation, and we ruled out acute coronary or pulmoembolic syndrome. We performed both transtoracic and transesophageal echocardiography, which showed structurally normal heart with normal heart cavities and good systolic function of the left ventricle, with no visible thrombus. He was on telemetry monitoring during the index hospitalization. After having ruled out immediate and life-threatening causes, such as cardiac ischemia, congestive heart failure, and pulmonary embolism, other possible causes of paroxysmal AF were considered. The common causes of atrial fibrillation are well known, and diagnostic tests revealed no underlying structural heart disease. Thyrotoxicosis was excluded and there were no electrolyte disorders.

Therapeutic interventions. According to AF treatment guidelines and patient workup results, we decided for rhythm-control strategy rather than rate-control strategy since paroxysmal FA lasted less than 48 hours. Propafenone was prescribed in an oral dose of 150 mg twice a day, bisoprolol 2.5 mg in the morning, and standard thromboprophylaxis

with nadroparine 0.8 ml subcutaneously once a day. A betablocator was excluded from therapy due to AF with bradycardic ventricular response (<60 bpm), and a drop of arterial BP to 105/75 mm Hg. He was very anxious and experienced palpitations, therefore we decided to treat him with acupuncture before performing a transesophageal ultrasound. He was scheduled for electrocardioversion for the upcoming day. Acupuncture was administered by a physician accredited at the Croatian Society for Acupuncture, a member of the International Council of Medical Acupuncture and Related Techniques. He was stimulated bilaterally with acupuncture needles (Tewa coated needle PB 2540, 0.25 × 40 mm) at 3 acupuncture points (HT-7, ST-36 and PC-6). Manual stimulation of the acupuncture point was performed until "De-Qui" effect (sensation of numbness, distension, or electrical tingling at the needling site) was produced, and then needles were left for 25 minutes. There was an instant drop of ventricular response rate during treatment and 2 hours after acupuncture therapy cardioversion to sinus rhythm occurred. There was no significant drop of arterial BP during or after acupuncture therapy. He received additional ambulatory acupuncture therapy during 10 treatments every third day in addition to propafenone at peroral dose of 300 mg twice a day. No anticoagulation was recommended due to CHA2DS2-VASC score of zero (0). He was urged to minimize work-related stress and keep a diary of his symptoms.

Follow-up and outcomes. Twenty-four-hour Holter ECG performed after one month showed sinus rhythm with median frequency of 72/min. At 3 month follow-up examination, ECG showed sinus rhythm. No palpitations or other symptoms were reported by the patient. Events and interventions are summarized in the timeline (Figure 1). A written consent was provided by the patient regarding presenting his case.

Discussion. Recent reports indicate that acupuncture might have a role in reducing AF recurrences in persistent AF after cardioversion.⁴ Vagal modulation is the most likely explanation for effects exerted by Neiguan spot stimulation, including reduction of AF recurrence rate after cardioversion.⁴ Although paroxysmal AF can terminate spontaneously and administered therapy can have late antiarrhythmic effects, temporal coincidence of acupuncture, immediate heart rate decrease, and subsequent cardioversion in our patient could be explained by an adjuvant vagal effect of acupuncture. During follow-up period we could only assess symptomatic recurrences, and we are limited in evaluating long-term effects of acupuncture in our patient. Several reports have

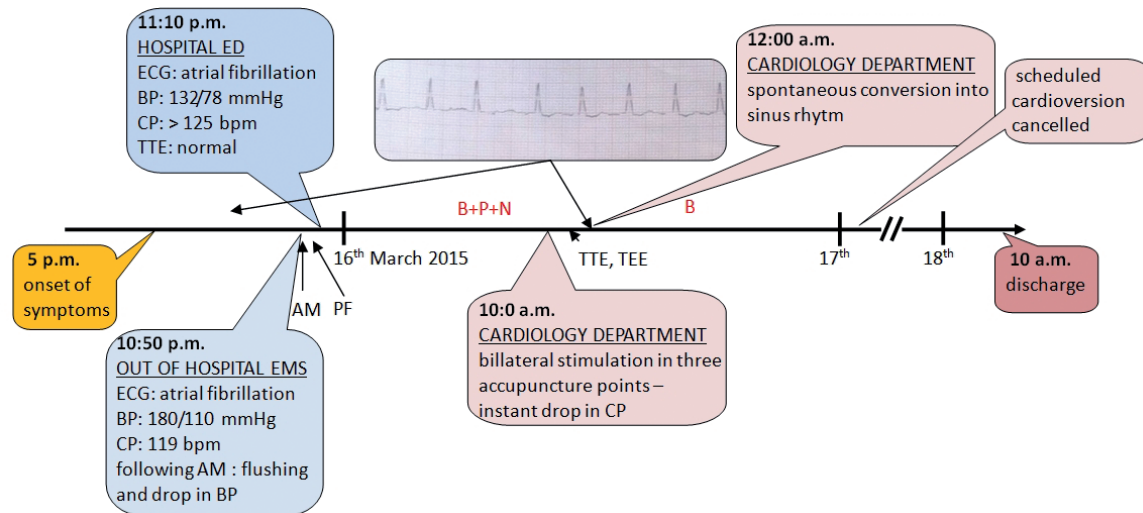


Figure 1 - Timeline of events. BP - blood pressure, CP - pulse frequency, TTE - transthoracic echocardiography, ECG - electrocardiogram; TEE - transesophageal echocardiography; ED - emergency department, EMS - emergency medical service, AM - amiodarone 300 mg intravenously, PF - propafenone 300 mg intravenously, B - bisoprolol 2.5 mg orally, P - propafenone 150 mg orally, N - nadroparine 0.8 mL subcutaneously

indicated that imbalanced autonomic neural activity is associated with initiation and maintenance of AF episodes.⁵ Non-pharmacologic autonomic system neuromodulation techniques are already in clinical use in AF management and control, while others, including somatic sensory stimulation are still being tested.⁶

Stimulation of the Neiguan spot (PC-6) has been used in Western medicine for treatment of chest pain, sickness, and vomiting.⁴ Acupuncture efficiency has been investigated in several cardiovascular conditions, however, results remain controversial. A randomized controlled trial⁷ showed that 6 weeks of acupuncture treatment significantly lowered mean BP compared with sham acupuncture, which could be explained by a mediating effect of autonomous nerve system. Likewise, acupuncture significantly affected heart rate variability in healthy subjects.⁸ A recent study⁹ reported acupuncture efficacy similar to that of “the most active available antiarrhythmic drug”. With respect to these reports, it seems plausible that acupuncture effects could be additive to antiarrhythmic efficacy of conventional pharmacotherapy. Acupuncture safety and efficacy remain to be determined, as well as selection criteria for patients who could benefit from this treatment.

In conclusion, acupuncture treatment as a minimally invasive procedure appears to be safe, without any pro-arrhythmic effects, low-cost, and effective additional therapy in patients with paroxysmal atrial fibrillation.

References

1. European Heart Rhythm Association; European Association for Cardio-Thoracic Surgery, Camm AJ, Kirchhof P, Lip GY, Schotten U, et al. Guidelines for the management of atrial fibrillation: the Task Force for the Management of Atrial Fibrillation of the European Society of Cardiology (ESC). *Eur Heart J* 2010; 31: 2369-2429.
2. Kirchhof P, Auricchio A, Bax J, Crijns H, Camm J, Diener HC, et al. Outcome parameters for trials in atrial fibrillation: executive summary. *Eur Heart J* 2007; 28: 2803-2817.
3. Luo J, Xu H, Liu B. Real world research: a complementary method to establish the effectiveness of acupuncture. *BMC Complement Altern Med* 2015; 15: 153.
4. Lomuscio A, Belletti S, Battezzati PM, Lombardi F. Efficacy of acupuncture in preventing atrial fibrillation recurrences after electrical cardioversion. *J Cardiovasc Electrophysiol* 2011; 22: 241-247.
5. Park J, Kim HS, Lee SM, Yoon K, Kim WS, Woo JS, et al. Acupuncture antiarrhythmic effects on drug refractory persistent atrial fibrillation: study protocol for a randomized, controlled trial. *Evid Based Complement Alternat Med* 2015; 2015: 613970.
6. Chen PS, Chen LS, Fishbein MC, Lin SF, Nattel S. Role of the autonomic nervous system in atrial fibrillation: pathophysiology and therapy. *Circ Res* 2014; 114: 1500-1515.
7. Flachskampf FA, Gallasch J, Gefeller O, Gan J, Mao J, Pfahlberg AB, et al. Randomized trial of acupuncture to lower blood pressure. *Circulation* 2007; 115: 3121-3129.
8. Chung JW, Yan VC, Zhang H. Effect of acupuncture on heart rate variability: a systematic review. *Evid Based Complement Alternat Med* 2014; 2014: 819871.
9. Lombardi F, Belletti S, Battezzati PM, Lomuscio A. Acupuncture for paroxysmal and persistent atrial fibrillation: An effective non-pharmacological tool? *World J Cardiol* 2012; 4: 60-65.