

Original Article



Single-port laparoscopic transperitoneal infrarenal para-aortic lymphadenectomy as part of staging operation for early ovarian cancer and high grade endometrial cancer

Yoon Soon Lee

Department of Obstetrics and Gynecology, Kyungpook National University Medical Center, Kyungpook National University School of Medicine, Daegu, Korea

OPEN ACCESS

Received: Dec 9, 2015

Revised: Jan 24, 2016

Accepted: Jan 25, 2016

Correspondence to

Yoon Soon Lee

Department of Obstetrics and Gynecology,
Kyungpook National University Medical Center,
Kyungpook National University School of
Medicine, 807 Hoguk-ro, Buk-gu, Daegu
41404, Korea.
E-mail: yslee@knu.ac.kr

Copyright © 2016. Asian Society of
Gynecologic Oncology, Korean Society of
Gynecologic Oncology

This is an Open Access article distributed under
the terms of the Creative Commons Attribution
Non-Commercial License ([http://
creativecommons.org/licenses/by-nc/4.0/](http://creativecommons.org/licenses/by-nc/4.0/))
which permits unrestricted non-commercial
use, distribution, and reproduction in any
medium, provided the original work is properly
cited.

ORCID

Yoon Soon Lee
<http://orcid.org/0000-0001-9013-9740>

Conflict of Interest

No potential conflict of interest relevant to this
article was reported.

ABSTRACT

Objective: The aim of this paper was to demonstrate the techniques of single-port laparoscopic transperitoneal infrarenal paraaortic lymphadenectomy as part of surgical staging procedure in case of early ovarian cancer and high grade endometrial cancer.

Methods: After left upper traction of rectosigmoid, a peritoneal incision was made caudad to inferior mesenteric artery. Rectosigmoid was mobilized, and then the avascular space of the lateral rectal portion was found by using upward traction of rectosigmoid mesentery. Inframesenteric nodes were removed without injury to the ureter and the left common iliac nodes were easily removed due to the upward traction of the rectosigmoid. The superior hypogastric plexus was found overlying the aorta and sacral promontory, and presacral nodes were removed at subaortic area. Peritoneal traction suture to right abdomen was needed for right para-aortic lymphadenectomy. After right lower para-aortic node dissection, operator was situated between the patient's legs. After upper traction of the small bowel, left upper para-aortic nodes were removed. To prevent chylous ascites, we used hemolock or Ligasure application (ValleyLab Inc.) to upper part of infrarenal and aortocaval nodes.

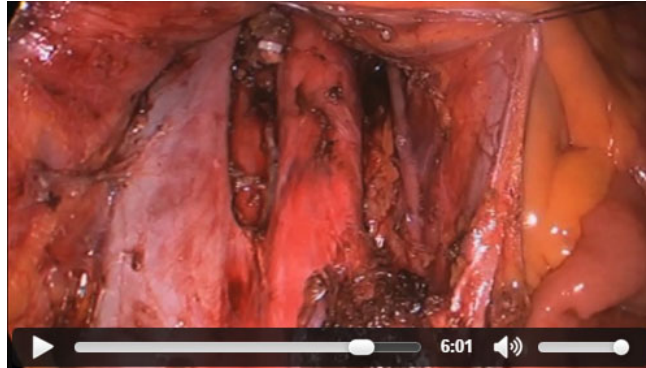
Results: Single-port laparoscopic transperitoneal infrarenal para-aortic lymphadenectomy was performed without serious perioperative complications.

Conclusion: Even though the technique of single-port surgery is still a difficult operation, the quality of single-port laparoscopic transperitoneal infrarenal para-aortic node dissection is excellent, especially mean number of para-aortic nodes. In cases of staging procedures for ovary and endometrial cancer, single-port transperitoneal para-aortic lymphadenectomy is acceptable as an oncologic procedure.

Keywords: Infrarenal Para-Aortic Lymphadenectomy; Single-Port; Transperitoneal

VIDEO CLIP

Single-port laparoscopic transperitoneal infrarenal para-aortic lymphadenectomy as part of staging operation for early ovarian cancer and high grade endometrial cancer.



Video can be found with this article online at <http://ejgo.org/src/sm/jgo-27-e32-s001.wmv>.