

Sequential MR imaging (with diffusion-weighted imaging) changes in metronidazole-induced encephalopathy

Rupinder Singh, Ramanjeet Kaur², Pawan Pokhariyal¹, Rajul Aggarwal¹

Departments of Neuroradiology and ¹Neurology, Sri Bala Ji Action Medical Institute, ²Department of Gynaecology, Kasturba Hospital, New Delhi, India

Correspondence: Dr. Rupinder Singh, Department of Neuroradiology, Sri Bala Ji Action Medical Institute, New Delhi, India.
E-mail: rupinder.dr@gmail.com

Abstract

Metronidazole-induced neuro-toxicity, though rare, is known. A characteristic spatial distribution of lesions in cerebellar dentate nuclei and dorsal pons is known. However, temporal progression of lesions on magnetic resonance imaging (MRI) has not been described previously. We describe two such cases which presented initially with splenial hyperintensity and showed progression to characteristic lesions. Both cases improved with stoppage of metronidazole.

Key words: Magnetic resonance imaging; metronidazole; metronidazole-induced encephalopathy; splenial hyperintensity

Introduction

Metronidazole is an antibiotic, antiprotozoal, and amoebicide agent of the nitroimidazole group. It is one of the commonly used antibiotics in clinical practice and is considered safe. In the past few years, there have been few reports of metronidazole-induced neurotoxicity and characteristic pattern of bilateral symmetrical hyperintensity in the supratentorial white matter, corpus callosum, and within the cerebellum and deep cerebellar nuclei on magnetic resonance imaging (MRI).^[1] However, none of these describe the temporal progression of lesions on MRI. We present two cases depicting progressive MRI changes including diffusion-weighted imaging (DWI) changes of metronidazole toxicity.

Case History

Case 1

A 41-year-old male presented with fever for 2 days, slurring of speech, difficulty in recognition, and irrelevant talk since 1 day. No history of headache, loss of consciousness, or seizures was present. Patient was admitted 15 days back with complaints of loose motions, abdominal pain, and fever. He was diagnosed to have amoebic liver abscess and was started on metronidazole 400 mg orally thrice a day.

This time neurological examination revealed altered consciousness [Glasgow Coma Scale 14 (E4M6V4)], disorientation, bilateral reacting pupils, slurring of speech, and positive cerebellar signs with left past pointing. No cranial nerve palsy or motor weakness was seen.

This is an open access article distributed under the terms of the Creative Commons Attribution-NonCommercial-ShareAlike 3.0 License, which allows others to remix, tweak, and build upon the work non-commercially, as long as the author is credited and the new creations are licensed under the identical terms.

For reprints contact: reprints@medknow.com

Cite this article as: Singh R, Kaur R, Pokhariyal P, Aggarwal R. Sequential MR imaging (with diffusion-weighted imaging) changes in metronidazole-induced encephalopathy. Indian J Radiol Imaging 2017;27:129-32.

Access this article online

Quick Response Code:



Website:
www.ijri.org

DOI:
10.4103/ijri.IJRI_341_16

MRI brain on day 1 of the admission showed DWI hyperintensity in the splenium of corpus callosum suggesting acute infarct or toxic encephalopathy. Restricted diffusion was confirmed on apparent diffusion coefficient mapping (with ADC value of $0.5 \times 10^{-3} \text{ mm}^2/\text{s}$) [Figure 1]. Gradient recovery echo images showed no evidence of hemorrhage.

The patient was started on antiplatelet, low molecular weight heparin, and other supportive treatment. Metronidazole was continued. However, there was no improvement, rather severity of ataxia increased.

MRI brain repeated on the fifth day showed hyperintensities involving the bilateral dentate nuclei in cerebellum with resolution of corpus callosal lesions suggesting toxic encephalopathy [Figure 2].

At this point, metronidazole toxicity was strongly considered. Metronidazole was immediately stopped, and the patient started showing recovery over next 3 days. He was discharged on the eighth day without any motor or cranial nerve deficit.

Case 2

A 56-year-old female presented with difficulty in speech and decreased hearing since 1 day. She was taking

metronidazole 400 mg orally thrice daily since 5 days for gastroenteritis (severe vomiting and loose motions). The patient was admitted with a possibility of cerebrovascular event and investigated.

Her neurological examination revealed disorientation, altered consciousness (GCS-E4M5Vslurred), bilateral reacting pupils, slurring of speech, and positive cerebellar signs with right cerebellar ataxia. Motor examination revealed right upper limb weakness with power of 4/5 and bilateral mute plantar reflexes.

MRI brain [Figure 3] which showed hyperintensity in the splenium of corpus callosum with diffusion restriction (ADC value of $0.6 \times 10^{-3} \text{ mm}^2/\text{s}$) for which radiological possibilities of infarct, metabolic, or viral encephalitis were considered. Lumbar puncture showed 3 cells, mostly lymphocytes, glucose 80mg/dl, and protein 20mg/dl.

She was started with antiplatelets, antibiotics, and other supportive treatment. Metronidazole was continued. Patient condition deteriorated over the next 48 hours, became drowsier, and was intubated. MRI brain [Figure 4] repeated after 3 days showed multiple hyperintense lesions in corpus callosum, dentate nuclei of cerebellum, brainstem, and deep white matter, suggesting toxic encephalopathy.

Possibility of metronidazole toxicity was strongly considered at this stage. Metronidazole was withheld

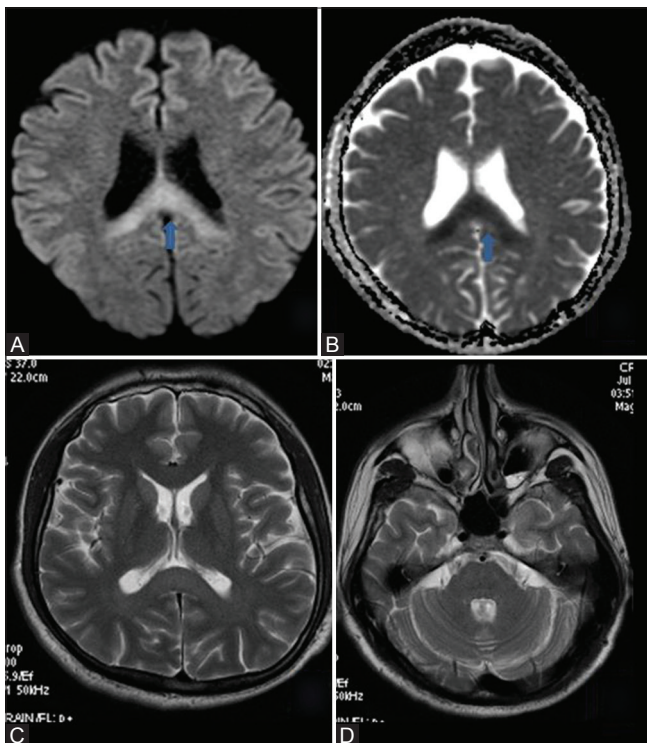


Figure 1 (A-D): Initial Magnetic resonance imaging (Brain) of case 1, showing symmetric areas of hyper intensity in splenium of the corpus callosum (arrow) on DWI (A) with restricted diffusion ADC mapping (B) (ADC value of $0.5 \times 10^{-3} \text{ mm}^2/\text{s}$) and T2-weighted images, axial (C and D) no signal change in corpus callosum (C) cerebellum and pons (D)

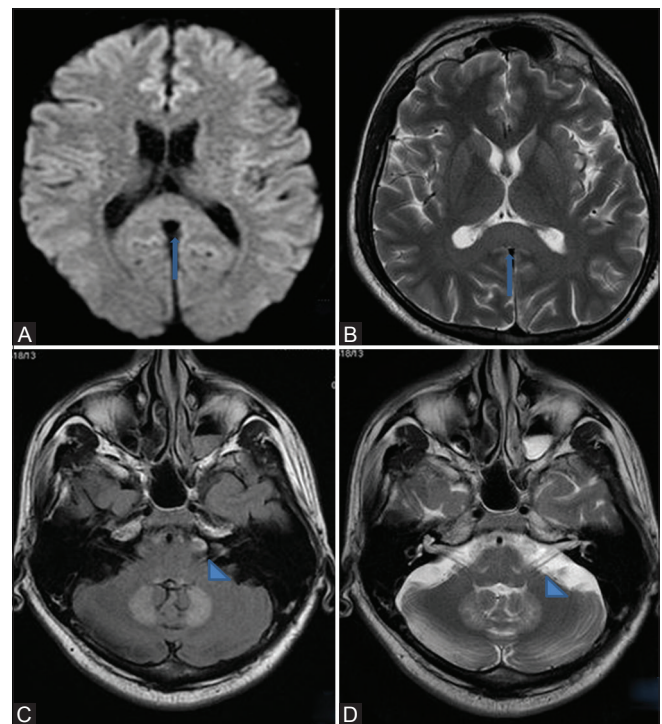


Figure 2 (A-D): Follow up MRI of case 1 after 5 days, showing resolution of hyper intensity in splenium of corpus callosum (arrow) on DWI (A) normal signal on T2W (B) and characteristic involvement of dentate nucleus on (C) Axial FLAIR and (D) Axial T2-weighted images

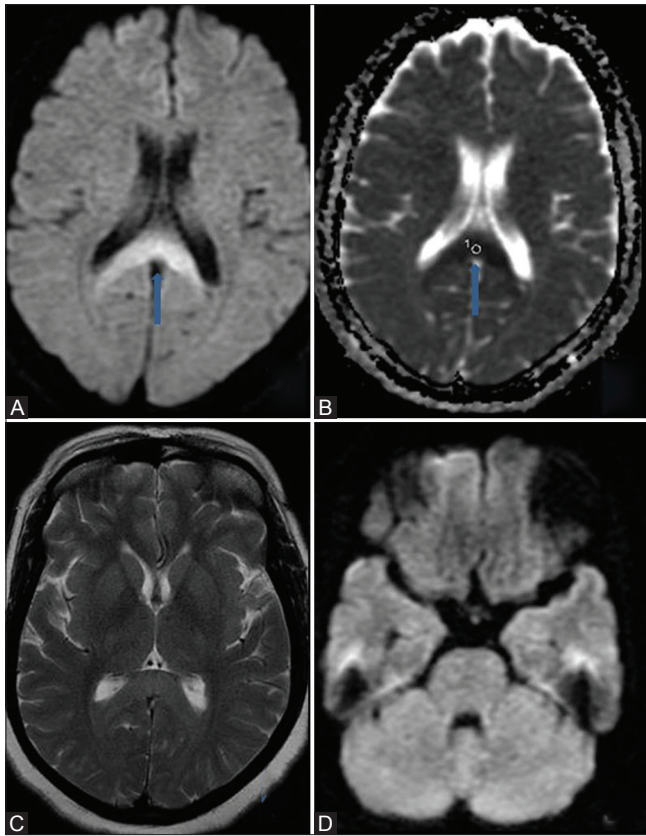


Figure 3 (A-D): Initial Magnetic resonance imaging (Brain) of case 2, showing symmetric areas of hyper intensity involving the splenium of the corpus callosum (arrow) on (A) Axial DWI with restricted diffusion (value of $0.6 \times 10^{-3} \text{ mm}^2/\text{s}$) on ADC map (B), (C) axial T2-weighted images, signal change in corpus callosum (D) Axial DWI no signal change in cerebellum and pons

immediately. Patient started improving and was weaned off the ventilator over the next 3 days. Patient was discharged on the ninth day in stable condition.

Discussion

The available literature describes very few cases with imaging findings of metronidazole-induced encephalopathy and none describe the temporal progression of initial midline splenial lesions to more characteristic sites as bilateral symmetrical supratentorial white matter and deep cerebellar nuclei, as seen in both our cases.

Among the initial descriptions in literature, Ahmed *et al.*^[1] were the first to describe MRI findings of metronidazole toxicity in a 45-year-old female as bilateral symmetrical, abnormal hyperintensity in the supratentorial white matter, corpus callosum, and within the cerebellum and deep cerebellar nuclei on T2-weighted images. They suggested axonal swelling with increased water content due to toxic injury or localized reversible ischemia due to vascular spasm as possible mechanism. A few subsequent case reports^[2-4] have described symmetric lesions at additional sites as in

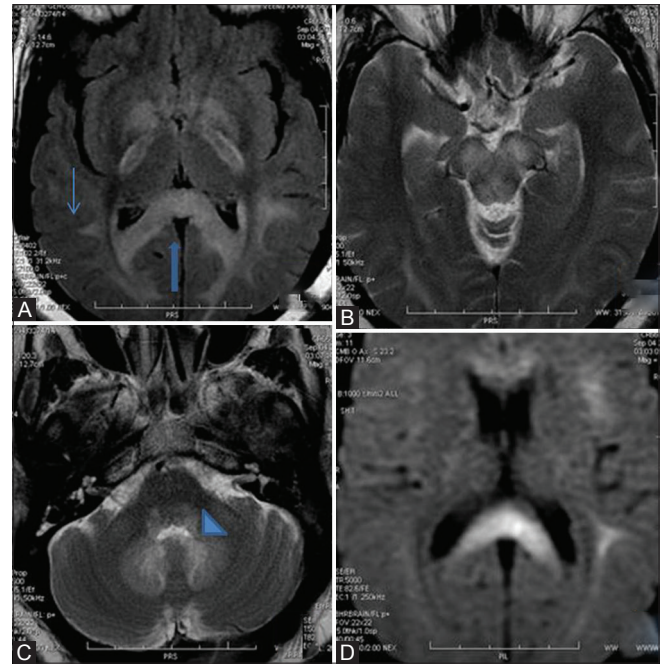


Figure 4 (A-D): Follow up MRI brain, Axial T2 (A-C) Multiple T2 hyper intense lesions at characteristic sites involving corpus callosum (bold arrow), subcortical white matter (arrow), midbrain (B), dentate nucleus (arrowhead) and dorsal pons. (D) Axial DWI showing symmetric areas of hyper intensity involving the splenium of the corpus callosum

colliculus, superior olive, and cochlear nuclei, indicating their reversibility. Other theories for signal changes including interstitial edema and ischemia as cause of signal intensity on diffusion-weighted imaging or cell damage to Purkinje cells due to binding of the drug to neuronal RNA, causing inhibition of protein synthesis, and axonal degeneration have also been postulated.^[2-4]

Second MR in our cases showed similar characteristic spatial distribution of cerebellar dentate nuclei and dorsal pons in both the cases prompting us to implicate metronidazole as a causative agent. Other common causes of such multifocal hyper intensities such as multiple sclerosis, acute disseminated encephalomyelitis, Wernicke encephalopathy, and enteroviral encephalomyelitis were excluded by clinical history and investigations.

In both our cases, initial imaging showed only splenial hyperintensity on DWI. The differential diagnosis of splenial hyperintensity (or boomerang sign as it is sometimes described)^[5] is vast including ischemia, infections – encephalitis (influenza, *Escherichia coli*, mumps, adenovirus, Epstein-Barr, virus and Rota virus), demyelinating lesions including multiple sclerosis, posterior reversible encephalopathy syndrome, diffuse axonal injury, Marchiafava-Bignami disease, adrenoleukodystrophy, AIDS dementia complex, lymphoma, epilepsy, antiepileptic drug usage, osmotic myelinolysis, and acute toxic

encephalopathy.^[6] However, mechanism of this splenial hyperintensity is incompletely understood. Various mechanisms proposed include breakdown of the blood–brain barrier,^[7] reversible demyelination or transient disturbance of energy metabolism, and ionic transport causing intramyelinic edema.^[8] In both the cases, metronidazole toxicity was not considered at the onset, and the drug was continued as index of suspicion was low both radiologically and clinically. Both these cases showed restricted diffusion on initial MR indicative of cytotoxic edema as cause in initial stage, suggesting a mechanism of intramyelinic edema.

We propose a mechanism of selective vulnerability and variable affinity of neurons for metronidazole as cause of characteristic and temporal progression of lesions. Metronidazole or its immune mediator may have specific high affinities receptors on splenial axons evidenced by initial cytotoxic edema (confirmed by high ADC values), and persistent exposure might result in cell damage and involvement of other characteristic sites with lesser affinity such as cerebellar dentate nuclei dorsal pons and cerebral white matter.

These cases call attention to metronidazole toxicity as differential diagnosis of splenial hyperintensity before MRI reveals characteristic multifocal site pattern.

Financial support and sponsorship

Nil.

Conflicts of interest

There are no conflict of interest.

References

1. Ahmed A, Loes DJ, Bressler EL. Reversible magnetic resonance imaging findings in metronidazole induced encephalopathy. *Neurology* 1995;45:588-9.
2. Kim E, Na DG, Kim EY, Kim JH, Son KR, Chang KH. Imaging of metronidazole induced encephalopathy: Lesion distribution and diffusion-weighted imaging findings. *Am J Neuroradiol* 2007;28:1652-8.
3. Lee SS, Cha SH, Lee SY, Song CJ. Reversible inferior colliculus lesion in metronidazole induced encephalopathy: Magnetic resonance findings on diffusion-weighted and Fluid Attenuated Inversion Recovery Imaging. *J Comput Assist Tomogr* 2009;33:305-8.
4. Kalia V, Vibhuti, Sagar K. Case report: MRI of the brain in metronidazole toxicity. *Indian J Radiol Imaging* 2010;20:195-7.
5. Hardeep M S, Ravindra GK, Mukund VR, Pawan KS. Boomerang sign: Clinical significance of transient lesion in splenium of corpus callosum. *Ann Indian Acad Neurol* 2012;15:151-7.
6. Conti M, Salis A, Urigo C, Canalis L, Frau S, Canalis GC. Transient focal lesion in the splenium of the corpus callosum: MR imaging with an attempt to clinical-physiopathological explanation and review of the literature. *Radiol Med* 2007;112:921-35.
7. Cohen-Gadol AA, Britton JW, Jack CR, Jr, Friedman JA, Marsh WR. Transient postictal magnetic resonance imaging abnormality of the corpus callosum in a patient with epilepsy. Case report and review of the literature. *J Neurosurg* 2002;97:714-7.
8. Oster J, Doherty C, Grant PE, Simon M, Cole AJ. Diffusion-weighted imaging abnormalities in the splenium after seizures. *Epilepsia* 2003;44:852-4.