

Modified deep anterior lamellar keratoplasty for the treatment of advanced keratoconus with steep corneal curvature to help in eliminating the wrinkles in the Descemet's membrane

Hamid Khakshoor, Alireza Eslampoor¹, Saeed Shokoohi Rad, Amirhossein Vejdani²

Aims: To determine the clinical efficacy of modified deep anterior lamellar keratoplasty (DALK) for the treatment of advanced-stage keratoconus with steep curvature. **Materials and Methods:** In this interventional, non-comparative case series, 30 patients with advanced stages of keratoconus and curvature of more than 60 D underwent a modified DALK procedure. In this technique, after big-bubble formation, posterior stromal lamella was cut and removed 5 mm centrally (barring Descemet's membrane completely) with posterior stromal layer remaining peripherally. **Results:** The study included 30 eyes (30 patients with a mean \pm SD age of 25 ± 5.4 years). The follow-up examination was performed for all participants up to 12 months after the surgery. The mean uncorrected visual acuity (UCVA) increased from 20/800 before the surgery to a subsequent 3/10 ($P = 0.12$). Likewise, best spectacle corrected visual acuity (BSCVA) improved, reaching 6/10 postoperatively (former quantity 20/200) ($P = 0.18$). In addition, mean keratometry and keratometric astigmatism managed to achieve considerable improvement, from 58.8 ± 5.4 D to 46.5 ± 2.1 D and 7.8 ± 2.1 to 4.54 ± 1.54 D, respectively ($P = 0.52$). Descemet's membrane wrinkling was not seen in any patient postoperatively. **Conclusions:** This technique is effective in restoring acceptable vision and corneal regularity in advanced cases of keratoconus with a curvature more than 60 D who are also at risk of Descemet's membrane wrinkling after DALK. Therefore, this procedure could prevent from Descemet membrane wrinkling in such cases.

Key words: Keratoconus, modified deep anterior lamellar keratoplasty, steep corneal curvature

Deep anterior lamellar keratoplasty (DALK), which aims to remove and replace affected corneal stroma while preserving host healthy endothelium, eliminates the risk of endothelial graft rejection^[1] and has minimal effect on endothelial cell density.^[2] It may be possible to remove corneal sutures earlier after DALK than after penetrating keratoplasty (PKP), leading to faster visual rehabilitation.^[3,4] Additionally, compared to PKP, the DALK technique avoids most complications encountered during an open sky surgery such as anterior synechia, expulsive hemorrhage, and endophthalmitis and requires less rigid criteria for donor corneal tissue selection.^[5] However, DALK is a time-consuming and technically demanding procedure. In addition, light scattering at the host-donor interface may decrease the quality of vision.^[5] Compared with manual dissection, the injection of viscoelastic^[6] or air^[7] into the deep corneal stroma makes the separation of Descemet membrane (DM) from stroma much easier and leaves smoother and uniform host-donor interface, thereby, reducing the complications encountered with conventional lamellar keratoplasty such as interface opacity.^[7]

DALK procedure in keratoconus patients with very steep corneas sometimes induce post-operative wrinkling in DM. This wrinkling could interfere with the quality of vision, due

to the mismatch between donor and recipient corneas. In this study, we present the results of DALK using a modified technique in patients with advanced keratoconus and very steep corneal curvature.

Materials and Methods

In this interventional, non-comparative case series, patients with advanced stages of keratoconus and corneal curvature of more than 60 D who underwent the modified DALK procedure between April and December 2009 were evaluated. Informed consent was obtained from all patients and the protocol of this study was approved by the Research Ethics Committee of the university. Keratoconus was diagnosed clinically, based on slit-lamp findings (stromal thinning, Fleischer ring, Vogt striae) and keratometry, and confirmed by corneal topography. Inclusion criteria were advanced keratoconus patients with corneal curvature more than 60 D in at least one meridian with poor spectacle-corrected visual acuity, rigid gas-permeable contact lens intolerance, or inappropriate contact lens fit. Patients were excluded in case of any other pathological condition such as Fuchs' endothelial dystrophy and active vernal keratoconjunctivitis (VKC) and the presence or history of acute hydrops. In addition, the presence of cataract, retinal disorders, and glaucoma led to patient's exclusion.

Preoperatively, complete ocular examinations were performed including uncorrected visual acuity (UCVA), best spectacle corrected visual acuity (BSCVA) using the Snellen acuity chart, slit-lamp examination, tonometry, dilated funduscopy, manifest refraction (when possible), corneal topography and vitreous length measurement using A-scan biometry (A/B scan; Sonomed Inc Lake Success, NY).

Eye Research Centre, ¹Vitreo-Retinal Research Center, ²Cornea Research Centre, Khatam-Al-Anbia Hospital, Faculty of Medicine, Mashhad University of Medical Sciences, Mashhad, Iran

Correspondence to: Dr. Alireza Eslampoor, Vitreo-Retinal Research Center of Mashhad University of Medical Sciences, Khatam-Al-Anbia Eye Hospital, Abutaleb Junction, Ghareni blvd, Mashhad, Iran. E-mail: Dr.eslampoor@gmail.com, Eslampoura@mums.ac.ir

Manuscript received: 11.10.12; **Revision accepted:** 02.07.13

Access this article online

Website:
www.ijo.in

DOI:
10.4103/0301-4738.121108

Quick Response Code:



All eyes were operated by an experienced anterior segment surgeon (H.K) and a cornea fellowship (A.R.E) under general anesthesia using the big-bubble technique as described by Anwar and Teichmann.^[7] Briefly, the size of trephination was chosen according to the size of the cone and vertical corneal diameter.

After trephination to approximately 80% of corneal thickness with a Hessburg-Barron suction trephine (Katena, Denville, NJ), a 30-gauge needle, attached to a 5-cc syringe, bent at 100 degrees (bevel facing downward) was inserted into the stroma up to the center of the cornea. Air was injected gently into the mid-stroma until a big bubble was formed extending to the border of trephination. If the big bubble was not formed after the first attempt, the injection was repeated. After big-bubble formation, debulking of the anterior two-thirds of the corneal stroma was performed with a crescent blade. Afterward, a peripheral paracentesis was performed to reduce intraocular pressure; the bubble was punctured with a 15-degree slit-knife to enable escaping of the air and collapsing the bubble. Viscoelastic material (Coatel, Bausch and Lomb, Waterford, Ireland) was injected to keep DM away from manipulations. Vannas scissors were used to divide the rest of the corneal stroma into four quadrants from corneal center to near 1-2 mm from the trephined edge of cornea; each quadrant was completely excised using left and right transplantation scissors baring DM completely in central 5 mm with posterior stromal layer remaining peripherally. Bevel formation on stroma at periphery to zone 5 mm causes better adhesion donor to recipient. The viscoelastic material was then completely washed out before proceeding to graft suturing. Donor tissues suitable only for lamellar keratoplasty (based on the graft rating and endothelial cell count) were procured from Central Eye Bank of Iran. At the same time, high-quality donor tissues suitable for PKP were available as backup to be used if needed. The donor cornea was punched from the endothelial side with the Barron punch (Katena, Denville, NJ). The donor was oversized by 0.25 mm. Donor DM and endothelium was gently stripped off with a dry cellulose sponge or forceps. The donor cornea was initially fixed with 4 cardinal 10/0 nylon sutures (SharpPoint; Angiotech, Vancouver, Canada) at 3, 6, 9, and 12 o'clock. The suturing technique comprised of 16-bite interrupted, or combined (8-bite interrupted accompanied by 16-bite single running) sutures. Interrupted sutures were chosen if there was any problem such as peripheral corneal vascularization and previous history of VKC, which could lead to suture complications (vascularized or loose sutures).

Combined and single running sutures were left for eyes without any problems leading to suture complications. With all suturing techniques, it was attempted to encompass about 90% of thickness of the recipient and donor tissues. Intraoperative keratometry was performed to adjust suture tension. At the end of the operation, cefazolin 100 mg and betamethasone 4 mg were injected subconjunctivally.

The patients were medicated with topical Chloramphenicol every 6 hours for 30 days and topical betamethasone 0.1% every 6 hours tapered over 2-3 months. If indicated, topical sodium chloride 5% was prescribed to reduce graft edema and topical lubricants were administered to treat filamentary keratitis and hasten epithelial healing. Follow-up examinations were scheduled 1, 3, 7, 30 days and 3, 6, and 12 months,

postoperatively, and at least, 3 months after complete suture removal and every 6 months thereafter.

Postoperatively, UCVA, BSCVA, manifest refraction, and keratometric astigmatism, as well as intra- and postoperative complications or secondary interventions (e.g. resuturing) were recorded. On condition that more than one procedure was required (e.g. resuturing and graft refractive surgery), the final results were considered.

Data analysis was performed using Statistical Package for Social Sciences (SPSS) statistical software (version 15, SPSS, Inc, Chicago, Illinois, USA). Paired *t*-test was used to compare pre- and postoperative astigmatism and BSCVA measurements. The Chi-square test was used for comparison of qualitative parameters. $P < 0.05$ was considered statistically significant.

Results

A total of 12 (40%) eyes were male and 18 (60%) of cases were female. At the time of surgery, the mean \pm SD age of the study population was 25.45 ± 5.4 years, ranging from 19 years to 36 years. The mean follow-up examination period was 6 ± 2 months.

Mean preoperative UCVA was recorded as 20/800. Mean preoperative BSCVA increased from 1.27 ± 0.4 (0 to 2.10) logMAR (equivalent to 20/400), to 0.25 ± 0.2 (range 0-1.4) logMAR (equivalent to 20/32) at final follow-up visit ($P = 0.001$).

In 23 eyes, for which the corneal curvature was measurable, mean preoperative keratometry was between 44.25 D and 71.5 D (mean 55.66 ± 5.3 D). This value was decreased to 47.0 ± 2.2 D (range 42.25 to 55.5 D), postoperatively ($P = 0.001$). Postoperative refraction and keratometric astigmatisms were 3.04 ± 2.3 , and 3.67 ± 2.1 D, respectively.

A bared DM was successfully achieved in 25 (83.2%) of cases, whereas in five (16.8%) eyes, it was necessary to perform layer-by-layer manual stromal dissection due to the lack of big-bubble formation after several attempts. During the first 2 weeks after operation, corneal surface problems such as delayed epithelial healing, superficial punctate keratitis (SPK), and filamentary keratitis (FK) were relatively common.

Discussion

Keratoconus is the most common indication for PKP in many countries.^[8-10] Patients with keratoconus are young adults in their 3rd-5th decades of life and need good visual acuity lifelong. Although some studies^[11-14] indicated that the visual outcomes after DALK are comparable with those after PKP, several other studies have documented that it is inferior compared to PKP in terms of BSCVA measurements.^[3,4,15] This difference can be attributed to the irregularity at the host-donor interface, limiting vision after lamellar keratoplasty.^[16]

Postoperative BSCVA of 20/40 or better was achieved in 77.8% of patients in the present study, which is fairly comparable to the results of other studies reporting a range between 80% and 92.3%.^[17] Furthermore, the severity of keratoconus did not have any negative impact on visual outcomes including BSCVA, spherical equivalent refractive error and keratometric astigmatism. This supports the idea that this type of transplantation is equally effective for

advanced keratoconus. Authors believe that in modified DALK procedure peripheral stromal scaffold from recipient and lower surface of bared DM significantly decreases DM fold formation and wrinkling especially in advanced cases of keratoconus (>60 D) [Figs. 1 and 2].

In the current study, the big-bubble was successfully formed in 25 (83.2%) of cases, resembling the success rate of 80% to 90% reported by Anwar and Teichmann^[7] in a large series of 181 cases with keratoconus. In this regard, our result is better than those reported by Fogla *et al.*,^[15] and Fontana *et al.*,^[16] (69.2% and 64%, respectively). In addition, the rate of DM perforation and intraoperative conversion to PKP in the current study was 6.6% and 3.3% (excluded from study), respectively. Several published studies reported various rates of DM perforation and conversion to PKP, ranging from 4% to 39.2% and from 0% to 14%, respectively.^[4,13,15,18-21] Such variation may reflect different indications for keratoplasty or different surgical techniques in study groups. Additionally, the steep learning curve of the surgical technique can explain the difference in the success rate of big-bubble formation in different studies, as the majority of failed air injections were among patients operated at the beginning of the study. Interface scarring and irregularities are among the causes leading to poorer visual results in lamellar keratoplasty as compared to PKP. Should the interface between host and donor be smooth and the corneal stroma be removed down to the DM, the optical quality of the interface is excellent.

Comparing the eyes with keratoconus which underwent DALK using Melles technique with those experienced PKP, Ardjomna *et al.*,^[17] found that the visual acuity of the DALK group was similar to the PKP group only when the recipient corneal bed thickness was less than 20 μm , whereas the BSCVA of the DALK group decreased significantly with increasing thickness of recipient stroma. In contrast, we did not find any significant difference between the bared DM and pre-Descemet groups in terms of visual outcomes and refractive status, which can be attributed to the small number of participants in the pre-Descemet group in relation to the bared DM group (5 vs. 25). Furthermore, the thickness of the recipient bed left in the pre-Descemet group was not measured in this study, making it difficult to compare our results with those of Ardjomand *et al.*^[17] It should be noted that filamentary keratitis

was the most common complication (13.3%) encountered in this study.

Certain complications such as persistent epithelial defects and filamentary keratitis are more likely to develop as a result of low-quality donor tissue unsuitable for PKP. The deleterious effect of poor quality grafts on epithelial healing has already been demonstrated.^[18] Van Meter *et al.*,^[18] evaluated the effect of death-to-preservation time on donor corneal epithelium and found that increased death to preservation interval, hence poor donor tissue quality, increases the incidence of corneal epithelial defects on the first postoperative day, which can adversely affect the survival of the graft. They concluded that the presence of donor epithelial defects on day 1 can lead to postoperative complications such as subepithelial scarring or infectious keratitis. Also, studies by Chou *et al.*,^[22] and Kim *et al.*,^[19] demonstrated that longer storage and longer death-to-preservation time are associated with epithelial defects after keratoplasty. Therefore, it may be advisable to use good donor quality grafts for DALK and to avoid damage to the corneal epithelium during the preparation of the donor tissue. Atonic pupil developed in 2 eyes after the injection of the air bubble into the anterior chamber to seal DM perforation which may occur during the operation. We believe that an attack of pupillary block glaucoma, which also resolved on its own, occurred immediately after the operation due to overfilling the anterior chamber with air. Given that, less than half of the anterior chamber should be filled with the air bubble at the end of the operation to eliminate the risk of pupillary block glaucoma and its complications. In the current study, three (10%) eyes required graft refractive surgery due to high post-DALK astigmatism. Astigmatism of greater than 4D after DALK has been reported between 16% and 24.6%.^[21,23] Despite that some techniques, including Ruiz procedure and arcuate keratotomy, have been reported to reduce post-DALK astigmatism,^[24] we found relaxing incisions combined with adjustment sutures at the steep meridians a reliable and effective method for post-DALK astigmatism in these eyes. Although DALK eliminates the risk of endothelial rejection, other types of graft rejection (subepithelial and stromal) may still develop. The clinical picture of subepithelial and stromal graft rejection

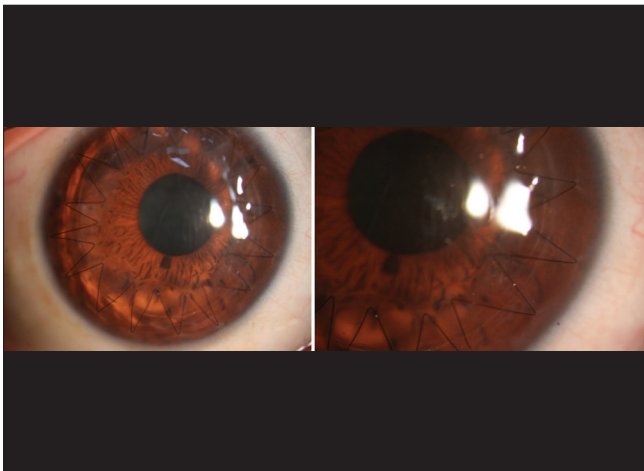


Figure 1: DALK in a patient with steep curvature showing postoperative Descemet's membrane wrinkling and folding

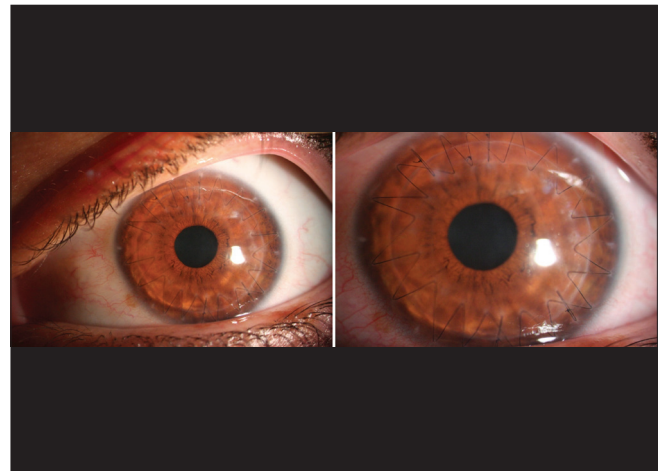

Figure 2: Modified DALK in a patient with steep curvature showing no evidence of postoperative Descemet's membrane wrinkling and folding

after DALK is very similar to that following PKP. In contrast to previous studies, such as the study conducted by Javadi and colleagues,^[25] reporting the rate of immunologic rejection of 3-8% after DALK, we observed a higher rate (13.3%) in our study population. Frequent topical corticosteroids led to reversal of rejection in all cases and all subjects regained the level of visual acuity prior to the rejection episode. This higher rate of graft rejection in our series can be explained by the presence of risk factors for which the surgeon was inclined to choose DALK; this is supported by the fact that the majority of rejection episodes occurred in the eyes with previous history of VKC.

Another interesting point is the good final visual function in two eyes that sustained blunt trauma 47 and 55 days after surgery leading to wound dehiscence. We believe that these eyes would have suffered severe damage, if PKP had been performed because globe integrity does not reach the normal value even years after PKP.^[25] This observation highlights another advantage of DALK over PKP, which is globe integrity preservation and more structural resistance against blunt trauma.

In the current study, PKP was performed in one (3.3%) case (excluded from study population). As the postoperative results indicate, performing lamellar dissection did not pose any challenge to the surgical technique or postoperative course of these eyes, which had a mean postoperative BSCVA better than 20/30. In conclusion, DALK is an appropriate alternative to PKP in eyes with moderate to advanced keratoconus, especially those with history of VKC. It eliminates the risk of endothelial graft rejection, preserves globe integrity, and provides acceptable visual function.

Acknowledgments

The authors would like to thank Dr. Asieh Ehsaei, Phd in Optometry and Vision Sciences, for her help in editing this manuscript. The authors have no financial interests in any materials or devices mentioned in this article to disclose.

References

- Shimmura S, Tsubota K. Deep anterior lamellar keratoplasty. *Curr Opin Ophthalmol* 2006;17:349-55.
- Anwar M, Teichmann KD. Deep lamellar keratoplasty: Surgical techniques for anterior lamellar keratoplasty with and without baring of Descemet's membrane. *Cornea* 2002;21:374-83.
- Archila EA. Deep lamellar keratoplasty dissection of host tissue with intrastromal air injection. *Cornea* 1984;3:217-8.
- Benson WH, Goosey CB, Prager TC, Goosey JD. Visual improvement as a function of time after lamellar keratoplasty for keratoconus. *Am J Ophthalmol* 1993;116:207-11.
- Richard JM, Paton D, Gasset AR. A comparison of penetrating keratoplasty and lamellar keratoplasty in the surgical management of keratoconus. *Am J Ophthalmol* 1978;86:807-11.
- Manche EE, Holland GN, Maloney RK. Deep lamellar keratoplasty using viscoelastic dissection. *Arch Ophthalmol* 1999;117:1561-5.
- Anwar M, Teichmann KD. Big-bubble technique to bare Descemet's membrane in anterior lamellar keratoplasty. *J Cataract Refract Surg* 2002;28:398-403.
- Kanavi MR, Javadi MA, Sanagoo M. Indications for penetrating keratoplasty in Iran. *Cornea* 2007;26:561-3.
- Terry MA. The evolution of lamellar grafting techniques over twenty-five years. *Cornea* 2000;19:611-6.
- Watson SL, Ramsay A, Dart JK, Bunce C, Craig E. Comparison of deep lamellar keratoplasty and penetrating keratoplasty in patients with keratoconus. *Ophthalmology* 2004;111:1676-82.
- Coombes AG, Kirwan JF, Rostron CK. Deep lamellar keratoplasty with lyophilised tissue in the management of keratoconus. *Br J Ophthalmol* 2001;85:788-91.
- Funnell CL, Ball J, Noble BA. Comparative cohort study of the outcomes of deep lamellar keratoplasty and penetrating keratoplasty for keratoconus. *Eye (Lond)* 2006;20:527-32.
- Saini JS, Jain AK, Sukhija J, Saroha V. Indications and outcome of optical partial thickness lamellar keratoplasty. *Cornea* 2003;22:111-3.
- Sugita J, Kondo J. Deep lamellar keratoplasty with complete removal of pathological stroma for vision improvement. *Br J Ophthalmol* 1997;81:184-8.
- Fogla R, Padmanabhan P. Results of deep lamellar keratoplasty using the big-bubble technique in patients with keratoconus. *Am J Ophthalmol* 2006;141:254-9.
- Fontana L, Parente G, Tassinari G. Clinical outcomes after deep anterior lamellar keratoplasty using the big-bubble technique in patients with keratoconus. *Am J Ophthalmol* 2007;143:117-24.
- Ardjomand N, Hau S, McAlister JC, Bunce C, Galaretta D, Tuft SJ, *et al.* Quality of vision and graft thickness in deep anterior lamellar and penetrating corneal allografts. *Am J Ophthalmol* 2007;143:228-35.
- Van Meter WS, Katz DG, White H, Gayheart R. Effect of death-to-preservation time on donor corneal epithelium. *Trans Am Ophthalmol Soc* 2005;103:209-22.
- Kim T, Palay DA, Lynn M. Donor factors associated with epithelial defects after penetrating keratoplasty. *Cornea* 1996;15:451-6.
- Al-Torbak AA, Al-Motowa S, Al-Assiri A, Al-Kharashi S, Al-Shahwan S, Al-Mezaine H, *et al.* Deep anterior lamellar keratoplasty for keratoconus. *Cornea* 2006;25:408-12.
- Watson SL, Tuft SJ, Dart JK. Patterns of rejection after deep lamellar keratoplasty. *Ophthalmology* 2006;113:556-60.
- Chou L, Cohen EJ, Laibson PR, Rapuano CJ. Factors associated with epithelial defects after penetrating keratoplasty. *Ophthalmic Surg* 1994;25:700-3.
- Karimian F, Feizi S. Deep anterior lamellar keratoplasty: Indications, surgical techniques and complications. *Middle East Afr J Ophthalmol* 2010;17:28-37.
- Kubaloglu A, Coskun E, Sari ES, Gunes AS, Cinar Y, Pinero DP, *et al.* Comparison of astigmatic keratotomy results in deep anterior lamellar keratoplasty and penetrating keratoplasty in keratoconus. *Am J Ophthalmol* 2011;151:637-43.
- Javadi MA, Feizi S, Jamali H, Mirbabaee F. Deep anterior lamellar keratoplasty using the big-bubble technique in keratoconus. *J Ophthalmic Vis Res* 2009;4:8-13.

Cite this article as: Khakshoor H, Eslampoor A, Rad SS, Vejdani A. Modified deep anterior lamellar keratoplasty for the treatment of advanced keratoconus with steep corneal curvature to help in eliminating the wrinkles in the Descemet's membrane. *Indian J Ophthalmol* 2014;62:392-5.

Source of Support: Nil. **Conflict of Interest:** None declared.