

Multiparametric magnetic resonance imaging-transrectal ultrasound fusion prostate biopsy: A prospective, single centre study

Somendra Bansal, Narmada P. Gupta*, Rajiv Yadav, Rakesh Khara, Kulbir Ahlawat¹, Dheeraj Gautam², Rajesh Ahlawat³, Gagan Gautam⁴

Department of Urology, Kidney and Urology Institute, Medanta - The Medicity, ¹Division of Radiology and Nuclear Medicine, Medanta - The Medicity, ²Department of Pathology and Laboratory Medicine, Medanta - The Medicity, Gurgaon, ³Department of Urology and Renal Transplant, Fortis Escorts Heart Institute and Research Centre, ⁴Department of Uro-oncology, Max Institute of Cancer Care, New Delhi, India
*E-mail: narmadagupta@gmail.com

ABSTRACT

Introduction: Transrectal ultrasound (TRUS)-guided systematic biopsy is the gold standard for diagnosis of prostate cancer. However, systematic biopsy has high false-negative rate and often misses anteriorly located tumors. Magnetic resonance imaging (MRI)-TRUS fusion biopsy can potentially improve cancer detection by better visualization and targeting of cancer focus. We evaluated the role of fusion biopsy in detection of prostate cancer and the association of prostate imaging reporting and data system (PI-RADS) score for predicting cancer risk and its aggression.

Methods: Ninety-six consecutive men with suspected prostate cancer underwent MRI-TRUS fusion-targeted biopsy of suspicious lesions and standard 12 core biopsy from May 2014 to July 2015 in our institution. All patients underwent 3.0 T multiparametric MRI before biopsy. mp-MRI included T2W, DWI, DCE and MRS sequences to identify lesions suspicious for prostate cancer. Suspected lesions were scored according to PI-RADS scoring system. Comparison of cancer detection between standard 12 core biopsy and MRI-TRUS fusion biopsy was done. Detection of prostate cancer was primary end point of this study.

Results: Mean age was 64.4 years and median prostate-specific antigen was 8.6 ng/ml. Prostate cancer was detected in 57 patients (59.3%). Of these 57 patients, 8 patients (14%) were detected by standard 12 core biopsy only, 7 patients (12.3%) with MRI-TRUS fusion biopsy only, and 42 patients (73.7%) by both techniques. Of the 7 patients, detected with MRI-TRUS fusion biopsy alone, 6 patients (85.7%) had Gleason ≥ 7 disease. Prostate cancer was detected on either standard 12 core biopsy or MRI-TRUS fusion biopsy in 0%, 42.8%, 74%, and 89.3% patients of suspicious lesions of highest PI-RADS score 2, 3, 4, and 5, respectively.

Conclusions: MRI-TRUS fusion prostate biopsy improves cancer detection rate when combined with standard 12 cores biopsy and detects more intermediate or high-grade prostate cancer (Gleason ≥ 7). With increasing PI-RADS score, there is an increase chance of detection of cancer as well as its aggressiveness.

INTRODUCTION

Prostate cancer is the most common cancer (27%) and the second most common cause of cancer-related death (10%) in men in the United States.^[1] In India,

it is one of the five leading cancers among males in most registries.^[2] Transrectal ultrasound (TRUS)-guided prostate biopsy is the standard approach to diagnose prostate cancer as it is quick, widely available, office-based, real time in nature, and relatively less expensive. However, it has some

Access this article online	
Quick Response Code:	Website: www.indianjurol.com
	DOI: 10.4103/0970-1591.203414

This is an open access article distributed under the terms of the Creative Commons Attribution-NonCommercial-ShareAlike 3.0 License, which allows others to remix, tweak, and build upon the work non-commercially, as long as the author is credited and the new creations are licensed under the identical terms.

For reprints contact: reprints@medknow.com

Received: 21.01.2016, **Accepted:** 19.07.2016

Financial support and sponsorship: Nil.

Conflicts of interest: There are no conflicts of interest.

limitations such as low diagnostic yield, sampling error, and the propensity to miss anterior lesions.^[3,4]

TRUS is also not reliable for assessing tumor volume, extent, and aggressiveness. Up to 40% of prostate cancer detected by TRUS-guided biopsy may be upgraded to a higher Gleason score on final surgical histopathology. Thus, patients with the most clinically significant prostate cancer may not be accurately stratified by this technique.^[5,6]

Magnetic resonance imaging (MRI) is used as an alternative to TRUS to improve cancer detection. It has emerged as the imaging modality of choice for diagnosis of prostate cancer.^[7] MRI provides increased resolution with best depiction of prostate contours and its internal zonal anatomy and extraprostatic extension of tumor. Multiparametric MRI (mp-MRI) allows functional assessment and tumor grading.^[8] The established parameters of mp-MRI are T2-weighted images (T2WI), diffusion-weighted imaging (DWI), dynamic contrast-enhancement (DCE), and MR spectroscopy (MRS).^[7,8]

The European Society of Urogenital Radiology (ESUR) has proposed the prostate imaging reporting and data system (PI-RADS) in 2012 for the detection of prostate cancer using mp-MRI. In this PI-RADS scoring system, each parameter T2WI, DWI, DCE-MRI, and MRS is scored on a five-point scale. PI-RADS score predicts the probability of cancer risk and its aggressiveness.^[9]

MRI suspicious lesions can be targeted by different methods such as cognitive guidance (MRI suggested), MRI-guided biopsy (in gantry), and MRI-ultrasound fusion systems.^[7]

Real-time MRI-guided prostatic biopsy of tumor suspicious regions is an accurate method to detect prostatic carcinoma, but it is time consuming, cumbersome, costly, and impractical because the entire procedure is conducted in the MRI gantry.^[3,10] To resolve these issues, MRI-TRUS fusion systems have been developed to fuse previously acquired MRI images with real-time TRUS image. This system combines the benefits of both MRI and TRUS in a single technique without the requirement of MRI suite during biopsy.^[3,11-13] Fusion biopsy allows targeting the MRI suspicious lesion with decreased sampling error.

The aim of this study was to evaluate the role of MRI-TRUS fusion biopsy in the detection of prostate cancer by comparing the yield of standard 12-core biopsy and MRI-TRUS fusion biopsy and to find the association of PI-RADS scoring of MRI suspicious lesions with the histopathology report.

METHODS

In this single-center, prospective study, 96 patients underwent MRI-TRUS fusion as well as standard 12

core biopsy. Indications for biopsy were prostate-specific antigen (PSA) >4 ng/ml and/or abnormality on digital rectal examination (DRE). Patients with recent urinary tract infection, bleeding disorders, rectal pathology, or PI-RADS score 1 were excluded from the study. Informed consent was taken from all patients.

All patients first underwent 3.0 T mp-MRI using body coils (phased array coils) in Siemens Verio MRI machine. mp-MRI included T2W, DWI, DCE, and MRS sequences to identify lesions suspicious for prostate cancer. Suspected lesions were scored according to PI-RADS scoring system (ESUR guideline 2012) and marked by three radiologists with experience in interpretation of prostate MRI. ProFuse software version 3.0.0.116 (California, USA) was used for PI-RADS scoring and marking the suspicious lesions.

Office-based prostate biopsy was done in the left lateral decubitus position after intrarectal 2% lignocaine jelly and periprostatic block using 2% lignocaine.

First, a prostate scan was done to create three-dimensional (3D) reconstruction image of prostate. This was followed by fusion of previously acquired MRI images (loaded in a disc) onto real-time TRUS images, using advanced 3D semi-robotic targeted prostate biopsy software (ei-Nav Artemis machine version 2.1.3.5 (California, USA)).

All patients first underwent MRI-TRUS fusion-targeted biopsy followed by standard 12 core biopsy in the same sitting by same urologist. Two cores were taken from each MRI suspicious lesion. All biopsy cores were labeled and sent separately for histopathological examination. This study was approved by the Institutional Review Board and Institutional Ethics Committee of our institute.

Statistical analysis

Quantitative data were presented in terms of means and standard deviation, and qualitative/categorical data were presented as absolute numbers and proportions. Cross tabulation was generated, and Chi-square test was used for testing of association and standard normal deviate test for proportions. Independent Student's *t*-test was used for comparison of cancer length between standard 12-cores and MRI-TRUS fusion biopsy cores. $P < 0.05$ was considered statistically significant. SPSS software, version 24 (Bengaluru, Karnataka, India) was used for analysis. The sample size is 96 for desired confidence level of 95% and power of 80%.

RESULTS

Mean age of the 96 patients was 64.4 (range 43–79) years, median PSA was 8.6 (range 4–140) ng/ml, and median prostate volume was 41 (range 20–120) cc. Patients' characteristics are provided in Table 1.

Patient-wise analysis

Prostate cancer was detected in 57 patients (59.3%). Of these 57 patients, 8 patients (14%) were detected by standard 12 core biopsy only, 7 patients (12.3%) with MRI-TRUS fusion biopsy only, and 42 patients (73.7%) by both techniques [Table 2]. 44 patients (77.2%) had Gleason score ≥ 7 . Of these 44 patients, 13.6% (6 of 44) patients were detected only by MRI-TRUS fusion biopsy, 4.6% (2 of 44) patients were detected only by standard 12 core biopsy, and 81.8% (36 of 44) patients were detected by both modalities. Of the 7 patients who had only MRI-TRUS fusion biopsy positive, 6 patients had cancer in anterior and/or apex of prostate.

Core-wise analysis

Total 352 cores in MRI-TRUS fusion biopsy and 1152 cores in standard 12 core biopsy were taken. MRI-TRUS fusion biopsy detected significantly more cancerous cores as compared to standard 12 core biopsy (44.3% vs. 16.2%, $P < 0.0001$). Out of the positive cores, Gleason ≥ 7 was present in 71.2% and 60.2% cores in MRI-TRUS fusion and standard 12 core biopsy, respectively ($P = 0.033$). Mean cancer core length was 5.3 ± 3.1 mm for MRI-TRUS fusion biopsy and 3.8 ± 2.9 mm for standard 12 core biopsy ($P < 0.0001$) [Table 3].

Table 1: Patients' characteristics

Clinical and radiological Characteristics	Mean(Range)/Median(IQR)/n(%)
Number of patients (n)	96
Mean age \pm SD (range), years	64.4 \pm 7.5 (43-79)
Family history of prostate cancer (%)	8 (8.3)
Abnormal DRE (%)	24 (25)
History of the previous negative prostate biopsy (%)	21 (21.8)
Median serum PSA (ng/ml)	8.6 (IQR* 6.3-12.5)
Median prostate volume (cc)	41 (IQR* 30.4-55.0)
Total number of MRI suspicious lesions	176
Mean number of MRI suspicious lesions per patient (range)	1.8 (1-4)
Average maximum diameter of largest MRI suspicious lesion \pm SD (range), mm	15.2 \pm 6.6 (6-42)

*Interquartile range. DRE=Digital rectal examination, PSA=Prostate-specific antigen, MRI=Magnetic resonance imaging, SD=Standard deviation

Table 2: Comparison of standard 12 core biopsy and magnetic resonance imaging-transrectal ultrasound fusion prostate biopsy (patient-wise analysis)

MRI-TRUS fusion-targeted biopsy	Standard 12 core biopsy		Group total
	Positive for cancer	Negative for cancer	
Positive for cancer	42	7	49
Negative for cancer	8	39	47
Overall total	50	46	96

Kappa statistics=0.687 (agreement between two methods is 68.7%), 95% CI (0.542-0.833). CI=Confidence interval, MRI=Magnetic resonance imaging, TRUS=Transrectal ultrasound

In patients who had cancer detected only by MRI-TRUS fusion biopsy, 68.4% (13 of 19) cores had Gleason ≥ 7 and 31.6% (6 of 19) cores had Gleason < 7 . In patients who had cancer detected only by standard 12 cores biopsy, 21% (4 of 19) cores had Gleason ≥ 7 and 79% (15 of 19) cores had Gleason < 7 .

Subgroup analysis

History of previous negative transrectal rectal ultrasound biopsy

Of the 21 patients with history of previous negative TRUS biopsy, 14 patients (66.7%) had prostate cancer. Of these 14 patients, 11 patients (78.6%) were detected by both MRI-TRUS fusion biopsy and standard 12 core biopsy and rest 3 patients (21.4%) were detected only by MRI-TRUS fusion biopsy. 8 patients had suspicious lesions in the anterior and/or apex of prostate. Of these 8 patients, prostate cancer was detected in 7 patients [Table 4].

Abnormal digital rectal exam

Of the 24 patients with abnormal DRE, 19 patients (79.2%) had prostate cancer detected, 18 patients were detected by both MRI-TRUS fusion biopsy and standard 12 core biopsy and one patient was detected only by MRI-TRUS fusion biopsy. Hence, MRI-TRUS fusion biopsy did not improve detection rate in patients with positive DRE [Table 4].

Prostate-specific antigen

Prostate cancer was detected in 51.6%, 72.7%, and 80% of patients in PSA range of < 10 , 10–20, and > 20 ng/ml. In the PSA < 10 group, 7 patients were detected only by MRI-TRUS fusion biopsy and 4 patients were detected only by standard 12 core biopsy. In patients with PSA ≥ 10 ng/ml, MRI-TRUS fusion biopsy did not detect any additional patients with cancer over and above the standard 12 core biopsy [Table 4].

Prostate volume

Of the 7 patients with only MRI-TRUS fusion biopsy positive, 5 patients had prostate volume 40–70cc. No improved detection of disease by MRI-TRUS fusion biopsy alone seen in prostate volume > 70 cc [Table 4].

Association of prostate imaging reporting and data system scores with detection of prostate cancer

Totally, 176 MRI suspicious lesions were identified in 96 patients. On average, 1.8 suspicious lesions per patient (range 1–4) were identified. Average maximum diameter of largest MRI suspicious lesion in a particular patient was 15.2 mm (6–42 mm).

Patient-wise analysis

Lesions with highest PI-RADS score of 2, 3, 4, and 5 were present in 13, 28, 27, and 28 patients, respectively. Prostate cancer was detected on either standard 12 core biopsy or MRI-TRUS fusion biopsy in 0%, 42.8%, 74%, and 89.3% patients of suspicious lesions of highest PI-RADS score 2, 3,

4, and 5, respectively. Gleason score >7 prostate cancer was present in 58%, 75%, and 88% of cancer positive patients of lesions with highest PI-RADS score 3, 4, and 5, respectively [Chi-square test; Table 5] 13 patients had only PI-RADS 2 suspicious lesions on MRI. Of these 13 patients, one patient had focal atypia and rest 12 patients had benign pathology.

Magnetic resonance imaging suspicious lesions-wise analysis
Prostate cancer was detected in 80 of 176 MRI suspicious lesions [Figure 1]. Prostate cancer was detected in 0%, 35.6%, 68.4%, and 87.5% of suspicious lesions of PI-RADS

Table 3: Comparison of magnetic resonance imaging-transrectal ultrasound fusion biopsy and standard 12 core biopsy (core-wise analysis)

Variable	MRI-TRUS fusion biopsy (%)	Standard 12 core biopsy (%)	P
Total cores	352	1152	
Cancer cores	156/352 (44.3)	186/1152 (16.2)	<0.0001
Gleason \geq 7	111/156 (71.2)	112/186 (60.2)	0.033
Gleason <7	45/156 (28.9)	74/186 (39.8)	0.033
Mean cancer core length \pm SD (mm)	5.3 \pm 3.1	3.8 \pm 2.9	<0.0001

SD=Standard deviation, MRI=Magnetic resonance imaging, TRUS=Transrectal ultrasound

Table 4: Comparison of magnetic resonance imaging-transrectal ultrasound fusion biopsy and standard 12 core biopsy in subgroups

Subgroup	MRI-TRUS fusion biopsy (n=96)	Standard 12 core biopsy (n=96)	P
Previous negative TRUS			
Yes (n=21)	14 (11+3*)	11 (11+0*)	0.345
No (n=75)	35 (31+4*)	39 (31+8*)	0.513
Abnormal DRE			
Yes (n=24)	19 (18+1*)	18 (18+0*)	0.732
No (n=72)	30 (24+6*)	32 (24+8*)	0.716
PSA			
4<10 (n=64)	29 (22+7*)	26 (22+4*)	0.593
10-20 (n=22)	12 (12+0*)	16 (12+4*)	0.210
>20 (n=10)	8 (8+0*)	8 (8+0*)	
Prostate volume			
<40 (n=46)	26 (24+2*)	30 (24+6*)	0.393
40-70 (n=35)	17 (12+5*)	14 (12+2*)	0.470
>70 (n=15)	6 (6+0*)	6 (6+0*)	

*Value depicts cancer detected only by the particular modality. TRUS=Transrectal ultrasound, DRE=Digital rectal examination, PSA=Prostate-specific antigen, MRI=Magnetic resonance imaging

Table 5: Association of prostate imaging reporting and data system scores with prostate cancer detection and Gleason score (patient-wise analysis)

Highest PI-RADS score (n=96 patients)	Prostate cancer, n=57 (%)	Gleason \geq 7, n=44 (%)	Gleason <7, n=13 (%)
2 (n=13)	0	0	0
3 (n=28)	12/28 (42.8)	7/12 (58.3)	5/12 (41.7)
4 (n=27)	20/27 (74)	15/20 (75)	5/20 (25)
5 (n=28)	25/28 (89.3)	22/25 (88)	3/25 (12)

For prostate cancer, $\chi^2=35$ (P=0.000); For Gleason score, $\chi^2=4.14$ (P=0.126). PI-RADS=Prostate imaging reporting and data system

score 2, 3, 4, and 5, respectively. Gleason score >7 prostate cancer was present in 42.3%, 76.9%, and 92.8% of cancer positive lesions with PI-RADS score 3, 4, and 5, respectively [Table 6].

One patient had postprocedural fever for which rehospitalization was done and managed conservatively.

DISCUSSION

To the best of our knowledge, this study is the first of its kind in Indian men and represents a cohort different from the Western populations. The current studies pertaining to MRI-TRUS fusion biopsy are all derived from Western populations. The demographic and characteristics of disease are different in India. Batra *et al.*,^[14] showed that the majority of Indian patients had higher stage prostate disease (93% patients had intermediate and high-risk D' Amico category prostate cancer).

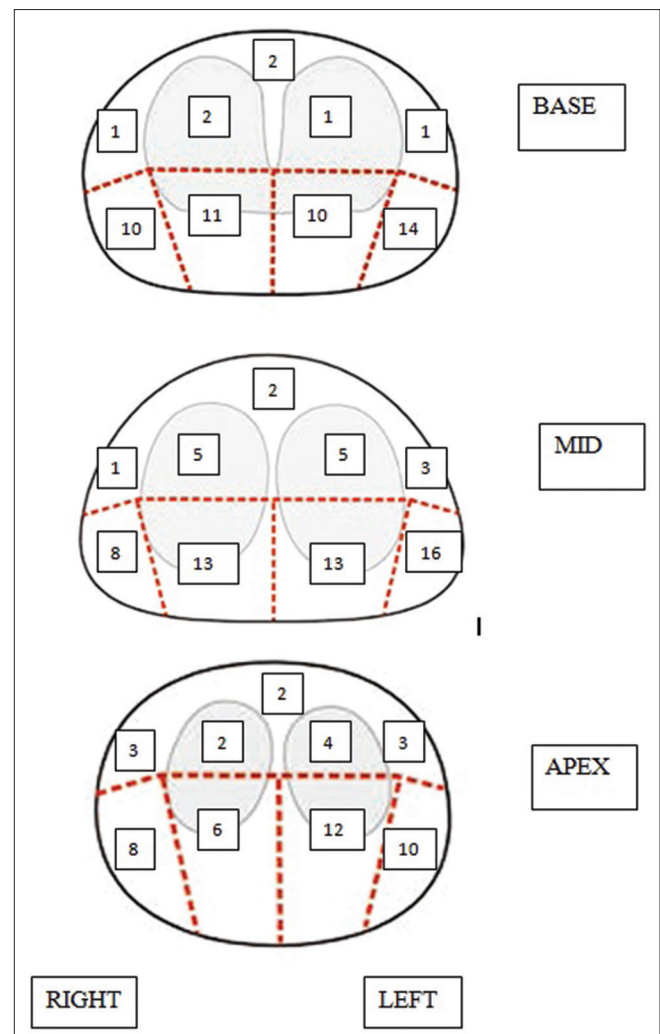


Figure 1: Twenty-seven regions prostate magnetic resonance imaging reporting scheme. Locations of eighty cancer positive magnetic resonance imaging suspicious lesions in 168 regions (one cancer positive magnetic resonance imaging suspicious lesions can be located in one or multiple regions)

Table 6: Association of prostate imaging reporting and data system scores with prostate cancer detection and Gleason score (magnetic resonance imaging suspicious lesions-wise analysis)

PI-RADS scores (n=176)*	Prostate cancer, n=80 (%)	Gleason \geq 7, n=57 (%)	Gleason <7, n=23 (%)
2 (n=33)	0	0	0
3 (n=73)	26/73 (35.6)	11/26 (42.3)	15/26 (57.7)
4 (n=38)	26/38 (68.4)	20/26 (76.9)	6/26 (23.1)
5 (n=32)	28/32 (87.5)	26/28 (92.8)	2/28 (7.1)

*Total number of MRI suspicious lesions or ROI (n)=176; For prostate cancer, $\chi^2=61.25$ ($P<0.001$); For Gleason score, $\chi^2=15.8$ ($P=0.000$). MRI: Magnetic resonance imaging, ROI: Region of interest, PI-RADS=Prostate imaging reporting and data system

In this study, 96 patients underwent MRI-TRUS fusion biopsy followed by standard 12-core biopsy. Prostate cancer was detected in 57 patients (59.4%) using both MRI-TRUS fusion biopsy and standard 12 core biopsy. MRI-TRUS fusion biopsy detected cancer in 51% (49 of 96) patients, and standard 12 core biopsy detected cancer in 52% (50 of 96) patients and agreement between two methods was 68.7%. Similar, findings were noted by Siddiqui *et al.*^[15]

In our study, high-grade cancer was defined as Gleason \geq 7. Combining MRI or MRI-TRUS fusion biopsy with standard 12 core biopsy increases detection of prostate cancer as well as improves detection of high grade or clinically significant cancer.^[15-18] 7 additional patients were detected with MRI-TRUS fusion biopsy alone and of these 7 patients, 6 patients had Gleason \geq 7 disease. Limiting prostate biopsy to only MRI-targeted biopsy protocol misses some clinically significant cancer. It may be due to the presence of several significant cancers outside MRI suspicious lesions.^[12,19] In our patients also, 8 patients were detected only by standard 12 core biopsy and not by MRI-TRUS fusion biopsy, of which 2 patients had high-grade cancer.

Conventional TRUS biopsy often misses cancer in apical and anterior part of prostate.^[3,4] MRI-TRUS fusion biopsy is the most useful in targeting suspicious lesions of anterior prostate and is ideally suited for patients with history of previous negative TRUS biopsy and persistently elevated PSA.^[20,21] In our patients, additional detection of prostate cancer by MRI-TRUS fusion biopsy alone was seen mainly in anterior and apical portion of prostate. Of the 21 patients with previous negative TRUS biopsy, 7 patients (33.3%) had cancer positive MRI suspicious lesion in the anterior part of prostate. In other studies, 47–57% tumor was found in anterior prostate in patient who underwent MRI-targeted biopsy after previous negative TRUS.^[3,10,22]

Roethke *et al.*^[23] evaluated the ESUR PI-RADS scoring system for detection of prostate cancer by 3.0 T mp-MRI and concluded that PI-RADS score was useful prognostic tool for prostate cancer risk stratification, and it improved detection

of clinically significant cancer. PI-RADS score had clear association with cancer incidence and its aggressiveness.^[17,24]

In our study too, prostate cancer was detected on either standard 12 core biopsy or MRI-TRUS fusion biopsy in 0%, 42.8%, 74%, and 89.3% patients of suspicious lesions of highest PI-RADS score 2, 3, 4 and 5, respectively. Gleason score $>$ 7 prostate cancer was present in 58.3%, 75%, and 88% of cancer positive patients of lesions with highest PI-RADS score 3, 4, and 5, respectively. It indicates that as PI-RADS score increases, there is an increase in chances of detection of intermediate or high-grade cancer.

In patients with abnormal DRE, PSA $>$ 10 ng/ml or prostate volume $>$ 70 cc, we were unable to detect any additional patients of prostate cancer by adding MRI-TRUS fusion biopsy to the standard 12 core biopsy. Hence, in these patients, the additional expense of this procedure may not be justified. Hambroek *et al.*^[10] also found no difference in cancer detection rate between MRI-guided biopsy and TRUS-guided biopsy in patients with PSA $>$ 20 ng/ml and prostate volume $>$ 65 cc.

Our study is limited by the small number of patients in subgroups analysis. The accuracy of MRI-TRUS fusion biopsy could not be determined without comparing with the gold standard of radical prostatectomy specimen. We did not have follow-up of patients with negative prostate biopsy.

Cost-effectiveness analyses of MRI-TRUS fusion prostate biopsy are needed, especially in our cohort, where majority of patients had higher grade prostate cancer and majority of patients were detected by both MRI-TRUS fusion biopsy and standard 12 core biopsy.

However, we do believe that this study being first of its kind in Indian men may provide the foundation for further evaluation of this technique in our population. Moreover, it may also assist clinical practitioners in deciding the role of fusion biopsy in a particular case. In future, it may serve to increase the detection of higher grade cancer, while decreasing the diagnosis of clinical insignificant cancer.

CONCLUSIONS

MRI-TRUS fusion prostate biopsy improves cancer detection rate when combined with standard 12 cores biopsy and detects more intermediate or high-grade prostate cancer (Gleason $>$ 7). Fusion biopsy is useful in patients with previous negative prostate biopsy and tumor located in the anterior and apex of prostate. However, according to our study, this benefit may be limited to men with serum PSA 4–10 ng/ml with normal DRE. Prostate biopsy can be avoided in patients with PI-RADS 2 and patients can be kept on surveillance.

REFERENCES

1. Siegel R, Ma J, Zou Z, Jemal A. Cancer statistics, 2014. *CA Cancer J Clin* 2014;64:9-29.
2. Yeole BB. Trends in the prostate cancer incidence in India. *Asian Pac J Cancer Prev* 2008;9:141-4.
3. Yacoub JH, Verma S, Moulton JS, Eggner S, Aytekin O. Imaging-guided prostate biopsy: Conventional and emerging techniques. *Radiographics* 2012;32:819-37.
4. Lawrentschuk N, Haider MA, Daljeet N, Evans A, Toi A, Finelli A, *et al.* 'Prostatic evasive anterior tumours': The role of magnetic resonance imaging. *BJU Int* 2010;105:1231-6.
5. Yakar D, Hambrock T, Hoeks C, Barentsz JO, Fütterer JJ. Magnetic resonance-guided biopsy of the prostate: Feasibility, technique, and clinical applications. *Top Magn Reson Imaging* 2008;19:291-5.
6. Isariyawongse BK, Sun L, Bañez LL, Robertson C, Polascik TJ, Maloney K, *et al.* Significant discrepancies between diagnostic and pathologic Gleason sums in prostate cancer: The predictive role of age and prostate-specific antigen. *Urology* 2008;72:882-6.
7. Stephenson SK, Chang EK, Marks LS. Screening and detection advances in magnetic resonance image-guided prostate biopsy. *Urol Clin North Am* 2014;41:315-26.
8. Turkbey B, Albert PS, Kurdziel K, Choyke PL. Imaging localized prostate cancer: Current approaches and new developments. *AJR Am J Roentgenol* 2009;192:1471-80.
9. Barentsz JO, Richenberg J, Clements R, Choyke P, Verma S, Villeirs G, *et al.* ESUR prostate MR guidelines 2012. *Eur Radiol* 2012;22:746-57.
10. Hambrock T, Somford DM, Hoeks C, Bouwense SA, Huisman H, Yakar D, *et al.* Magnetic resonance imaging guided prostate biopsy in men with repeat negative biopsies and increased prostate specific antigen. *J Urol* 2010;183:520-7.
11. Pinto PA, Chung PH, Rastinehad AR, Baccala AA Jr., Kruecker J, Benjamin CJ, *et al.* Magnetic resonance imaging/ultrasound fusion guided prostate biopsy improves cancer detection following transrectal ultrasound biopsy and correlates with multiparametric magnetic resonance imaging. *J Urol* 2011;186:1281-5.
12. Sonn GA, Natarajan S, Margolis DJ, MacAiran M, Lieu P, Huang J, *et al.* Targeted biopsy in the detection of prostate cancer using an office based magnetic resonance ultrasound fusion device. *J Urol* 2013;189:86-91.
13. Natarajan S, Marks LS, Margolis D, Huang J, Macairanb ML, Lieub P, *et al.* Clinical application of a 3D ultrasound-guided prostate biopsy system: Biopsy tracking and lesion targeting via real-time MRI/ultrasound fusion. *Urol Oncol* 2011;29:334-42.
14. Batra V, Gautam G, Jaipuria J, Suryavanshi M, Khera R, Ahlawat R. Predictive factors for lymph node positivity in patients undergoing extended pelvic lymphadenectomy during robot assisted radical prostatectomy. *Indian J Urol* 2015;31:217-22.
15. Siddiqui MM, Rais-Bahrami S, Turkbey B, George AK, Rothwax J, Shakir N, *et al.* Comparison of MR/ultrasound fusion-guided biopsy with ultrasound-guided biopsy for the diagnosis of prostate cancer. *JAMA* 2015;313:390-7.
16. Puech P, Rouvière O, Renard-Penna R, Villers A, Devos P, Colombel M, *et al.* Prostate cancer diagnosis: Multiparametric MR-targeted biopsy with cognitive and transrectal US-MR fusion guidance versus systematic biopsy – Prospective multicenter study. *Radiology* 2013;268:461-9.
17. Pokorny MR, de Rooij M, Duncan E, Schröder FH, Parkinson R, Barentsz JO, *et al.* Prospective study of diagnostic accuracy comparing prostate cancer detection by transrectal ultrasound-guided biopsy versus magnetic resonance (MR) imaging with subsequent MR-guided biopsy in men without previous prostate biopsies. *Eur Urol* 2014;66:22-9.
18. Mendhiratta N, Rosenkrantz AB, Meng X, Wysock JS, Fenstermaker M, Huang R, *et al.* Magnetic resonance imaging-ultrasound fusion targeted prostate biopsy in a consecutive cohort of men with no previous biopsy: Reduction of over detection through improved risk stratification. *J Urol* 2015;194:1601-6.
19. Peltier A, Aoun F, Lemort M, Kwizera F, Paesmans M, Van Velthoven R. MRI-targeted biopsies versus systematic transrectal ultrasound guided biopsies for the diagnosis of localized prostate cancer in biopsy naïve men. *Biomed Res Int* 2015;2015:571708.
20. Vourganti S, Rastinehad A, Yerram N, Nix J, Volkin D, Hoang A, *et al.* Multiparametric magnetic resonance imaging and ultrasound fusion biopsy detects prostate cancer in patients with prior negative TRUS biopsies. *J Urol* 2012;188:2152-7.
21. Marks L, Young S, Natarajan S. MRI-ultrasound fusion for guidance of targeted prostate biopsy. *Curr Opin Urol* 2013;23:43-50.
22. Franiel T, Stephan C, Erbersdobler A, Dietz E, Maxeiner A, Hell N, *et al.* Areas suspicious for prostate cancer: MR-guided biopsy in patients with at least one transrectal US-guided biopsy with a negative finding – multiparametric MR imaging for detection and biopsy planning. *Radiology* 2011;259:162-72.
23. Roethke MC, Kuru TH, Schultze S, Tichy D, Kopp-Schneider A, Fenchel M, *et al.* Evaluation of the ESUR PI-RADS scoring system for multiparametric MRI of the prostate with targeted MR/TRUS fusion-guided biopsy at 3.0 Tesla. *Eur Radiol* 2014;24:344-52.
24. Junker D, Schäfer G, Edlinger M, Kremser C, Bektic J, Horninger W, *et al.* Evaluation of the PI-RADS scoring system for classifying mpMRI findings in men with suspicion of prostate cancer. *Biomed Res Int* 2013;2013:252939.

How to cite this article: Bansal S, Gupta NP, Yadav R, Khera R, Ahlawat K, Gautam D, *et al.* Multiparametric magnetic resonance imaging-transrectal ultrasound fusion prostate biopsy: A prospective, single centre study. *Indian J Urol* 2017;33:134-9.