

The presence of left atrial posterior wall fibrillation despite restoration of sinus rhythm after posterior box ablation



Khalid Abozguia, MD, PhD,^{*} Michael J. Cutler, DO, PhD,[†] Ohad Ziv, MD^{*}

From the ^{*}Heart and Vascular Center, MetroHealth Campus, Case Western Reserve University, Cleveland, Ohio, and [†]Intermountain Heart Institute, Murray, Utah.

Introduction

Catheter ablation plays an important role in the management of persistent atrial fibrillation (AF),¹ though recurrences of AF following ablation in patients with this condition remains high.² There is general agreement that catheter ablation for AF should include pulmonary vein antral isolation (PVAI). The location and extent of ablation that should be performed beyond PVAI for the management of persistent AF remains uncertain.^{1–3} Although controversial, the targeting of the posterior left atrial wall for ablation beyond isolation of the pulmonary veins (PVs) has been promoted by some operators.⁴ We present a case demonstrating the potential importance in some patients of targeting the posterior wall for ablation.

Case report

A 74-year-old woman was referred to the outpatient department with a history of symptomatic persistent AF despite receiving a maximal dose of dofetilide. Her other medication included warfarin, lisinopril, and atorvastatin. There was no history of hypertension, coronary artery disease, or obstructive sleep apnea. A previous transthoracic echocardiogram had been reported as demonstrating a mildly dilated left atrium (LA) at 4.2 cm with normal left ventricle (LV) systolic function (ejection fraction 70%). A preoperative transesophageal echocardiogram showed no evidence of clot in the left atrial appendage with 4 PVs draining into the LA. These findings were

confirmed by a preoperative multislice computed tomography scan. The patient elected to have radiofrequency catheter ablation for AF. Dofetilide was held 5 days prior to the procedure.

The patient presented to the laboratory in AF. A double transeptal puncture was performed and heparin was given as a bolus and infused targeting activated coagulation times of 300–400 seconds. A 3-dimensional electroanatomic mapping technique was employed (CARTO 3 Navigation System, Biosense Webster, Diamond Bar, CA). A 6F Lasso variable circular catheter (Biosense Webster) and an irrigated-tip mapping/ablation catheter (F curve ThermoCool Irrigated Tip Catheter SF, Biosense Webster) were introduced into the LA.

Wide antral isolation of the left and right PVs was performed initially. Powers of 35–43 W were used anteriorly and 25–30 W posteriorly in the LA. The patient remained in AF after all 4 PVs demonstrated isolation. The patient was successfully cardioverted to sinus rhythm, following a single synchronized direct current shock of 150 J. All PVs remained isolated. However, AF recurred shortly after cardioversion. Posterior wall isolation was therefore targeted with a roof line and floor line to complete a “posterior box.” After further ablation, including that at the cavotricuspid isthmus and LA septal roof, the patient converted to sinus rhythm during radiofrequency delivery on the LA roof. During sinus rhythm, the Lasso catheter was placed back onto the posterior wall to check for electrical isolation. At this time, the posterior wall appeared to have continuous irregular electrical signal during sinus rhythm, suggesting AF existing on the now isolated posterior wall during sinus rhythm in the remainder of the atria (Figure 1).

The post-procedure course was uncomplicated. The patient was restarted on dofetilide and was discharged home the next day. Dofetilide was discontinued 2 months post ablation. Now, 7 months post ablation and off antiarrhythmic drugs, she has remained asymptomatic and in sinus rhythm. A 1-month Event monitor at 3 months post ablation and a 2-week Holter monitor at 6 months post ablation did not reveal any atrial arrhythmias.

KEYWORDS Atrial fibrillation; Catheter ablation; Left atrium; Posterior wall; Pulmonary vein isolation

ABBREVIATIONS AF = atrial fibrillation; LA = left atrium; LV = left ventricle; PA = posteroanterior; PV = pulmonary vein; PVAI = pulmonary vein antral isolation (Heart Rhythm Case Reports 2015;1:416–418)

Conflict of Interest: Dr. Cutler has received honorarium from Boston Scientific. All other authors report no conflict of interest. **Address reprint requests and correspondence:** Dr Ohad Ziv, Heart and Vascular Center, MetroHealth Campus, Case Western Reserve University, 2500 MetroHealth Drive, Hamann 3, Cleveland, OH 44109-1998. E-mail address: oziv@metrohealth.org.

KEY TEACHING POINTS

- Pulmonary vein isolation may not be sufficient to treat some patients with persistent atrial fibrillation.
- The posterior wall of the left atrium may be a source of atrial fibrillation in patients with persistent atrial fibrillation.
- Targeting the posterior wall for electrical isolation with catheter ablation may improve ablation outcomes in patients with persistent atrial fibrillation.

Discussion

In patients with persistent AF, recurrence of atrial arrhythmias post catheter ablation remains high.² The location and extent of ablation that should be performed beyond PV-wide antral isolation for the management of persistent AF remains uncertain.¹⁻³ Some recent data suggest more-extensive ablation may reduce post-ablation recurrences.^{5,6} Posterior wall isolation as an adjunct to PVAI has been reported previously but has remained controversial.^{7,8} Some experienced operators strongly believe in the utility of posterior wall ablation, because it may be a further source of AF triggers.⁴ However,

1 randomized trial demonstrated no improvement in recurrences with the addition of posterior wall isolation.¹⁰

In this example, PV isolation was not sufficient to maintain sinus rhythm immediately after cardioversion. Furthermore, in this patient, complete isolation of the posterior wall with a “box” technique not only restored sinus rhythm, but preserved ongoing fibrillatory activity on the LA posterior wall. Similar potential benefits were observed in using electrical isolation of non-PV foci such as LA appendage⁹. Furthermore, isolated AF due to the creation of a scar border has been described before, in the atrioatrial anastomoses of recipients of heart transplant.^{11,12} This example of AF persisting on the posterior wall after a posterior “box” isolation underscores the potential for the LA posterior wall to trigger and maintain AF. Interestingly, PVs and the posterior LA have similar pacemaker cell properties and share the same embryologic origin, the sinus venosus. Hence, it was postulated that non-PV foci could originate from the posterior LA.¹³ These findings support that in select patients, the isolation of the posterior LA in addition to PVs may improve acute results of catheter ablation for AF. The potential added advantage of the posterior “box” is that it allows for isolation of these triggers while limiting the surface area of the posterior wall that is exposed to ablation, therefore reducing the potential for thermal injury to the esophagus.

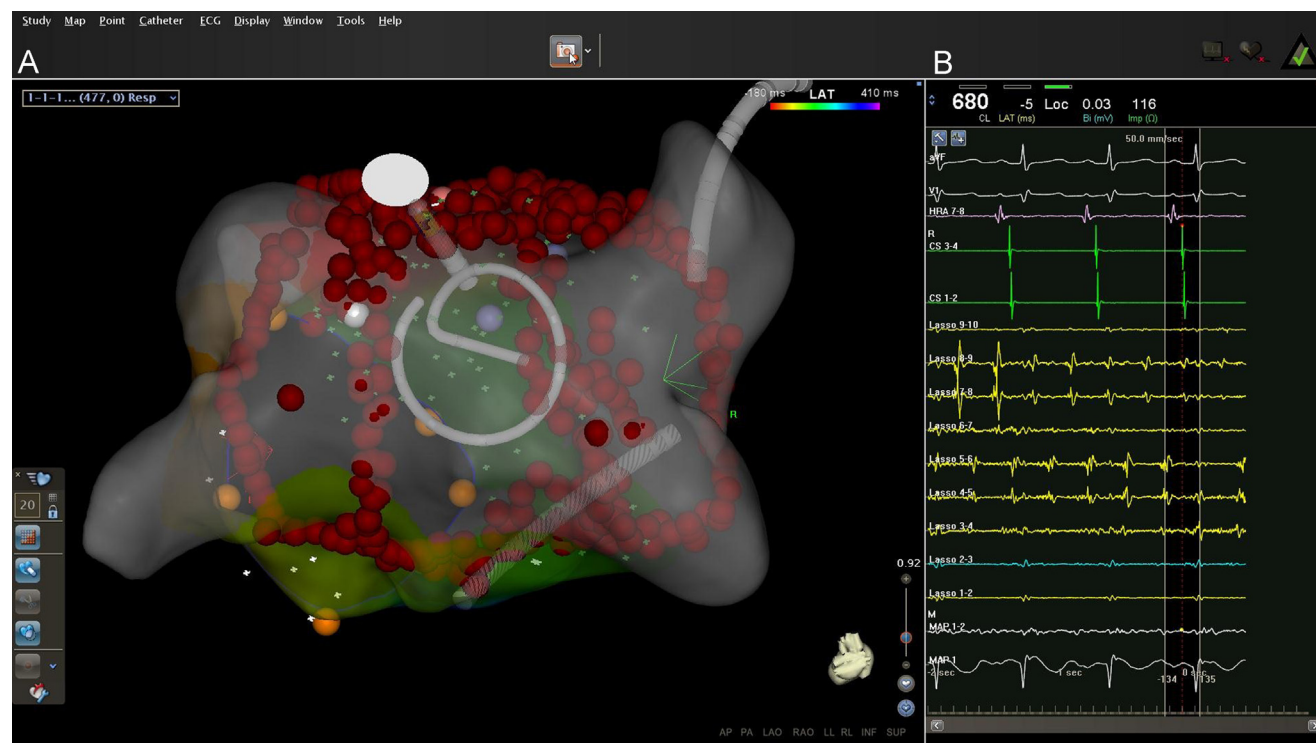


Figure 1 Persistence of fibrillation in the posterior wall of the left atrium (LA) following the electrical isolation of the pulmonary veins and the posterior wall. The image from a snapshot taken with the CARTO 3 Navigation System. (A) shows a posteroanterior view of the LA geometry obtained during the case. Radiofrequency lesions are in red. The Lasso catheter is seen abutting the posterior wall within the borders of the radiofrequency lesions delivered. The signals in (B) show, from top to bottom, surface leads I and V1; high right atrium and coronary sinus electrograms showing normal sinus rhythm; the Lasso catheter (LS) poles 3–9 demonstrating a continuous signal with a shifting activation sequence; on the posterior roof, Lasso 1–2 and 9–10, along with the ablation catheter, showing far-field LA signals in normal sinus rhythm.

Conclusion

The posterior wall can be an important source of trigger for AF and may furthermore support the maintenance of AF. As a result, it should be considered a target for ablation and isolation in select patients with persistent AF.

References

1. January CT, Wann LS, Alpert JS, et al. 2014 AHA/ACC/HRS guideline for the management of patients with atrial fibrillation: A report of the American College of Cardiology/American Heart Association task force on practice guidelines and the heart rhythm society. *J Am Coll Cardiol* 2014;64:e1–e76.
2. Calkins H, Kuck KH, Cappato R, et al. 2012 HRS/EHRA/ECAS expert consensus statement on catheter and surgical ablation of atrial fibrillation: Recommendations for patient selection, procedural techniques, patient management and follow-up, definitions, endpoints, and research trial design. *J Interv Card Electrophysiol* 2012;33:171–257.
3. Themistoclakis S, Raviele A, China P, et al. Prospective european survey on atrial fibrillation ablation: Clinical characteristics of patients and ablation strategies used in different countries. *J Cardiovasc Electrophysiol* 2014;25:1074–1081.
4. Di Biase L, Santangeli P, Natale A. How to ablate long-standing persistent atrial fibrillation? *Curr Opin Cardiol* 2013;28:26–35.
5. Verma A, Sanders P, Champagne J, Macle L, Nair GM, Calkins H, Wilber DJ. Selective complex fractionated atrial electrograms targeting for atrial fibrillation study (select af): A multicenter, randomized trial. *Circ Arrhythm Electrophysiol* 2014;7:55–62.
6. Lin YJ, Chang SL, Lo LW, et al. A prospective and randomized comparison of limited versus extensive atrial substrate modification after circumferential pulmonary vein isolation in nonparoxysmal atrial fibrillation. *J Cardiovasc Electrophysiol* 2014;25:803–812.
7. Kumagai K, Muraoka S, Mitsutake C, Takashima H, Nakashima H. A new approach for complete isolation of the posterior left atrium including pulmonary veins for atrial fibrillation. *J Cardiovasc Electrophysiol* 2007;18:1047–1052.
8. Chilukuri K, Scherr D, Dalal D, Cheng A, Spragg D, Nazarian S, Barcelon BD, Marine JE, Calkins H, Henrikson CA. Conventional pulmonary vein isolation compared with the “box isolation” method: A randomized clinical trial. *J Interv Card Electrophysiol* 2011;32:137–146.
9. Di Biase L, Burkhardt JD, Mohanty P, et al. Left atrial appendage: An underrecognized trigger site of atrial fibrillation. *Circulation* 2010;122:109–118.
10. Tamborero D, Mont L, Berruezo A, Matiello M, Benito B, Sitges M, Vidal B, de Caralt TM, Perea RJ, Vatasescu R, Brugada J. Left atrial posterior wall isolation does not improve the outcome of circumferential pulmonary vein ablation for atrial fibrillation: A prospective randomized study. *Circ Arrhythm Electrophysiol* 2009;2:35–40.
11. Gupta R, Latif F, Dasari TW, Lozano P. Coexisting normal sinus rhythm and atrial fibrillation 18 years after heart transplant. *J Card Surg* 2008;23:792–794.
12. Marine JE, Schuger CD, Bogun F, Kalahasty G, Arnaldo F, Czerska B, Krishnan SC. Mechanism of atrial flutter occurring late after orthotopic heart transplantation with atrio-atrial anastomosis. *Pacing Clin Electrophysiol* 2005;28:412–420.
13. Kumagai K. Catheter ablation of atrial fibrillation. State of the art. *Circ J* 2011;75:2305–2311.