

[ CASE REPORT ]

## Rheumatoid Arthritis Complicated with Anti-melanoma Differentiation-associated Gene 5 Antibody-positive Interstitial Pneumonia

Haruki Matsumoto, Shuzo Sato, Yuya Fujita, Makiko Yashiro-Furuya, Naoki Matsuoka, Tomoyuki Asano, Hiroko Kobayashi, Hiroshi Watanabe and Kiyoshi Migita

### Abstract:

Anti-melanoma differentiation-associated gene 5 (MDA5) antibodies are frequently detected in amyopathic dermatomyositis with rapidly progressive interstitial lung disease (RP-ILD). However, the presence of anti-MDA5 antibodies in other connective tissue diseases is not well known. We herein report a case of rheumatoid arthritis complicated with refractory anti-MDA5 antibody-positive ILD. A 75-year-old Japanese woman was referred to our hospital for refractory ILD. Serological testing was positive for anti-MDA5 antibody without any muscle or skin lesions. Immunosuppressive therapy (prednisolone and tacrolimus) ameliorated her symptoms as well as ILD. Anti-MDA5 antibody-positive ILD, as well as dermatomyositis with RP-ILD, can occur in patients with rheumatoid arthritis.

**Key words:** anti-MDA5 antibody, rheumatoid arthritis, interstitial lung disease

(Intern Med 58: 737-742, 2019)

(DOI: 10.2169/internalmedicine.1613-18)

### Introduction

Myositis-specific autoantibodies (MSAs) are autoantibodies specific to idiopathic inflammatory myopathy, and they have recently been used to help diagnose polymyositis/dermatomyositis (PM/DM) (1). Many of these antibodies are associated with a unique clinical subset of PM/DM, making them useful for predicting and monitoring certain clinical manifestations.

Interstitial lung disease (ILD) is often accompanied by PM/DM, including a subset of clinically amyopathic dermatomyositis (CADM). Anti-melanoma differentiation-associated gene 5 (MDA5) antibodies are frequently detected in CADM with rapidly-progressive ILD (RP-ILD), which is often fatal during the early stage of illness (2, 3). Anti-MDA5 antibodies have been reported to be associated with the disease activity of DM with RP-ILD, and these antibodies have an important role in the onset of lung disease (4). However, the presence of anti-MDA5 antibodies in other connective tissue diseases (CTD) is not recognized, es-

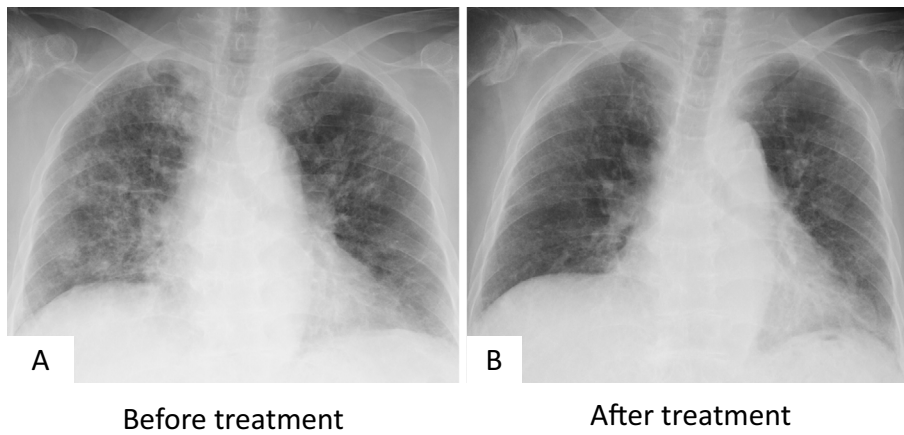
pecially in patients complicated with ILD.

We herein report the case of a patient with rheumatoid arthritis (RA) complicated with anti-MDA5 antibody-positive refractory ILD during immunosuppressive therapy.

### Case Report

A 75-year-old Japanese woman was referred to our hospital for refractory ILD from a hospital where she had been treated previously. She had received surgeries for cholecystitis, appendicitis, and myoma uteri. She had no history of smoking. Ten years earlier, she had suffered polyarthralgia and joint swelling of the wrists and knees. She was diagnosed with RA based on her symptoms and was positive for rheumatoid factor (RF) (194 IU/mL) and elevated anti-cyclic citrullinated peptide (CCP) antibodies (7.5 U/mL).

Chest X-ray showed slight ground-glass opacification (GGO) in both lower lungs. No symptoms of myositis were found, including normal serum creatine kinase (CK) levels (57 U/L). She received low-dose prednisolone (PSL, 5 mg/day), salazosulfapyridine (SASP) (known as sulfasalazine in



**Figure 1.** Chest X-ray findings (A: before immunosuppressive treatment, B: after treatment).

the US), and methotrexate (MTX, 6 mg/week). However, the arthralgia was sustained, and the administration of adalimumab (ADA, 40 mg/2 weeks) was started at 1 year after the initial treatment. Subsequently, the symptoms and activity of RA, as well as ILD, were reduced and were stable for nine years.

One month before admission, the patient reported a common cold following a persistent dry cough. Two weeks later, she visited her previous hospital for dyspnea and arthralgia in both knees. Chest computed tomography (CT) showed diffuse GGO with traction bronchiectasis predominantly in both lower lungs. Krebs von den Lungen-6 (KL-6) was elevated to 2,150 U/mL. She was hospitalized and received methylprednisolone pulse therapy (mPSL 500 mg for 3 days) following oral 35 mg of PSL. However, she complained of sustained dyspnea. She was therefore transferred to our hospital for further treatment.

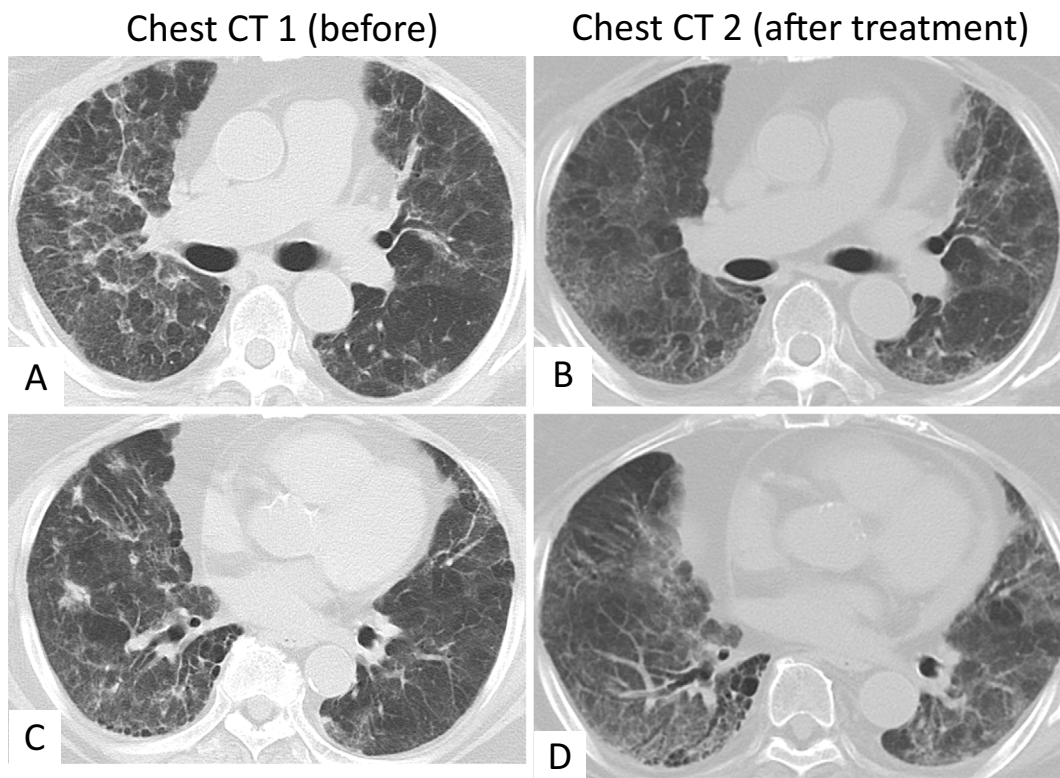
On admission, her body temperature was 36.4°C, and her blood pressure was 150/83 mmHg. A physical examination showed fine crackles in both lower lungs. Neither skin lesions nor muscle weakness were observed. She complained of arthralgia and joint tenderness in both knees. Her oxygen saturation by pulse oximetry was 98% on 3 L/min of oxygen flow via nasal cannula. Chest X-ray and chest CT showed diffuse GGO with slight traction bronchiectasis predominantly in both lower lung fields, with no remarkable improvement from images taken before steroid pulse therapy (Fig. 1A, 2A, C). X-rays and CT scans of the hands showed bone erosion as well as joint space narrowing on both hands (Fig. 3). The RA activity scores using the Disease Activity Score with erythrocyte sedimentation rate (DAS28-ESR) (4) were 3.63, indicating moderate disease activity. The laboratory data showed elevated white blood cell counts (18,000/ $\mu$ L), LDH (lactic dehydrogenase) (315 U/L), and serum creatinine (1.01 mg/dL). The CK and aldolase levels were normal (28 U/L and 6.6 U/L, respectively). KL-6, surfactant proteins A (SP-A) and D (SP-D) levels were all elevated (3,820 U/mL, 53.5 ng/mL, and 262 ng/mL, respectively). The RF and erythrocyte sedimentation rate were also elevated (19 IU/mL and 20 mm/h, respectively). Anti-CCP an-

tibodies and anti-SSA antibodies were negative (Table 1). There was no clinical or laboratory evidence of infection. Unexpectedly, as Table 1 shows, increased anti-MDA5 antibody levels were detected (53 index). Based on these findings, a diagnosis of RA complicated with ILD accompanied by elevated anti-MDA5 antibodies was finally established.

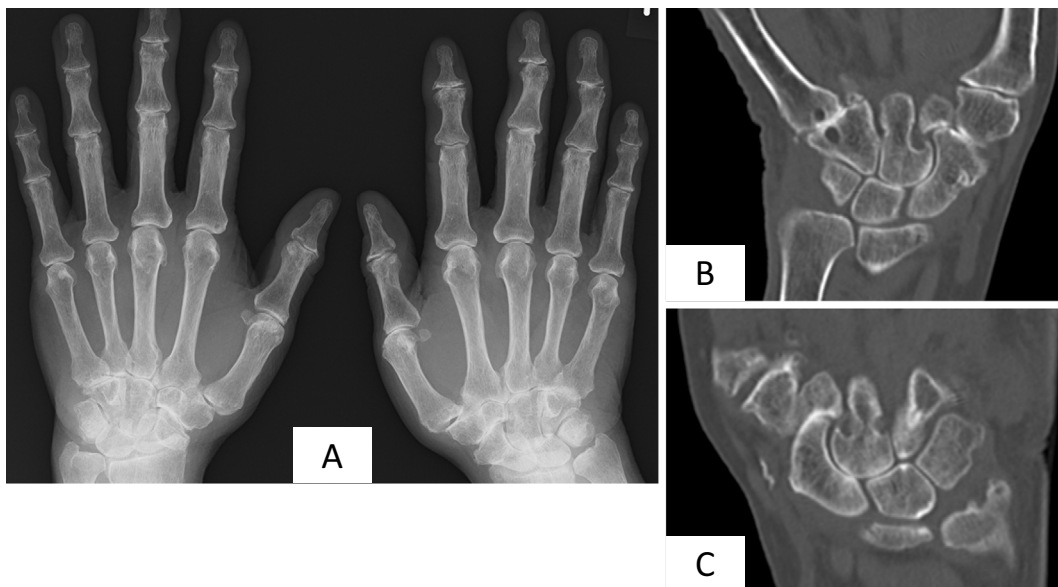
The clinical course is summarized in Fig. 4. MTX, SASP, and ADA were discontinued due to suspicions of drug-induced ILD. After systemic screening, the patient received mPSL pulse therapy (1 g/day for 3 days) followed by 30 mg of oral PSL and tacrolimus (TAC, 1 mg/day, increased up to 1.5 mg/day). After TAC administration, her symptoms, including the lung shadows, improved. However, the ILD relapsed when oral PSL was tapered to 20 mg/day. She received mPSL pulse therapy again followed by an increased dose of PSL (60 mg/day). Her symptoms improved gradually, and the ILD became stable with oral PSL and TAC (Fig. 1B, 2B, D). However, she later suffered thrombocytopenia and was diagnosed with aplastic anemia by a bone marrow examination. Intravenous cyclophosphamide therapy was not performed out of consideration of bone marrow suppression. After transfer back to her previous hospital, her PSL doses were successfully tapered to 10 mg/day with no major relapse.

## Discussion

Anti-MDA-5 antibodies are often detected in patients with CADM, and these antibodies are particularly markedly elevated in patients with RP-ILD (5, 6). Sato et al. reported that this antibody is only detected in DM patients with ILD/RP-ILD (6, 7). Furthermore, it has been reported that the anti-MDA5 antibody titer correlates with the disease activity and predicts the disease outcome in patients with DM and RP-ILD (4). Indeed, idiopathic interstitial pneumonia (IIP) patients with RP-ILD showed decreased anti-MDA5 antibody levels after immunosuppressive treatment (from 147 to 48 index), as in the present case (Fig. 4) (8). However, in contrast to these previous reports, several cases of patients with anti-MDA5 antibody-positive ILD without typical der-



**Figure 2.** Chest CT findings (A, C: before treatment, B, D: after treatment). CT: computed tomography



**Figure 3.** Differences in the X-ray and CT findings of the hands on admission (A: hand X-rays on admission, B and C: hand CT findings on admission). CT: computed tomography, RA: rheumatoid arthritis

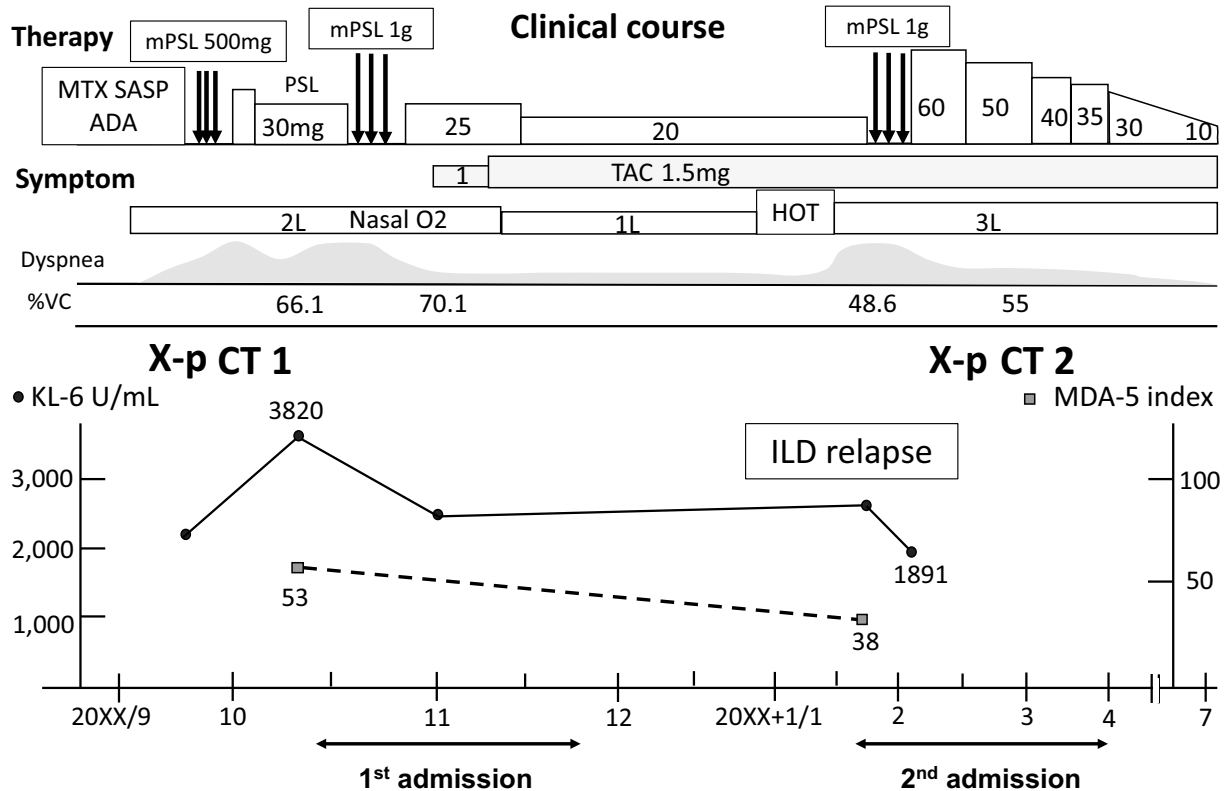
matomyositis symptoms have been reported (8, 9). These cases were reported as arthritis with a clinical suspicion of RA and IIP complicated with RP-ILD, with patients being found to be positive for anti-MDA5 antibodies without any skin lesions (Table 2). These cases were treated with mPSL pulse therapy, high-dose PSL, and immunosuppressants (cyclophosphamide, calcineurin inhibitors, etc.).

In our patient, the lung shadows were deemed unlikely to be RP-ILD, as both lung shadows mainly consisted of a nonspecific interstitial pneumonia (NSIP) pattern, rather than a typical RP-ILD (10). A previous report indicated that patients with anti-MDA5 antibody-positive RP-ILD mainly show lower consolidation or GGO patterns and random GGO patterns on chest CT (10). In RA patients, complica-

**Table 1. Laboratory Data on Admission.**

WBC	18,000 / $\mu$ L	CRP	0.03 mg/dL	SP-A	53.5 ng/mL
Neu	90 %	ESR	20 mm (1 h)	SP-D	262 ng/mL
Lym	4 %	RF	19 IU/mL	IgG	1,033 mg/dL
Mono	4 %	TP	6.7 g/dL	IgA	327 mg/dL
Baso	1 %	Alb	3.5 g/dL	IgM	161 mg/dL
Eo	1 %	T-Bil	0.5 mg/dL	MMP3	222 ng/mL
RBC	377 $\times$ 10 <sup>4</sup> / $\mu$ L	AST	20 U/L	CMV antigenemia	negative
Hb	11.5 g/dL	ALT	21 U/L	Beta-D glucan	<6.0 pg/mL
Hct	35.9 %	LDH	315 U/L	IGRA	negative
MCV	95 fl	ALP	235 U/L		
Plt	12.1 $\times$ 10 <sup>4</sup> / $\mu$ L	CK	28 U/L	ANA	$\times$ 80
		ALD	6.6 U/L	Anti-CCP	1.7 U/mL
BNP	12.8 pg/mL	BUN	24 mg/dL	Anti-SS-A/SS-B	<0.5/<0.5
		Cre	1.01 mg/dL	Anti-MDA-5	53 index
		KL-6	3,820 U/mL	Anti-ARS	<5 index

WBC: white blood cell count, Neu: neutrophil, Lym: lymphocyte, Mono: monocyte, Baso: basophil, Eo: eosinophil, RBC: red blood cell count, Hb: hemoglobin, Ht: hematocrit, MCV: mean corpuscular volume, Plt: platelets, BNP: brain natriuretic peptide, CMV: cytomegalovirus, CRP: C-reactive protein, ESR: erythrocyte sedimentation rate, RF: rheumatoid factor, TP: total protein, Alb: albumin, T-Bil: total bilirubin, AST: aspartate aminotransferase, ALT: alanine aminotransferase, LDH: lactate dehydrogenase, ALP: alkaline phosphatase,  $\gamma$ -GTP: gamma-glutamyl transpeptidase, CK: creatine kinase, ALD: aldolase, BUN: blood urea nitrogen, Cre: creatinine, KL-6: Krebs von den Lungen-6, SP-A: surfactant proteins A, SP-D: surfactant proteins D, IgG: immunoglobulin G, IgA: immunoglobulin A, IgM: immunoglobulin M, MMP-3: matrix metalloproteinase-3, IGRA: interferon-gamma release assays, ANA: anti-nuclear antibody, Anti-CCP: anti-cyclic citrullinated peptide antibody, Anti-SS-A/B: anti-Sjögren's-syndrome-related antigen A/B antibody, Anti-MDA-5: anti-melanoma-differentiation associated gene 5 antibody, Anti-ARS: anti-aminoacyl tRNA synthetase antibody



**Figure 4. Clinical course.** ADA: adalimumab, HOT: home oxygen therapy, ILD: interstitial lung disease, KL-6: Krebs von den Lungen-6, MDA-5: anti-melanoma differentiation-associated gene 5 antibody, MTX: methotrexate, mPSL: methylprednisolone, PSL: prednisolone, SASP: salazosulfapyridine, TAC: tacrolimus, %VC: % vital capacity



**Table 2. Patients with Anti-MDA5 Antibody-positive ILD without CADM Symptoms.**

Reference	Age/ sex	Disease	IP/RP-ILD	Other complication	Therapy	Outcome
Our case	75/F	RA	IP Relapse+	-	mPSL pulse, PSL, TAC	alive
9	54/F	RA suspect	RP-ILD	-	mPSL pulse, PSL, IV-CY, CyA	alive
8	61/F	IIP	RP-ILD	-	mPSL pulse, PSL, TAC, IV-CY, IVIG	alive

CADM: clinically amyopathic dermatomyositis, CyA: cyclosporine A, F: female, IIP: idiopathic interstitial pneumonia, ILD: interstitial lung disease, IP: interstitial pneumonia, IV-CY: intravenous cyclophosphamide, IVIG: intravenous immunoglobulin, MDA-5: melanoma-differentiation associated gene 5, mPSL: methylprednisolone, RP-ILD: rapidly progressive interstitial lung disease, RA: rheumatoid arthritis, TAC: tacrolimus

tion with NSIP is relatively common, in contrast to the relatively low occurrence of diffuse alveolar damage (11). In addition, NSIP can relapse despite immunosuppressive treatment, in contrast to the typical course of anti-MDA5 antibody-positive RP-ILD (2).

Indeed, not all patients with anti-MDA5 antibody-positive RP-ILD show the typical clinical features of RP-ILD. As described previously, anti-MDA5 antibody-positive CADM patients with RP-ILD are typically resistant to immunosuppressive therapy and have a poor outcome for the first six months of the diagnosis; however, the prognosis in those who survive the first six months is good, and the recurrence rate is very low (2). Of note, though: Sato et al. described a case of anti-MDA5 antibody-positive CADM with recurrent deterioration over nine years (12). In addition, a case of CADM with anti-MDA5 antibody-positive RP-ILD showing a non-DAD pattern (NSIP pattern) has also been described (13). These previous findings suggest that another type of anti-MDA5 antibody-positive ILD (NSIP without other RP-ILD symptoms) may exist.

Regarding why CADM with RP-ILD-specific anti-MDA5 antibodies was detected in a case of non-PM/DM CTD, one possibility is that anti-MDA5 antibodies originally exist in non-PM/DM CTD in relatively low titers and/or frequency. Previous reports have indicated that a very small number of patients show slightly elevated levels of anti-MDA5 antibodies (nearly at the cut-off) according to an enzyme-linked immunosorbent assay (ELISA) (6, 7). MDA5 and anti-MDA5 antibodies may play an important role in lung disease development, as anti-MDA5 antibodies are closely associated with the disease activity of CADM with RP-ILD (4). Since anti-MDA5 antibodies are not routinely investigated in ILD without DM symptoms, their prevalence in non-PM/DM CTDs may be underestimated. Genetic factors may also play an important role in PM/DM with ILD development. Recently, a variant of the WDFY family member 4 (WDFY4) gene was found to have a significant association with CADM in a genome-wide association study (14). This report suggested that WDFY4 and its variants might be associated with the disease development of anti-MDA5 antibody-positive CADM by augmenting NF- $\kappa$ B activation through MDA5 interaction. Interestingly, the association of variants in WDFY4 is also reported in RA and systemic lupus

erythematosus (SLE) in Asian populations (15, 16). These findings suggest that these genetic factors may be associated with ILD occurrence in not only patients with CADM but also those with non-DM ILD (RA and SLE). Further investigations will be needed to clarify this issue.

Another possibility is that skin lesion development is masked by immunosuppressive therapy to treat preceding arthralgia in the course of DM/CADM with ILD development. In fact, patients with DM with RP-ILD who initially show arthralgia and are positive for RF mimicking RA symptoms (non-erosive arthritis) have been reported (17). However, this likelihood is quite small, as the present and previous cases showed no skin lesions throughout the clinical course (Table 2). In addition, as Fig. 3 shows, our patient had obvious RA features with a long disease duration (almost 10 years).

In our case, the tumor necrosis factor (TNF)- $\alpha$  inhibitor ADA was used for refractory RA treatment before ILD exacerbation. TNF- $\alpha$  inhibitors are effective in RA patients; however, severe adverse events, including autoimmune disease development (lupus-like syndrome), have been reported (18, 19). The pathogenesis of autoimmune disease onset can be explained by upregulated interferon alpha (IFN- $\alpha$ ) production due to blocking TNF signaling (18, 20). Previous reports have indicated that cases of anti-MDA5 antibody-positive DM show elevated serum IFN- $\alpha$  levels and serum ferritin levels (21). These facts indicate that TNF- $\alpha$  inhibitors can also affect the initiation of ILD flare in patients with anti-MDA5 antibody-positive ILD by increasing serum the IFN- $\alpha$  levels. Serum IFN- $\alpha$  and ferritin levels were not measured before immunosuppressive treatment in the present case (ferritin levels were normal after immunosuppressive therapy, 51 ng/mL). In the treatment of patients with anti-MDA5 antibody-positive ILD, monitoring such variables can be useful.

In conclusion, anti-MDA5 antibody-positive CTD with ILD can exist in patients other than those with DM/CADM. Further investigations are needed to clarify the clinical features of such cases.

Informed consent was obtained from the patient for the publication of this report.

The authors state that they have no Conflict of Interest (COI).

## References

- Betteridge Z, McHugh N. Myositis-specific autoantibodies: an important tool to support diagnosis of myositis. *J Intern Med* **280**: 8-23, 2016.
- Koga T, Fujikawa K, Horai Y, et al. The diagnostic utility of anti-melanoma differentiation-associated gene 5 antibody testing for predicting the prognosis of Japanese patients with DM. *Rheumatology (Oxford)* **51**: 1278-1284, 2012.
- Nakashima R, Imura Y, Kobayashi S, et al. The RIG-I-like receptor IFIH1/MDA5 is a dermatomyositis-specific autoantigen identified by the anti-CADM-140 antibody. *Rheumatology (Oxford)* **49**: 433-440, 2010.
- Sato S, Kuwana M, Fujita T, Suzuki Y. Anti-CADM-140/MDA5 autoantibody titer correlates with disease activity and predicts disease outcome in patients with dermatomyositis and rapidly progressive interstitial lung disease. *Mod Rheumatol* **23**: 496-502, 2013.
- Sato S, Hirakata M, Kuwana M, et al. Autoantibodies to a 140-kd polypeptide, CADM-140, in Japanese patients with clinically amyopathic dermatomyositis. *Arthritis Rheum* **52**: 1571-1576, 2005.
- Sato S, Hoshino K, Satoh T, et al. RNA helicase encoded by melanoma differentiation-associated gene 5 is a major autoantigen in patients with clinically amyopathic dermatomyositis: association with rapidly progressive interstitial lung disease. *Arthritis Rheum* **60**: 2193-2200, 2009.
- Sato S, Murakami A, Kuwajima A, et al. Clinical utility of an enzyme-linked immunosorbent assay for detecting anti-melanoma differentiation-associated gene 5 autoantibodies. *PLoS One* **11**: e0154285, 2016.
- Koga T, Kaieda S, Okamoto M, et al. Successful treatment of rapidly progressive unclassifiable idiopathic interstitial pneumonia with anti-melanoma differentiation-associated gene-5 antibody by intensive immunosuppressive therapy. *Intern Med* **57**: 1039-1043, 2018.
- González-Moreno J, Raya-Cruz M, Losada-Lopez I, CACHEDA AP, Oliver C, Colom B. Rapidly progressive interstitial lung disease due to anti-MDA5 antibodies without skin involvement: a case report and literature review. *Rheumatol Int* 2018.
- Tanizawa K, Handa T, Nakashima R, et al. HRCT features of interstitial lung disease in dermatomyositis with anti-CADM-140 antibody. *Respir Med* **105**: 1380-1387, 2011.
- Tsuchiya Y, Takayanagi N, Sugiura H, et al. Lung diseases directly associated with rheumatoid arthritis and their relationship to outcome. *Eur Respir J* **37**: 1411-1417, 2011.
- Sato Y, Otsuka K, Tamai K, Ono Y, Hamaguchi Y, Tomii K. An atypical clinical course of anti-mda5 antibody-positive interstitial lung disease in a patient with three deteriorations in 9 years. *Intern Med* **56**: 341-346, 2017.
- Suzuki A, Kondoh Y, Taniguchi H, et al. Lung histopathological pattern in a survivor with rapidly progressive interstitial lung disease and anti-melanoma differentiation-associated gene 5 antibody-positive clinically amyopathic dermatomyositis. *Respir Med Case Rep* **28**: 5-8, 2016.
- Kochi Y, Kamatani Y, Kondo Y, et al. Splicing variant of WDFY4 augments MDA5 signalling and the risk of clinically amyopathic dermatomyositis. *Ann Rheum Dis* **77**: 602-611, 2018.
- Yang W, Shen N, Ye DQ, et al. Genome-wide association study in Asian populations identifies variants in ETS1 and WDFY4 associated with systemic lupus erythematosus. *PLoS Genet* **6**: e1000841, 2010.
- Zhang Y, Bo L, Zhang H, Zhuang C, Liu R. E26 transformation-specific-1 (ETS1) and WDFY family member 4 (WDFY4) polymorphisms in Chinese patients with rheumatoid arthritis. *Int J Mol Sci* **15**: 2712-2721, 2014.
- Ho S, Troyanov Y, Fritzler MJ, et al. Describing and expanding the clinical phenotype of anti-MDA5-associated rapidly progressive interstitial lung disease: case series of nine Canadian patients and literature review. *Scand J Rheumatol* **47**: 210-224, 2018.
- Moulis G, Sommet A, Lapeyre-Mestre M, Montastruc JL. Association Française des Centres Régionaux de Pharmacovigilance. Is the risk of tumour necrosis factor inhibitor-induced lupus or lupus-like syndrome the same with monoclonal antibodies and soluble receptor? A case/non-case study in a nationwide pharmacovigilance database. *Rheumatology (Oxford)* **53**: 1864-1871, 2014.
- Araújo-Fernández S, Ahijón-Lana M, Isenberg DA. Drug-induced lupus: including anti-tumour necrosis factor and interferon induced. *Lupus* **23**: 545-553, 2014.
- Cantaert T, Baeten D, Tak PP, van Baarsen LG. Type I IFN and TNF $\alpha$  cross-regulation in immune-mediated inflammatory disease: basic concepts and clinical relevance. *Arthritis Res Ther* **12**: 219, 2010.
- Horai Y, Koga T, Fujikawa K, et al. Serum interferon- $\alpha$  is a useful biomarker in patients with anti-melanoma differentiation-associated gene 5 (MDA5) antibody-positive dermatomyositis. *Mod Rheumatol* **25**: 85-89, 2015.

The Internal Medicine is an Open Access journal distributed under the Creative Commons Attribution-NonCommercial-NoDerivatives 4.0 International License. To view the details of this license, please visit (<https://creativecommons.org/licenses/by-nc-nd/4.0/>).