Original Research

Transtibial Versus Anteromedial Portal ACL Reconstruction

Is a Hybrid Approach the Best?

Jonathan K. Jennings,* MD, Daniel P. Leas,† MD, James E. Fleischli,‡ MD, Donald F. D'Alessandro,‡ MD, Richard D. Peindl,† PhD, and Dana P. Piasecki,‡§ MD

Investigation performed at Carolinas Medical Center, Charlotte, North Carolina, USA

Background: Improved biomechanical and clinical outcomes are seen when the femoral tunnels of the anterior cruciate ligament (ACL) are placed in the center of the femoral insertion. The transtibial (TT) technique has been shown to be less capable of this than an anteromedial (AM) portal approach but is more familiar to surgeons and less technically challenging. A hybrid transtibial (HTT) technique using medial portal guidance of a transtibial guide wire without knee hyperflexion may offer anatomic tunnel placement while maintaining the relative ease of a TT technique.

Purpose: To evaluate the anatomic and biomechanical performance of the HTT technique compared with TT and AM approaches.

Study Design: Controlled laboratory study.

Methods: Thirty-six paired, fresh-frozen human knees were used. Twenty-four knees (12 pairs) underwent all 3 techniques (TT, AM, HTT) for femoral tunnel placement, with direct measurement of femoral insertional overlap and femoral tunnel length. The remaining 12 knees (6 pairs) underwent completed reconstructions to evaluate graft anisometry and tunnel orientation, with each technique performed in 4 specimens and tested using motion sensors with a quad-load induced model. Graft length changes and graft/femoral tunnel angle were measured at varying degrees of flexion.

Results: Percentage overlap of the femoral insertion averaged 37.0% ± 28.6% for TT, 93.9% ± 5.6% for HTT, and 79.7% ± 7.7% for AM, with HTT significantly greater than both TT ($P = .007$) and AM ($P = .001$) approaches. Graft length change during knee flexion (anisometry) was 30.1% for HTT, 12.8% for AM, and 8.5% for TT. When compared with the TT approach, HTT constructs exhibited comparable graft–femoral tunnel angulation (TT, 150° ± 3° vs HTT, 142° ± 2.3°; $P < .001$) and length (TT, 42.6 ± 2.8 mm vs HTT, 38.5 ± 2.0 mm; $P = .12$), while AM portal tunnels were significantly shorter (31.6 ± 1.6 mm; $P = .001$) and more angulated (121° ± 6.5°; $P < .001$).

Conclusion: The HTT technique avoids hyperflexion and maintains femoral tunnel orientation and length, similar to the TT technique, but simultaneously achieves anatomic graft positioning.

Clinical Relevance: The HTT technique offers an anatomic alternative to an AM portal approach while maintaining the technical advantages of a traditional TT reconstruction.

Keywords: ACL; transtibial; transportal; anatomic

A number of studies have demonstrated the importance of anatomic graft placement during anterior cruciate ligament (ACL) reconstruction, with biomechanical and clinical outcomes optimized when grafts are placed in the center of both femoral and tibial ACL insertions.[4,5,9,11,19,27,34,36] While a transtibial (TT) technique remains the most common femoral tunnel positioning technique worldwide, numerous publications have demonstrated how tibial tunnel constraint on the femoral drill guide prevents anatomic femoral tunnel positioning with this approach.[7,16,31,36] It is possible to modify a TT technique to achieve anatomic femoral tunnel positioning, but this requires short and/or posterior tibial tunnels and is much more technically challenging.[31]

§Address correspondence to Dana P. Piasecki, MD, OrthoCarolina Sports Medicine Center, 1915 Randolph Road, Charlotte, NC 28207, USA (email: dana.piasecki@orthocarolina.com).

*Southern Bone & Joint Specialists, Dothan, Alabama, USA.

†Department of Orthopaedic Surgery, Carolinas Medical Center, Charlotte, North Carolina, USA.

‡OrthoCarolina Sports Medicine Center, Charlotte, North Carolina, USA.

One or more of the authors has declared the following potential conflict of interest or source of funding: Arthrex donated 40 titanium screws in support of this study.

Ethical approval for this study was waived by Carolinas Medical Center.

The Orthopaedic Journal of Sports Medicine, 5(8), 2325967117719857
DOI: 10.1177/2325967117719857
© The Author(s) 2017

This open-access article is published and distributed under the Creative Commons Attribution - NonCommercial - No Derivatives License (http://creativecommons.org/licenses/by-nc-nd/3.0/), which permits the noncommercial use, distribution, and reproduction of the article in any medium, provided the original author and source are credited. You may not alter, transform, or build upon this article without the permission of the Author(s). For reprints and permission queries, please visit SAGE's website at http://www.sagepub.com/journalsPermissions.nav.

The anteromedial (AM) portal technique—in which the femoral drill guide is inserted through the medial portal to eliminate tibial tunnel constraint—has become a popular alternative to the TT approach as a result of these limitations. While allowing consistently anatomic femoral tunnel apertures,[14] this technique introduces new technical challenges. This occurs in part because even with flexible instrumentation the knee must be hyperflexed,[17] making it more difficult to obtain a familiar and consistent view of the lateral wall of the notch. Moreover, the transportal path and resultant horizontal trajectory of wire drilling and reaming with this technique increases the risk of articular cartilage damage, posterior cortical breakthrough, and critically short femoral tunnels, and makes graft passage more tedious.[6]

The juxtaposition of these 2 opposing techniques has left surgeons with a difficult choice: accept less anatomic femoral tunnel positions for an easier and safer surgery or risk greater difficulty to achieve an anatomic tunnel aperture. We have postulated that a combination of these 2 techniques—in which a flexible, transtibial guide wire is directed from the medial portal, without knee hyperflexion (Figure 1)—might not only allow maintenance of the easy, familiar, and reproducible elements of a TT technique but also provide femoral tunnel apertures as anatomic as an AM portal approach. In this cadaveric investigation, we sought to compare the performance of this hybrid transtibial (HTT) approach with that of both AM portal and TT techniques in positioning grafts at the center of the native ACL footprints. Our study (null) hypothesis was that no anatomic or biomechanical differences would be seen when comparing TT, AM portal, and HTT techniques.

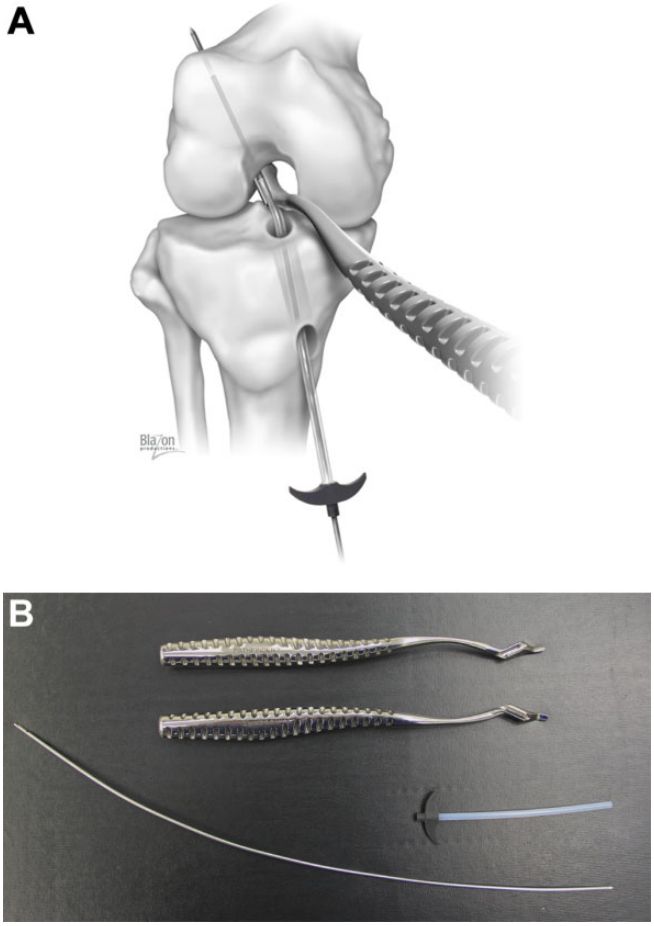

Figure 1. (A) Medial portal guidance of a flexible, transtibial guide wire obviates the need for hyperflexion. (B) This is made possible by use of a novel femoral drill guide (Pathfinder ACL Guide, DanaMed Inc). Shown are a pair of right and left guides along with flexible guide wire and sheath.

METHODS

A total of 36 paired, fresh-frozen, midfemur to midtibia human knees were acquired from the Anatomic Gifts Registry. All knees were subsequently thawed over 48 hours at room temperature and then used for 2 separate arms of investigation.

Insertional Overlap and Femoral Tunnel Length

In the first arm, 12 paired (6 right, 6 left) knees were used to directly measure femoral insertional overlap and tunnel length for each surgical technique. Each specimen was dissected free of soft tissues, with the exception of the joint capsule, popliteus, collateral ligaments, and extensor mechanism. Knees were examined to confirm the integrity of the ACL in all specimens, with the ligament then sectioned. The tibial and femoral ACL insertions were carefully dissected, their peripheries and centers marked.

The ACL femoral insertion was further characterized in each specimen by creation of a plastic template for each knee (Figure 2). This template was fashioned from a plastic ruler and trimmed to fit the precise dimensions of the ovoid femoral ACL footprint of each specimen. After osteotomizing the medial femoral condyle, each template was placed over its respective femoral insertion. Anterior, posterior, distal, and proximal reference marks were made on both the template and adjacent bone. These reference marks allowed for later referencing of the native anatomy after femoral tunnel reaming.

After anatomically reducing and pinning the medial femoral condyle, a standard TT tunnel was created in all specimens using a tibial tunnel starting point, as described by Morgan et al,[24] at the intersection of the pes tendons and anterior medial collateral ligament. From that starting point, a rigid guide wire was drilled through the center of the tibial ACL insertion and then overreamed with a cannulated, straight, fluted 10-mm rigid reamer.

After tibial tunnel reaming, femoral tunnels were created using 1 of 3 techniques:

1. *Transtibial technique:* With the knee maintained at 90° of flexion, a 7-mm over-the-top guide (Arthrex) was passed retrograde through the tibial tunnel to position a rigid guide wire on the femur. Once positioned around

Figure 2. Experimental setup for measurement of femoral tunnel length and insertional overlap. Custom plastic templates were created for each knee femoral insertion, and then used to directly measure femoral tunnel overlap. Shown is a right knee specimen (medial femoral condyle removed), with template applied after femoral tunnel reaming.

the posterior wall, the guide was maximally externally rotated to achieve the closest possible guide pin position to the center of the native ACL footprint. After drilling the guidewire through the distal femur and removal of the drill guide, the wire was overreamed with a 10-mm rigid acorn reamer, with care taken to advance the reamer to the lateral wall prior to reaming (to avoid any reaming of the back of the tibial tunnel).

2. *Hybrid transtibial technique:* A 7-mm offset Pathfinder ACL femoral drill guide (DanaMed Inc) was inserted through the standard medial portal. A flexible, sheathed nitinol guide wire (DanaMed Inc) was then passed separately through the tibial tunnel and into the open slot of the drill guide (see Figure 1). Once fully seated within the open slot, the drill guide was advanced to the lateral wall of the notch with the tip of the wire positioned as close as possible to the center of the femoral ACL footprint. The guide wire was then drilled through the distal femur using a standard motorized drill from outside the tibial tunnel (ie, TT drilling). Once drilling was complete, the sheath was slid off the wire, enabling the Pathfinder guide to be separated from the wire and withdrawn from the knee via the medial portal. A flexible 10-mm reamer (Stryker) was then passed over the wire to ream the femoral tunnel (ie, TT reaming). Drilling of the flexible guide wire and subsequent reaming over the wire was performed with the knee at 90° of flexion. As with the TT technique, care was taken to advance the reamer fully to the lateral wall of the intercondylar notch prior to reaming to prevent any reaming or bone removal from the posterior aspect of the tibial tunnel.
3. *Anteromedial portal technique:* A side-specific 7-mm offset AM portal drill guide (Stryker) was inserted through the medial portal and used to position a flexible guide wire as close as possible to the center of the native femoral footprint with the knee at 110° of flexion. With the knee maintained in this position, a 10-mm flexible reamer (Stryker) was then used to ream the femoral tunnel.

Prior to reaming, the length of the pilot femoral tunnel created by the guide wire was measured in each specimen, using the measured intraosseous length of the guide wire (lateral wall to lateral femoral cortex). After subsequent femoral tunnel reaming, the presence or absence of posterior cortical breakthrough was noted. The medial femoral condyle was then unpinned and retracted.

At this point, the femoral tunnel template for each knee was placed over the lateral wall of the notch and aligned with the previously marked osseous reference points. Overlap of the femoral tunnel aperture with this template was then marked on the template. Any misalignment (typically anteriorization) of the femoral tunnel aperture was measured with a ruler. ("Misalignment" was defined as the maximum distance of nonoverlapping portion of tunnel aperture from the central long-axis of the reamed femoral insertion, measured perpendicular to the axis.) The marked template was then taped to a flat sheet of paper and scanned to a PDF file. The percentage overlap of the area of the femoral insertion to the native ACL footprint was measured using AutoCad (AutoDesk) software. Comparison of percentage overlap and femoral tunnel lengths was performed with t tests, alpha set at .05, and P values less than .05 considered significant.

In order to allow multiple techniques to be performed within each knee, femoral tunnels were filled with epoxy after completion of the first femoral tunnel positioning technique. Marked bony landmarks (for template placement) were confirmed as intact, and the medial femoral condyle was then pinned back to the distal femur with Kirschner wires. For the first 6 knees, all 3 techniques were performed in this way. Subgroup analysis at that point demonstrated a significant difference between TT and both of the AM and HTT techniques. To simplify further analysis—and minimize the effect of repeated femoral tunnel drilling—only the AM and HTT techniques were performed in the remaining 6 knees, thus providing 6 total TT femoral tunnels, 12 AM femoral tunnels, and 12 HTT femoral tunnels. The order of technique was varied such that an equal number of knees were drilled first, then second (and third, where applicable) with each approach. Laterality was also varied such that an equal number of right and left knees were represented within each technique.

Femoral Tunnel-Graft Angle and Graft Length Changes

Eight pairs of fresh-frozen cadaveric knees (midfemur to midtibia) were originally obtained for this arm of the study. Approximately 7.5 cm of soft tissue was removed to the bone from the proximal femur and distal tibia to

allow potting of the proximal and distal ends of each specimen into PVC (polyvinyl chloride) tubing (5-cm inner diameter × 7.5-cm depth) with fast-drying epoxy. All specimens were then arthroscopically examined to rule out prior ACL injuries. One pair of knees was excluded due to visualization of a partial ACL tear. From the remaining pairs of specimens, 6 pairs were separated into 3 groups of 2 matched pairs each. The groups were determined by attempting to best match each group in terms of size distribution (ie, by length and weight of each pair). One pair of knees was used to troubleshoot various procedures during protocol development.

The anterior surface of the thigh was opened, and the quadriceps tendon was separated from the vastus lateralis and medialis. All other musculature and the knee joint capsule were left intact. A section of nylon webbing (2.5 cm × 1 m) was sutured to the quadriceps tendon for the purpose of applying an extensor load to the knee. Next, 3 randomly located and oriented sensor trunnions were installed in both the femur and the tibia of each specimen in tapped holes created through stab wounds between the potted ends of each bone and the knee capsule. These trunnions remained in place through the entirety of the experimental protocol. The trunnions consisted of $\frac{3}{8}$ inch 16 nylon socket head cap screws (3.3 cm long with 1.1-cm shoulder) with a centrally drilled 2-mm hole to a depth of 18 mm. Trunnions were installed to ensure tight impingement at the shoulder, and impingement was checked in each case when sensors were reinstalled for testing. This allowed each cylindrical magnetic sensor to be initially positioned and accurately relocated at the bony surface at each trunnion location throughout a series of alternating kinematic tests and surgical procedures when specimens and sensors were uninstalled and reinstalled in the test fixture.

Experimental Setup and Specimen Instrumentation

Specimens were installed in a custom nonmagnetic load frame with the femur horizontal and the knee in 90° of flexion. A 1-kg nylon weight (ie, approximately the weight of a human foot) was positioned at the end of each tibia at 27 cm from the mean medial-lateral joint center of the knee. The weight produced a flexion moment of approximately 2.65 N·m at the center of all knees at full extension. The webbing, attached to the quadriceps tendon, was loaded by means of a pulley system and a voltage-controlled pneumatic cylinder such that knee extension could be manually controlled.

An 8-channel 3D Guidance trakSTAR electromagnetic tracking system (Ascension Technology Corp) was used to monitor knee kinematics during dynamic flexion/extension testing of each knee for intact knees, ACL-deficient knees, and knees with ACL reconstruction using 1 of the 3 reconstruction techniques. For testing, 3 magnetic sensors (Ascension Technology Corp; Model 180) were inserted in the 3 marker trunnions in the femurs and tibias. These marker triads were used to establish local origins and orthogonal axis systems for each of the femurs and tibias with regard to the trakSTAR global tracking coordinate system. During the test protocol, additional data establishing ACL footprints or graft tunnel inlets and outlets were collected using a sensor-instrumented carbon fiber stylus and a sensor-instrumented carbon fiber rod, respectively. These data were always collected with regard to the local coordinate system for each bone. Once the location of the ACL footprint and the tunnel endpoints were established in each bone local coordinate system, these data points could then be followed during dynamic testing by using local system data transformed into the trakSTAR global coordinate system, to ultimately assess graft length changes and graft-tunnel angulation.

Kinematic Testing and Surgical Protocol

Once specimens were instrumented, kinematic data were collected while the knee was extended from 90° to 10° of flexion over approximately 10 seconds in 3 trials. ACLs were then removed using a scalpel through a medial arthrotomy approximately 7.5cm long. Femoral ACL footprints were then outlined by a sports medicine fellowship–trained orthopaedic surgeon and, subsequently, digitized using an instrumented stylus using the trakSTAR system. The arthrotomies were closed with sutures, and the knee was dynamically tested again in 3 trials in flexion-extension to the prescribed limits. Ten-millimeter-wide bone–patellar tendon–bone autografts were then harvested from each specimen for use in reconstruction of their respective ACLs. Knee and graft specimens were then frozen to −20°C to await surgical reconstruction.

After thawing at room temperature, all knees were reconstructed in a vivarium operative suite using standard arthroscopic tools and equipment (Stryker). As previously implied, for consistency, all repairs used 10-mm-diameter femoral and tibial tunnels. Each approach (TT, AM, and HTT) was then used to reconstruct a group of 4 specimens. After reconstruction, each knee was reinstrumented and dynamically tested again in flexion-extension as previously described.

After testing was completed, each knee was disarticulated and stripped of soft tissue. A 10-mm-diameter instrumented tunnel probe with sensors at the tip and rear was inserted in each tunnel up to the center of each tunnel inlet into the joint space. Sensors were also inserted into the bone trunnions, and all 5 sensors were scanned together. From these scans, tunnel inlet locations and orientations were determined with regard to each bone's local origin and coordinate system. These data were tabularized for use in the global kinematic analyses of each knee.

Data Analysis

Digitized femoral ACL footprint data were converted into best-fit ellipses, and the distance from the center of each ellipse to the femoral tunnel inlet as obtained by the tunnel probe was calculated. These center-to-center offset differences were compared for each reconstruction technique. Tibial trunnion triad kinematic data for tibial extension were used to calculate the movement of the tibial coordinate system origin and the orientation with respect to the

trakStar global coordinate system. Tabularized data for tibial tunnel endpoints with regard to the local coordinate system were then transformed into the global coordinate system. Similar transformations were performed for the unmoving femoral tunnel. In this way, change in graft length and included angles between the graft and both femoral and tibial tunnels were calculated versus knee flexion angles, and these data were averaged for each group by reconstruction technique.

RESULTS

An intact ACL was confirmed in all tested specimens. The average tibial tunnel length measured 42.3 ± 2.3 mm, and in no knee was there any visualized posteriorization of the tibial tunnel aperture after femoral tunnel reaming. Tibial tunnel-graft angulation was not significantly different for any of the reconstructions (mean ± SD: AM 152° ± 7°, HTT 149° ± 4°, TT 156° ± 5°; TT vs HTT, $P = .3$, TT vs AM, $P = .6$, HTT vs AM, $P = .8$).

Insertional Overlap and Femoral Tunnel Length

Femoral guide pin distance from the center of the femoral insertion was significantly greater for TT (mean ± SD: 10.0 ± 5.1 mm vs 2.1 ± 1.9 mm for AM [$P = .02$] and 1.0 ± 0.2 mm for HTT [$P = .02$]), while AM and HTT pin positions were equally close to the center of the femoral insertion ($P = .89$). Percentage overlap of the reamed tunnels with the original native ACL footprint was greatest with HTT (93.9% ± 5.6%; vs 79.7% ± 7.7% for AM, $P = .001$; vs 37.0% ± 28.6% for TT, $P = .007$). There was a trend toward greater overlap with AM versus TT ($P = .05$). The extension of femoral apertures shallow to the distal border of the native femoral insertion averaged 5.5 ± 1.2 mm for TT tunnels, 2.0 ± 1.2 mm for AM, and 0.2 ± 0.5 mm for HTT. This degree of anteriorization was significantly greater with both TT (vs HTT, $P = .002$) and AM (vs HTT, $P = .001$) and trended toward significance for TT vs AM ($P = .05$).

Femoral tunnel length was not significantly different for TT and HTT (TT, 42.6 ± 2.8 mm vs HTT, 38.5 ± 2.0 mm; $P = .12$), although the AM portal tunnels were significantly shorter (31.6 ± 1.6 mm; vs HTT, $P = .001$; vs TT, $P = .002$). Posterior (intratunnel) cortical breakthrough was noted in one of the AM femoral tunnels, but in none of the TT or HTT tunnels (Figure 3).

Femoral Tunnel-Graft Angle and Graft Length Changes

The mean angle created by the graft and the femoral tunnel—over all flexion angles—was 150° ± 3° for TT, 142° ± 2° for HTT, and 121° ± 7° for AM. Relative to a line connecting the center of the tibial and femoral tunnels, this represented a graft deviation angle of 30° ± 3° for TT, 38° ± 2° for HTT, and 59° ± 7° for AM portal. These angulation differences were significant across all flexion angles for each of the 3 techniques (TT vs HTT, $P = .01$; TT vs AM, $P < .0001$; HTT vs AM, $P = .003$) (Figure 4).

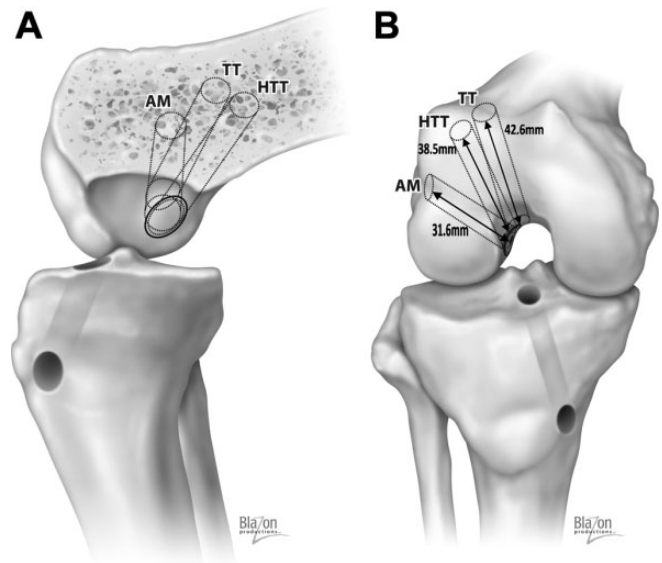

Figure 3. (A) Hybrid transtibial (HTT) femoral tunnels overlapped more than 90% of the native femoral insertion, slightly greater than anteromedial (AM) portal tunnels (roughly 80% overlap), which were more circular and slightly anteriorized. Transtibial (TT) tunnels were high on the notch and averaged roughly 40% overlap of the native insertion. (B) Femoral tunnel lengths were significantly shorter for AM portal tunnels than for either HTT or TT.

Between 10° and 90° of flexion, graft constructs exhibited an overall increase in graft length (anisometry) of 8.5% for TT, 12.8% for AM portal, and 30.1% for HTT. These differences were not significant at any knee flexion angle for TT or AM, although significantly greater anisometry was seen for HTT constructs at all knee positions except 70° (whereas AM and HTT were not distinguishable, $P = .08$) (Figure 5).

DISCUSSION

This study demonstrated that a hybrid transtibial technique—using medial portal guidance of a flexible, transtibial guide wire without knee hyperflexion—achieved anatomic femoral tunnel positioning while maintaining many of the perceived technical benefits of a traditional transtibial technique. While avoiding the need to hyperflex the knee, the HTT constructs consistently positioned the femoral guide pin within 1 mm of the center of the femoral insertion (1.0 ± 0.2 mm vs 2.1 ± 1.9 mm for AM, $P = .89$; and 10.0 ± 5.1 mm for TT, $P = .02$) and created apertures with greater insertional overlap (93.9% ± 5.6%) than both AM portal (79.7% ± 7.7%, $P = .001$) and TT (37.0% ± 28.6%, $P = .007$). Grafts fixed within the HTT tunnels exhibited a level of anisometry (30.1% vs 12.8% for AM and 8.5% for TT) that was more consistent with the published behavior of grafts placed in the center of the femoral insertion. Additionally, the femoral tunnels created with HTT were similar in length, integrity, and orientation to TT tunnels. These findings are clinically relevant

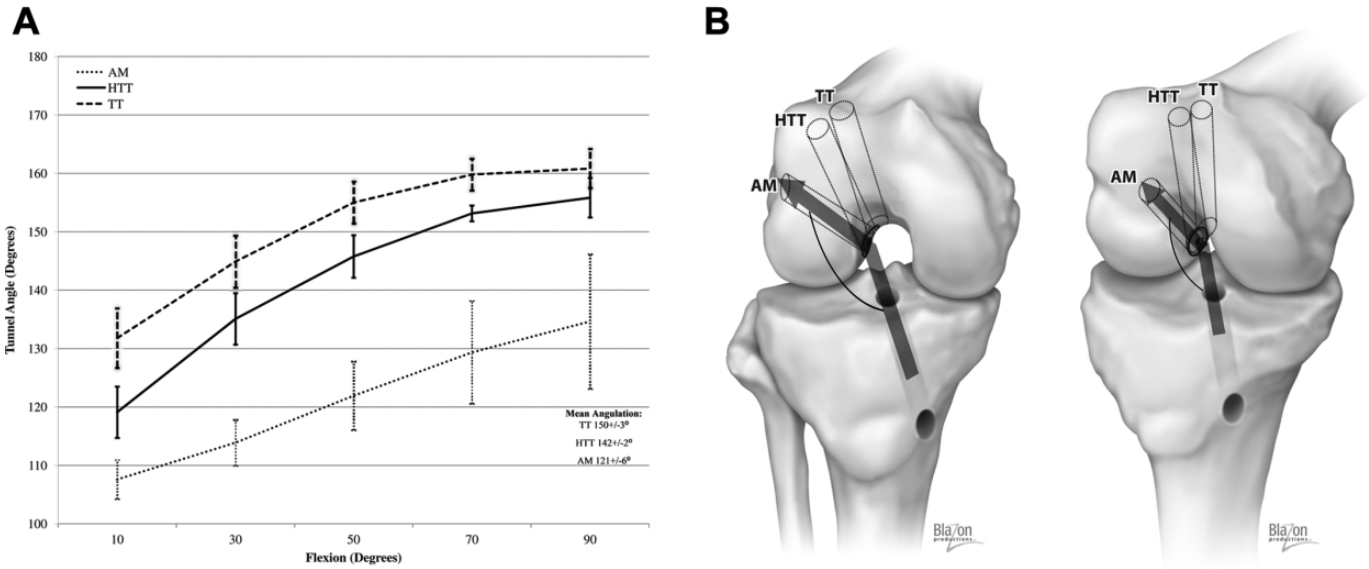

Figure 4. (A) Significant differences were seen across all tested flexion angles for all 3 techniques. Transtibial (TT) and hybrid transtibial (HTT) differed by roughly 8°, while anteromedial (AM) portal femoral tunnels were 20° to 30° more angulated (relative to a straight line trajectory). (B) These angulation differences are represented schematically (left, lateral portal view; right, medial portal view). Anterior cruciate ligament grafts placed with an AM portal technique deviated much more from a linear path.

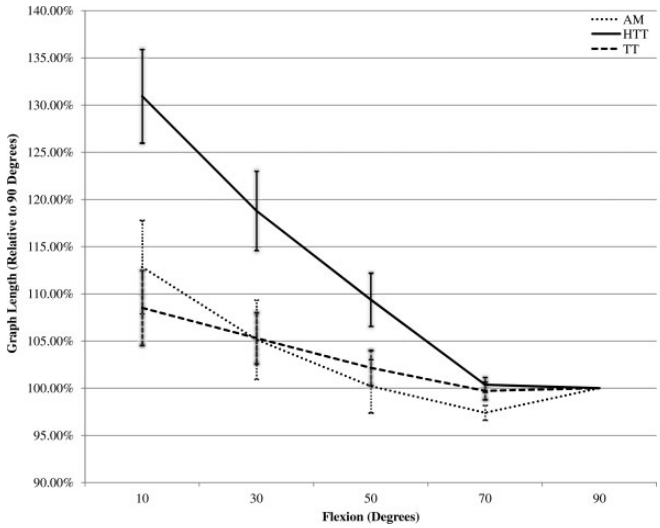

Figure 5. Graft anisometry. Hybrid transtibial (HTT) reconstructions demonstrated anisometric behavior that closely mirrors what has been reported for anatomically placed grafts. The level of anisometry with these constructs was significantly greater than both anteromedial (AM) portal and transtibial (TT constructs).

because a growing body of research has suggested the importance of consistently placing the femoral tunnel aperture at the center of the femoral ACL footprint, yet doing so can be challenging with current surgical techniques.

It has become increasingly clear that even minor changes in femoral graft position can significantly affect postsurgical outcome. Kondo et al[19] demonstrated that—with the same centered tibial tunnel aperture—a femoral tunnel placed in the upper half of the femoral insertion was not rotationally distinguishable from an ACL-deficient knee. By contrast, a graft placed in the center of the femoral insertion—only 3 to 4 mm lower on the notch wall[20]—normalized anterior and rotational stability, a finding duplicated in several other cadaveric studies.[10,18,36] Clinically as well, centered femoral tunnel apertures appear to improve both stability and clinical outcome measures in prospective cohort and randomized controlled trials.[27,34] These findings have encouraged surgeons to position femoral tunnels as close as possible to the center of the native femoral insertion.

Unfortunately, the most common current surgical techniques have significant limitations in achieving this. The TT technique remains the most common femoral tunnel positioning technique worldwide, for a number of sound, often overlooked reasons. Apart from its familiarity, instrumenting through the tibial tunnel allows the knee to remain at 90° of flexion throughout the operation, which simultaneously obviates the need for an assistant to reposition the leg and provides the most expansive and reproducible arthroscopic view of the intercondylar notch. Additionally, drilling and reaming through the tibial tunnel provides an element of safety, in that the reamer cannot cause damage to the articular cartilage along this path. The femoral tunnel created is also closely aligned with the tibial tunnel, making graft passage easy while avoiding any killer turn for the graft. Finally, the TT femoral tunnel is regularly of adequate length and integrity.[31] The principal drawback of a TT technique is that tibial tunnel constraint on the femoral drill guide prevents anatomic femoral tunnel aperture positioning unless the tibial tunnel aperture is posteriorized or the tibial tunnel starting point is made very close to the joint line, resulting in a critically short

tibial tunnel.[6,16,31] If a consistently usable tibial tunnel and anatomic tibial tunnel aperture are prerequisites, it is unlikely that a TT technique will achieve overlap of more than the upper 50% of the femoral insertion,[31] a tunnel position shown rotationally inferior by Kondo et al[19] and others.[10,18] While a number of highly skilled surgeons have reported good to excellent clinical outcomes with a TT technique,[1,2] the literature suggests that better results may be achieved with improved aperture positioning.

The most commonly performed TT alternative—an AM portal approach—solves the aperture problem of a TT technique by passing the femoral drill guide through the medial portal to eliminate tibial tunnel constraint. While this technique allows consistently more anatomic femoral apertures,[14] it sacrifices many of the benefits of a TT technique. For instance, even with flexible instrumentation, the knee needs to be hyperflexed to create the safest guide wire trajectory and an aperture shape that most closely mimics the native ACL insertion.[17] Unfortunately, hyperflexion significantly limits visualization of the intercondylar notch and is associated with an increased risk of posterior wall blow-out.[6] Furthermore, the passage of the reamer from the medial portal to the intercondylar notch can damage the articular cartilage of the medial femoral condyle. Finally, the more horizontal trajectory of the guide wire—because it passes through the narrower width of the lateral femoral condyle—will result in a much shorter femoral tunnel[6] that is angulated significantly from the normal path of the ACL, increasing the risk of graft-tunnel mismatch and making graft passage more challenging.

That these 2 techniques have directly opposing pros and cons presents surgeons with a difficult trade-off: accept some loss of potential outcome for an easier and potentially safer technique, or accept a more challenging approach with a higher risk of complication to achieve a more anatomic femoral tunnel position. Ideally, the benefits of both techniques could be combined into a single approach, but doing so requires an understanding of each approach's drawbacks. In the case of the TT technique, the primary limiter is tibial tunnel constraint on the femoral drill guide. Likewise, the AM portal approach is hampered by too much having to be done exclusively through the medial portal. The concept of a "hybrid transtibial technique" involves the separation of femoral drill guide from guide wire, with the guide wire remaining within the tibial tunnel—along a transtibial trajectory—but directed by a drill guide inserted separately through the medial portal, thus eliminating tibial tunnel constraint. We theorized that this type of approach might allow anatomic positioning of the femoral guide wire, while maintaining all the other benefits of a TT technique, since the knee could remain at 90° of flexion and the transtibial path of the wire, reamer, and graft would be largely preserved.

To make this technique possible, we developed a novel femoral drill guide that could capture a separately inserted TT guidewire and direct it along an anatomic path (Pathfinder ACL Drill Guide, DanaMed Inc) (see Figure 1). In this investigation, we compared the ability of standardized TT, AM portal, and HTT techniques (using this new femoral drill guide) to position a workable femoral tunnel in the center of the native femoral insertion.

With the goal of achieving centered femoral tunnel apertures for each technique, we found that the HTT achieved consistent placement of the femoral tunnel aperture at the center of the native femoral insertion. This was demonstrated by highly consistent, anatomic positioning of the femoral guide wire (1.0 mm vs 2.1 mm for AM and 10.0 mm for TT) and near-complete femoral insertional overlap that exceeded that of both AM portal and TT approaches (93.9% vs 79.7% for AM and 37.0% for TT) (see Figure 4). This performance for both AM portal and TT is consistent with that of other studies,[14,31] further confirming the anatomic limitation of a traditional TT and the aperture advantage of an AM portal approach. Likewise, the consistent positioning of the HTT guide wire in the center of the native insertion and the high degree of resulting insertional overlap is consistent with idealized results after an AM portal technique.[17] The increased overlap seen with HTT versus AM portal in our study—despite similar overall guide wire positioning—may reflect the slightly more oblique angle of approach that the reamer takes when following a transtibial path versus the more perpendicular approach of a transportal reamer. We noted—as have other authors[14,17]—that the more perpendicular approach of the reamer with the AM portal knees resulted in more circular tunnel apertures that miss the upper and/or lower portions of the native insertion and can result in slightly more shallow aperture positions. This effect was not typical in the more oval apertures of HTT femoral tunnels. While increased insertional fill has been associated with improved clinical stability,[32] it is not clear that the statistical difference seen between AM portal and HTT approaches (79.7% vs 93.9% overlap) is clinically relevant. It is probable, however, that both techniques outperform the traditional TT approach used in this study, and each has the capacity for creating femoral tunnel apertures centered on the native femoral footprint. It is likely that surgeons performing this HTT technique can expect femoral tunnel positioning at least as good as that accomplished with AM portal techniques, and potentially with slightly greater insertional overlap. While we can only speculate as to the clinical implications of this, the literature suggests that both HTT and AM portal approaches would likely have comparable outcome benefits.[27,32,34]

Our findings also suggest greater consistency with the HTT technique. While the *potential* for anatomic femoral tunnel positioning with an AM portal approach has been well described, the greater freedom of drill guide movement and the impact of small differences in knee flexion angle[17] may lead to greater variability in guide wire positioning. This did appear to be the case in our specimens, with guide wire position deviating from the center of the femoral insertion up to 4 mm in the AM portal knees—similar to the findings of Gadikota et al[14]—while guide wire position deviated $\leq$1 mm from the femoral insertional center in all HTT specimens. Given the normal dimensions of the ACL femoral insertion,[31] this degree of variability in the AM portal knees would be expected to occasionally

result in tunnel positions no better than a traditional TT technique.[10,18,19,31]

It is also notable that AM portal tunnels tended to be shallower in position than the native insertion, a finding that was not present in the HTT reconstructions, and could reflect the more circular aperture shape created with this technique. Indeed, Gadikota et al[14] noted 13.6% ± 15.7% of AM portal femoral tunnel apertures extended evenly both deep and shallow to the respective margins of the femoral footprint. We would also speculate that differences in notch morphology in hyperflexion—whereby a standard 7-mm offset may not necessarily correlate with the center of the ACL insertion—could be relevant for an AM portal technique. While the center of the femoral footprint is a well-conserved distance from the posterior wall when measured with the knee at 90° of flexion (ie, where the axis of measurement is essentially parallel with the long axis of the femur),[31] this distance would be expected to change if measured from different points on the posterior wall and/or at different angles relative to the femoral shaft. Both of these factors would be expected to change when the knee is hyperflexed, and the degree of their influence would likely be affected by the amount of hyperflexion.[17] Because hyperflexion is required of a reproducible AM portal technique[17] and is difficult to standardize during surgery, this introduces an inherent level of variability with this surgical approach. Combined with the greater freedom of movement of the AM portal drill guide itself, we feel this increased variability resulting from knee hyperflexion may explain why several of the AM apertures in this study were seen to deviate into the posterior half of the native ACL insertion with extension beyond the posterodistal border of the footprint. While further clinical study would be required to demonstrate the clinical implications of this shallower tunnel position, one might expect some flexion-induced strain on grafts positioned in this manner. By avoiding hyperflexion and simultaneously achieving highly consistent, anatomic guide wire positioning without shallow aperture positioning, the HTT approach appears to avoid this issue.

Our graft-length change data also appeared to support the finding that HTT reliably positions the femoral tunnel in the center of the femoral insertion. It is well established that the central aspect of the normal ACL is not isometric, the distance between the centers of femoral and tibial insertions increasing when the knee is extended from a flexed position because of a change in the center of rotation of these bony locations during flexion.[21] Fujimaki et al[13] demonstrated that in an ACL-intact state, the distance from the center of both insertions increases up to 27.8% (6.8 mm) when the knee is extended from 90° and the tibia loaded anteriorly. Nawabi et al[26] reported similar findings, with centrally placed graft fibers lengthening 23.7% during flexion versus only 10.9% for grafts placed in the upper half of the insertion. Other authors have noted similar lengthening (7.6 ± 2.01 mm,[35] 5.9 mm[30]) of graft fibers placed in the center of both ACL insertions. Robinson et al[33] demonstrated in a cadaveric navigation model that the degree of length change in the intact ACL—and in centrally positioned grafts—is not well described by an average of the AM and posterolateral (PL) bundles. While we found that the central aspects of both AM and PL bundles behaved similar to that noted by the other studies,[13,30,35] the large majority of fibers making up the ligament/graft are anisometric, and the central portion of the ligament/graft demonstrated a level of anisometry (6 mm length change) only slightly less than the center of the PL bundle (7 mm length change). Despite traditional recommendations that the ACL graft be placed in an isometric position,[23] which corresponds to femoral tunnel positions that overlap with only the anterior portion of the native femoral footprint,[25] these findings support the concept that grafts placed in the center of the native femoral insertion will have a degree of anisometry slightly less than or equal to that of the PL bundle, with an expected length change in the range of 5 to 8 mm.[13,22,26,33,35] Indeed, cadaveric study has confirmed that grafts placed centrally in the femoral insertion—presumably with the above level of anisometry—restore more normal kinematics than do those placed in isometric positions.[25]

Our investigation—using a model comparable to that of Fujimaki et al[13]—found a similar mean 30.1% length change over the same range of motion for the HTT knees. Assuming the same resting ACL length as in the study by Fujimaki et al, this would correspond to 7.5 mm of central lengthening, within the range reported in the previously cited studies for the central fibers of the intact ACL and for grafts placed at the centers of both tibial and femoral insertions. This conclusion is further supported by the other anatomic data we report (ie, high uniformity of anatomic femoral pin positioning with the HTT technique [within 1 mm in all knees], and >90% femoral insertional overlap). While we concede that no perfect amount of anisometry has been defined in the literature, we feel the available data provide ample evidence that graft anisometry at the level seen in the HTT grafts is more anatomic than the behavior of the other grafts in our study (12.5% length change for AM portal, 8.5% for TT). Provided the goal of ACL reconstruction is to most closely reconstitute the normal ACL—and given the previously cited studies supporting the advantages of this graft position in doing so—we speculate this similarity is a positive one, and at minimum it helps confirm that HTT graft positioning was consistent with the center of the femoral insertion in this study.

It is not entirely clear why AM portal reconstructions (12.5% length change) did not demonstrate higher levels of anisometry in our results, given apertures that were similar to HTT knees. It is possible the small differences in deep-shallow femoral aperture position and/or femoral tunnel obliquity between these 2 techniques may have explained some of the differences, as other authors have suggested.[12] We also feel it is possible that factors unrelated to either technique played a role in the anisometry data. One potential explanation for the difference in graft-length change between HTT and AM portal knees is that grafts may have tended to occupy slightly different locations within the respective tunnels for these 2 techniques. For instance, the greater isometry of the AM portal grafts could be explained by some anteriorization of the graft on the femur, because the femoral interference screw is inserted in hyperflexion with this technique and may have tended to occupy a lower (more posterior) position within

the femoral tunnel (ie, pushing the graft more anteriorly). Additionally, Smith et al[35] noted that the least isometric position for ACL graft fibers is the one centered on the femoral insertion but resting in the posterior aspect of the tibial insertion. It is relevant that our method of tibial-sided graft fixation in this study was to place interference screws in the anterior aspects of each tibial tunnel (ie, potentially pushing some of the grafts posteriorly within the tibial tunnel). It is possible some of the variability seen between AM portal and HTT knees (and within each technique group) could be explained by grafts being posteriorized by the anteriorly placed interference screws in this way, particularly feasible in osteoporotic cadaveric bone. We feel this particular effect could also explain why other authors have described some increased anterior tibial translation in knees with centered tunnels[10] (ie, grafts placed anatomically on the femur but sitting more posteriorly within the tibial insertion would be expected to eliminate some of the AM bundle's resistance to anterior tibial translation).

It is important to note that the ideal amount of ACL graft anisometry—and for that matter, the perfect graft position—has not yet been established. While the bulk of the current literature supports better results with single-bundle grafts positioned in the middle of both insertions, it is not yet clear that the anisometry associated with this graft position—despite being similar to the native ACL—is desirable. While a recent long-term follow-up study suggests even abnormally increased graft lengthening may be very well tolerated clinically,[15] recent reports imply that even better graft function might be achieved by choosing femoral tunnel positions prioritized less on the geometric center of the femoral insertion and more on a "functional" center where the most important elements of the ligament exist.[26,37] For the purposes of our study results, it is important to note that our investigation was never intended to endorse one graft position over another—only to evaluate HTT, AM portal, and TT abilities to position grafts in the best way the literature currently suggests. As noted above, the sum of our anatomic data—including the anisometry profiles—support a high capacity for the HTT technique to achieve that goal alone. Nonetheless, we would speculate that, given the anatomic hurdles both AM and HTT overcome to achieve anatomic guide wire positioning, both techniques would likely be comparably good at positioning grafts in any desired portion of the femoral insertion.

While providing highly consistent, anatomic femoral tunnel apertures and graft behavior consistent with anatomic graft placement, our findings also show that the HTT technique preserves many of the advantages of a traditional TT technique. Femoral tunnel length, for example, was very similar with both HTT and TT, versus the much shorter AM portal tunnels (see Figure 4). It is notable that all techniques in this study utilized long tibial tunnels with anatomic tibial apertures. The combination of long, workable femoral *and* tibial tunnels distinguishes the HTT approach from other TT alternative techniques that achieve anatomic femoral apertures only by sacrificing one tunnel for the other. A modified TT technique,[31] for instance, can achieve an anatomic femoral aperture only by significantly shortening the tibial tunnel (or posteriorizing its aperture). Likewise, an AM portal technique can achieve anatomic femoral placement, but with the drawback of shortening the femoral tunnel.[6] Preserving long tunnels on both sides of the joint—a key advantage of a traditional TT approach—represents a shared positive feature of the HTT, as this would be expected to minimize the graft-tunnel mismatch and fixation concerns that accompany the shorter tunnels of an AM portal technique.[6]

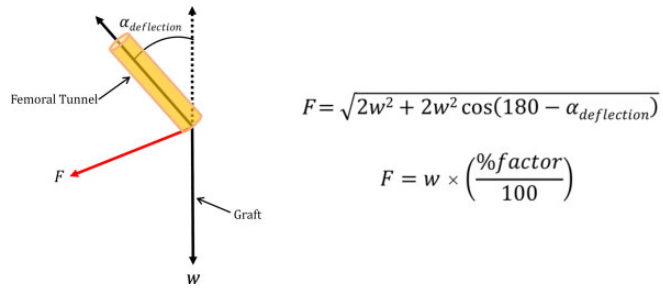

Figure 6. Graft angulation. Deflection of a tensioned structure will increase the force on that structure at the site of its deflection, the magnitude, and percentage increase predicted by the amount of tension and the degree of angulation (formula above). This phenomenon is analogous to an anterior cruciate ligament graft being tensioned at the aperture of the femoral tunnel. Relative to the transtibial tunnels, the increased angulation in the anteromedial portal knees would be predicted to increase this force by 98.3% (29° increase in angulation) versus 27.6% (8° increase in tunnel angulation) for hybrid transtibial knees. F = resultant force at the site of deflection; w = initial tension; $\alpha_{deflection}$ = angle of deviation from straight-line pull.

HTT also maintained a comparably favorable degree of femoral tunnel-graft angulation (see Figure 5), which would be expected to make graft passage of similar ease as with TT. By contrast, the AM portal approach resulted in femoral tunnels that were much more angulated in the coronal and sagittal planes. In addition to increasing the difficulty of graft passage, increased femoral tunnel angulation would be expected to increase the amount of force applied to the graft at the shallow and anterior edge of the femoral tunnel aperture during knee range of motion. As noted in Figure 6, the greater the degree of deflection of the graft, the greater the predicted force on the graft at the tunnel aperture as it is stretched over this bony edge. While we did not measure graft force directly in this study, the forces created by the tunnel angulations seen in this study would be predicted to nearly double the forces seen in the AM portal constructs (vs TT grafts). It is not yet clear that the degree of graft-tunnel angulation seen with AM portal reconstructions has any implications for graft survival in a clinical setting, although the effect of femoral tunnel orientation has recently been recognized as significant biomechanically. Ebersole et al[12] demonstrated in a cadaveric model that, with the same anatomic femoral tunnel aperture, the increased femoral tunnel angulation associated with an all-epiphyseal technique tripled graft strain relative to TT and AM constructs. Further study is needed to

determine if lesser degrees of femoral tunnel obliquity affect graft survival and/or performance.

Finally, the HTT allows the knee to remain at 90° of flexion throughout the technique and preserves a transtibial path for the wire, reamer, and graft. As is the case with a traditional TT approach, these technical elements would be expected to improve intraoperative visualization and ease of drilling and reaming, while maintaining a low risk of complication.

This investigation is limited in a number of ways. We elected to use the same, well-recognized distal tibial tunnel starting point[24] for all specimens to standardize the effect of tibial tunnel constraint and establish a prerequisite of consistently long and workable tibial tunnels for all three techniques. We felt this was a reasonable baseline requirement because tibial tunnel compromise is a recognized limitation of a modified transtibial technique[31] and the degree of tibial tunnel compromise necessary to achieve the same level of anatomic femoral tunnel positioning as has been published for an AM portal technique[14] was not felt to be clinically practical.[7] Nonetheless, it is likely a more proximal tibial tunnel starting point for the TT knees would have enhanced the performance of that technique, and our data should not be interpreted as the best that a TT technique can achieve. Likewise, our AM portal technique utilized a standard offset guide that might not be representative of an AM portal approach using other commercially available guides. While there is no established way to measure femoral tunnel overlap with the native femoral insertion—particularly given difficulty in defining the edges of the insertion with imaging modalities—our direct measurement technique using specimen-specific templates and marked landmarks would be expected to have more variability than a digitizer, as has been used by other authors.[31] This direct measurement approach was designed specifically to allow sequential femoral tunnels to be drilled in the same knee, and while we feel it accurately demonstrated tunnel aperture differences between the 3 tested techniques, we recognize that this particular technique may be less accurate than others described in the literature. Another limitation is the absence of formal measurement of tibial insertional overlap. We chose not to add this additional measurement to the study protocol because Piasecki et al[31] have demonstrated that a 10-mm reamer drilled over a guide wire from our chosen tibial tunnel starting point to the center of the tibial insertion corresponds with anatomic overlap with the native tibial insertion, and gross inspection of the tibial tunnel apertures in our specimens (relative to the marked boundaries of the tibial insertion) were consistent with those findings. Additionally, among the knees tested with the trackStar motion tracking system, the data files for one of the AM portal knees was lost, limiting our AM portal data in that category to 3 knees. While gross inspection of the fourth specimen suggested consistency with our overall study results—and the absence of these data does not alter our overall conclusions—our overall graft length change and tunnel angulation data set is less complete than originally intended. As noted earlier, with the small number of specimens tested, the differences seen in graft isometry between the 3 reconstructive techniques could reflect factors unrelated to the techniques themselves. In particular, it is possible that differences in graft position within the given tunnels (ie, greater isometry for grafts pushed by the interference screws to the anterior aspect of their femoral tunnels, and increased anisometry for those pushed posteriorly on the tibia) could explain some of the anisometry findings, and this factor was not evaluated in this investigation. Recognizing that no cadaveric model can perfectly simulate the live knee, our particular model—while representing an established method of assessing ligament kinematics[3,28,29] and providing the information we sought to obtain—cannot comment on all the kinematic features of normal knee function and did not assess translational or rotational stability, as some authors have.[8] Finally, while our findings suggest HTT may represent a favorable balance between both AM portal and TT approaches, our cadaveric model only assessed the ability of the 3 tested techniques to achieve the goal tunnel position, not whether that particular position is itself ideal. While we think it likely that grafts placed in the center of the femoral insertion with the HTT technique would perform similar to what has been published on grafts placed in this position with other techniques,[18,19,27,34] we can only speculate as to the potential clinical implications of this new approach.

CONCLUSION

ACL reconstruction using a TT technique is easier and more familiar, but it is limited by nonanatomic femoral tunnel positioning. An AM portal approach can achieve more anatomic femoral tunnel positioning, but it is more variable, technically challenging, and carries an increased risk of complication. In this study, the HTT technique—using medial portal guidance of a TT guide wire without knee hyperflexion maintained the many technical benefits of a traditional TT technique, while also achieving highly anatomic femoral tunnel apertures. Grafts positioned with this technique also appeared to behave more like a centered ACL graft than AM portal and TT constructs, although further study is needed to determine the ideal level of graft anisometry and the role that intratunnel graft positional differences may play. By combining the primary benefits of both AM and TT but simultaneously removing their most significant drawbacks, the HTT technique provides a familiar, reproducible way of achieving long and anatomically positioned tunnels on both sides of the joint and may represent a positive evolution of both techniques.

ACKNOWLEDGMENT

The authors thank the staff of OrthoCarolina Research Institute for study administration (Amy Roznowski and Caryn Thompson), proofreading, and statistical review (Bryce A. Van Doren).

REFERENCES

1. Bach BR Jr, Aadalen KJ, Dennis MG, et al. Primary anterior cruciate ligament reconstruction using fresh-frozen, nonirradiated patellar tendon allograft: minimum 2-year follow-up. *Am J Sports Med*. 2005;33:284-292.

2. Bach BR Jr, Levy ME, Bojchuk J, Tradonsky S, Bush-Joseph CA, Khan NH. Single-incision endoscopic anterior cruciate ligament reconstruction using patellar tendon autograft. Minimum two-year follow-up evaluation. *Am J Sports Med*. 1998;26:30-40.
3. Barnes CL, Blaha JD, DeBoer D, Stemniski P, Obert R, Carroll M. Assessment of a medial pivot total knee arthroplasty design in a cadaveric knee extension test model. *J Arthroplasty*. 2012;27: 1460-1468.e14.
4. Bedi A, Maak T, Musahl V, et al. Effect of tibial tunnel position on stability of the knee after anterior cruciate ligament reconstruction: is the tibial tunnel position most important? *Am J Sports Med*. 2011;39:366-373.
5. Bedi A, Musahl V, Steuber V, et al. Transtibial versus anteromedial portal reaming in anterior cruciate ligament reconstruction: an anatomic and biomechanical evaluation of surgical technique. *Arthroscopy*. 2011;27:380-390.
6. Bedi A, Raphael B, Maderazo A, Pavlov H, Williams RJ 3rd. Transtibial versus anteromedial portal drilling for anterior cruciate ligament reconstruction: a cadaveric study of femoral tunnel length and obliquity. *Arthroscopy*. 2010;26:342-350.
7. Bhatia S, Korth K, Van Thiel GS, et al. Effect of tibial tunnel diameter on femoral tunnel placement in transtibial single bundle ACL reconstruction. *Knee Surg Sports Traumatol Arthrosc*. 2016;24:51-57.
8. Brophy RH, Voos JE, Shannon FJ, et al. Changes in the length of virtual anterior cruciate ligament fibers during stability testing: a comparison of conventional single-bundle reconstruction and native anterior cruciate ligament. *Am J Sports Med*. 2008;36: 2196-2203.
9. Chalmers PN, Mall NA, Cole BJ, Verma NN, Bush-Joseph CA, Bach BR Jr. Anteromedial versus transtibial tunnel drilling in anterior cruciate ligament reconstructions: a systematic review. *Arthroscopy*. 2013; 29:1235-1242.
10. Driscoll MD, Isabell GP Jr, Conditt MA, et al. Comparison of 2 femoral tunnel locations in anatomic single-bundle anterior cruciate ligament reconstruction: a biomechanical study. *Arthroscopy*. 2012;28: 1481-1489.
11. Duffee A, Magnussen RA, Pedroza AD, Flanigan DC, Group M, Kaeding CC. Transtibial ACL femoral tunnel preparation increases odds of repeat ipsilateral knee surgery. *J Bone Joint Surg Am*. 2013;95: 2035-2042.
12. Ebersole GM, Eckerle P, Farrow LD, Cutuk A, Bledsoe G, Kaar S. Anterior cruciate ligament graft isometry is affected by the orientation of the femoral tunnel. *J Knee Surg*. 2016;29:260-266.
13. Fujimaki Y, Thorhauer E, Sasaki Y, Smolinski P, Tashman S, Fu FH. Quantitative in situ analysis of the anterior cruciate ligament: length, midsubstance cross-sectional area, and insertion site areas. *Am J Sports Med*. 2016;44:118-125.
14. Gadikota HR, Sim JA, Hosseini A, Gill TJ, Li G. The relationship between femoral tunnels created by the transtibial, anteromedial portal, and outside-in techniques and the anterior cruciate ligament footprint. *Am J Sports Med*. 2012;40:882-888.
15. Goodwillie AD, Shah SS, McHugh MP, Nicholas SJ. The effect of postoperative KT-1000 arthrometer score on long-term outcome after anterior cruciate ligament reconstruction. *Am J Sports Med*. 2017;45: 1522-1528.
16. Heming JF, Rand J, Steiner ME. Anatomical limitations of transtibial drilling in anterior cruciate ligament reconstruction. *Am J Sports Med*. 2007;35:1708-1715.
17. Hensler D, Working ZM, Illingworth KD, Thorhauer ED, Tashman S, Fu FH. Medial portal drilling: effects on the femoral tunnel aperture morphology during anterior cruciate ligament reconstruction. *J Bone Joint Surg Am*. 2011;93:2063-2071.
18. Herbort M, Domnick C, Raschke MJ, et al. Comparison of knee kinematics after single-bundle anterior cruciate ligament reconstruction via the medial portal technique with a central femoral tunnel and an eccentric femoral tunnel and after anatomic double-bundle reconstruction: a human cadaveric study. *Am J Sports Med*. 2016;44: 126-132.
19. Kondo E, Merican AM, Yasuda K, Amis AA. Biomechanical comparison of anatomic double-bundle, anatomic single-bundle, and nonanatomic single-bundle anterior cruciate ligament reconstructions. *Am J Sports Med*. 2011;39:279-288.
20. Lee JK, Lee S, Seong SC, Lee MC. Anatomy of the anterior cruciate ligament insertion sites: comparison of plain radiography and three-dimensional computed tomographic imaging to anatomic dissection. *Knee Surg Sports Traumatol Arthrosc*. 2015;23:2297-2305.
21. Lee JS, Kim TH, Kang SY, et al. How isometric are the anatomic femoral tunnel and the anterior tibial tunnel for anterior cruciate ligament reconstruction? *Arthroscopy*. 2012;28:1504-1512, 1512e1-2.
22. Lubowitz JH. Anatomic ACL reconstruction produces greater graft length change during knee range-of-motion than transtibial technique. *Knee Surg Sports Traumatol Arthrosc*. 2014;22:1190-1195.
23. Morgan CD, Kalmam VR, Grawl DM. Isometry testing for anterior cruciate ligament reconstruction revisited. *Arthroscopy*. 1995;11:647-659.
24. Morgan CD, Kalman VR, Grawl DM. Definitive landmarks for reproducible tibial tunnel placement in anterior cruciate ligament reconstruction. *Arthroscopy*. 1995;11:275-288.
25. Musahl V, Plakseychuk A, VanScyoc A, et al. Varying femoral tunnels between the anatomical footprint and isometric positions: effect on kinematics of the anterior cruciate ligament-reconstructed knee. *Am J Sports Med*. 2005;33:712-718.
26. Nawabi DH, Tucker S, Schafer KA, et al. ACL fibers near the lateral intercondylar ridge are the most load bearing during stability examinations and isometric through passive flexion. *Am J Sports Med*. 2016;44:2563-2571.
27. Noh JH, Roh YH, Yang BG, Yi SR, Lee SY. Femoral tunnel position on conventional magnetic resonance imaging after anterior cruciate ligament reconstruction in young men: transtibial technique versus anteromedial portal technique. *Arthroscopy*. 2013;29:882-890.
28. Noyes FR, Butler DL, Grood ES, Zernicke RF, Hefzy MS. Biomechanical analysis of human ligament grafts used in knee-ligament repairs and reconstructions. *J Bone Joint Surg Am*. 1984;66:344-352.
29. Ode GE, Piasecki DP, Habet NA, Peindl RD. Cortical button fixation: a better patellar tendon repair? *Am J Sports Med*. 2016;44:2622-2628.
30. Pearle AD, Shannon FJ, Granchi C, Wickiewicz TL, Warren RF. Comparison of 3-dimensional obliquity and anisometric characteristics of anterior cruciate ligament graft positions using surgical navigation. *Am J Sports Med*. 2008;36:1534-1541.
31. Piasecki DP, Bach BR Jr, Espinoza Orias AA, Verma NN. Anterior cruciate ligament reconstruction: can anatomic femoral placement be achieved with a transtibial technique? *Am J Sports Med*. 2011; 39:1306-1315.
32. Plaweski S, Petek D, Saragaglia D. Morphometric analysis and functional correlation of tibial and femoral footprints in anatomical and single bundle reconstructions of the anterior cruciate ligament of the knee. *Orthop Traumatol Surg Res*. 2011;97(suppl 6):S75-S79.
33. Robinson J, Stanford FC, Kendoff D, Stuber V, Pearle AD. Replication of the range of native anterior cruciate ligament fiber length change behavior achieved by different grafts: measurement using computer-assisted navigation. *Am J Sports Med*. 2009;37:1406-1411.
34. Sadoghi P, Kropfl A, Jansson V, Muller PE, Pietschmann MF, Fischmeister MF. Impact of tibial and femoral tunnel position on clinical results after anterior cruciate ligament reconstruction. *Arthroscopy*. 2011;27:355-364.
35. Smith JO, Yasen S, Risebury MJ, Wilson AJ. Femoral and tibial tunnel positioning on graft isometry in anterior cruciate ligament reconstruction: a cadaveric study. *J Orthop Surg (Hong Kong)*. 2014;22:318-324.
36. Steiner ME, Battaglia TC, Heming JF, Rand JD, Festa A, Baria M. Independent drilling outperforms conventional transtibial drilling in anterior cruciate ligament reconstruction. *Am J Sports Med*. 2009; 37:1912-1919.
37. Tampere T, Van Hoof T, Cromheecke M, et al. The anterior cruciate ligament: a study on its bony and soft tissue anatomy using novel 3D CT technology. *Knee Surg Sports Traumatol Arthrosc*. 2017;25: 236-244.