



# Latissimus Dorsi Tendon Transfer With Acromial Osteotomy for Massive Irreparable Rotator Cuff Tear

Nicholas R. Pagani, B.S., Antonio Cusano, B.S., and Xinning Li, M.D.

**Abstract:** Latissimus dorsi tendon transfer is an effective option for young and active patients with massive irreparable posterosuperior rotator cuff tears and intact subscapularis tendon. This approach has been shown to relieve pain and improve shoulder function in both the short and long term. We describe a surgical technique using an acromial osteotomy to better expose the greater tuberosity for the tendon transfer without disrupting the deltoid muscle. The latissimus dorsi tendon is reinforced with a human dermal collagen matrix (GraftJacket; Wright Medical Group) for additional augmentation of the muscle to gain more excursion for the tendon transfer to the greater tuberosity. The transferred tendon is fixed to the supraspinatus and infraspinatus footprints on the greater tuberosity using suture anchors. The acromial osteotomy is repaired back anatomically with several No. 5 braided sutures (FiberWire; Arthrex).

**M**assive rotator cuff tears lead to disabling pain and severe functional impairment and often fail to respond to nonoperative management strategies. These injuries may be acute or chronic and most commonly result in tears involving both the supraspinatus and infraspinatus tendons, resulting in loss of active forward flexion, external rotation, and the ability to control the arm in space. Chronic massive rotator cuff tears with severe retraction may lead to muscle atrophy with fatty infiltration, which prevents primary arthroscopic rotator cuff repair from being a valid treatment option to provide a predictable outcome.<sup>1,2</sup>

Reverse total shoulder arthroplasty is an effective option for elderly patients with massive irreparable rotator cuff tears but may not be an optimal treatment

in a younger patient population.<sup>3,4</sup> As an alternative to reverse shoulder arthroplasty, tendon transfer procedures are a good option to restore function in younger and active patients.<sup>1</sup> These include latissimus dorsi, teres major, and lower trapezius transfers. Latissimus dorsi tendon transfers have been shown to effectively improve pain and function in young patients with irreparable rotator cuff tears.<sup>5,6</sup> We describe a surgical technique for latissimus dorsi muscle tendon transfer with augmentation using a human dermal collagen matrix tissue (GraftJacket; Wright Medical Group, Memphis, TN) and using an acromial osteotomy to optimize the exposure to the greater tuberosity without disrupting the deltoid insertion in a young and active patient with an irreparable massive posterosuperior rotator cuff tear involving the supraspinatus, infraspinatus, and teres minor muscle belly with severe fatty infiltration ([Video 1](#)).

*From the School of Medicine, Boston University, Boston, Massachusetts, U.S.A.*

*The authors report the following potential conflict of interest or source of funding: X.L. receives support from Journal of Medical Insight. Editorial board and equity in company. Full ICMJE author disclosure forms are available for this article online, as [supplementary material](#).*

*Received April 13, 2017; accepted August 10, 2017.*

*Address correspondence to Xinning Li, M.D., Department of Orthopaedic Surgery, Boston Medical Center, 850 Harrison Ave, Dowling 2, North Boston, MA 02118, U.S.A. E-mail: [Xinning.li@gmail.com](mailto:Xinning.li@gmail.com)*

*© 2017 by the Arthroscopy Association of North America. Published by Elsevier. This is an open access article under the CC BY-NC-ND license (<http://creativecommons.org/licenses/by-nc-nd/4.0/>).*

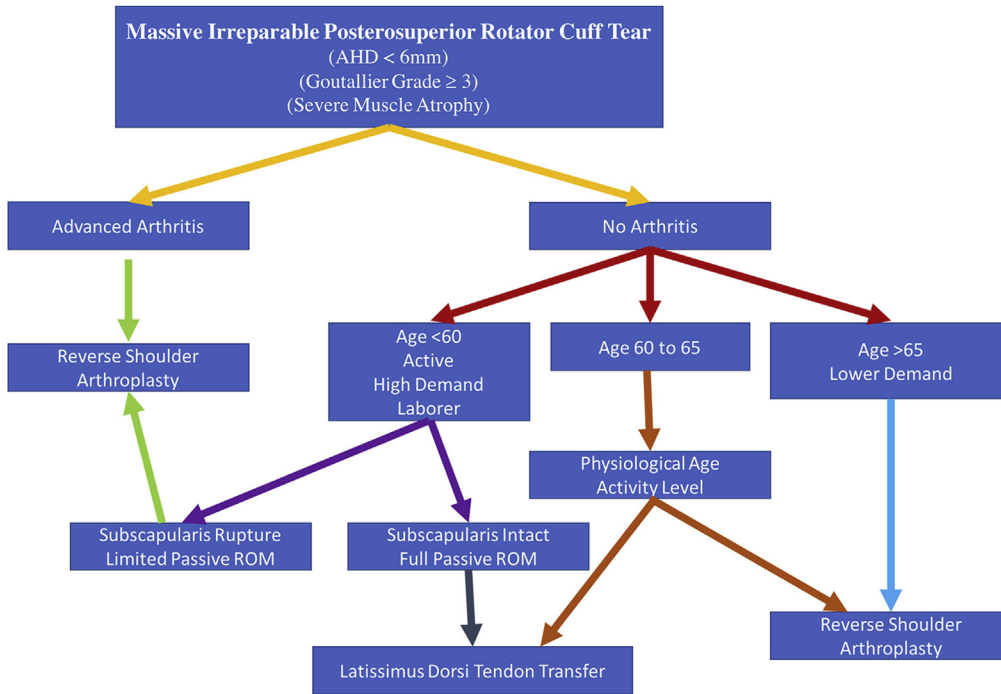
*2212-6287/17550*

*<https://doi.org/10.1016/j.eats.2017.08.059>*

## Surgical Technique

### Indications

The indication for the described surgical technique is a relatively young and active patient with a massive irreparable posterosuperior rotator cuff tear and minimal glenohumeral arthritis resulting in the loss of active forward flexion and external rotation ([Fig 1](#), [Table 1](#)). The definition of a massive irreparable rotator cuff tear includes proximal humeral head migration with an acromial-humeral distance of less than 6 mm



**Fig 1.** Algorithm proposed by the senior author (X.L.) for the management of patients with massive irreparable posterosuperior rotator cuff tears. The Goutallier classification is as follows: grade 1, fatty streak; grade 2, more muscle than fat; grade 3, muscle equal to fat; and grade 4, more fat than muscle. (AHD, acromial-humeral distance; ROM, range of motion.)

on static standing radiographs, fatty infiltration of the cuff muscle of grade 3 or higher according to the Goutallier classification, and retraction of the tear to the level of the glenoid, along with severe muscle atrophy. These patients are not candidates for a reverse shoulder arthroplasty because of their young age and activity level (heavy laborer or high-demand work). There should not be an exact age cutoff to indicate whether a patient will need a tendon transfer or reverse shoulder arthroplasty because the chronological age does not always match the physiological age and activity level. Each patient must be approached individually on the basis of his or her goals and expectations. In addition, the subscapularis tendon must be intact for a successful latissimus dorsi tendon transfer. Specific contraindications include axillary nerve injury or loss of function of the deltoid muscle, subscapularis tendon rupture, shoulder stiffness with limitation of passive shoulder range of motion, advanced glenohumeral osteoarthritis, and lack of patient compliance or unwillingness to follow the postoperative rehabilitation regimen.

**Setup and Acromial Osteotomy**

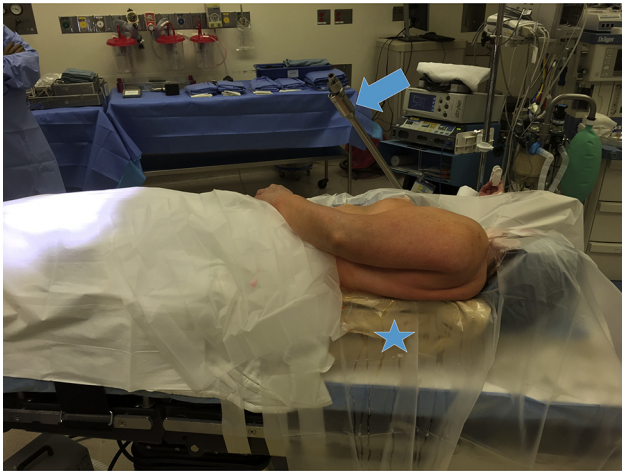The patient is placed in the lateral decubitus position with the involved limb positioned in a Spider arm holder (Tenet Medical) (Fig 2). A superior longitudinal incision is made in line over the middle aspect of the acromion (Fig 3A). Soft-tissue dissection is performed with a Bovie device (Bovie Medical) to identify the

middle to lateral aspect of the acromion. By use of an osteotomy saw, an osteotomy is cut around 7 to 8 mm from the lateral edge of the acromion in transverse fashion to expose the greater tuberosity. Alternatively, the osteotomy is made at the middle aspect of the

**Table 1.** Indications and Contraindications for Latissimus Dorsi Tendon Transfer

Indications	
Massive irreparable posterosuperior rotator cuff tear with intact subscapularis tendon and function	
Chronic tendon tear with retraction to level of glenoid	
Combined loss of active forward flexion and external rotation with positive external rotation lag sign and horn-blower sign	
Proximal migration of humeral head with acromiohumeral interval <7 mm	
Stage 3 or 4 fatty infiltration of posterosuperior rotator cuff musculature on CT or MRI	
Best candidate for surgery is patient with active flexion to horizon and preserved passive flexion similar to contralateral side and with ability to hold arm up without assistance	
Contraindications	
Tear of subscapularis with positive liftoff and/or belly-press test	
Deltoid dysfunction	
Glenohumeral arthritis	
Stiffness with passive forward flexion <100°	
Unable to hold arm up at maximal forward flexion	
Active infection	
Unable to cooperate with postoperative rehabilitation protocol	
Parkinson disease	
Brachial plexus injury	

CT, computed tomography; MRI, magnetic resonance imaging.



**Fig 2.** The patient is placed on a beanbag (star) in the lateral decubitus position with the left shoulder and hemithorax prepared and draped free and with the arm positioned in a Spider arm holder (arrow) that is on the opposite side of the table.

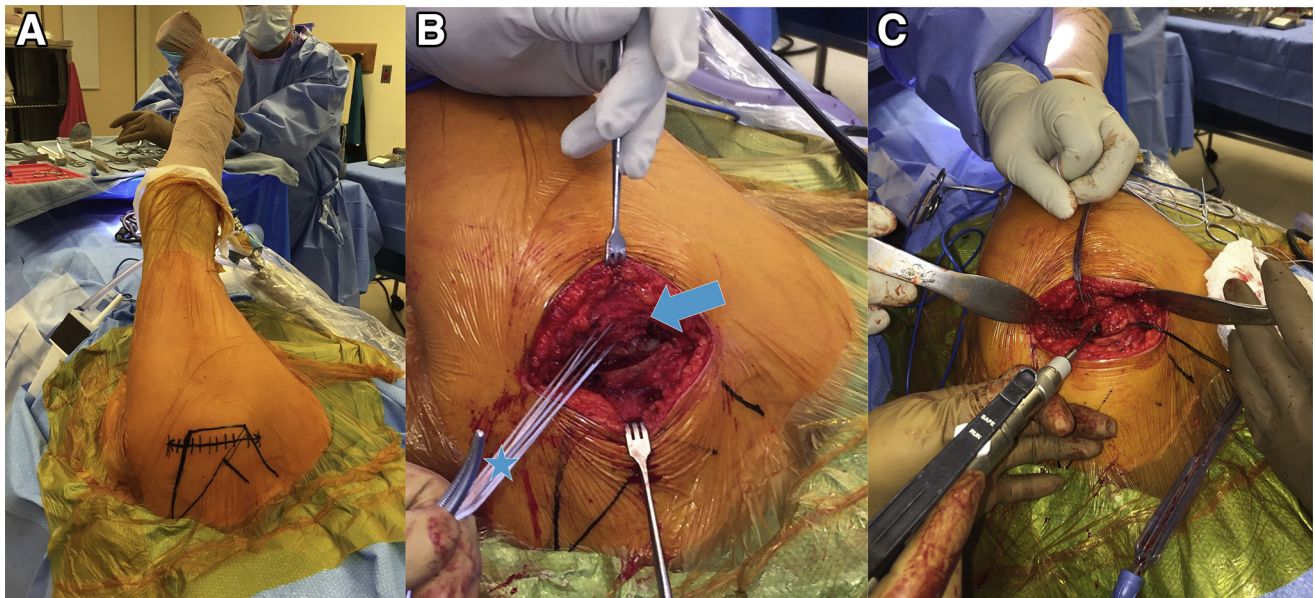
acromion by dividing the lateral acromion in half. After the osteotomy is performed, it is tagged with 3 to 4 No. 5 FiberWire stitches (Arthrex, Naples, FL) depending on the size of the lateral acromion and the osteotomy (Fig 3B). With the acromial osteotomy, the surgeon will gain excellent visualization of the greater tuberosity for the tendon transfer. The greater tuberosity is decorticated down to a bleeding bone bed with a pineapple burr in preparation for latissimus dorsi muscle transfer (Fig 3C).

### Latissimus Dorsi Muscle and Tendon Harvest

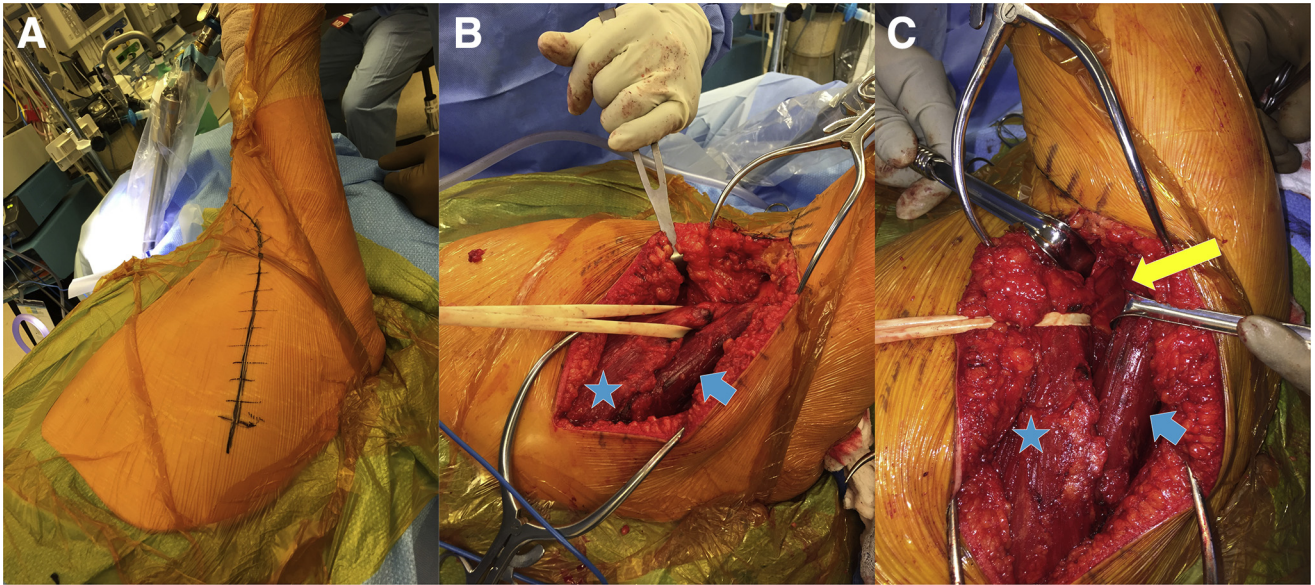
The arm is placed in a flexed position for the latissimus dorsi harvest. A large incision is made, centered over the latissimus dorsi muscle and extending into the axilla (Fig 4A). Soft-tissue dissection is performed to identify the latissimus dorsi and teres major. The interval between the latissimus dorsi and teres major is spread. By use of a right-angle clamp, a Penrose drain is passed around the latissimus to aid with dissection and harvest of the tendon (Fig 4B). Next, the arm is taken off the limb positioner and internally rotated to expose the latissimus tendon insertion on the proximal humerus. By internally rotating the arm, the insertion location of the latissimus dorsi tendon is better exposed, which will allow for safe harvest of the tendon (Fig 4C). The latissimus dorsi tendon is now taken down at the base of its humeral insertion with Metz scissors. The latissimus is manually dissected and free as a pedicle, with the surgeon paying attention not to injury the neurovascular bundle to achieve appropriate excursion. Then, further dissection is performed to identify the neurovascular pedicle that enters the latissimus dorsi between the latissimus and teres major (Fig 5). After dissection is completed, excursion of the latissimus should be tested to ensure it is appropriate and has enough length to reach the greater tuberosity for the transfer.

### Tendon Augmentation, Transfer, and Fixation

The GraftJacket is used to serve as augmentation to reinforce the latissimus dorsi tendon transfer. The



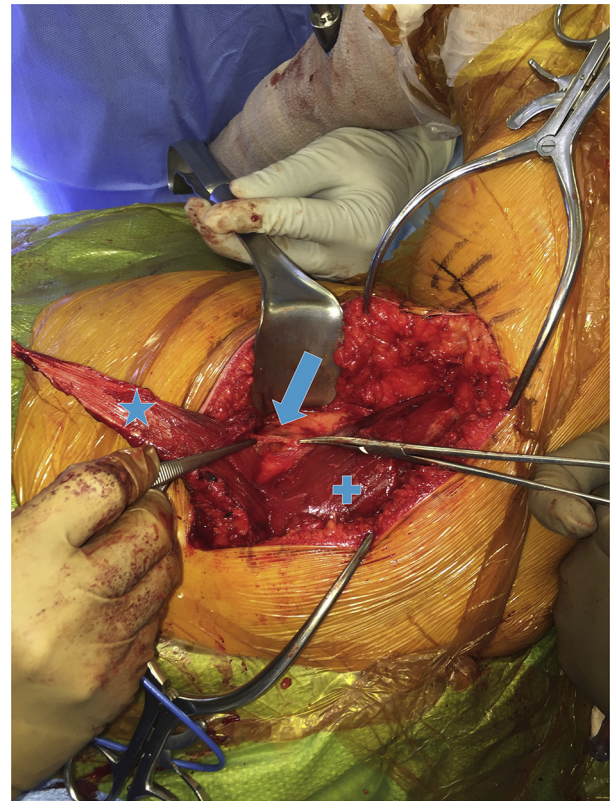
**Fig 3.** The patient is placed in the lateral decubitus position on a beanbag; the left shoulder is shown. (A) The acromial osteotomy incision is centered over the distal acromion. (B) The osteotomy is performed (arrow) with a sagittal saw and tagged with 3 to 4 No. 5 braided sutures (star). (C) A burr is used to decorticate or roughen the greater tuberosity and prepare it for the transfer. Two smooth cobra devices are placed anterior and posterior to the humeral head to help with the exposure.



**Fig 4.** The patient is in the lateral decubitus position with the left arm flexed using the Spider arm holder. (A) A large incision is centered over the latissimus dorsi muscle belly. (B) The latissimus dorsi muscle (star) is dissected, isolated from the teres major muscle (arrow), and tagged with a Penrose drain. (C) The left arm is taken out of the Spider arm holder and internally rotated to better expose the latissimus dorsi muscle-tendon footprint for harvest (yellow arrow). Both the latissimus dorsi muscle (star) and the teres major muscle (blue arrow) are shown.

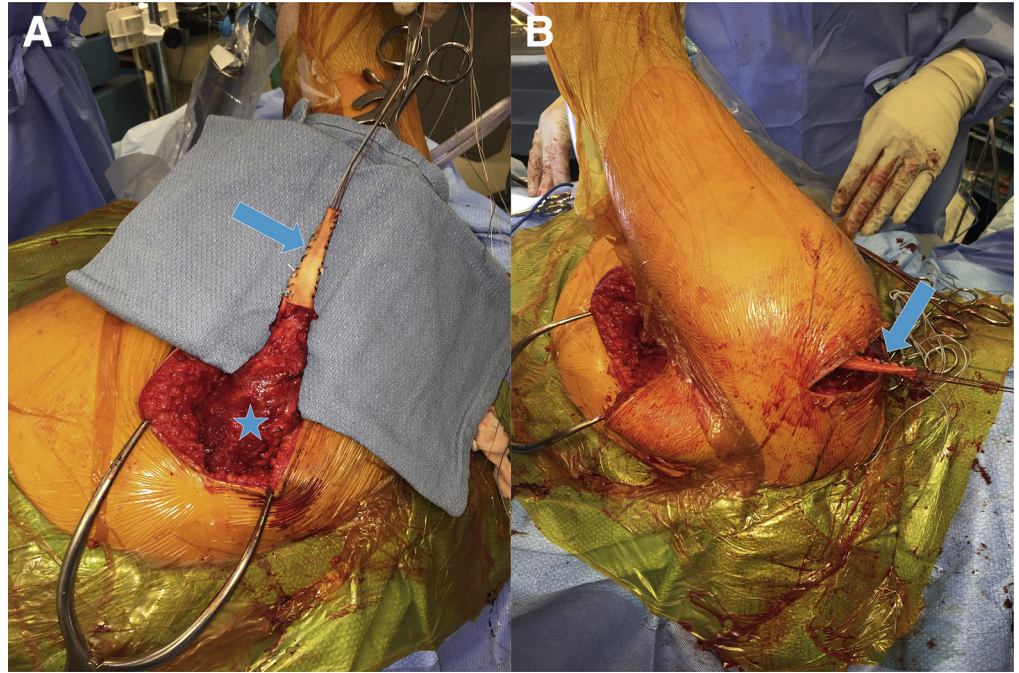
GraftJacket is cut to the appropriate size and shaped around the tendon. Two running stitches (No. 2 braided Ethibond; Ethicon, Somerville, NJ) are used on each edge of the GraftJacket and run to the top (Fig 6A). The arm is then placed at about 30° of abduction, 30° of flexion, and 30° of external rotation for the muscle transfer. A tunnel is created underneath the deltoid where the latissimus dorsi travels just over the teres major tendon and to the top of the greater tuberosity. All adhesions are freed in this area with blunt dissection with the surgeon's finger. The senior author (X.L.) also prefers to use a Kelly clamp to help further open up this space for the passage of the muscle-transfer. The latissimus dorsi can now be pulled beneath the deltoid and over the top of the greater tuberosity in preparation for the transfer (Fig 6B).

Three metal Healix anchors (Mitek Sports Medicine, Raynham, MA) are inserted in stellate fashion into the tendon footprint on the greater tuberosity (Fig 7A). A free needle is used to pass suture across the GraftJacket with the latissimus dorsi tendon in a horizontal mattress fashion. Alternatively, a 90° suture lasso passer can be used to help facilitate the passage of these sutures. The sutures are then tied down with surgeon knots with alternating half-hitches. The transferred latissimus tendon is further secured to the anchors using Arthrex SwiveLock anchors using a suture bridge— or double row— equivalent repair technique. The final transfer is shown in Figure 7C.



**Fig 5.** The patient is in the lateral decubitus position, and the left arm is flexed with the Spider arm holder. The latissimus dorsi tendon (star) is harvested with the neurovascular bundle identified (arrow). The teres major muscle (plus sign) is also shown.

**Fig 6.** The patient is in the lateral decubitus position, and the left arm is flexed with the Spider arm holder. (A) The GraftJacket is used to augment the latissimus dorsi tendon for the harvest. No. 2 braided sutures (arrow) are placed on either side of the GraftJacket to augment the graft to the latissimus dorsi muscle (star). (B) The latissimus dorsi muscle with the GraftJacket augmentation (arrow) is tunneled underneath the deltoid muscle to the top of the shoulder and over the greater tuberosity for the final transfer.

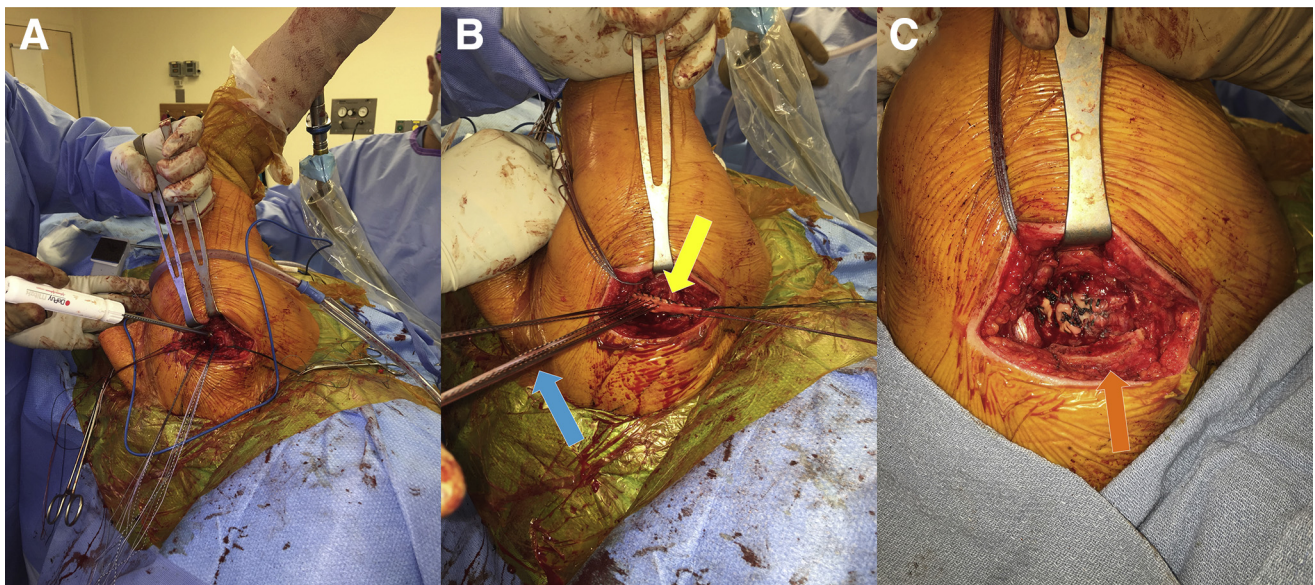


### Acromial Osteotomy Reduction

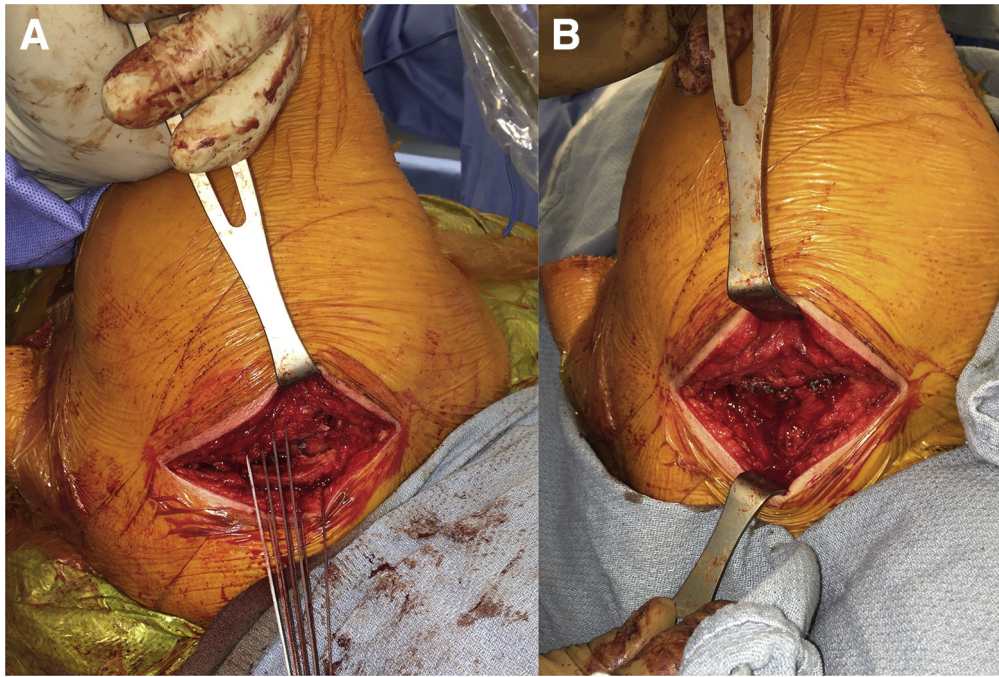
Three or four drill holes are placed over the acromion, and No. 5 FiberWire is passed around the drill holes with a free needle (Fig 8A). The acromial osteotomy is now reduced onto the acromion, and the No. 5 FiberWire sutures are tied down using surgeon knots with alternating half-hitches to achieve fixation (Fig 8B).

### Wound Closure

The soft tissue of the superficial acromial osteotomy wound overlying the lateral acromion is closed with No. 2 braided sutures in an interrupted fashion. The superficial skin wound overlying both the lateral acromion and the latissimus dorsi muscle harvest site is closed with No. 0 Vicryl (Ethicon), No. 2-0 Monocryl (Ethicon), and running No. 3-0 Monocryl, and a drain



**Fig 7.** The patient is in the lateral decubitus position, and the left arm is flexed to 30° of flexion, 30° of abduction, and 30° of external rotation with the Spider arm holder. (A) Several metal suture anchors are placed in the greater tuberosity. (B) The sutures are passed across the tendon transfer with the GraftJacket augment. The blue arrow is pointing to the 90 degrees passer (Ideal Passer with Chia; Mitek, Raynham, MA) and the yellow arrow is pointing to the tip of the passer. (C) Final muscle tendon transfer to the greater tuberosity. The acromial osteotomy site is illustrated with the orange arrow.



**Fig 8.** The patient is placed in the lateral decubitus position on a beanbag; the left shoulder is shown. (A) Three to four drill holes are made in the acromion, and the No. 5 braided FiberWire is used to repair the osteotomy bone back to the acromion. (B) Final fixation of acromial osteotomy.

is placed at the site of latissimus harvest. Dermabond (Ethicon) is used on both wounds, and they are dressed with 4" × 4" dressings and Tegaderm (3M). The arm is now placed in an abduction and external rotation brace for 6 weeks.

### Postoperative Care

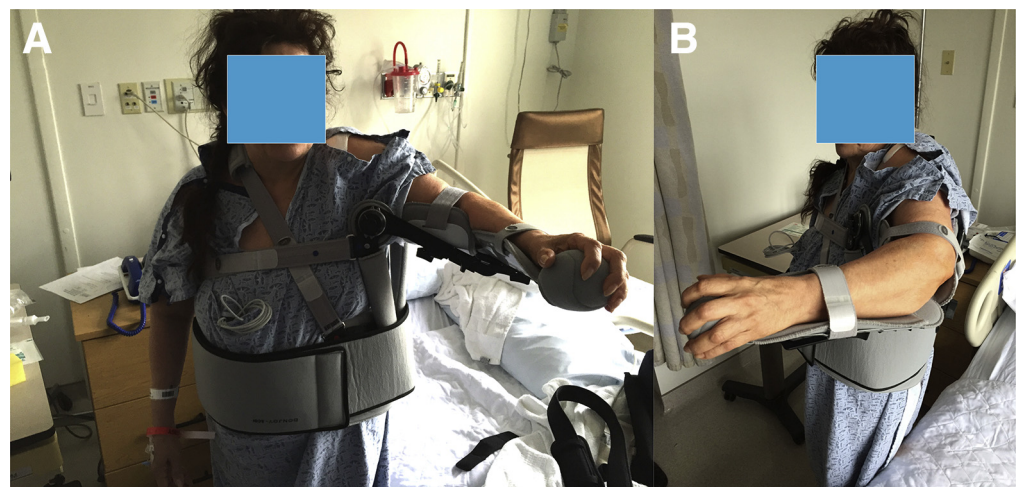
After the procedure, the arm must be immobilized for 6 weeks in an SCOI brace (DonJoy, Vista, CA) to maintain 70° to 80° of abduction and 20° to 30° of external rotation for 6 weeks (Fig 9). At 6 weeks postoperatively, the patient may begin passive shoulder range of motion in forward flexion and external rotation

as tolerated and limited by pain. Transition from passive to active-assisted to active range of motion occurs from 2 to 4 months after surgery. After 3 to 4 months, a biofeedback program is started to retrain the latissimus dorsi to act as an active flexor and external rotator of the shoulder using a coupled J motion. Strengthening may begin around the 4-month time point. Full functional recovery will take 1 year from the date of surgery.

### Discussion

This article describes a method to perform latissimus dorsi muscle transfer with an acromial osteotomy for

**Fig 9.** The patient's left shoulder is placed in an SCOI brace with the arm in about 80° of flexion, 70° of abduction, and neutral to 10° of external rotation after the surgical procedure for 6 weeks. (A) Frontal view of brace. (B) View from side.



**Table 2.** Risks and Limitations

Risks
Acromial fracture from osteotomy
Damage to deltoid muscle
Postoperative axillary nerve palsy or intraoperative injury
Injury to neurovascular pedicle of latissimus dorsi
Avulsion of latissimus tendon from transferred position
Brachial plexus injury
Postoperative hematoma
Limitations
Intensive postoperative rehabilitation required to retrain latissimus to function as shoulder flexor and external rotator
Patients with extensive arthritis of glenohumeral joint are not good candidates for latissimus dorsi transfer
Technically challenging

massive irreparable rotator cuff tears (Tables 2-4). Massive tears involving the posterosuperior rotator cuff may become irreparable because of reduced muscle quality or atrophy and fatty infiltration, which presents a challenging problem for surgeons. Several surgical options are available, including arthroscopic debridement, partial repair, reverse total shoulder arthroplasty, superior capsule reconstruction, and tendon transfer. Arthroscopic debridement and partial repair techniques have been shown to relieve pain but do not improve strength or functionality.<sup>1</sup> Reverse total shoulder arthroplasty has been shown to provide pain relief with return of shoulder function, but it may not be an optimal option for young and active patients.<sup>4</sup> Tendon transfer procedures such as latissimus dorsi transfer are a good alternative for young patients. Gerber et al.<sup>5</sup> assessed the outcome of latissimus dorsi transfer in 44 patients at an average

follow-up of 147 months and found substantial increases in the Subjective Shoulder Value, relative Constant score, pain score, flexion, abduction, and external rotation. A systematic review by Namdari et al.<sup>6</sup> showed similar findings, indicating that latissimus dorsi tendon transfer offers effective treatment for irreparable rotator cuff tears. It has been shown that patients achieve the best outcome with latissimus dorsi tendon transfer when the subscapularis is intact and they are able to elevate to horizontal or 90° of flexion before surgery.<sup>7</sup> Furthermore, one recent study found that latissimus dorsi tendon transfer is especially effective in active patients aged under 60 years.<sup>8</sup> These findings are useful in guiding patient selection for our surgical technique.

The described latissimus tendon transfer technique offers numerous advantages. Acromial osteotomy allows for excellent visualization of the greater tuberosity and the retracted rotator cuff without compromising the deltoid insertion. This is key because injury to the deltoid muscle leads to inferior results when treating massive rotator cuff tears.<sup>9</sup> Moreover, the acromial osteotomy allows for bone-to-bone healing, which is more predictable than muscle-to-bone healing. In addition, this technique uses the GraftJacket as augmentation to the transfer, which provides additional reinforcement to the latissimus tendon and more excursion. The limitations of this technique are similar to those of other tendon transfer procedures. Patients must be willing to engage in intensive postoperative rehabilitation, which is crucial to retrain the latissimus dorsi to function as a shoulder flexor and external rotator.

**Table 3.** Surgical Pearls and Pitfalls

Pearls
Perform the acromial osteotomy at the middle aspect of the distal-lateral acromion to give at least 7-8 mm of bone for repair back to the acromion.
Use No. 5 braided sutures to tie back the acromial osteotomy to the drill hole.
Use the GraftJacket to reinforce and give more excursion to the transferred latissimus dorsi tendon.
Release the latissimus tendon at the base of its humeral insertion for maximal tendon strength.
Take the arm out of the arm holder and internally rotate it to help further delineate the latissimus dorsi insertion point for safe harvest.
Ensure sufficient tendon tensioning to maximize strength postoperatively.
Note that the arm must be in 30° of flexion, 30° of external rotation, and 30° of abduction to ensure proper tensioning of the repair and muscle transfer.
Use multiple suture anchors spaced out on the greater tuberosity to fix down the tendon transfer.
Repair the residual tendon back to the tuberosity if possible. Note that even partial repair in combination with the muscle transfer may help the ultimate function of the patient.
Pitfalls
Acromial fracture may occur at the time of osteotomy and may require ORIF and plate fixation.
Damage to the deltoid during acromial osteotomy will impair the outcome.
Insufficient latissimus dorsi excursion makes fixation difficult.
Failure to sufficiently enlarge the tunnel beneath the deltoid makes transfer difficult and may result in postoperative adhesions.
Inadequate tendon fixation to the greater tuberosity due to poor bone quality increases the risk of avulsion.
The arm position for the tendon transfer is crucial for the success of the procedure.
The patient must be immobilized in an SCOI brace postoperatively for 6 wk to protect the muscle transfer.

ORIF, open reduction–internal fixation.

**Table 4.** Key Surgical Steps

Steps	Description
1. Patient positioning	The lateral decubitus position is used, with the arm and hemithorax exposed for surgical access. The limb is placed in an arm holder. The arm holder is placed on the opposite side of the table.
2. Acromial osteotomy	An incision is made over the lateral acromion; it should be centered. Transverse osteotomy is performed approximately 7-8 mm from the acromion edge. The acromial osteotomy is tagged with 3-4 No. 5 braided sutures to help with mobilization and to perform repair back to the acromion at the end of the case.
3. Latissimus dorsi harvest	The greater tuberosity is decorticated with a burr to a bleeding bone bed. The arm is placed in an overhead or flexed position in the arm holder. The incision is made, centered over the latissimus dorsi muscle and extending into the axilla. The senior author (X.L.) prefers a curved incision into the axilla. The interval between the latissimus dorsi and teres major muscle is spread, and the latissimus dorsi muscle is isolated with a Penrose drain. The arm is removed from the arm holder and internally rotated to further help in the exposure of the latissimus dorsi insertion. The latissimus tendon is released at the base of the humeral insertion.
4. Tendon augmentation	The latissimus muscle belly is bluntly dissected and freed to increase excursion for the transfer and to identify the neurovascular pedicle coming into the muscle belly underneath. The GraftJacket is cut to the appropriate size and shape around the tendon. Two No. 2 Ethibond stitches are run on each edge of the GraftJacket to the top. The senior author prefers to extend the GraftJacket another 2-3 cm past the muscle belly to increase the excursion of the latissimus dorsi muscle for the transfer to the greater tuberosity.
5. Tendon transfer	The arm is positioned at 30° of abduction, 30° of flexion, and 30° of external rotation with the arm holder. The latissimus dorsi tendon is transferred through a tunnel beneath the deltoid and pulled over the top of the greater tuberosity. Passage can be performed with the help of a large Kelly clamp.
6. Tendon fixation	Three metal Healix anchors are inserted in stellate fashion into the tendon footprint on the greater tuberosity. Suture is passed across the GraftJacket with the latissimus tendon in a horizontal mattress fashion using a free needle or a 90° suture passer. The latissimus dorsi tendon is secured to the greater tuberosity using a suture bridge— or double row—equivalent repair with SwiveLock anchors as lateral-row anchors. In addition, a superior capsule reconstruction can be performed at this time to augment the tendon transfer.
7. Acromial osteotomy reduction	Three to four drill holes are placed over the acromion, and the osteotomy fragment undergoes fixation back to the acromion with No. 5 braided FiberWire sutures.
8. Closure	The wound is closed with Monocryl sutures, and both the acromion incision and the latissimus dorsi transfer incision undergo Dermabond application. A drain can be placed in the latissimus dorsi harvest site to prevent hematoma formation.

## References

1. Khair MM, Gulotta LV. Treatment of irreparable rotator cuff tears. *Curr Rev Musculoskelet Med* 2011;4:208-213.
2. Deniz G, Kose O, Tugay A, Guler F, Turan A. Fatty degeneration and atrophy of the rotator cuff after arthroscopic repair: Does it improve, halt or deteriorate? *Arch Orthop Trauma Surg* 2014;134:985-990.
3. Drake GN, O'Connor DP, Edwards TB. Indications for reverse total shoulder arthroplasty in rotator cuff disease. *Clin Orthop Relat Res* 2010;468:1526-1533.
4. Mulieri P, Dunning P, Klein S, Pupello D, Frankle M. Reverse shoulder arthroplasty for the treatment of irreparable rotator cuff tear without glenohumeral arthritis. *J Bone Joint Surg Am* 2010;92:2544-2556.
5. Gerber C, Rahm SA, Catanzaro S, Farshad M, Moor BK. Latissimus dorsi tendon transfer for treatment of irreparable posterosuperior rotator cuff tears: Long-term results at a minimum follow-up of ten years. *J Bone Joint Surg Am* 2013;95:1920-1926.
6. Namdari S, Voleti P, Baldwin K, Glaser D, Huffman GR. Latissimus dorsi tendon transfer for irreparable rotator cuffs: A systematic review. *J Bone Joint Surg Am* 2012;94:891-898.
7. Gerber C, Macqueira G, Espinosa N. Latissimus dorsi transfer for the treatment of irreparable rotator cuff tears. *J Bone Joint Surg Am* 2006;88:113-120.
8. Petriccioli D, Bertone C, Marchi G. Recovery of active external rotation and elevation in young active men with irreparable posterosuperior rotator cuff tear using arthroscopically assisted latissimus dorsi transfer. *J Shoulder Elbow Surg* 2016;25:e265-e275.
9. Gumina S, Di Gogio G, Perugia D, Postacchini F. Deltoid detachment consequent to open surgical repair of massive rotator cuff tears. *Int Orthop* 2008;32:81-84.