

## Cesium-associated hypokalemia successfully treated with amiloride

Sarah Horn, Elliot Naidus, Seth L. Alper and John Danziger

Beth Israel Deaconess Medical Center, Harvard Medical School, Boston, MA, USA

Correspondence to: Sarah Horn; E-mail: skhorn@bidmc.harvard.edu

### Abstract

Self-treatment of cancer with cesium chloride, despite proven lack of efficacy, continues to produce serious adverse effects. Among these is hypokalemia predisposing to life-threatening arrhythmia. The mechanism of cesium-associated hypokalemia (CAH) has not been described. We report urinary potassium wasting responsive to amiloride therapy in a cancer patient with CAH, and discuss possible mechanisms.

**Keywords:** cancer; cesium; hypokalemia

### Background

The alkali metal cesium is used as an alternative and complementary cancer treatment in the context of ‘high pH therapy’ [1]. This therapy was based upon the hypothesized but never demonstrated preferential uptake by malignant cells of cesium cations in exchange for protons, purportedly retarding tumor cell cycle progression secondary to unvalidated intracellular alkalosis. Two uncontrolled, non-randomized case series [1, 2] suggesting potential benefits of cesium therapy were not confirmed by subsequent studies [3, 4]. Despite the American Cancer Society’s explicit warning against cesium use (<http://www.cancer.org/treatment/treatmentsandsideeffects/complementaryandalternativemedicine/herbsvitaminsandminerals/cesium-chloride>), unapproved ingestion of cesium has led to toxicity and death [4, 5].

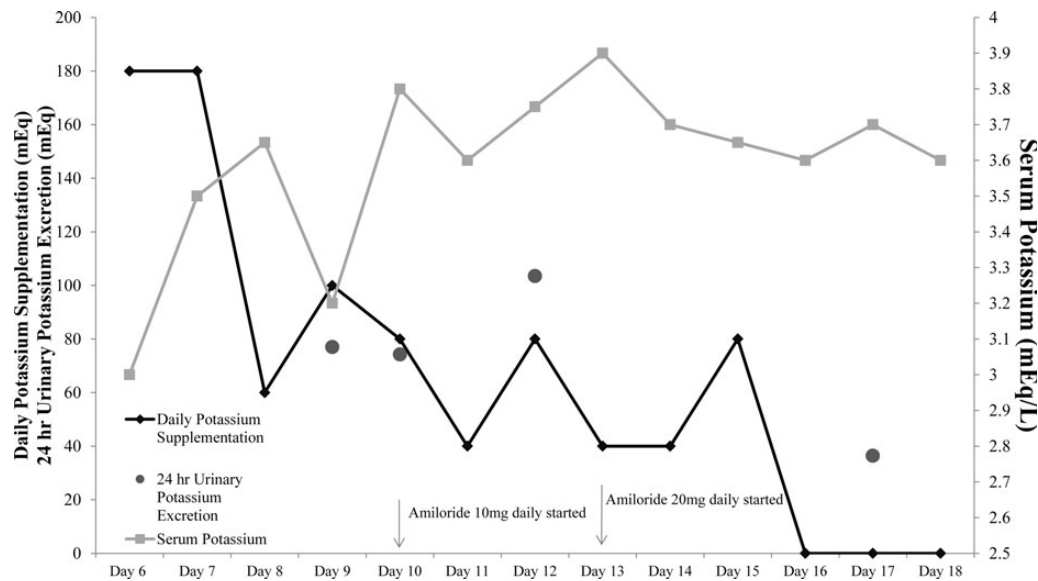
Cesium shares its outer-shell electronic structure with sodium, potassium and lithium. Like potassium, cesium is avidly absorbed in the small bowel and secreted by the distal nephron [4, 6]. Cesium ingestion is associated with depletion of both intracellular and extracellular potassium [4]. Cesium administration to rodents can model torsades de pointes, and human ingestion has caused prolonged QTc, torsades de pointes, ventricular tachycardia, and death [7]. Cesium-associated arrhythmias are likely exacerbated by cesium-associated hypokalemia (CAH), which has been attributed to ‘cellular shift’. This case report describes renal potassium handling during a trial of amiloride therapy in a patient with CAH.

### Case report

A 45-year-old man presented with hoarseness following a long history of tobacco use. Evaluation revealed stage four laryngeal cancer of the small cell neuroendocrine type with metastases to lymph nodes, liver and adrenal glands, which failed to respond to a 3-month course of cisplatin and etoposide. Serum  $[K^+]$  ranged from 4.1 to 4.5 mmol/L during cisplatin treatment. Two months after cessation of cisplatin and just prior to initiation of cesium, serum  $[K^+]$  was 4.2 mmol/L. Subsequent therapies, including topotecan, carboplatin, paclitaxel and radiation, also proved ineffective.

The patient sought (and reportedly achieved) pain relief by self-medication with 3 g daily of cesium chloride, usually ingested but occasionally with a topical preparation purchased online. His first subsequent serum  $[K^+]$  within weeks after starting cesium was 3.5 mmol/L. Peripheral paresthesias were noted after 2 months on this regimen, when serum  $[K^+]$  was 3.3 mmol/L. Despite the patient’s own extensive reading about hypokalemic side effects, and against medical advice, he continued his cesium with self-directed daily supplementation of ~130 mEq potassium in the form of a potassium supplement ordered online, 1–6 bananas, coconut water and 1 L vegetable juice.

Upon hospitalization with pancreatitis in the setting of growing abdominal metastases, admission serum  $[K^+]$  was 3.3 mmol/L. Normalization required daily potassium supplementation, both intravenous and oral, of 60–180 mEq (Figure 1). Nephrology consultation revealed absence



**Fig. 1.** Renal potassium handling after amiloride initiation. Serum potassium levels (light gray squares and line), potassium supplementation (black diamonds and line) and urinary potassium excretion (dark gray circles) over 12 days in hospital. After starting amiloride, urinary potassium excretion and potassium supplementation decreased while serum potassium levels increased.

of hypertension and edema. Normal serum electrolytes included  $[Mg^{2+}]$  0.86 mmol/L [2.1 mg/dL],  $[HCO_3^-]$  29 mmol/L, and a normal anion gap. Proteinuria and glycosuria were absent, and urine pH ranged from 6 to 7.5. Twenty-four-hour urine  $K^+$  excretion ranged from 60 to 100 mmol. Serum levels of cortisol, renin and aldosterone were normal. Serum cesium concentration was 28 000 mcg/L (or 0.2 mM; normal value <10 mcg/L), with a urine cesium concentration of 130 000 mcg/L (or 1.0 mM; normal value <20 mcg/L). In the absence of alkalosis, hyperaldosteronism, hypercortisolism or hypomagnesemia, the patient's hypokalemia in the setting of urinary potassium wasting was attributed to systemic cesium toxicity.

To reduce the patient's requirement for oral potassium supplementation, he was treated initially with 10 mg amiloride daily, subsequently increased to 20 mg. After 1 week of amiloride treatment, the patient no longer required extra-dietary potassium supplementation, and his urine  $K^+$  excretion decreased to 36 mmol/day. In contrast, urine cesium concentration increased to 310 000 mcg/L and serum cesium concentration remained unchanged after 4 days on amiloride.

At post-discharge nephrology follow-up, the patient reported recurrence of severe pain and acknowledged continued episodic self-administration of cesium. He died 2 months later in hospice care, 18 months after initial presentation.

## Discussion

CAH has been noted in multiple case reports (Table 1) but its prevalence cannot be reliably established in the context of cesium self-administration without prescription. Clinical data suggesting a mechanism of CAH are minimal. The current case report is the first to demonstrate inappropriate urinary potassium wasting in CAH. Amiloride, a competitive inhibitor of ENaC, the epithelial sodium channel of the connecting segment and cortical collecting duct, dramatically

reduced our patient's kaliuresis and his supplemental potassium requirement. The data suggest that amiloride treatment can mitigate CAH.

Cesium's effects on renal tubular  $K^+$  channels and transporters suggest several possible mechanisms of CAH.  $K^+$  channels have evolved to exclude the smaller  $Na^+$  cation from the channel pore, usually at the cost of reduced discrimination among cations of size comparable to or larger than potassium, including the cesium cation,  $Cs^+$ . Thus,  $Cs^+$  acts not only as an inhibitor, but for some  $K^+$  channels may also serve as a permeant cation, causing differences of potassium distribution in a channel-specific manner [18].

Urinary potassium excretion is regulated largely at the level of the distal nephron. ROMK/Kir1.1/KCNJ1 channels constitute the major route for distal nephron potassium secretion [19, 20]. ROMK is the major secretory  $K^+$  recycling channel of the apical membrane of the thick ascending limb (TAL) epithelial cells. ROMK's function allows continued  $NaCl$  reabsorption by the TAL apical membrane bumetanide receptor, NKCC2/SLC12A1 (for which cesium is not likely a substrate but instead a weak inhibitor, by analogy with its effects on the homologous SLC12 potassium-chloride cotransporters) [21].

ROMK also functions as the major  $K^+$  secretion channel of the apical membrane of the CNT and collecting duct (CD) principal cells. Extracellular  $Cs^+$  blocks  $K^+$  influx through ROMK, but can enhance  $K^+$  efflux through ROMK up to 5-fold. In addition, the number of active ROMK channels at the apical membrane may increase in response to elevated dietary potassium (and perhaps also cesium) load [22–24]. This increase could further enhance potassium secretion in response to the postulated increased absorptive tubular sodium load presented to ENaC.  $Cs^+$  also blocks Kir4.1 [25], a component of the KCNJ10/16 heteromer, the major recycling  $K^+$  channel of the DCT/CNT basolateral membrane. Blockade of this channel would reduce DCT/CNT  $Na^+$  reabsorption (mimicking EAST/SESAME syndrome) [26], predisposing to increased downstream ENaC-mediated  $Na^+$  absorption electrically coupled to increased  $K^+$  secretion through apical ROMK channels.

**Table 1.** Case reports documenting cesium side effects

Patient, diagnosis	Presentation (findings)	Initial K (mmol/L)	Duration of hypokalemia	Outcome
61/F, breast mass [5]	Cardiac arrest (polymorphic Vtach, long QT)	2.7	Unknown	Death at 10 days
65/F, rectal cancer [8]	Syncope (long QT, TDP)	2.8	5 weeks	Discharge at 27 days
16/F, HCC [9]	Syncope (long QT, monomorphic Vtach)	Unknown	N/A	Discharge at 7 days
43/F, brain neoplasm [10]	Seizure (monomorphic Vtach)	3.1	Long-term K and Mg supplementation	Discharge
39/F, menorrhagia [11]	Syncope (long QT, U waves)	3.1	Unknown	Discharge
42/F, breast cancer [12]	Seizure (abnormal CT head)	Unknown	N/A	Death at 2 days
45/F, breast cancer [13]	Syncope (long QT, TDP)	3.9	1 week	Discharge at 7 days
62/M, prostate cancer [7]	Syncope (TDP, long QT)	2.8	Unknown	Discharge
8/M, osteogenic sarcoma [14]	Shaking, non-responsiveness, and urinary incontinence (bradycardia, TDP, Vfib, long QT)	Low	Noted normal at 6 months	Discharge
52/F, colon cancer [15]	Syncope (polymorphic Vtach, hypotension, long QT)	3.2, 2.8	2 days	Discharge at 3 days
47/F, breast cancer prevention [16]	Fall (long QT, polymorphic Vtach)	3.2	2 days	Discharge at 4 days
46/F, melanoma [17]	syncope, diarrhea (TDP, long QT)	3.7	Persistent hypokalemia during hospitalization (35 days)	Discharge at 35 days

Twelve case reports in the English language medical literature describing side effects from cesium treatment. TDP, torsades de pointes; Vtach, ventricular tachycardia; Vfib, ventricular fibrillation.

Another major distal nephron  $K^+$  secretory pathway, the high conductance BK channel (KCa3.1/KCNMA1) of CNT and CD epithelial cells, is responsible for luminal flow-stimulated  $K^+$  secretion. Since extracellular  $Cs^+$  can reduce effective single-channel conductance of BK channels while also increasing channel open probability [27, 28], the proportional contribution of BK channels to  $K^+$  secretion in the setting of CAH is difficult to predict.

The mechanism by which amiloride reduces urinary potassium wasting in the setting of CAH may reflect multiple pathways. Amiloride is known to reduce urinary excretion of rubidium as well as potassium [29, 30].  $Cs^+$  competitively inhibits ENaC in the collecting duct [31], but the much more potent inhibition by amiloride of ENaC-mediated electrogenic  $Na^+$  reabsorption should reduce ROMK-mediated potassium secretion to a greater degree [30].

Amiloride also increased fractional excretion of cesium from 7 to 16.7%, likely reflecting inhibition of tubular  $Cs^+$  reabsorption by the weakly amiloride-sensitive cation channel PKD2L1/TRPP3 [32] and/or other renal TRP channels, or increased  $Cs^+$  secretion by undefined pathways. Serum cesium concentration did not fall after initiation of amiloride treatment, likely reflecting cesium's 75–100 day half-life and its large volume of distribution.[4]. Long-term follow-up of serum and urine cesium concentrations was of insufficient duration to determine the effect of amiloride on total body cesium clearance.

Our patient's serum aldosterone was not suppressed in the presence of his sustained hypokalemia, and aldosterone itself might have contributed to potassium wasting. Failure to suppress aldosterone levels may reflect inhibition by  $Cs^+$  of KCNJ5 [33], a component of the Kir3.4/Kir3.1 hyperpolarizing potassium channel of the adrenal glomerulosa cell. Loss-of-selectivity mutations in this channel are associated with hyperaldosteronism, as are mutants that lead to altered membrane trafficking of the channel [26]. We therefore propose that cesium levels in this patient were high enough to inhibit KCNJ5, leading to chronic glomerulosa cell depolarization accompanied by constitutive aldosterone synthesis and secretion. Patient aldosterone levels post-correction of hypokalemia were unavailable.

Interpretation of our patient's hypokalemia was further confounded by his history of potential  $K^+$ -wasting chemotherapy with cisplatin and carboplatin. However, his hypokalemia appeared only after initiation of self-administered cesium therapy, months after discontinuation of cisplatin and before initiation of carboplatin. The absence of hypomagnesaemia, a frequent complication of cisplatin treatment, further supports cesium as the principal cause of hypokalemia.

Our patient ultimately died from complications of his progressive, metastatic laryngeal cancer. His self-treatment with cesium as part of his struggle with an aggressive cancer illustrates that CAH can be both profound and prolonged. Our case report further supports urinary potassium wasting as the mechanism of CAH, and adds preliminary clinical data suggesting that amiloride therapy can mitigate urinary potassium loss. Additional studies will be required to further elucidate molecular participants in CAH.

**Acknowledgements.** We thank Drs Paul A. Welling and David H. Vandorpe for helpful discussion.

**Conflict of interest statement.** None declared.

## References

1. Brewer AK. The high pH therapy for cancer tests on mice and humans. *Pharmacol Biochem Behav* 1984; 21(Suppl 1): 1–5
2. Sartori HE. Cesium therapy in cancer patients. *Pharmacol Biochem Behav* 1984; 21(Suppl 1): 11–13
3. Samadani U, Marcotte P. Zero efficacy with cesium chloride self-treatment for brain cancer. *Mayo Clin Proc* 2004; 79: 1588; author reply 1588–1589
4. Melnikov P, Zanoni LZ. Clinical effects of cesium intake. *Biol Trace Elem Res* 2010; 135: 1–9
5. Sessions D, Heard K, Kosnett M. Fatal cesium chloride toxicity after alternative cancer treatment. *J Altern Complement Med* 2013; 19: 973–975
6. Leggett RW, Williams LR, Melo DR et al. A physiologically based biokinetic model for cesium in the human body. *Sci Total Environ* 2003; 317: 235–255
7. Pinter A, Dorian P, Newman D. Cesium-induced torsades de pointes. *N Engl J Med* 2002; 346: 383–384
8. Chan CK, Chan MH, Tse ML et al. Life-threatening Torsades de Pointes resulting from “natural” cancer treatment. *Clin Toxicol (Phila)* 2009; 47: 592–594
9. O'Brien CE, Harik N, James LP et al. Cesium-induced QT-interval prolongation in an adolescent. *Pharmacotherapy* 2008; 28: 1059–1065
10. Dalal AK, Harding JD, Verdino RJ. Acquired long QT syndrome and monomorphic ventricular tachycardia after alternative treatment with cesium chloride for brain cancer. *Mayo Clin Proc* 2004; 79: 1065–1069
11. Vyas H, Johnson K, Houlihan R et al. Acquired long QT syndrome secondary to cesium chloride supplement. *J Altern Complement Med* 2006; 12: 1011–1014
12. Khangure SR, Williams ES, Welman CJ. CT brain findings in a patient with elevated brain cesium levels. *Neuroradiol J* 2013; 26: 607–609
13. Wiens M, Gordon W, Baulcomb D et al. Cesium chloride-induced torsades de pointes. *Can J Cardiol* 2009; 25: e329–e331
14. Curry TB, Gaver R, White RD. Acquired long QT syndrome and elective anesthesia in children. *Paediatr Anaesth* 2006; 16: 471–478
15. Lyon AW, Mayhew WJ. Cesium toxicity: a case of self-treatment by alternate therapy gone awry. *Ther Drug Monit* 2003; 25: 114–116
16. Saliba W, Erdogan O, Niebauer M. Polymorphic ventricular tachycardia in a woman taking cesium chloride. *Pacing Clin Electrophysiol* 2001; 24(4 Pt 1): 515–517
17. Young F, Bolt J. Torsades de pointes - a report of a case induced by caesium taken as a complementary medicine, and the literature review. *J Clin Pharm Ther* 2013; 38: 254–257
18. Lam YL, Zeng W, Sauer DB et al. The conserved potassium channel filter can have distinct ion binding profiles: Structural analysis of rubidium, cesium, and barium binding in NaK2K. *J Gen Physiol* 2014; 144: 181–192
19. Welling PA, Ho K. A comprehensive guide to the ROMK potassium channel: form and function in health and disease. *Am J Physiol Renal Physiol* 2009; 297: F849–1863
20. Wang T. Renal outer medullary potassium channel knockout models reveal thick ascending limb function and dysfunction. *Clin Exp Nephrol* 2012; 16: 49–54
21. Payne JA, Rivera C, Voipio J et al. Cation-chloride co-transporters in neuronal communication, development and trauma. *Trends Neurosci* 2003; 26: 199–206
22. Sackin H, Syn S, Palmer LG et al. Regulation of ROMK by extracellular cations. *Biophys J* 2001; 80: 683–697
23. Sackin H, Vasilyev A, Palmer LG et al. Permeant cations and blockers modulate pH gating of ROMK channels. *Biophys J* 2003; 84(2 Pt 1): 910–921
24. Wang WH, Giebisch G. Regulation of potassium (K) handling in the renal collecting duct. *Pflugers Arch* 2009; 458: 157–168
25. Edvinsson JM, Shah AJ, Palmer LG. Kir4.1 K<sup>+</sup> channels are regulated by external cations. *Channels (Austin)* 2011; 5: 269–279
26. Cheng CJ, Sung CC, Huang CL et al. Inward-rectifying potassium channelopathies: new insights into disorders of sodium and potassium homeostasis. *Pediatr Nephrol* 2015; 30: 373–383
27. Demo SD, Yellen G. Ion effects on gating of the Ca(2+)-activated K<sup>+</sup> channel correlate with occupancy of the pore. *Biophys J* 1992; 61: 639–648
28. Solaro CR, Ding JP, Li ZW et al. The cytosolic inactivation domains of BK channels in rat chromaffin cells do not behave like simple, open-channel blockers. *Biophys J* 1997; 73: 819–830
29. Beck FX, Dorge A, Giebisch G et al. Studies on the mechanism of rubidium-induced kaliuresis. *Kidney Int* 1989; 36: 175–182
30. Wen D, Cornelius RJ, Rivero-Hernandez D et al. Relation between BK-alpha/beta4-mediated potassium secretion and ENaC-mediated sodium reabsorption. *Kidney Int* 2014; 86: 139–145
31. Palmer LG. Ion selectivity of epithelial Na channels. *J Membr Biol* 1987; 96: 97–106
32. Dai XQ, Ramji A, Liu Y et al. Inhibition of TRPP3 channel by amiloride and analogs. *Mol Pharmacol* 2007; 72: 1576–1585
33. Dibb KM, Rose T, Makary SY et al. Molecular basis of ion selectivity, block, and rectification of the inward rectifier Kir3.1/Kir3.4 K(+) channel. *J Biol Chem* 2003; 278: 49537–49548

Received for publication: 21.12.14; Accepted in revised form: 26.2.15