



OPEN ACCESS

Case of laparoscopic-assisted anorectoplasty performed with temporary umbilical loop colostomy for high anorectal malformation (rectovesical fistula): a three-stage minimally invasive surgery

Hideki Isa, Hisayuki Miyagi, Daisuke Ishii, Masatoshi Hirasawa

Division of Pediatric Surgery,
Department of Surgery,
Asahikawa Medical University,
Asahikawa, Japan

Correspondence to

Dr Hisayuki Miyagi;
miyagi@mvi.biglobe.ne.jp

Accepted 19 January 2021

SUMMARY

This is the first report of three-stage laparoscopic-assisted anorectoplasty (LAARP) with temporary umbilical loop colostomy aiming for minimally invasive surgery in a boy with high anorectal malformation. The procedure was performed safely and resulted in small inconspicuous wounds. LAARP with temporary umbilical loop colostomy was a sufficiently useful therapeutic approach to high anorectal malformation.

BACKGROUND

Levitt and Peña recommend divided colostomy in the descending colon when creating a stoma for intermediate and high anal atresia.¹ In Japan, loop colostomy is performed in the sigmoid colon or transverse colon for intermediate/high anal atresia in many facilities. By any procedure, a stoma is created in the upper or lower abdomen, which leaves a large surgical wound after closure and which can impose a large aesthetic burden on children who have undergone the procedure. Our department has performed colostomy in the umbilical region for intermediate/high anal atresia (except persistent cloaca) since 2000, and we have obtained satisfactory functional and aesthetic outcomes. The patient reported here is the first case of rectovesical fistula according to the Krinkenburg classification, or high anal atresia, that was treated by laparoscopic-assisted anorectoplasty performed with temporary umbilical loop colostomy in three stages as minimally invasive surgery safely and with a small inconspicuous wound. Three-stage surgery involving laparoscopic-assisted anorectoplasty with temporary umbilical loop colostomy is considered a feasible treatment strategy for high anorectal malformation.

There have been reports of laparoscopic surgery in which the umbilical stoma is hollowed out and used as a camera port, with the stoma closed at the same time.² However, this is the first report of a three-stage laparoscopic operation in which the umbilical region was not used as a camera port, and the umbilical region stoma was left as it was.

CASE PRESENTATION

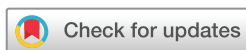The patient was a boy born vaginally at 35 weeks and 5 days of gestation with a birth weight of 1934 g. Single umbilical cord artery, inversion of the left lower limb and anal atresia were noted, and

the boy was admitted to the neonatal intensive care unit of our hospital. Close examination after admission disclosed ventricular septal defect, right fused kidney and congenital hydronephrosis, and tethered cord syndrome, and the condition was considered the VACTERL (vertebral defects, anal atresia, cardiac defects, tracheo-esophageal fistula, renal anomalies, and limb abnormalities) association. Regarding anal atresia, rectourethral fistula was suggested by abdominal ultrasonography at birth, and as abdominal distention intensified, colostomy was selected, and a stoma using the transverse colon was created in the umbilical region (figure 1). The postoperative course was uneventful, and as the boy's body weight exceeded 6 kg 6 months after birth, anorectoplasty was scheduled. A rectovesical fistula was confirmed by preoperative urethrography (figure 2), and, with a diagnosis of high anal atresia, we decided to perform laparoscopic-assisted anorectoplasty.

TREATMENT

The patient was placed in the lithotomy position under general anaesthesia. Cystoscopy was performed first, and the diagnosis of a rectovesical fistula was confirmed by detecting the fistula in the neck of the bladder. A 6 Fr renal pelvic balloon catheter was placed in the rectovesical fistula under cystoscopy and was used as a marker of the rectovesical fistula during the surgery.

Anorectoplasty was performed next. After intestinal lavage, the stoma in the umbilical region was covered with film dressing to prevent faecal leakage into the surgical field. The surgeon stood on the left side of the patient, and an assistant was positioned on each side. The first port was placed in the left upper abdomen and laparotomy was performed by Hasson's open-entry technique (this technique is also used for laparoscopic urachal resection). After confirming the absence of adhesions, a 5 mm port was inserted, and additional 5 mm VersaStep ports (Covidien, USA) were placed on the left side of the abdomen, right side of the umbilicus and right side of the abdomen. Of the four ports, the two ports in the upper abdomen were used for repositioning the camera, by which the lateral and posterior walls of the rectum and the entire fistulous tract could be sufficiently and circumferentially observed. The port in which the camera was not inserted was used by the assistants for deployment manoeuvres. The



© BMJ Publishing Group Limited 2021. Re-use permitted under CC BY-NC. No commercial re-use. See rights and permissions. Published by BMJ.

To cite: Isa H, Miyagi H, Ishii D, et al. *BMJ Case Rep* 2021;**14**:e240389. doi:10.1136/bcr-2020-240389

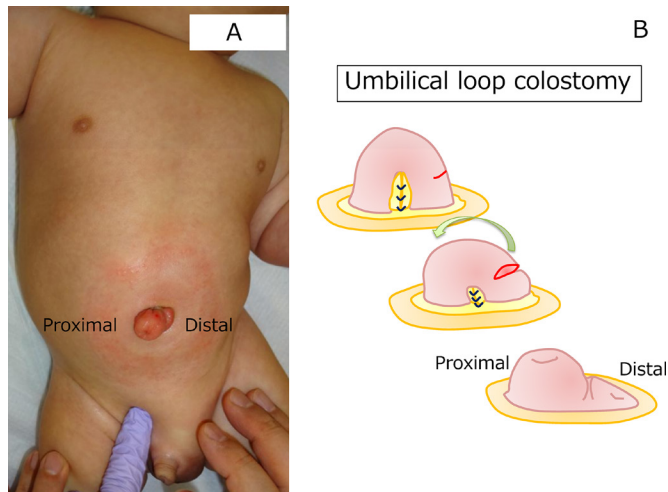


Figure 1 Umbilical stoma. (A) Loop colostomy was performed in the umbilical region. (B) A loop colostomy was created in double-barreled fashion using non-absorbable suture. Figure drawn by Hisayuki Miyagi.

two ports in the lower abdomen were used by the surgeon to manipulate the forceps and energy devices (figure 3).

The rectum was identified and separated from the retroperitoneum, and the rectovesical fistula was located. The entire length of the fistulous tract was checked; a 3–0 Nesporen NES-COSUTURE was inserted, and the tract was ligated; and the rectal side was separated with a Ligasure. Both the bladder side (to the insertion/ligation site) and the rectal stump were ligated using an ENDOLOOP and closed in two layers.

By concomitantly using a nerve stimulator, the centre of the levator ani muscle and coarse tissues were detached, and a pull through route was created. A Penrose drain was inserted into the route, and the route was widened by inserting No. 8–No. 15 Hegar bougies across the Penrose drain. A 12 mm port was inserted from the anal side, the rectum was pulled through this port with anchoring using 4–0 Vicryl at four points, and anoplasty was completed by circumferentially suturing the rectum to the skin using 4–0 Vicryl.

OUTCOME AND FOLLOW-UP

Cystography was performed on the seventh postoperative day, and no bladder diverticulum or leakage was detected. After

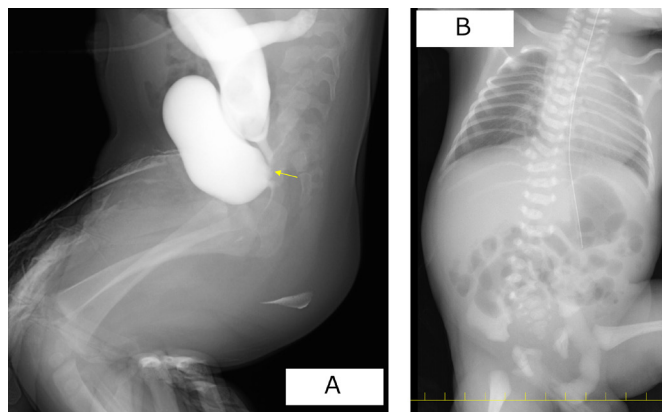


Figure 2 (A) Pressure-augmented colostogram: (A) rectovesical fistula (arrow) was detected, and high anorectal malformation was diagnosed. (B) Chest and abdominal X-ray images at birth showing sacral malformation.

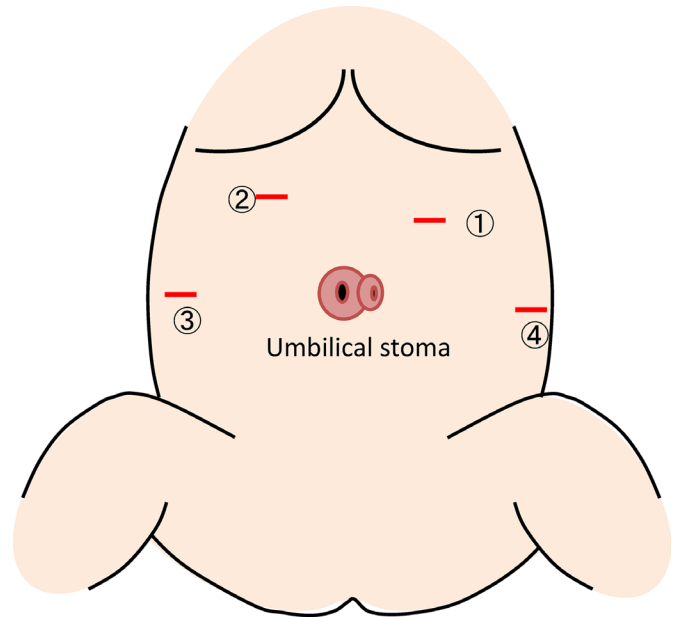


Figure 3 Port arrangement (for laparoscopic-assisted anorectoplasty). The first port (5 mm) was created in the upper left abdomen, and additional 5 mm ports were created in the left lateral abdomen, right upper abdomen and right lateral abdomen. Figure drawn by Hisayuki Miyagi.

withdrawing the urethral balloon, spontaneous urination was confirmed, and the patient was discharged on the eighth postoperative day.

After discharge, we performed anal dilation using Hegar bougies and infusion of sham stools prepared with agar jelly through the distal stoma. We closed the temporary umbilical colostomy 1 month after anorectoplasty. No particular postoperative complication was noted, and the patient was discharged on the seventh postoperative day. During the anorectoplasty, the position of the rectum in the centre of the anal sphincter was confirmed by inserting the ultrasound probe into the anoplasty site in the gluteal region.

Three months after closing the temporary umbilical colostomy (figure 4), no complications have occurred, and unassisted defecation is possible; however, long-term follow-up is necessary.

In fact, this patient had tethered cord syndrome, and untethering operation was performed by a neurosurgeon 2 months after stoma closure. Long-term follow-up is essential to evaluate defecation function.

DISCUSSION

Laparoscopic-assisted anorectoplasty has become a common treatment for high anorectal malformations. Recently, there have also been reports of one-stage³ and two-stage² laparoscopic-assisted anorectoplasty procedures. However, three-stage surgery is considered important at our facility. In three-stage surgery, the temporary colostomy is closed after infusing sham stools through the distal stoma for a period of time to improve disuse atrophy of the intestine, increase the anal-side intestinal capacity, prevent anal skin erosion, and to allow for simple assessment of defecation function after anorectoplasty. The incidence of failure of the sutures after closure of a temporary colostomy in children is approximately 3%,⁴ and both chemical and physical effects are possible with infusion of sham stools before closure. Regarding the chemical effects, Richardson *et al*⁵ reported that infusing

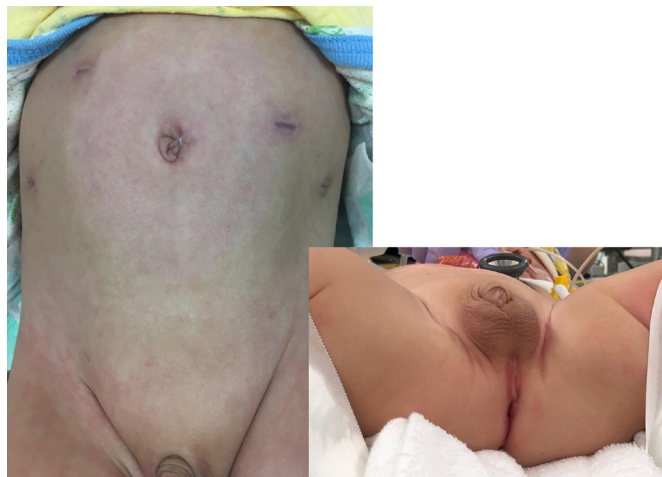

Figure 4 Body surface photographs after laparoscopic-assisted anorectoplasty and colostomy closure: only the scars from the four 5 mm ports are noted, and the umbilical wound is inconspicuous.

sham stools into the distal intestine is expected to induce ‘adaptation’ through cell hyperplasia, intestinal hypertrophy, elongation and hypertrophy of villi, and improved peristalsis and mucus development. Infusing sham stools into the distal side of the stoma also effectively prevents bacterial translocation as well as disuse atrophy of the distal intestine.⁶ Regarding the physical effects, the difference in diameter between the oral and distal stomas is reduced by infusing sham stools into the distal stoma. A decrease in the ratio between the oral and anal intestinal diameters to approximately 2:1 is considered necessary for safe end-to-end anastomosis. For these reasons, we perform sham stool infusions for a set period before anorectoplasty.

Another reason for three-stage surgery is that it is considered appropriate from the viewpoint of covering the stoma because the possibility of complications, such as suture failure after anorectoplasty, cannot be excluded. Oral feeding is possible even on the day of anorectoplasty, using this approach.

Umbilical colostomy in children was reported by Cameron and Lauand⁷ and Hamada *et al.*,⁸ who performed loop colostomy in the umbilical region for intermediate anal atresia, reported (1) minimal surgical complications, (2) good attachment of the stoma bag, (3) easy stoma care, (4) excellent appearance of the umbilicus and (5) no other abdominal wound as advantages of the procedure. Our department has adopted umbilical colostomy for Hirschsprung disease and intermediate and high anal atresia since 2000 as minimally invasive surgery to achieve an inconspicuous surgical wound after colostomy closure. However, if laparoscopic surgery is planned after colostomy, inserting the umbilical port is difficult, and there is concern regarding an increase in postoperative complications, including infection, leading to hesitation in selecting the umbilical region as the colostomy site. If laparoscopic surgery is performed after umbilical colostomy in three-stage surgery, as the umbilicus cannot be used for port insertion, the surgical procedure is expected to be more difficult. However, in the present case, we performed surgery without problems by leaving the umbilical stoma as it was, placing the first port by Hasson’s open-entry technique, and using a total of four ports. Although there is still room for improvement, umbilical colostomy is considered to be worth evaluating in three-stage surgery with the possibility of a laparoscopic approach. In many institutions in Japan, loop colostomy is performed for children with high-type and intermediate-type anorectal malformations.

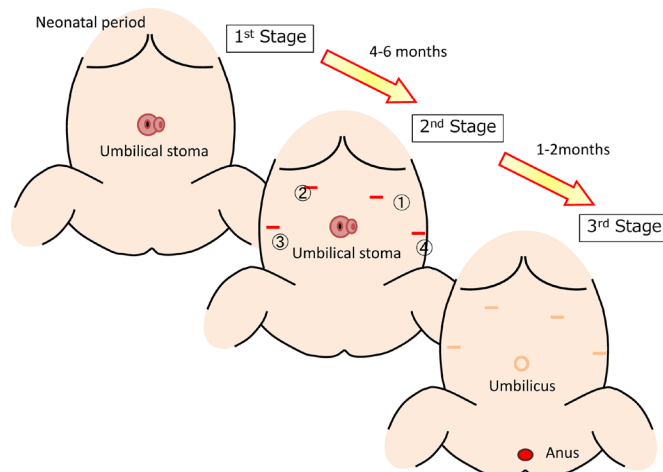


Figure 5 Treatment plan: first stage: for high anal atresia, umbilical colostomy is performed 12–24 hours after birth. Second stage: laparoscopic-assisted anorectoplasty is performed when the child’s body weight reaches 6–7 kg, and infusion of sham stools into the distal stoma is started. Third stage: colostomy closure is performed 1–2 months after anorectoplasty. Figure drawn by Hisayuki Miyagi.

Learning points

- ▶ Umbilical colostomy is aesthetically advantageous and can be combined with minimally invasive surgery.
- ▶ Laparoscopic surgery is possible after temporary umbilical colostomy.
- ▶ To avoid complications, colostomy closure by three-stage surgery is recommended.
- ▶ High anorectal malformation can be treated by laparoscopic-assisted anorectoplasty following temporary umbilical loop colostomy with minimal invasion, leaving no conspicuous wounds.

Recently, some institutions reported that the loop stoma did not make a significant difference in the onset of urinary tract infection (UTI).^{9–11} However, because loop colostomy has been reported to have a higher risk of stoma prolapse than divided colostomy,¹¹ we have selected ways to perform loop colostomy, such as creating the colostomy in double-barreled fashion with a high chimney⁸ using non-absorbable suture (figure 1).

Concerning the postoperative wounds, umbilical colostomy leaves no scars related to the stoma or attached devices; the only scars are at the 5 mm port sites on both sides of the abdomen. The umbilicus is also shaped appropriately and naturally (figure 5).

For radical treatment for intermediate anal atresia, our facility has performed three-stage surgery by creating an umbilical stoma, performing transsacral perineal anoplasty using the Stephens procedure rather than laparoscopic anoplasty, and closing the stoma. We have obtained both aesthetically and functionally satisfactory results without scarring related to the abdominal wounds.

The limitations of this study are that the follow-up period was short and that defecation function must still be evaluated. Evaluating additional cases is also necessary.

In conclusion, we performed laparoscopic-assisted anorectoplasty after temporary umbilical loop colostomy, without problems. The possibility that this procedure interferes with laparoscopic surgery is considered low, and three-stage laparoscopic-assisted anorectoplasty after temporary umbilical

loop colostomy is considered a useful minimally invasive procedure for high anorectal anomalies.

Acknowledgements The author appreciates the assistance of Ranko Hinooka, Certified Nurse in Wound, Ostomy, and Continence Nursing, in the treatment of the patient. We thank Jane Charbonneau, DVM, from Edanz Group (<https://en-author-services.edanzgroup.com/ac>) for editing a draft of this manuscript.

Contributors DI, HM, MH and HI performed the surgical procedure. HI and HM contributed to drafting the manuscript and the literature review, and critically revised the manuscript. All authors read and approved the final manuscript.

Funding The authors have not declared a specific grant for this research from any funding agency in the public, commercial or not-for-profit sectors.

Competing interests None declared.

Patient consent for publication Parents/Guardian consent obtained.

Provenance and peer review Not commissioned; externally peer reviewed.

Open access This is an open access article distributed in accordance with the Creative Commons Attribution Non Commercial (CC BY-NC 4.0) license, which permits others to distribute, remix, adapt, build upon this work non-commercially, and license their derivative works on different terms, provided the original work is properly cited and the use is non-commercial. See: <http://creativecommons.org/licenses/by-nc/4.0/>.

REFERENCES

- Levitt MA, Peña A. Management in the Newborn Period. In: Holschneider AM, Hutson J, eds. *Anorectal malformations in children*. Heidelberg: Springer, 2006: 289–94.
- Yang L, Tang S-T, Li S, et al. Two-Stage laparoscopic approaches for high anorectal malformation: transumbilical colostomy and anorectoplasty. *J Pediatr Surg* 2014;49:1631–4.
- Xiao H, Chen L, Ren X-H, et al. One-Stage Laparoscopic-Assisted anorectoplasty for neonates with anorectal malformation and Recto-Prostatic or Recto-Bulbar fistula according to the Krickenbeck classification. *J Laparoendosc Adv Surg Tech A* 2018;28:1029–34.
- Yadav PS, Choudhury SR, Grover JK, et al. Early feeding in pediatric patients following stoma closure in a resource limited environment. *J Pediatr Surg* 2013;48:977–82.
- Richardson L, Banerjee S, Rabe H. What is the evidence on the practice of mucous fistula refeeding in neonates with short bowel syndrome? *J Pediatr Gastroenterol Nutr* 2006;43:267–70.
- Pinto FEL, Brandt CT, Medeiros AdaC. Bacterial translocation in rats nonfunctioning diverted distal colon. *Acta Cir Bras* 2007;22:195–201.
- Cameron GS, Lau GY. The umbilicus as a site for temporary colostomy in infants. *J Pediatr Surg* 1982;17:362–4.
- Hamada Y, Takada K, Nakamura Y, et al. Temporary umbilical loop colostomy for anorectal malformations. *Pediatr Surg Int* 2012;28:1133–6.
- Kim W, Lee S, Seo J-M. Vesicoureteral reflux increases the risk of urinary tract infection prior to corrective surgery in newborn males with anorectal malformation. *Pediatr Surg Int* 2020;36:1495–500.
- Mullassery D, Iacona R, Cross K, et al. Loop colostomies are safe in anorectal malformations. *J Pediatr Surg* 2018;53:2170–3.
- Youssef F, Arbash G, Puligandla PS, et al. Loop versus divided colostomy for the management of anorectal malformations: a systematic review and meta-analysis. *J Pediatr Surg* 2017;52:783–90.

Copyright 2021 BMJ Publishing Group. All rights reserved. For permission to reuse any of this content visit <https://www.bmj.com/company/products-services/rights-and-licensing/permissions/>
BMJ Case Report Fellows may re-use this article for personal use and teaching without any further permission.

Become a Fellow of BMJ Case Reports today and you can:

- ▶ Submit as many cases as you like
- ▶ Enjoy fast sympathetic peer review and rapid publication of accepted articles
- ▶ Access all the published articles
- ▶ Re-use any of the published material for personal use and teaching without further permission

Customer Service

If you have any further queries about your subscription, please contact our customer services team on +44 (0) 207111 1105 or via email at support@bmj.com.

Visit casereports.bmj.com for more articles like this and to become a Fellow