

Available online at [www.sciencedirect.com](http://www.sciencedirect.com)

journal homepage: [www.elsevier.com/locate/radcr](http://www.elsevier.com/locate/radcr)

## Case Report

# Successful aspiration thrombectomy in a patient with submassive, intermediate-risk pulmonary embolism following COVID-19 pneumonia

Julian Pohlan, MD<sup>a,#,\*</sup>, Sarah Nadine Kamel, MD<sup>b,#</sup>, Giovanni Federico Torsello, MD<sup>a</sup>, Daniel Zickler, MD<sup>b</sup>, Jan Matthias Kruse, MD<sup>b</sup>, Kai-Uwe Eckardt, MD<sup>b</sup>, Bernard Gebauer, MD<sup>a</sup>

<sup>a</sup> Department of Diagnostic and Interventional radiology, Charité – Universitätsmedizin Berlin, Charitéplatz 1, 10117, Berlin, Germany

<sup>b</sup> Department of Nephrology and Medical Intensive Care, Charité – Universitätsmedizin Berlin, Berlin, Germany

### ARTICLE INFO

#### Article history:

Received 7 July 2020

Revised 11 July 2020

Accepted 11 July 2020

Available online 16 July 2020

#### Keywords:

Acute pulmonary embolism

Catheter directed therapy

Aspiration thrombectomy

Right ventricle dysfunction

Right heart strain

### ABSTRACT

A 64-year-old female patient presented with severe dyspnea shortly after apparent recovery from COVID-19 disease. Chest computed tomography revealed central pulmonary embolism and ultrasonography showed a deep vein thrombosis of her right leg. The patient was tachycardiac with evidence of right ventricular strain on echocardiography. An interdisciplinary decision for interventional therapy was made.

Angiographic aspiration thrombectomy resulted in a significant reduction of thrombus material and improved flow in the pulmonary arteries and immediate marked clinical improvement and subsequent normalization of functional echocardiographic parameters.

This case adds to the emerging evidence for severe thromboembolic complications following COVID-19 and suggests aspiration thrombectomy can be considered in pulmonary embolism of intermediate risk.

© 2020 The Authors. Published by Elsevier Inc. on behalf of University of Washington.

This is an open access article under the CC BY-NC-ND license.

(<http://creativecommons.org/licenses/by-nc-nd/4.0/>)

## Introduction

### Background

Pulmonary embolism (PE) is a potentially fatal condition associated with right heart strain and circulatory arrest [1,2]. Only

recently has pulmonary embolism been identified to be a serious complication of COVID-19 [3,4].

Treatment options for PE comprise both systemic therapeutic anticoagulation or lysis, and local therapies [5–7]. Current guidelines stratify patients with PE into a low-risk group, best treated with anticoagulation, and a high-risk group with massive thromboembolism and hypotension in need of systemic thrombolysis [5].

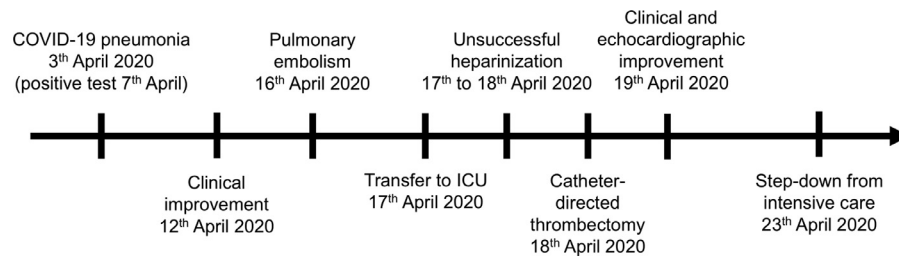
\* Corresponding author.

E-mail address: [julian.pohlan@charite.de](mailto:julian.pohlan@charite.de) (J. Pohlan).

# Both authors contributed equally.

<https://doi.org/10.1016/j.radcr.2020.07.028>

1930-0433/© 2020 The Authors. Published by Elsevier Inc. on behalf of University of Washington. This is an open access article under the CC BY-NC-ND license. (<http://creativecommons.org/licenses/by-nc-nd/4.0/>)



**Fig. 1 – Timeline of events.**

Echocardiography is a highly relevant diagnostic tool for quantification of right ventricular dysfunction in PE, with proven prognostic value [8,9]. An intermediate-risk group with submassive PE, that is, right ventricular strain but no hypotension, might benefit from thrombolysis, since it may prevent cardiac decompensation [5,10]. However, especially in patients with an intermediate risk, the expected clinical benefit of systemic thrombolysis must be weighed against the bleeding risk [10].

Catheter-directed therapy is considered as an alternative to systemic treatment [5]. A meta-analysis of catheter-directed treatment reports a clinical success rate of 86.5% with a rate of major complications of 2.4% [11]. Complications of catheter-directed therapies include perforation of the pulmonary artery or cardiac structures causing tamponade, stroke, or death [12]. Current data suggest a similar effectiveness of catheter-directed thrombolysis and thrombectomy [13], which supports an individualized approach with interdisciplinary discussion.

### Case report

A 64-year-old female patient presented to the emergency department of an external hospital with sudden onset of severe shortness of breath and right leg pain. In the previous 2 weeks, she had suffered from COVID-19 pneumonia, that is, clinical diagnosis with a throat swab positive for Sars-Cov-2 infection in an emergency department. Hospitalization was not recommended at that time. Nine days after onset of her symptoms, she experienced a significant improvement of fever, weakness, and cough, before her condition deteriorated again 6 days later (Fig. 1).

She had no preexisting medical conditions and was not on any regular medication. During her COVID-19 disease, she took paracetamol occasionally for symptom relief. At that time, she was ill at home and reduced her daily activities, but did not maintain bed rest. The patient had recently retired as a nurse serving on an intermediate care ward.

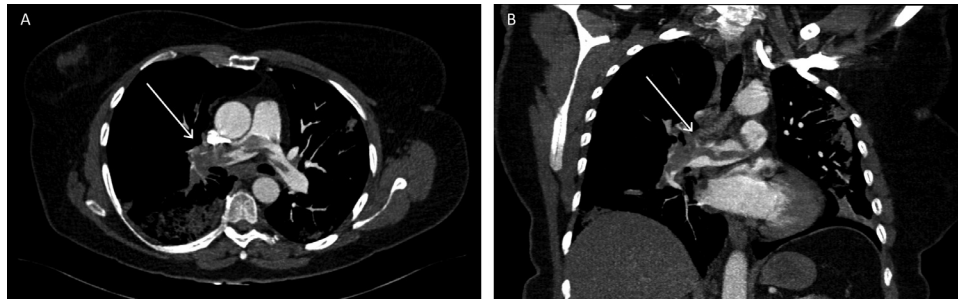
Based on the patient's clinical presentation with tachycardia and shortness of breath, a color-coded Doppler sonography of the right leg as well as a contrast enhanced chest computed tomography (CT) scan were performed. These examinations revealed a deep vein thrombosis in the right leg and a massive PE mainly affecting the right pulmonary trunk (Fig. 2). Since the patient was considered to have intermediate-risk PE with normal blood pressure and 90% oxygen saturation under room air with a moderately

elevated respiratory rate of 30/min, she was treated by anticoagulation with unfractionated heparin. As the chest CT scan also revealed bilateral patchy infiltrates as a sign of bilateral pneumonia along with an elevated CRP level, the patient was started on intravenous antibiotic therapy with sultamicillin.

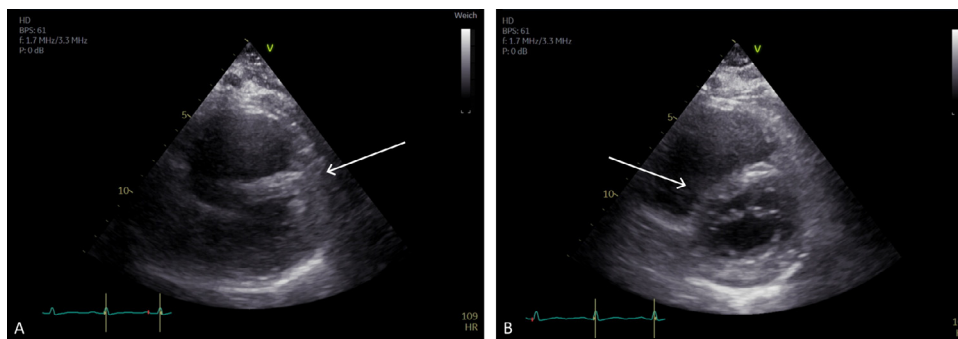
Due to limited capacity of the hospital to which she initially presented, she was then transferred to the intensive care unit (ICU) of our hospital, where she continued to be tachycardic, but normotensive with an oxygen saturation of 96% at 3-4l oxygen via a breathing mask. The slightest exertion, even conversation, caused severe dyspnea. Additionally, she complained about breathing-dependent right thoracic pain. Transthoracic echocardiography at this time showed a dilated right ventricle with septal bowing (Fig. 3). A tricuspid annular plane systolic excursion of 1.9 cm and a hyperdynamic small left ventricle, along with elevated levels of NT-proBNP (3936 ng/l) and troponin (31 ng/l), indicative of right heart strain. A positive D-Dimer was at 18.3 mg/l at that time. TSH was normal at 0.48 mU/l. There was no clinical or laboratory evidence of hepatic or renal impairment.

The patient was still considered at intermediate-risk for PE, as she did not require hemodynamic stabilization. Furthermore, the possibility was considered that the patient's pneumonia might contribute to her severe dyspnea. The diagnosis of pneumonia was based on imaging findings, that is, consolidations on CT, no microbiological proof of bacterial infection was noted. Because of her serious clinical condition and proven right heart strain, we discussed systemic lysis as well as other therapeutic approaches. Following interdisciplinary consultation, we decided to perform an angiographic aspiration thrombectomy.

The patient provided informed consent for the procedure. Ultrasound indicated a patent left femoral vein, while the right femoral vein was known to be occluded from thrombosis. After local anesthesia, left femoral venous puncture was performed for access. The pulmonary trunk was accessed via the right atrium and chamber using a pigtail catheter over an inverse and preformed 0.035" stiff guide wire (J-wire). Angiography confirmed the largest thrombus burden in the central right pulmonary artery, which was accessed using a hydrophilic 0.035" guide wire (Radiofocus, Terumo Interventional Systems, Tokyo, Japan) and a vertebral catheter. A 90-cm long 6F sheath (Destination, Terumo) was advanced to the level of the right pulmonary artery. Over the stiff Amplatz wire (Boston Scientific, North Quincy, MA), the aspiration thrombectomy system (AngioJet, Boston Scientific) was introduced and suction thrombolysis started with 5000 IU of



**Fig. 2 – (A, B) CT scan in axial (A) and coronary (B) reformation at 3 mm, showing central pulmonary embolism and main thrombus load in the right pulmonary artery. White arrows pointing at the right pulmonary artery in axial and coronary reformation.**



**Fig. 3 – (A, B) Preinterventional echocardiography (A) reveals right ventricular enlargement with septal bowing. Following aspiration thrombectomy (B), right ventricular strain is reduced with normalization of right/left ventricular ratio (R/V ratio). White arrows pointing at the septum.**

unfractionated heparin. Alternatingly, a pigtail catheter was used to mechanically fractionate the thrombus. As the aspiration time is limited by an increasing risk of hemolysis, the procedure was only continued until the thrombus burden was markedly reduced. Eventually, blood flow was significantly improved both in the right pulmonary artery and in the lung periphery (Fig. 4). With only residual wall-adherent thrombus left in the right artery, no thrombolysis catheter for local thrombolysis was introduced. Catheter material was then carefully removed with manual compression of the puncture site.

During the intervention, the patient received mild sedation only with continuous monitoring by electrocardiography, invasive blood pressure measurement, and continuous oxymetry. The procedure was paused repeatedly to mild-to-moderate cardiac bradyarrhythmia, causing patient discomfort. The patient's heart rate normalized immediately after successful thrombectomy and shortly thereafter the patient reported a significant improvement of dyspnea.

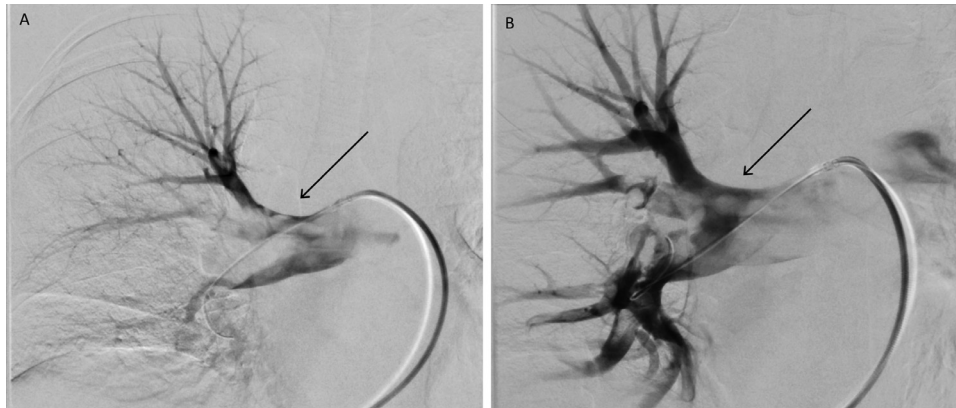
During the subsequent monitoring in our ICU, no arrhythmia, bleeding of the puncture site, or any other complication occurred. Her clinical presentation and global heart function, as determined by echocardiography, markedly improved. Accordingly, the previously elevated NTproBNP fell to 1735 ng/l. Anticoagulation therapy was changed to low-molecular weight heparin with monitoring of anti-Xa activity. Five days

later, the patient was transferred back to the regular ward of the external hospital for further treatment.

## Discussion

This case report illustrates impressive clinical improvement following aspiration thrombectomy in a patient with submassive PE due to COVID-19. Also, this adds to the accumulating evidence for thromboembolic complications of COVID-19 [3]. The mechanisms inducing enhanced coagulation remain incompletely understood, but are not confined to severe courses of the disease [4]. PE remains a serious condition with high mortality rates despite several treatment options [5]. With the ongoing SARS-nCoV-2 pandemic, an expected rise in the number of patients with PE might challenge healthcare providers. Recent data also imply an increased bleeding risk for the subgroup of patients with COVID-19 with a high risk of thromboembolic events [14]. Prophylactic anticoagulation in patients with COVID-19 – both in severe and in mild cases as this one – is a current matter of discussion.

This patient presented with tachycardia and severe dyspnea on exertion with echocardiographic evidence of right ventricular strain due to PE, and was therefore treated with anticoagulation. As there was no hypotension, we decided against



**Fig. 4 – (A, B) Pulmonary angiography before the intervention (A). After aspiration thrombectomy (B), angiography indicates massively reduced thrombotic material in the central right pulmonary artery. Significantly improved perfusion of upper, middle, and lower right lobes is noted, resulting in greater efficiency of systemic anticoagulation. Black arrows pointing at the right pulmonary artery before and after the intervention.**

systemic thrombolysis due to an unacceptably high bleeding risk. An interdisciplinary discussion brought up the possibility of catheter-directed therapy. The patient was able to provide informed consent.

In this patient with submassive PE, we achieved excellent reperfusion with aspiration thrombectomy alone. Other patients may require adjunct local thrombolysis, which was considered unnecessary in this case. After thrombectomy, the patient's clinical improvement correlated with the recovery of cardiac function. One study reports an advantage of catheter-directed thrombectomy over treatment with anticoagulation only in patients with submassive PE, as reflected by an improvement in the right/left ventricular ratio [15]. Except for mild to moderate cardiac arrhythmias, the patient tolerated the procedure well.

This case supports the hypothesis that patients with intermediate-risk PE may benefit from catheter-directed therapies such as aspiration-thrombectomy. To our knowledge, this is the first report of successful treatment of massive PE with local thrombectomy in a patient with COVID-19. We believe this option should be considered in centers with angiographic expertise. Further studies are needed to gain detailed insights into patient selection and the effectiveness of specific techniques and devices.

Written consent to anonymous publication of this case report was given.

### Declaration of Competing Interest

None.

### Supplementary materials

Supplementary material associated with this article can be found, in the online version, at doi:[10.1016/j.radcr.2020.07.028](https://doi.org/10.1016/j.radcr.2020.07.028).

### REFERENCES

- [1] Bougouin W, Marijon E, Planquette B, Karam N, Dumas F, Celermajer DS, et al. Factors associated with pulmonary embolism-related sudden cardiac arrest. *Circulation* 2016;134(25):2125–7. doi:[10.1161/CIRCULATIONAHA.116.024746](https://doi.org/10.1161/CIRCULATIONAHA.116.024746).
- [2] Carroll BJ, Heidinger BH, Dabreo DC, Matos JD, Mohebbi D, Feldman SA, et al. Multimodality assessment of right ventricular strain in patients with acute pulmonary embolism. *Am J Cardiol* 2018;122(1):175–81. <https://doi.org/10.1016/j.amjcard.2018.03.013>.
- [3] Klok FA, Kruip M, van der Meer NJM, Arbous MS, Gommers D, Kant KM, et al. Incidence of thrombotic complications in critically ill ICU patients with COVID-19. *Thromb Res* 2020. <https://doi.org/10.1016/j.thromres.2020.04.013>.
- [4] Lodigiani C, Iapichino G, Carenzo L, Cecconi M, Ferrazzi P, Sebastian T, et al. Venous and arterial thromboembolic complications in COVID-19 patients admitted to an academic hospital in Milan, Italy. *Thromb Res* 2020;191:9–14. <https://doi.org/10.1016/j.thromres.2020.04.024>.
- [5] Konstantinides S.V., G. Meyer, C. Becattini, H. Bueno, G.-J. Geersing, V.-P. Harjola, et al (2019) 2019 ESC Guidelines for the diagnosis and management of acute pulmonary embolism developed in collaboration with the European Respiratory Society (ERS). The Task Force for the diagnosis and management of acute pulmonary embolism of the European Society of Cardiology (ESC) 54(3) 1901647. <https://doi.org/10.1183/13993003.01647-2019>
- [6] Jaff MR, McMurry MS, Archer SL, Cushman M, Goldenberg N, Goldhaber SZ, et al. Management of massive and submassive pulmonary embolism, iliofemoral deep vein thrombosis, and chronic thromboembolic pulmonary hypertension: a scientific statement from the American Heart Association. *Circulation* 2011;123(16):1788–830. <https://doi.org/10.1161/CIR.0b013e318214914f>.
- [7] Kearon C, Akl EA, Ornelas J, Blaivas A, Jimenez D, Bounameaux H, et al. Antithrombotic therapy for VTE disease: CHEST guideline and expert panel report. *Chest* 2016;149(2):315–52. <https://doi.org/10.1016/j.chest.2015.11.026>.

- [8] Khemasuwan D, Yingchoncharoen T, Tunsupon P, Kusunose K, Moghekar A, Klein A, et al. Right ventricular echocardiographic parameters are associated with mortality after acute pulmonary embolism. *J Am Soc Echocardiogr* 2015;28(3):355–62. <https://doi.org/10.1016/j.echo.2014.11.012>.
- [9] Grifoni S, Olivotto I, Cecchini P, Pieralli F, Camaiti A, Santoro G, et al. Short-term clinical outcome of patients with acute pulmonary embolism, normal blood pressure, and echocardiographic right ventricular dysfunction. *Circulation* 2000;101(24):2817–22. <https://doi.org/10.1161/01.cir.101.24.2817>.
- [10] Meyer G, Vicaute E, Danays T, Agnelli G, Becattini C, Beyer-Westendorf J, et al. Fibrinolysis for patients with intermediate-risk pulmonary embolism. *N Engl J Med* 2014;370(15):1402–11. <https://doi.org/10.1056/NEJMoa1302097>.
- [11] Kuo WT, Gould MK, Louie JD, Rosenberg JK, Sze DY, Hofmann LV. Catheter-directed therapy for the treatment of massive pulmonary embolism: systematic review and meta-analysis of modern techniques. *J Vasc Interv Radiol* 2009;20(11):1431–40. <https://doi.org/10.1016/j.jvir.2009.08.002>.
- [12] Bayiz H, Dumantepe M, Teymen B, Uyar I. Percutaneous aspiration thrombectomy in treatment of massive pulmonary embolism. *Heart Lung Circ* 2015;24(1):46–54. <https://doi.org/10.1016/j.hlc.2014.06.014>.
- [13] Avgerinos ED, Abou Ali A, Toma C, Wu B, Saadeddin Z, McDaniel B, et al. Catheter-directed thrombolysis versus suction thrombectomy in the management of acute pulmonary embolism. *J Vasc Surg Venous Lymphat Disord* 2019;7(5):623–8. <https://doi.org/10.1016/j.jvsv.2018.10.025>.
- [14] Wang T, Chen R, Liu C, Liang W, Guan W, Tang R, et al. Attention should be paid to venous thromboembolism prophylaxis in the management of COVID-19. *Lancet Haematol* 2020;7(5):e362–3. [https://doi.org/10.1016/S2352-3026\(20\)30109-5](https://doi.org/10.1016/S2352-3026(20)30109-5).
- [15] Hennemeyer C, Khan A, McGregor H, Moffett C, Woodhead G. Outcomes of catheter-directed therapy plus anticoagulation versus anticoagulation alone for submassive and massive pulmonary embolism. *Am J Med* 2019;132(2):240–6. <https://doi.org/10.1016/j.amjmed.2018.10.015>.