

case report

Bilateral benign endobronchial schwannomas

Ahmet Bircan,* Nilgun Kapucuoglu,† Onder Ozturk,* Metin Ciris,† Munire Gokirmak,* Ahmet Akkaya*

From the *Department of Pulmonary Medicine and †Department of Pathology, Faculty of Medicine, Suleyman Demirel University, Turkey

Correspondence and reprint requests: Dr. Ahmet Bircan · Department of Pulmonary Medicine · Faculty of Medicine · Suleyman Demirel University · Isparta · Turkey · T: +902462112418 · F: +902462371762 ahbircan@yahoo.com Accepted for publication November 2006

Ann Saudi Med 2007; 27(5): 375-377

Neurofibroma and neurilemmoma are rare tumors of neurogenic origin that may present at any age. Neurilemmoma, also known as schwannoma, is even more uncommon.¹ It typically arises from neural crest cells that encapsulate the nerve sheath and can originate anywhere in the thorax commonly from sympathetic or intercostals nerves, and rarely from the vagal nerves.² Localization of schwannomas in the bronchi or within the pulmonary parenchyma is also very rare.³ Here, we report a case of multiple endobronchial schwannomas with bilateral proximal airway involvement.

CASE

An 80-year-old man was admitted to our hospital with complaints of pleuritic chest pain and dyspnea on exertion which started two months previously. He denied smoking cigarettes, but stated that the walls in his house were plastered with white-stucco, including environmental asbestos minerals. He had no previous history of neurogenic lesions elsewhere. The past and family histories were also unremarkable for neurofibromatosis. Chest examination revealed fine crackles on the left lung fields and breathing sounds were diminished at the left posterior lung base. Chest X-ray showed a linear density on the right side, extending from the hilar region to the pleural surface, with an irregular mass lesion in the hilar region, moderate pleural effusion on the left side, and the syndrome of Chilitiditi. The patient was not cooperative for pulmonary function tests and his arterial blood gases were within normal limits. In addition to chest X-ray, a thorax CT revealed an irregular soft-tissue density with punctuate calcification surrounding and narrowing the left upper lobe bronchus, and left pleural thickening with moderate pleural effusion (Figure 1). Bronchoscopic examination showed mucosal fragility, engorgement and narrowing of the right upper lobe bronchus and nearly complete obliteration of the left upper lobe bronchus with a submucosal tumor. Although the lesions had smooth surfaces, the mucosal biopsies were taken from each one. The histopathologi-

cal examination of each of these biopsies revealed that the tumors were placed under the bronchial epithelium, and composed of fascicles of spindle cells and palisading nuclei without pleomorphism and mitotic activity (Figure 2). The immunohistochemical staining of tumor cells were strongly positive for S-100 protein (Figure 2), and negative for collagen IV, SMA, Desmin and C-kit. CD34 immunoreactivity was detected in scattered cells. According to these findings the pathological diagnosis was reported as bilateral benign peripheral nerve sheath tumor consistent with schwannoma. The therapeutic options for endobronchial schwannomas such as surgery, electrocoagulation or Nd-YAG laser were refused by the patient. A diagnostic thoracentesis and pleural needle biopsy revealed tuberculous pleurisy. Combined antituberculous treatment of isoniazid, rifampicin, ethambutol and pyrazinamide was started. In the follow-

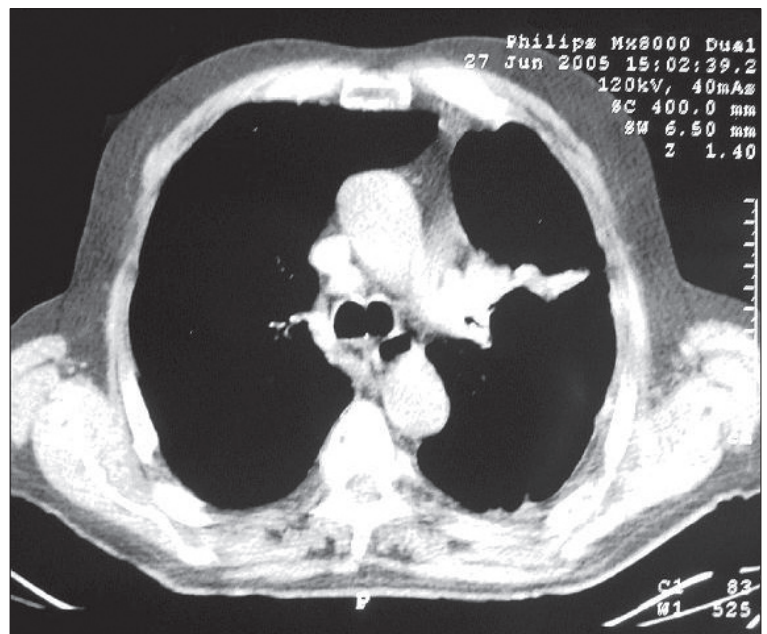


Figure 1. Thorax CT scan showing a soft tissue density obstructing left upper lobe bronchus and segmental atelectasis distal to the density.

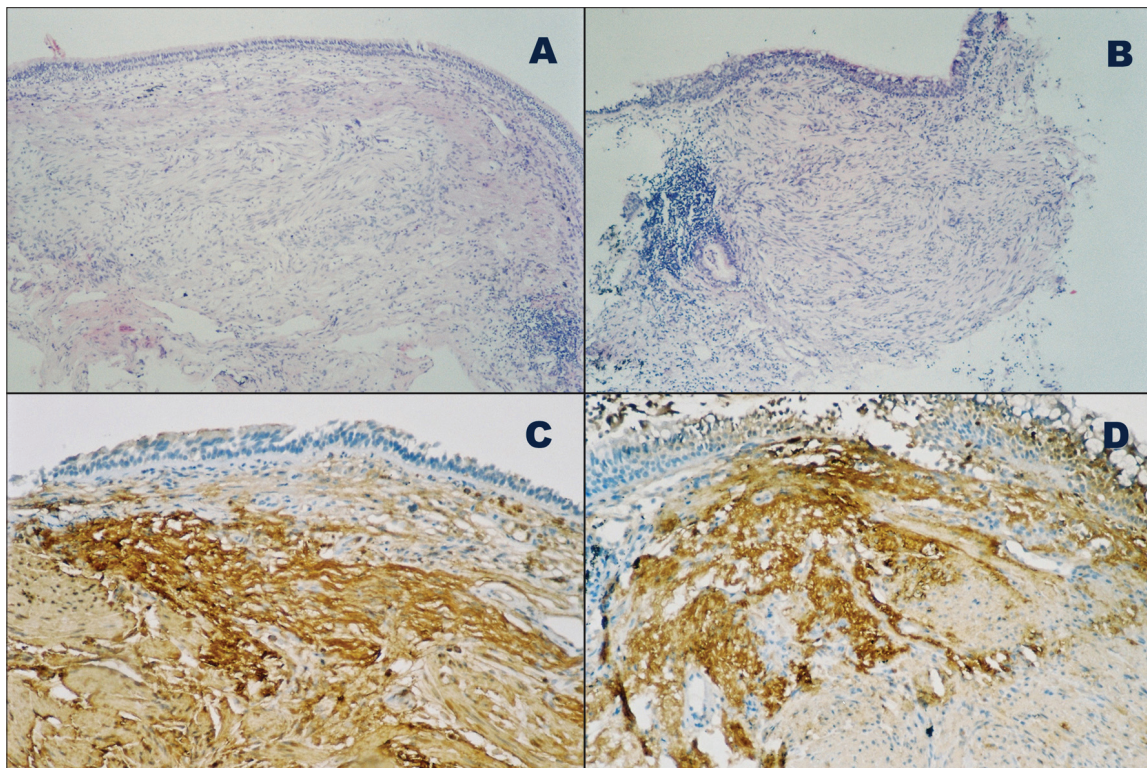


Figure 2. Bilateral bronchial biopsy specimens from right (A,C) and left (B,D) upper lobe bronchus. Fascicles of spindle cells and palisading nuclei are seen under the normal mucosa (HE×40) (A,B). Immunohistochemical staining with S-100 protein revealing strongly stained tumor cells (DAB×100) (C,D).

up period, the symptoms of the patient diminished on the second month of antituberculous treatment.

DISCUSSION

Neurogenic benign tumors arising from the tracheo-bronchial tree are relatively rare.⁴⁻⁷ Benign lung tumors have been reported to account for 1.9 % of total lung tumors and most of them are papilloma (29%), hamartoma (24%) and angioma (10%).⁸ The incidence of intrapulmonary neurogenic tumors was stated as 0.2% in a series of 1664 primary pulmonary tumors.³ Most intrapulmonary neurogenic tumors were neurofibromas, with schwannomas accounting for 25% of the tumors.⁹

Histopathological examination of the biopsy specimens in our case showed no malignant markers such as pleomorphism, atypia or mitotic activity, but schwannomas can demonstrate a degree of cellular pleomorphism and even show a degree of mitotic activity due to a reaction to degenerative change referred as ancient change. The negative staining for collagen IV, although it may be positive around Schwann cells, and the strong diffuse staining for S-100 protein reinforced the diagnosis of schwannoma.

Kasahara et al reviewed 50 cases of pulmonary neurolemmomas reported in Japan and classified them according to their localization as central and peripheral type.¹⁰ Of these 50 cases; 25 were classified as central type (13 at trachea, 12 at bronchus). In our case, the tumors were localized in the upper lobe orifices bilaterally. Two types of tumor extension were described by Kasahara et al, one of them was intraluminal growth and the other was the combined type involving both intraluminal and extraluminal spaces. Bronchoscopic examination and CT findings showed that the tumor extension in our case was of the combined type. To the best of our knowledge, there are only two case reports of endobronchial schwannoma located at two different sites. One of them was reported in the Japanese literature in which the tumors were detected bilaterally by bronchoscopy.¹¹ The other was reported in the English literature in which the tumors were located in the right middle/lower lobe bronchi and in the right basalis anterior/basalis lateralis segmental bronchi.¹² In our case, the tumor nearly completely obliterated the left upper lobe bronchus and the other one was located at the bifurcation of right upper lobe bronchus.

The main symptoms of patients with endobronchial schwannoma are dyspnea, wheezing, cough, sputum production, and hemoptysis.^{3-5,10} Of the cases reported by Kasahara et al, three patients with the central type and all patients with the peripheral type were asymptomatic.⁶ It seems that the symptoms of our case (pleuritic chest pain and dyspnea on effort) were also not due to endobronchial tumors as the symptoms resolved after antituberculous treatment. The existence of a relationship between smoking and neurilemmoma is still unproven. Harada et al speculated that multiple endobronchial schwannomas might be caused by the proliferation of Schwann cells resulting from cigarette smoking followed by inflammation of the bronchial mucosa.¹² The presence of smoking history in all patients (three current and one former smoker) reported by Suzuki et al supported this speculation.¹³ In contrast to these observations, our case denied active or passive cigarette exposure. Accordingly, there are similar cases in the pediatric age group.¹⁴ The relationship between the underlying diseases and schwannoma is also unclear. In this context, newly diagnosed tuberculous pleurisy and a history of environmental asbestos exposure were present in our patient.

It is difficult to distinguish schwannoma from early bronchogenic carcinoma solely on the basis of bron-

choscopic findings.¹³ All bronchoscopic findings in our case were similar to bronchogenic carcinoma apart from bilateral placement of the tumors. Although it is a rare condition, the finding of multiple synchronous lung carcinomas bilaterally during bronchoscopic examination is possible. Endobronchial schwannomas are seen as nodules covered with normal bronchial mucosa bulging into the tracheobronchial lumen or raising the bronchial mucosa with hypervascularity at the spur of the bronchus.^{15,16} In our case bronchoscopic examination was compatible with the latter condition.

Treatment approaches for benign lung schwannomas vary. Interventional bronchoscopic techniques (resection by forceps, electrocoagulation, Nd-YAG laser, laser ablation) and surgical resection such as lobectomy or pneumonectomy are the therapeutic options for benign schwannomas.^{8,10,14,17} Although our patient had nearly complete obstruction of left upper lobe bronchus and atelectasis distal to the obstruction, he was not given treatment since he refused all treatment modalities.

The pathological examination is the cornerstone in the diagnosis of schwannoma, and bronchoscopic examination is recommended for both the diagnosis and treatment. Benign endobronchial schwannomas must be kept in mind in the differential diagnosis of the patient with multiple bronchial tumors.

REFERENCES

1. Tang LF, Chen ZM, Zou CC. Primary intratracheal neurilemmoma in children: case report and literature review. *Pediatr Pulmonol.* 2005; 40: 550-3.
2. Fujio A, Kitano M, Reshad K, Yagi K, Matsui T. A case of intrabronchial neurinoma originated from vagal nerve [in Japanese]. *Nippon Kyobu Shikkan Gakkai Zasshi.* 1984; 32: 126-9.
3. Roviario G, Montorsi M, Varoli F, Binda R, Cecchetto A. Primary pulmonary tumours of neurogenic origin. *Thorax.* 1983; 38: 942-5.
4. Oxner CR, Shinnors MJ, Godin DA, Lyn IT, Brent RB, McFadden PM. Obstructing tracheobronchial schwannoma. *J La State Med Soc.* 2005; 157: 159-61.
5. Chen SR, Chen MH, Ho DM, Lin FC, Chang SC. Massive hemoptysis caused by endobronchial schwannoma in a patient with neurofibromatosis 2. *Am J Med Sci.* 2003; 325: 299-302.
6. Kilani T, Zaimi M, Labbene N, Horchani H, Daoues A, Hammani S, et al. [Endobronchial neurogenic tumors]. *Ann Chir.* 1992; 46: 742-7.
7. Shirakusa T, Takada S, Yamazaki S, Ueda H, Ando K, Kusano T, et al. Intrabronchial neurilemmoma--review of cases in Japan. *Thorac Cardiovasc Surg.* 1989; 37: 388-90.
8. Suzuki H, Sekine Y, Motohashi S, Chiyo M, Suzuki M, Haga Y, et al. Endobronchial neurogenic tumors treated by transbronchial electrical snaring and Nd-YAG laser abrasion: report of three cases. *Surg Today.* 2005; 35: 243-6.
9. Bartey AD, Areal VM. Intrapulmonary neurogenic tumors. *J Thorac Cardiovasc Surg.* 1965; 50: 114-23.
10. Kasahara K, Fukuoka K, Konishi M, Hamada K, Maeda K, Mikasa K, et al. Two cases of endobronchial neurilemmoma and review of the literature in Japan. *Intern Med.* 2003; 42: 1215-8.
11. Yamaguchi M, Ohta K, Suzuki N, et al. [Bilateral endobronchial schwannoma detected by bronchoscopy]. *J Jpn Soc Bronchol.* 1994; 16: 391-6.
12. Harada T, Yamazaki K, Ogura S, Wakabayashi O, Oizumi S, Kojima T, et al. Multiple endobronchial schwannomas arising at the bronchial spur of two different sites. *J Bronchol.* 2003; 10: 195-7.
13. Suzuki M, Matsuoka R, Nagayama T, Kitamura S. Four cases of small endobronchial neurilemmomas. *J Bronchol.* 1998; 5: 34-6.
14. Weiner DJ, Weatherly RA, DiPietro MA, Saanders GM. Tracheal schwannoma presenting as status asthmaticus in a sixteen-year-old boy: airway considerations and removal with CO2 laser. *Pediatr Pulmonol.* 1998; 25: 393-7.
15. Feldhaus RJ, Anene C, Bogard P. A rare endobronchial neurilemmoma (Schwannoma). *Chest.* 1989; 95: 461-2.
16. Straus GD, Guckien JL. Schwannoma of the tracheobronchial tree. A case report. *Ann Otol Rhinol Laryngol.* 1951; 60: 242-6.
17. Setty SP, Niehans G, Kelly RF. Endobronchial laser ablation of a tracheal schwannoma. *J Bronchol.* 2005; 12: 52-3.