

## Gardner Syndrome

Maryam Aletaha, MD; Hamid Fateh-Moghadam, MD

Ophthalmic Research Center, Shahid Beheshti University of Medical Sciences, Tehran, Iran

A 24-year-old man presented with a palpable mass in the deep superonasal quadrant of the left orbit which had been present for one year. He had no visual complaints, yet noted multiple hard masses at the right and left mandibular angles. The patient had history of a similar mass in his right orbit which had prompted surgical intervention 2 years earlier. Histopathological evaluation of the right orbital mass had revealed an osteoma.

Ophthalmologic examination disclosed best corrected visual acuity of 20/20 in both eyes, no color vision impairment and briskly reactive pupils with no relative afferent pupillary defect. Intraocular pressure (IOP), slit lamp biomicroscopy and fundus examination were unremarkable and no proptosis or extraocular muscle restriction was noted. An immobile, smooth surfaced lesion in the deep superonasal quadrant of the left orbit was palpable on external examination (Fig. 1). Similar lesions were noted at the right and left mandibular angles (Fig. 2).

Computed tomography (CT) displayed well-circumscribed masses with bone density consistent with osteomas in the right orbital region adjacent to the optic canal, and within the ethmoidal air cells, bilaterally (Fig. 3). Hyperdensity was observed in the left mandible on skull x-ray consistent with an osteoma (Fig. 4). A visual field test was performed to rule out defects caused by compressive optic neuropathy, which revealed to be normal (Fig. 5).

The patient had a significant family history; his mother had died due to an unknown gastrointestinal problem at the age of 40.

The presence of multiple osteomas and a suspicious family history raised a presumptive diagnosis of Gardner syndrome.

Regarding long-term abdominal discomfort, epigastric pain and dyspepsia, gastroesophagoscopy was performed which

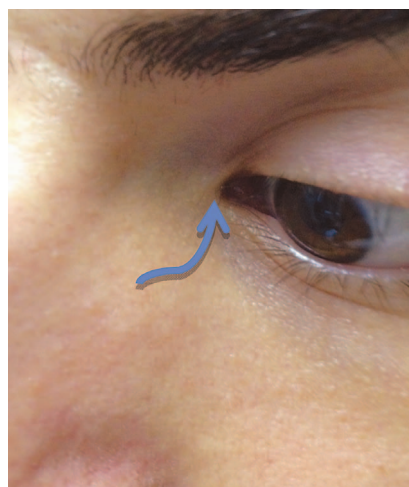


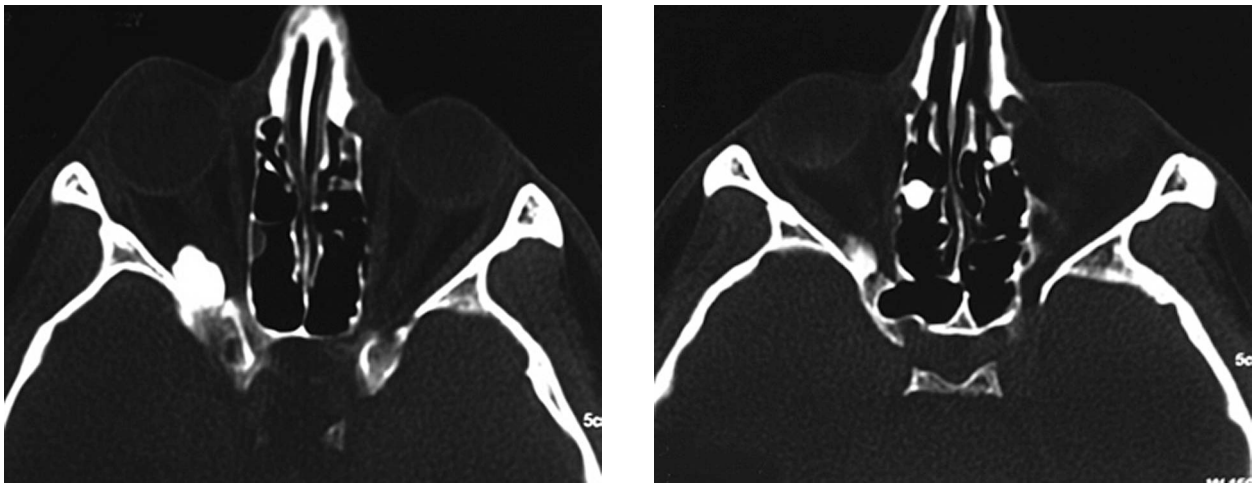
Figure 1. Deep superonasal orbital mass on the left side.

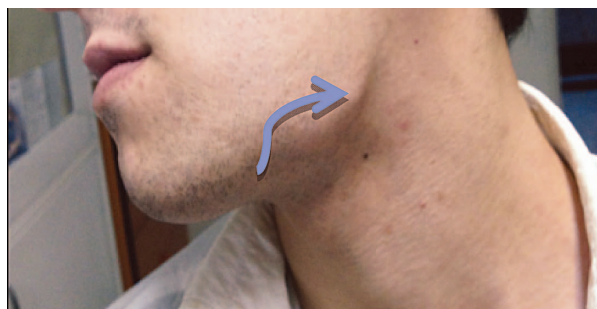

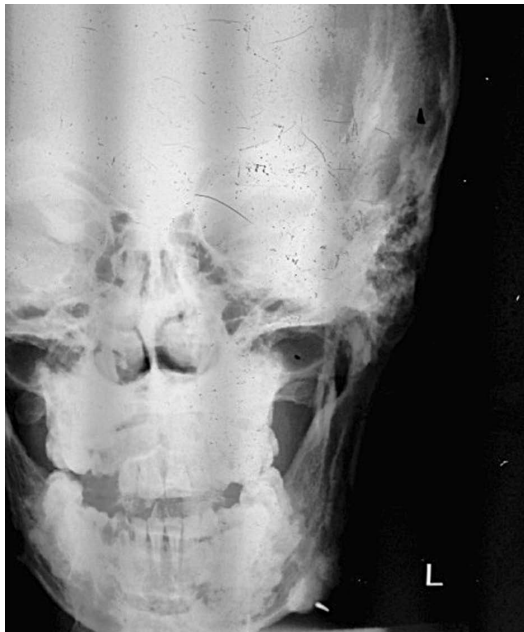Figure 2. Hard immobile mass at the left mandibular angle.

detected multiple large sessile polyps in the fundus and cardia of the stomach, and some small polyps in the prepyloric area (Fig. 6).

With an initial impression of familial adenomatous polyposis (FAP) and Gardner syndrome, the patient underwent colonoscopic examination which likewise revealed multiple sessile polyps in the cecum and ascending colon. Biopsy results showed tubular adenomas with low grade dysplasia. FAP was further confirmed by genetic analysis and the patient underwent total colectomy considering the high risk of colorectal cancer.



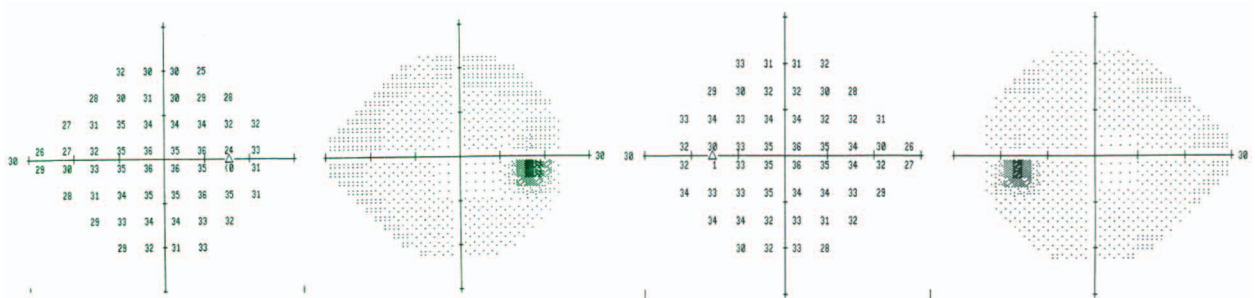
**Figure 3.** Axial computed tomography images; at mid-orbital plane (left image) a well-circumscribed mass with bone density is visible in the posterior region of the lateral wall of the right orbit, the mass seems to compress the optic nerve and optic canal. At a higher plane (right image) two other similar masses are seen within air cells of the right and left ethmoidal sinuses; the more anterior mass was palpable within the superonasal left orbit.



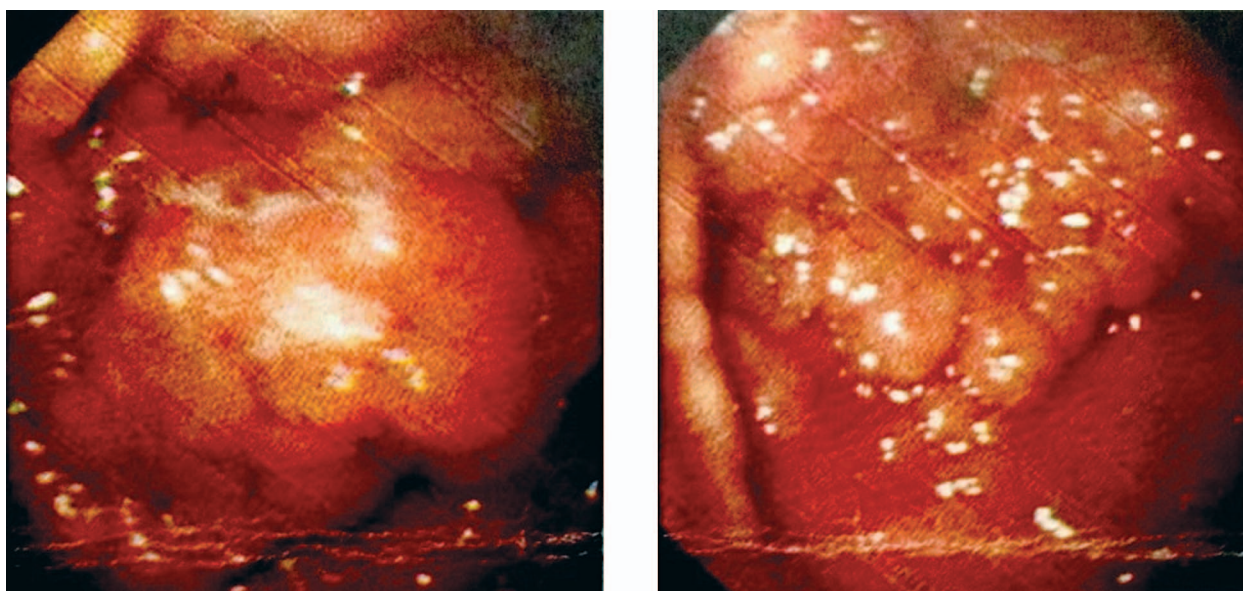
**Figure 4.** Skull x-ray (Caldwell view) shows hyperdensity in the left mandibular arc consistent with an osteoma.

## DISCUSSION

Gardner syndrome (GS) is a rare autosomal dominant disorder with a high degree of penetrance which was first described by Gardner and colleagues in the early 1950s. About one third of all GS cases occur as a result of spontaneous mutations. Mutations of the *MYH* gene (1p34.3-p32.1) on one hand and environmental factors (such as diet, exercise and smoking) on the other, play important roles in the pathogenesis of GS.<sup>1</sup> It has been reported that about 25% of GS patients have no family history and miniaturization of families makes the hereditary pattern less obvious.<sup>2</sup> Gardner syndrome is considered to be a subtype of FAP with a wider spectrum of abnormalities including gastrointestinal polyps, sebaceous cysts and multiple hard and soft tissue tumors such as osteomas and odontomas.<sup>3</sup>



**Figure 5.** Normal right and left visual fields with no evidence of compressive optic neuropathy.



**Figure 6.** Upper gastrointestinal endoscopy of the stomach and duodenum; multiple sessile and multi-lobulated polyps are seen.

The clinical presentation of GS is variable and diagnosis is often delayed, despite the presence of clues for a significant amount of time. Extraintestinal components may be apparent before those in the bowel, and their detection may lead to appropriate evaluation and life-saving treatment of the condition. Extracolonic manifestations include osteomas and congenital hypertrophy of the retinal pigmented epithelium.<sup>1</sup>

In the absence of a positive family history or colorectal polyps, GS may easily go undiagnosed; therefore, the stomach, thyroid, teeth, skull and eyes of any individual with colorectal polyps must be evaluated. Evaluation of *APC* and *MYH* mutations are also recommended to differentiate patients with GS and FAP, however these tests have uncertain diagnostic value.<sup>1</sup>

Osteomas are the hallmark of Gardner syndrome and the mandible is the most common location. However, lesions may appear in the skull, long bones or paranasal sinuses. CT scan may be employed to reveal the precise size and dimensions of the tumors.<sup>3</sup>

Polyps related to GS may be found in any part of the gastrointestinal tract from the stomach to the rectum, particularly in the distal colon. The polyps begin to form in puberty but mean age of symptomatic presentation is 39 years and the lesions have 100% risk of malignant

transformation.<sup>5,6</sup> Accidental radiographic recognition of osseous lesions can lead to early detection of polyps before they undergo malignant differentiation.<sup>3,4</sup>

Other tumors such as papillary thyroid carcinoma, adrenal adenoma and adenocarcinoma, hepatocellular carcinoma, osteosarcoma, chondrosarcoma, osteochondroma, thyroid tumors, liver tumors, and less commonly, hypertrophy of the retinal pigment epithelium have also been reported in association with this syndrome.<sup>4</sup>

In conclusion, adolescents and young adults with cranial osteomas or other features suspicious of Gardner syndrome are required to undergo colonoscopic studies; establishing a correct diagnosis by an ophthalmologist may lead to a life-saving intervention.

#### Conflicts of Interest

None.

#### REFERENCES

1. Gu GL, Wang SL, Wei XM, Bai L. Diagnosis and treatment of Gardner syndrome with gastric polyposis: a case report and review of the literature. *World J Gastroenterol* 2008;14:2121-2123.

2. Silva CA, Moraes Pde C, Furuse C, Junqueira JL, Thomaz LA, de Araújo VC. Gardner syndrome with no clinical family history. *J Craniofac Surg* 2009;20:1186-1189.
3. Oner AY, Pocan S. Gardner's syndrome: a case report. *Br Dent J* 2006;200:666-667.
4. Bess MA, Adson MA, Elveback LR, Moertel CG. Rectal cancer following colectomy for polyposis. *Arch Surg* 1980;115:460-467.
5. Payne M, Anderson JA, Cook J. Gardner's syndrome - a case report. *Br Dent J* 2002;193:383-384.
6. Luk GD. Diagnosis and therapy of hereditary polyposis syndromes. *Gastroenterologist* 1995;3:153-167.