

Office-Based Intraosseous Infiltrations of PRGF in Knee Osteoarthritis: Description of Technique



Antonio Ríos Luna, M.D., Ph.D., Homid Fahandezh-Saddi Díaz, M.D., Ph.D.,
Manuel Villanueva Martinez, M.D., Ph.D., Roberto Prado, Ph.D.,
Sabino Padilla, M.D., Ph.D., and Eduardo Anitua, M.D., Ph.D.

Abstract: Knee osteoarthritis is a low-degree inflammatory condition that involves the whole synovial joint tissues as an organ. Recently, a biological approach using plasma rich in growth factors (PRGF) to tackle not only the synovial joint with intraarticular injections of PRGF, but also the subchondral bone with intraosseous infiltrations has been implemented with promising results. However, this procedure requires sedation, which limits the implementation of the procedure to operating room. We propose a modified and less cumbersome PRGF intraosseous infiltration approach for moderate and severe knee osteoarthritis, conducting the procedure in the ambulatory setting assisted with WALANT (wide-awake local anesthesia no tourniquet) technique. The proposed technique with a minimally invasive local anesthesia involves subcutaneous infiltration of lidocaine and epinephrine in a solution without sedation, and using ultrasound guidance, thereby streamlining the original procedure. This procedure is both a cost-effective and safe approach that may contribute to the widespread use of intraosseous infiltrations.

Introduction

Knee osteoarthritis (KOA) is a sterile low-intensity, long-term inflammatory condition that disrupts the whole synovial joint tissue homeostasis as an organ.¹ There is increasing evidence pointing to subchondral bone as the initial tissue responsible for pain and the low degree of chronic inflammation, which may be the primary driver of KOA.^{1,2} Whereas the intra-articular delivery of therapeutic agents reaches

the synovial membrane (SM) and the articular cartilage (AC), it may make this route insufficient to tackle the subchondral bone.³ A safe and efficacious biological strategy to treat moderate and severe KOA is the combination of intra-articular and intraosseous injections of PRGF.^{4,5} Accordingly, several groups have already showed that this approach is safe, and it provides longer-term clinical benefits compared with intra-articular injections of PRGF alone, in moderate and severe KOA.^{6,7} Moreover, PRGF multimolecular intervention has been shown to positively restore an anti-inflammatory and trophic microenvironment and reduce joint pain and inflammation.^{6,8,9} Whereas the intra-articular injections are carried out in the ambulatory setting, the intraosseous infiltrations are performed in the operating room, assisted by a fluoroscope or ultrasound (US) guidance.^{4,10,11}

WALANT (wide-awake local anesthesia no tourniquet) technique is a minimally invasive local anesthesia involving subcutaneous infiltration of lidocaine and epinephrine in a solution, which is extensively used in the treatment of distal radius fractures and in wide awake hand in-office surgery being both cost-effective and safe approaches.¹²⁻¹⁴

We propose a modified and less cumbersome PRGF intraosseous infiltration approach for moderate and severe KOA by carrying out the procedure in the ambulatory setting assisted with WALANT technique,

From the Traumatología y Cirugía Ortopédica, Clínica Orthoindal, Almería, Spain (A.R.L.); Traumatología y Cirugía Ortopédica, Hospital de Alcorcón, Madrid, Spain (H.F.S.D.); Centro Médico Avañfi, Madrid (M.V.M.), and BTI Biotechnology Institute ImasD, Vitoria, Spain (R.P., S.P., E.A.).

The authors report the following potential conflicts of interest or sources of funding: E.A. reports that he is the director of BTI Biotechnology Institute, a biomedical company that investigates the fields of regenerative medicine and PRGF-Endoret technology. S.P. reports that he is a scientist at BTI Biotechnology Institute. R.P. reports that he is a scientist at BTI Biotechnology Institute. Full ICMJE author disclosure forms are available for this article online, as [supplementary material](#).

Received December 3, 2021; accepted January 11, 2022.

Address correspondence to Antonio Ríos Luna, M.D., M.D., Calle Rafael Alberti, 5, Department of Traumatología y Cirugía Ortopédica, Clínica Orthoindal, Almería 04004 - Spain. E-mail: antonioriosluna@gmail.com

© 2022 THE AUTHORS. Published by Elsevier Inc. on behalf of the Arthroscopy Association of North America. This is an open access article under the CC BY-NC-ND license (<http://creativecommons.org/licenses/by-nc-nd/4.0/>).
2212-6287/211723

<https://doi.org/10.1016/j.eats.2022.01.009>

without sedation, and using US guidance, thereby streamlining the original procedure.

General Considerations

The study was carried out in accordance with the international standards from the latest revised World Medical Association Declaration of Helsinki (Brazil, 2013). Patients whose KOA diagnosis was Ahlback degree II, III, and IV based on clinical symptoms and radiographic findings are treated with the proposed approach. In the first procedure, each patient receives one intraarticular injection and two intraosseous infiltrations of PRGF (one in tibial plateau and the other in femoral condyle). Two more weekly intra-articular injections of PRGF are performed.

Surgical Technique (With Video Illustration)

PRGF Preparation

The procedure is carried out in the ambulatory setting. First, to obtain the PRGF the blood withdrawal is performed in the same room where the procedure is implemented. Platelet-rich plasma (PRP) is prepared according to the PRGF-Endoret method.¹⁴ Briefly, 80 mL of peripheral venous blood is withdrawn from the patient and collected in 9-mL tubes containing sodium citrate (3.8% wt/vol) as anticoagulant. Then, the blood tubes are centrifuged at 580 g for 8 min at room temperature in the PRGF-Endoret System IV centrifuge (BTI Biotechnology Institute, S.L., Vitoria, Álava, Spain). The 2-mL plasma fraction located just above the sedimented red blood cells, is collected in a tube without aspirating the buffy coat. This plasma fraction (F2) presents approximately twofold the platelet count of peripheral blood with scarce leukocytes. Prior to the infiltration, the PRGF (F2 fraction) is activated by adding 20 μ L of calcium chloride (10% wt/vol) per milliliter of liquid PRGF.

Patient Preparation

After blood extraction, the patient is positioned supine on the office room table (Video 1). By using an Ultrasound E15 (Alpinion Medical Systems, Seoul, Korea), the joint line, the tibial plateau, and femoral condyle are located, explored, and visualized (Fig 1A). Moreover, after locating the articular line by US examination, the two insertion points in the medial region of the knee where we plan to perform the intraosseous infiltrations are drawn as follows: in the case of tibial plateau 2 cm distally from the knee joint line and 2 cm proximally in the case of femoral condyle. Then, the infiltration area, which encompasses the two entry points and 10 cm area both proximal and distal to the intraosseous infiltration entry point, is prepared with a povidone-iodine solution, finally covering the treatment region with

fenestrated sterile drapes. Therefore, we perform the intraosseous infiltrations in minor procedure rooms with field sterility rather than in the operating room with full sterility. The surgeon wears a mask, sterile gloves, and disposable surgical dressing gown, and the patient is not fully draped.¹⁵

WALANT Injection Technique

In order to provide effective analgesia in a safe manner and perform the intraosseous infiltration procedure without pain and patient's discomfort, a solution of lidocaine 1% (10 mg/mL) with 1:100,000 epinephrine (.005 mg/mL) is used following the WALANT technique.^{13,15} Briefly, a 10-mL syringe is filled with 10 mL of the mentioned solution and 1 mL of 8.4% sodium bicarbonate, thereby obtaining the final solution to be injected. The addition of sodium bicarbonate will reduce the burning sensation associated with a lidocaine injection and will buffer the acidity and normalize the pH of the infiltrated area as well.¹⁶ Although evidence points to 35 mg/kg lidocaine with epinephrine as the upper safe limit, we follow the conservative upper limit of lidocaine of 7 mg/kg as proposed by Lalonde and Martin.¹⁵ For instance, the limit for a patient weighing 70 kg would be 490 mg of 1% lidocaine with 1:100,000 epinephrine, namely, 49 mL of the solution.^{13,17} This is the dose conveyed when the intraosseous procedure is carried out in both knees (4 intraosseous infiltrations). Accordingly, our procedure recommends infiltration of 10 mL of the final solution in each entry point (tibial and femoral), which conveys a final dose of 200 mg of lidocaine. We use a 24 gauge \times 50-mm needle to subcutaneously inject the solution into the two entry points of intraosseous infiltrations as follows.

The injection technique is known as "hole-in-one" anesthesia,¹⁸ and the process is similar in both entry points, tibial plateau, and femoral condyle (Fig 1, B to F). We place the needle on the skin landmark drawn as insertion point and inject the first 2-3 mL under the skin very slowly (Fig 1B). Only in this first injection does the patient experience discomfort. Then, we reinsert the needle through tissue already anesthetized, and 3-4 mL of the solution are administered in a star manner (Fig 1, B to F) by angling the needle appropriately and moving the needle very little, injecting another 3-4 mL deeper with each piercing until making contact with the periosteum, where we plan to insert the trocar and deliver another 2 mL (both in tibial plateau and femoral condyle). In doing so, the patient may experience the discomfort of the needle penetration only once in the first injection.^{17,18} Because of the higher sensitivity of the femoral condyle skin, we recommend adding 3 mL of anesthetic solution in this location. We will wait 30 min to perform the intraosseous infiltrations.

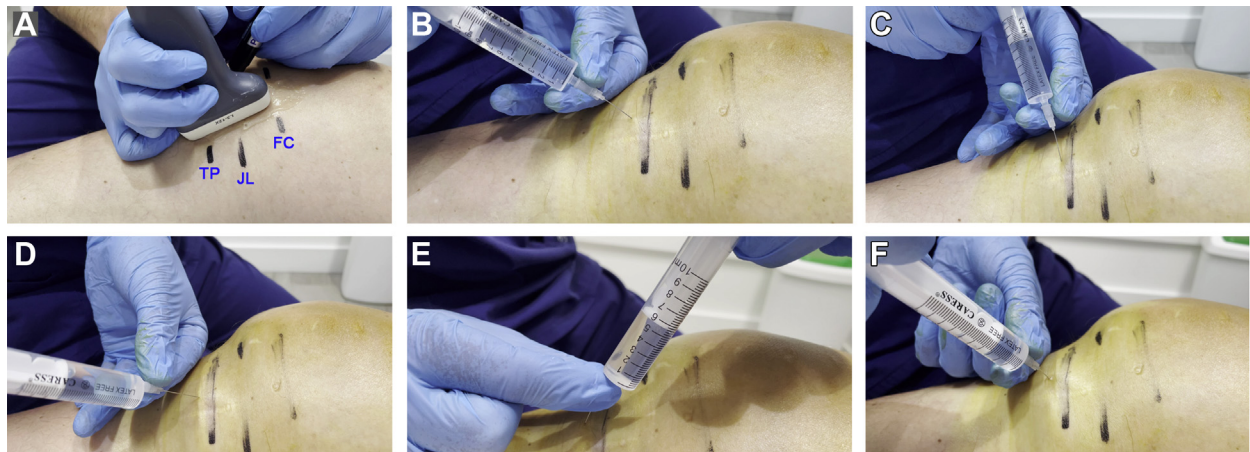


Fig 1. (A) The patient is placed in the supine position and the joint line (JL), the tibial plateau (TP), and femoral condyle (FC) are located using ultrasound. (B to F) Anesthesia injection process in the tibial plateau, according to the WALANT (wide-awake local anesthesia no tourniquet) technique. The needle is introduced through the tissue and the anesthetic (lidocaine and epinephrine solution) is administered in a star manner around and in the place where the trocar is to be inserted. FC, femoral condyle; JL, joint line; TP, tibial plateau.

Intraarticular Infiltration

Once the anesthetic solution is applied, namely, 10 mL into the tibial plateau area and 10 mL into the femoral condyle region, we proceed to infiltrate PRGF intraarticularly (Fig 2A). We activate 8 mL of PRGF (fraction F2) with calcium chloride (10% wt/vol). We use the parapatellar external approach, which avoids crossing the synovial membrane and the consequent pain. We use a 21-gauge needle and place the needle into the joint space. Arthrocentesis is executed first if needed; otherwise, we infiltrate 8 mL of freshly activated PRGF.

Intraosseous Tibial Plateau Infiltration

We recommend waiting 30 min between the injection of local anesthesia and the intraosseous infiltrations. Adequacy of anesthesia is assessed by palpating the area before performing the drilling into the tibial plateau and femoral condyle by asking the patient if he feels anything. We first address the tibial plateau by placing the tip of a 15-G trocar-biopsy needle system (1.8 mm-diameter \times 90 mm length, ARROW OnControl Aspiration needle set, Teleflex Medical Europe Ltd., Dublin, Ireland) on the tibial entry mark point. Then, the trocar is adjusted to a

Fig 2. (A) PRGF intra-articular infiltration via parapatellar external approach. (B) Intraosseous tibial plateau infiltration. The trocar is placed 2 cm distal to the joint line with an inclination of 45° and 1.5 cm deep into the bone (C) Ultrasound image corresponding to trocar insertion of 2B. The area marked with the asterisk shows the entry point into the subchondral bone. The black area is the acoustic shadow produced by the metallic trocar. FC, femoral condyle; JL, joint line; PRGF, plasma rich in growth factors; TP, tibial plateau.

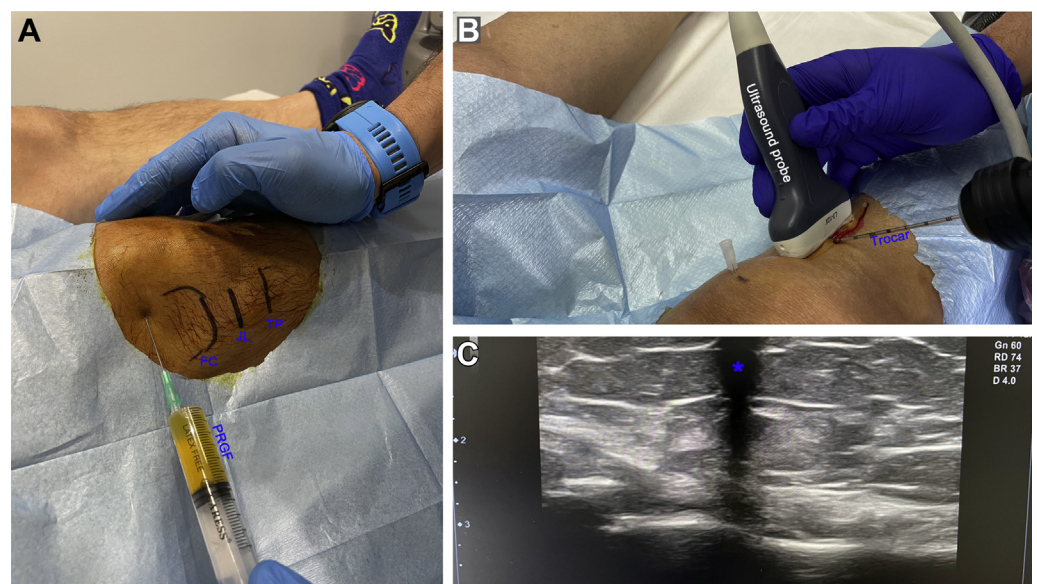


Table 1. Risks and Benefits of the Technique

Risks	
It requires advanced knowledge of ultrasound handling.	
Bending of the trocar can occur if the entry is forced.	
Overheating of the trocar if it is drilled very subchondrally	
Benefits	
No need for sedation or operating room	
Office-based, field sterility procedure	
No preoperative procedures	
No need for a postoperative unit care	
Lower economic costs	
Better time management of surgeon	

power driver (Arrow On Control Powered Bone Access System, Teleflex Medical Europe Ltd., Dublin, Ireland) that is covered with a sterile plastic sleeve. We advance the trocar (Fig 2B) making sure, by using the US image (Fig 2C), that the trocar is placed 2 cm distal to the articular line with an inclination of 45° and 1.5 cm deep into the bone (the trocar possesses laser marks every centimeter).¹⁹ Subsequently, the power driver is removed, the needle core pulled out, and 2 mL of recently activated PRGF F2 liquid is infiltrated gradually through the trocar. Finally, the needle core is inserted into the trocar, adjusted to the power driver and the trocar removed.

Intraosseous Femoral Condyle Infiltration

Accordingly, with the tibial plateau infiltration, we assess the effect of the anesthesia by touching the area. Then we place the tip of a 15-G trocar-biopsy needle system (1.8-mm diameter × 90 mm length, ARROW OnControl Aspiration needle set, Teleflex Medical Europe, Ltd., Dublin, Ireland) on the femoral condyle entry mark point. We adjust the power driver and making sure, by using the US image, that the trocar is placed 2 cm proximal to the articular line with an inclination of 30°, we advance the trocar 1.5 cm deep into the subchondral femoral bone.¹⁹ Subsequently, the power driver is removed and the needle core extracted, and 2 mL of recently activated PRGF F2 liquid is infiltrated gradually through the trocar. Then, and after inserting the needle core into the trocar and adjusting it to the power driver, the trocar is extracted.

Discussion

Knee osteoarthritis is the common end route of various initial triggers leading to a chronic inflammation that ends up disrupting the whole joint homeostasis, with long-term tissue remodeling and fibrosis, pain, and functional limitations of the knee. Sanchez et al.⁴ were the first in describing a “joint-centric” approach to treat severe KOA by applying a combination of intraosseous and intra-articular infiltrations of PRGF as a safe and effective local strategy by tackling the four synovial joint tissues—articular cartilage, synovial fluid, synovial membrane, and subchondral

bone.³⁻⁵ This biological strategy conveys chemotactic, endogenous mesenchymal stem cell homing, and chondrogenic factors such as SDF-1, TGF-β, and fibronectin, and anti-inflammatory and immunomodulatory factors, including but not limited to, TGF-β, HGF, IGF-1 in a sustained and gradual manner, rendering PRP a promising disease-modifying therapy.^{6,8,9} Accordingly, several clinical studies using a combination of intraosseous and intra-articular PRP infiltrations have reported improvement in clinical outcomes of patients with KOA.⁵⁻⁷ Moreover, recently the original PRGF intraosseous infiltration application in KOA has been reported to delay the need for knee arthroplasty between 1.5 and 5 years.²⁰

The incorporation of in-office procedure room intraosseous infiltrations into the therapeutic arsenal to treat moderate and severe KOA may represent a significant step forward for the health care system, patients, and surgeons. Lowering the massive costs entailed by sedation, operating room, postoperative care, and the number of nurses involved in the procedure¹⁴ might ease costs and management burdens and extend the application of PRGF intraosseous infiltration approach for moderate and severe KOA (Table 1). Our proposal keeps the core of the original technique, namely, the combination of intra-articular and intraosseous infiltrations of PRGF.^{3,4} However, we incorporate two modifications regarding the original technique, namely, the WALANT local anesthesia that replaces sedation and the in-office procedure that circumvents the operating room. The local anesthesia WALANT has been extensively used in the treatment of distal radius and hand fractures, carpal tunnel surgery, and tendon repair and transfer in finger and hand in-office surgery being both cost-effective and safe approach.^{12-15,17} The use of local anesthesia eliminates patient sedation, generates a bloodless surgical field, and avoids the postintervention care unit among other benefits.¹⁵ In the original application of intraosseous vascular access as a drug delivery via in emergency context with only aseptic technique, the rate of infection has been reported to be very low.²¹ Significantly, it has been reported that field sterility in the minor procedure room of a clinic or office and full sterility of the main

Table 2. Contraindications and Drawbacks of WALANT Technique for Intraosseous Infiltrations

Relative contraindication	
Patient with moderate anxiety	
Absolute contraindications	
History of vascular injury	
Underlying vascular condition	
Allergies to local anesthetics	
Extreme anxiety	
Drawbacks	
Jitters or trembling following injection	
Vasovagal fainting as in any injection or procedure	

Table 3. Some Pitfalls of the Technique

Insufficient volume of local anesthetic
Inadequate time delay between anesthetic injection and procedure
The use of US is recommended.
Postinfiltration pain is frequent but manageable with painkillers and anti-inflammatory medication.

operating room both present the same low superficial infection rates in carpal tunnel surgery,^{13,22} being lower than .4% and no deep infections have been reported.¹⁵ Regarding pain feeling in conscious patient without WALANT local anesthesia both in trocar insertion and fluid infusion, several research groups have reported a mean visual analog scale (VAS score) between 2.5 and 3.5, similar to scores associated with peripheral and central device placement.²¹ Importantly, as with all procedures, pain is individualized, and additional dosing might be required in WALANT technique in some patients. However, this procedure presents some drawbacks (Tables 2 and 3), as is the 30-minute delay between the application of anesthesia and the procedure. In addition, this procedure is not recommended in elderly people with vascular disorders, which somehow limit the application of WALANT technique. This office-based intraosseous infiltration assisted with WALANT technique and US guidance might be used to inject other therapeutic products into subchondral space.

Conclusion

By replacing sedation for local anesthesia and substituting the operating room by an in-office procedure, we streamline the original approach of intraosseous infiltration of PRGF to treat KOA, making this therapy less cumbersome, more accessible, and cost-efficient, and, therefore, more advantageous for treating this chronic disability.

References

- Brandt KD, Radin EL, Dieppe PA, van de Putte L. Yet more evidence that osteoarthritis is not a cartilage disease. *Ann Rheum Dis* 2006;65:1261-1264.
- Suri S, Walsh DA. Osteochondral alterations in osteoarthritis. *Bone* 2012;51:204-211.
- Sanchez M, Anitua E, Delgado D, et al. A new strategy to tackle severe knee osteoarthritis: Combination of intra-articular and intraosseous injections of platelet-rich plasma. *Expert Opin Biol Ther* 2016;16:627-643.
- Sanchez M, Fiz N, Guadilla J, et al. Intraosseous infiltration of platelet-rich plasma for severe knee osteoarthritis. *Arthrosc Tech* 2014;3:e713-717.
- Sanchez M, Delgado D, Sanchez P, et al. Combination of intra-articular and intraosseous injections of platelet-rich plasma for severe knee osteoarthritis: A pilot study. *Bio-med Res Int* 2016;2016:4868613.
- Sanchez M, Delgado D, Pompei O, et al. Treating severe knee osteoarthritis with combination of intra-osseous and intra-articular infiltrations of platelet-rich plasma: An observational study. *Cartilage* 2019;10:245-253.
- Su K, Bai Y, Wang J, Zhang H, Liu H, Ma S. Comparison of hyaluronic acid and PRP intra-articular injection with combined intra-articular and intraosseous PRP injections to treat patients with knee osteoarthritis. *Clin Rheumatol* 2018;37:1341-1350.
- Vaquerizo V, Plasencia MA, Arribas I, et al. Comparison of intra-articular injections of plasma rich in growth factors (PRGF-Endoret) versus durolane hyaluronic acid in the treatment of patients with symptomatic osteoarthritis: A randomized controlled trial. *Arthroscopy* 2013;29:1635-1643.
- Sanchez M, Fiz N, Azofra J, et al. A randomized clinical trial evaluating plasma rich in growth factors (PRGF-Endoret) versus hyaluronic acid in the short-term treatment of symptomatic knee osteoarthritis. *Arthroscopy* 2012;28:1070-1078.
- Fiz N, Perez JC, Guadilla J, et al. Intraosseous infiltration of platelet-rich plasma for severe hip osteoarthritis. *Arthrosc Tech* 2017;6:e821-e825.
- Fiz N, Delgado D, Garate A, et al. Intraosseous infiltrations of platelet-rich plasma for severe hip osteoarthritis: A pilot study. *J Clin Orthop Trauma* 2020;11:S585-S590.
- Ahmad AA, Yi LM, Ahmad AR. Plating of distal radius fracture using the wide-awake anesthesia technique. *J Hand Surg Am* 2018;43:1045 e1041-1045 e1045.
- Lalonde D. Minimally invasive anesthesia in wide awake hand surgery. *Hand Clin* 2014;30:1-6.
- Van Demark RE Jr, Becker HA, Anderson MC, Smith VJS. Wide-awake anesthesia in the in-office procedure room: Lessons learned. *Hand (N Y)* 2018;13:481-485.
- Lalonde D, Martin A. Epinephrine in local anesthesia in finger and hand surgery: The case for wide-awake anesthesia. *J Am Acad Orthop Surg* 2013;21:443-447.
- Frank SG, Lalonde DH. How acidic is the lidocaine we are injecting, and how much bicarbonate should we add? *Can J Plast Surg* 2012;20:71-73.
- Hyatt BT, Rhee PC. Wide-awake surgical management of hand fractures: Technical pearls and advanced rehabilitation. *Plast Reconstr Surg* 2019;143:800-810.
- Lalonde DH. "Hole-in-one" local anesthesia for wide-awake carpal tunnel surgery. *Plast Reconstr Surg* 2010;126:1642-1644.
- Delgado D, Garate A, Vincent H, et al. Current concepts in intraosseous platelet-rich plasma injections for knee osteoarthritis. *J Clin Orthop Trauma* 2019;10:36-41.
- Sanchez M, Jorquera C, Sanchez P, et al. Platelet-rich plasma injections delay the need for knee arthroplasty: A retrospective study and survival analysis. *Int Orthop* 2021;45:401-410.
- Phillips L. Consortium on intraosseous vascular access in health care settings. Recommendations for the use of intraosseous vascular access for emergent and non-emergent situations in various health care settings: A consensus paper. *J Pediatr Nurs* 2011;26:85-90.
- Leblanc MR, Lalonde DH, Thoma A, et al. Is main operating room sterility really necessary in carpal tunnel surgery? A multicenter prospective study of minor procedure room field sterility surgery. *Hand (N Y)* 2011;6:60-63.