

Laparoscopic adrenalectomy – ten-year experience

Tomasz Szydełko¹, Jarosław Lewandowski¹, Wojciech Panek¹, Krzysztof Tupikowski², Janusz Dembowski², Romuald Zdrojowy²

¹Department of Urology, Clinical Military Hospital, Wrocław, Poland

²Department of Urology and Urological Oncology, University of Medicine, Wrocław, Poland

KEY WORDS

laparoscopy ► adrenalectomy

ABSTRACT

Objectives. The objective of the study is to summarize the authors' 10-year experience with laparoscopic adrenalectomy and to analyze the intra- and postoperative complications of the procedure.

Material and methods. The records of 80 patients who had undergone laparoscopic adrenalectomy from January 2002 to January 2012 were reviewed retrospectively. There were 51 female and 29 male patients. The average age was 52. In 33 cases the right adrenal gland was affected, in 47 it was the left adrenal gland. Nineteen operations were performed with the retroperitoneal approach, in 61 a transperitoneal access was used. The average size of the tumor was 5 cm. The diagnosis was based on ultrasonography (USG) and computed tomography (CT). The biochemical tests were performed in all cases to assess hormonal activity of the tumor. Pheochromocytoma was diagnosed in 16 cases, Cushing syndrome in 3 cases, and Conn syndrome in 4 cases. All other tumors were hormonally inactive. Six patients were operated on because of adrenal metastases – from renal carcinoma in five cases and from lung carcinoma in one case.

Results. There were three open conversions. The mean operative time was 158 minutes. The mean hospital stay was 5.5 days. Blood transfusion was necessary in three patients. Postoperative complications were observed in 11 patients (13.7%).

Conclusions. Laparoscopic adrenalectomy is a safe and effective procedure and should be considered the first – line treatment of benign adrenal masses. Our experience indicates that patients with adrenal metastases are suitable candidates for laparoscopic adrenalectomy, providing a skilled laparoscopic surgeon is involved in operation.

adrenalectomy has become the gold standard in the treatment of benign adrenal tumors, there are still areas of controversy concerning the size for resection of a hormonally inactive incidentaloma and appropriateness of laparoscopic procedures in potentially malignant tumors.

The objective of the study is to summarize the authors' 10-year experience with laparoscopic adrenalectomy and to analyze the intra- and postoperative complications of the procedure.

MATERIAL AND METHODS

We reviewed retrospectively the records of 80 patients who had undergone laparoscopic adrenalectomy from January 2002 to January 2012. The first 64 procedures were performed at the Department of Urology and Urological Oncology, Wrocław University of Medicine, the last 16 (from April 2011) at the Department of Urology, Wrocław Clinical Military Hospital. There were 51 female and 29 male patients. The youngest of them was 29, the oldest was 73. The average age was 52. In 33 cases the right adrenal gland was affected, in 47 it was the left adrenal gland. Nineteen operations were performed with the retroperitoneal approach, in 61 the transperitoneal access was used. The retroperitoneal access was chosen in left-sided hormonally inactive tumors smaller than 6 cm in diameter. In all other cases a transperitoneal procedure was performed. The average size of the tumor was 5 cm (range from 1 to 10 cm). The diagnosis was based on ultrasonography (USG) and computed tomography (CT). All patients underwent biochemical tests at Wrocław University Department of Endocrinology or Department of Endocrinology at Wrocław Military Hospital to assess hormonal activity of the tumor. Pheochromocytoma was diagnosed in 16 cases, Cushing syndrome in three cases, and Conn syndrome in four cases. All other tumors were hormonally inactive. The clinical indications for adrenalectomy were: all hormonally active tumors; hormonally inactive tumors greater than 4 cm in diameter; and smaller than 4 cm, but enlarging on serial examinations (CT performed every 6 months). Laparoscopic adrenalectomies were also performed in six patients with suspected malignancy. Postoperative histology confirmed the metastases from renal carcinoma in five cases and from lung carcinoma in one case.

Operative technique

Transperitoneal approach

The patient was placed in a left 45° flank position. A Hasson 1 cm minilaparotomy was used to create a pneumoperitoneum. The first 10 mm trocar was inserted below the umbilicus in the midline (for right-sided tumors) or at the edge of the rectus muscle (for left-sided tumors) (Fig. 1). The pneumoperitoneum was achieved in a standard manner. Three additional trocars (2x5 mm, 1x10 mm) were inserted under direct vision beneath the costal margin. If the operation was performed on the left side, the left colonic flexure was fully mobilized and the splenorenal ligament was divided to expose the adrenal gland in the retroperitoneal space. Then the

INTRODUCTION

Laparoscopic adrenalectomy, first described by Gagner, Lacroix and Bolte, has rapidly become the reference standard in the treatment of benign adrenal masses [1]. Although there are no prospective randomized trials comparing laparoscopic and open adrenalectomies, based on retrospective studies, many authors indicate that advantages of the laparoscopic technique are: decreased intraoperative blood loss, fewer intra- and postoperative complications, shorter hospital stay, faster recovery, and decreased pain and narcotic use [2, 3]. Although in many centers laparoscopic

renal vein and adrenal vein were exposed. Once freely dissected, the adrenal vein was clipped using titanium clips (TFX Medical Ltd., High Wycombe, UK) and transected. In order to mobilize the adrenal gland a Liga-Sure device (Tyco Healthcare UK Ltd., Gosport, UK) was used. After completing the resection, the specimen was entrapped in an Endocatch bag (Tyco Healthcare UK Ltd., Gosport, UK). A 5-mm closed suction drain was inserted through the port left by the lateral trocar and positioned in the left retroperitoneal space. The adrenal specimen was removed through the 10-mm trocar hole. If the procedure was performed on the right side, the most lateral trocar was used for a fan retractor, which was inserted for liver elevation. The antero-lateral wall of the vena cava was exposed and the right adrenal vein was localized, clipped, and divided. The adrenal gland was then dissected, entrapped in a specimen bag, and removed.

Retroperitoneal approach

The patient was placed in a full flank position. A 2-cm incision was made between the tip of the 12th rib and the iliac crest. After finger dissection, a Hasson 10 mm port was introduced to the retroperitoneal space. Two additional ports were placed – cephalad and lateral (10 mm port) as well as cephalad and medial (5 mm port) to the primary site (Fig. 2). Attaching a fingerless surgical glove to the 10 mm trocar and filling it with 600 ml of air created the working space. The dissection was carried out along the psoas muscle to the upper pole of the kidney. The adrenal gland was identified and detached using a Liga-Sure device. Once the adrenal gland was completely mobilized, the adrenal vein was clipped and divided. The gland was placed in a retrieval bag and removed. A 5 mm closed suction drain was left in place.

RESULTS

There were three open conversions. Blood transfusion was necessary in three patients (overall 9 units). Two patients from that group needed blood transfusion because of the intraoperative injury to the spleen – in one case open conversion was performed, in the other the bleeding was secured by Tachosil® (Nycomed Pharma Sp. z o.o., Poland) and the procedure was completed laparoscopically. A third transfusion was necessary in a patient with a hematoma in the retroperitoneal space, which was observed in the postoperative period. This patient was successfully treated conservatively and did not need reoperation.

In one case the operation had to be stopped because of elevated blood pressure that could not be controlled (260 mmHg). In this particular patient the preoperative biochemical test did not

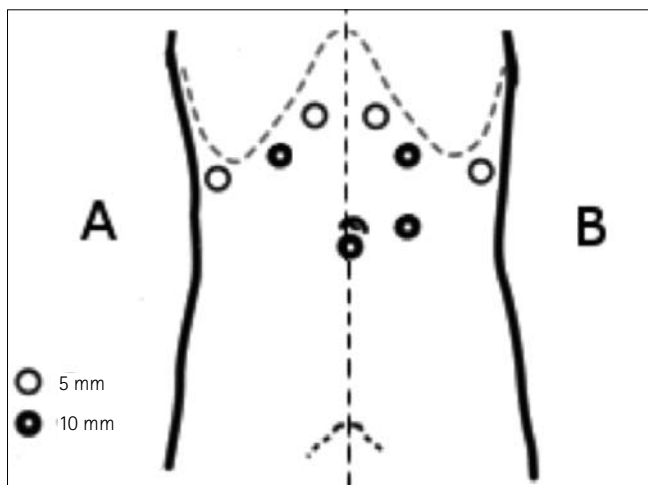


Fig. 1. Trocar placement for transperitoneal laparoscopic adrenalectomy: A – right side, B – left side.

Table 1. Intra- and postoperative complications

| Complications | Number of patients / % |
|-------------------------------------|------------------------|
| <i>Intraoperative complications</i> | |
| Open conversion | 3 / 3.75 |
| Spleen injury | 1 / 1.25 |
| Rise in blood pressure | 1 / 1.25 |
| Overall | 5 / 6.25 |
| <i>Postoperative complications</i> | |
| Grade I | |
| - elevation of pancreatic enzymes | 1 / 1.25 |
| Grade II | |
| - fever | 8 / 10 |
| - intraabdominal hematoma | 2 / 2.5 |
| Overall | 11 / 13.75 |

confirm pheochromocytoma. The procedure was completed laparoscopically with no subsequent complications three days later, after typical 2-day preparation with alpha-blocking agents and adequate hydration.

The shortest operative time was 90 minutes, the longest 440 minutes (mean 158 minutes)

The postoperative complications were observed in 11 patients. In two cases an intraabdominal hematoma was observed and required prolonged drainage. In one patient an elevation of pancreatic enzymes was observed (the serum concentration of the enzymes returned to normal within five postoperative days without treatment). Body temperature rose above 38°C in 8 cases. In one patient a fever was probably caused by a viral infection of the upper respiratory tract. The other patients showed no abnormalities upon physical examination, chest x-ray, and ultrasound of the abdomen. In all cases the fever returned to normal within 3-5 days of antibiotic treatment. The mean hospital stay was 5.5 days (range 2-19 days).

Perioperative parameters, intraoperative complications, and postoperative complications sub-divided according to the 5-grade Clavien classification are shown in Table 1 [4].

DISCUSSION

Laparoscopic adrenalectomy is nowadays a well-documented operative technique. Indications for laparoscopic adrenalectomy

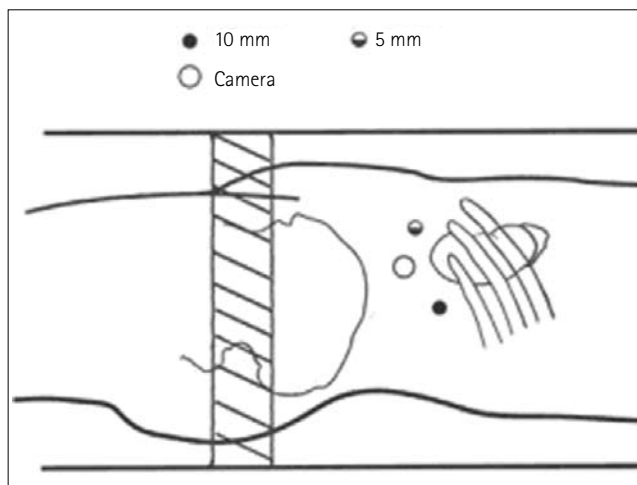


Fig. 2. Trocar placement for left retroperitoneal adrenalectomy.

include primary hyperaldosteronism, pheochromocytomas, and glucocorticoid secreting adrenal tumors (Cushing adenomas).

The indications for minimally invasive surgery remain controversial in some clinical situations involving adrenal tumors (incidentalomas, large size adrenal tumors, adrenocortical carcinomas, adrenal metastases, and bilateral adrenalectomy). Among adrenal incidentalomas, those recommended for surgery (first line: laparoscopic) include: tumors larger than 4 cm, tumors smaller than 4 cm but enlarging in serial CT examinations, secretory tumors, and malignant or potentially malignant tumors [9, 10]. Definitions of 'large size' adrenal tumors vary from 5 to 10 cm in different publications with a consensus of 6-8 cm being the threshold of applicability of laparoscopy [6, 11, 12]. The general consensus is that patients with adrenocortical carcinoma are not candidates for laparoscopic adrenalectomy. However, some authors suggest that, in experienced hands, the laparoscopic approach is not inferior to an open adrenalectomy in resecting localized tumors with diameters less than 10 cm [13, 14]. Patients with adrenal metastases are considered suitable candidates for laparoscopic adrenalectomy providing the involvement of a skilled laparoscopic surgeon in the operation and absence of locoregional invasion after resection of the primary tumor [15]. In our material, six laparoscopic adrenalectomies were performed due to metastasis to the adrenal gland and only one needed conversion to the open procedure.

The choice between lateral transperitoneal (LT) and posterior retroperitoneal (PR) laparoscopic access to the adrenal gland depends on the surgeon's preferences or clinical considerations. In general, transperitoneal access offers a high-volume operative space and the presence of identifiable landmarks. Moreover, the surgeon's overall familiarity with intraperitoneal space is of great importance. In contrast, the retroperitoneal approach enables direct access to the adrenal gland making it applicable in patients after previous intraperitoneal surgery, minimizes the limitations caused by spleen and liver, and often offers a shortened operation time. Clinical considerations influencing the choice between the two laparoscopic accesses include: type and size of tumor, side of the gland, previous surgery, and presence of obesity [5, 7, 8]. In our material, all cases of pheochromocytomas were operated transperitoneally due to the necessity to clip the adrenal vein at the beginning of the procedure to control the blood pressure, but some authors do not support our point of view and qualify pheochromocytomas to posterior retroperitoneal (PR) adrenalectomy [7]. We tend to operate all tumors except pheochromocytomas – transperitoneally in non-operated patients on the right side and retroperitoneally on the left. The choice of the method comes from the difference in length of adrenal veins on both sides. Since the access to adrenal vein takes place at the end-stage of the PR adrenalectomy, a short right adrenal vein may be damaged during gland dissection. Therefore we consider clipping right adrenal vein at the beginning of LT adrenalectomy a safer solution. On the left side however, the long adrenal vein enables safely maneuvering the gland during dissection and clipping the vein at the end of the PR adrenalectomy.

Our operative time decreased as the surgeon's experience increased and varied from 90 to 440 minutes, mean 158 minutes and is comparable with operative time in small volume centers, but longer than in high volume centers [7, 16, 17, 18]. We noted three conversions to the open procedure (3.75%) and it corresponds with other series [17, 19, 20]. The first conversion was caused by bleeding following an injury to the adrenal gland. The bleeding was not substantial and it seems that the decision to perform an open conversion was due to the surgeon's lack of experience. The second conversion was performed in a patient with suspected malignant tumor. The surgeon found it difficult to free the massive tumor

whose lower pole extended to the renal pedicle. So the decision was made to convert the operation to an open procedure. The third conversion was a consequence of the injury to the spleen, which had to be removed during the open operation.

Complications in our material occurred in 11 patients (13.75%), which is comparable with those reported by other authors [18, 19, 20]. Blood loss during laparoscopic adrenalectomy is usually low [17, 19, 20]. We noted three cases demanding transfusion. We associate these cases with the use of monopolar cautery – we did not note it after a more precise bipolar cautery or Liga-sure device had been introduced to our technique. Except one obvious case of infection of the upper respiratory tract, the reasons of the rise in body temperature remain unclear in the other 7 patients as all of them received standard perioperative antibiotic prophylaxis but such cases were reported by other authors [21].

CONCLUSIONS

Laparoscopic adrenalectomy is a safe and effective procedure and should be considered the first line treatment of benign adrenal masses. Our experience indicates that patients with adrenal metastases are suitable candidates for laparoscopic adrenalectomy, providing a skilled laparoscopic surgeon is involved in the operation.

REFERENCES

- Gagner M, Lacroix A, Bolte E: *Laparoscopic adrenalectomy in Cushing's syndrome and pheochromocytoma. Letter to editor.* N Engl J Med 1992; 327: 1033.
- Domoslawski P, Wojtczak B, Olewiński R, et al: *Laparoscopic adrenalectomy – a year's experience with a new technique compared with conventional open adrenalectomy.* Adv Clin Exp Med 2010; 19: 625-630.
- Prinz R: *A comparison of laparoscopic and open adrenalectomies.* Arch Surg 1995; 130: 489-492.
- Dindo D, Demartines N, Clavien PA: *Classification of surgical complications: A new proposal with evaluation in a cohort of 6336 patients and results of a survey.* Ann Surg 2004; 240: 205-213.
- Berber E, Telloglu G, Harvey A, et al: *Comparison of laparoscopic transabdominal lateral versus posterior retroperitoneal adrenalectomy.* Surg 2009; 146 (4): 621-625.
- Erbil Y, Barbaros U, Karaman G, et al: *The change in the principle of performing laparoscopic adrenalectomy from small to large masses.* Int J Surg 2009; 7: 266-271.
- Lang B, Fu B, OuYang JZ, et al: *Retrospective comparison of retroperitoneoscopic versus open adrenalectomy for pheochromocytoma.* J Urol 2008; 179: 57-60.
- Tai CK, Li SK, Hou SM, et al: *Laparoscopic adrenalectomy, Comparison of lateral transperitoneal and lateral retroperitoneal approaches.* Surg Laparosc Endosc Percutan Tech 2006; 16: 141-145.
- Germain A, Klein M, Brunaud L: *Surgical management of adrenal tumors.* J Visc Surg 2011; 148: 250-261.
- Zeiger M, Duh Q, Hamrahian A, et al: *American Association of Clinical Endocrinologists and American Association of Endocrine Surgeons medical guidelines for the management of adrenal incidentalomas: executive summary of recommendations.* Endocr Pract 2009; 15: 450-453.
- Palazzo F, Sebag F, Sierra M, et al: *Long-term outcome following laparoscopic adrenalectomy for large solid adrenal cortex tumors.* World J Surg 2006; 30: 893-898.
- Ippolito G, Palazzo F, Sebag F, et al: *Safety of laparoscopic adrenalectomy in patients with large pheochromocytomas: a single institution review.* World J Surg 2008; 32: 840-844.
- ShenW, Sturgeon C, Duh Q: *From incidentaloma to adrenocortical carcinoma: the surgical management of adrenal tumors.* J Surg Oncol 2005; 89: 186-192.

14. Brix D, Allolio B, Fenske W, et al: *German Adrenocortical Carcinoma Registry Group: Laparoscopic versus open adrenalectomy for adrenocortical carcinoma: surgical and oncologic outcome in 152 patients.* Eur Urol 2010; 58: 609-615.
15. Marangos I, Kazaryan A, Rosseland A, et al: *Should we use laparoscopic adrenalectomy for metastases? Scandinavian multicenter study.* J Surg Oncol 2009, 100, 43-47.
16. Suzuki K: *Laparoscopic adrenalectomy, retroperitoneal approach.* Urol Clin N Amer 2001, 28, 85-95.
17. Kulis T, Knezevic N, Pekez M, et al: *Laparoscopic adrenalectomy: les sons learned from 306 cases.* J Laparoendosc Adv Surg Tech 2012; 22: 22-26.
18. Pugliese R, Boniardi M, Sansonna F, et al: *Outcomes of laparoscopic adrenalectomy. Clinical experience with 68 patients.* Surg Oncol 2008; 17: 49-57.
19. Chan J, Meneghetti A, Meloche R, Pantom O: *Prospective comparison of early and late experience with laparoscopic adrenalectomy.* Am J Surg 2006; 191: 682-686.
20. Imai T, Kikumori T, Ohiwa M, et al: *A case-controlled study of laparoscopic compared with open lateral adrenalectomy.* Am J Surg 1999, 178, 50-53.
21. Gasman D, Droupy S, Koutani A, et al: *Laparoscopic adrenalectomy: the retroperitoneal approach.* J Urol 1998; 159: 1816-1820.

Correspondence

Tomasz Szydelko
146, Nenckiego Street
52-212 Wrocław, Poland
phone: +48 71 733 10 10
szydelko@urol.am.wroc.pl