

## RESEARCH

# Performance of contrast-enhanced ultrasound for lymph node metastasis in papillary thyroid carcinoma: a meta-analysis

Yong Yu<sup>1,2,\*</sup>, Lin-Lin Shi<sup>2,\*</sup>, Hua-Wei Zhang<sup>2</sup> and Qian Wang<sup>2</sup><sup>1</sup>Department of Ultrasound, Shandong Provincial Hospital, Shandong University, Jinan, Shandong, China<sup>2</sup>Department of Ultrasound, Shandong Provincial Hospital affiliated to Shandong First Medical University, Jinan, Shandong, ChinaCorrespondence should be addressed to Q Wang or H Zhang: [201420426@mail.sdu.edu.cn](mailto:201420426@mail.sdu.edu.cn) or [slyyzzhw@163.com](mailto:slyyzzhw@163.com)

\*(Y Yu and L-L Shi contributed equally to this work)

## Abstract

**Background:** Papillary thyroid carcinoma is the most common thyroid carcinoma worldwide. Papillary thyroid carcinoma metastasis to the cervical region increases the probability of local or regional recurrence and the requirement for further surgery. Contrast-enhanced ultrasound has been suggested as a possible adjunct diagnostic technique for evaluating papillary thyroid carcinoma metastatic lymph nodes in several studies. This meta-analysis aims to evaluate the diagnostic accuracy of contrast-enhanced ultrasound for cervical lymph nodes metastatic in papillary thyroid carcinoma patients.

**Methods:** A search for studies evaluating the role of contrast-enhanced ultrasound for assessing cervical lymph nodes metastatic in papillary thyroid carcinoma patients from January 2000 to May 2022 was performed in PubMed, Embase, OVID, and Web of Science databases. The Quality Assessment of Diagnostic Accuracy Studies 2 evaluated the quality of the studies. All analyses were performed using Review Manager 5.3 and Stata 17.0.

**Results:** A total of seven articles were finally included in this study. Perfusion type, enhancement homogeneous, hilum absent, and perfusion defect were involved in the meta-analysis as the standard of contrast-enhanced ultrasound, among which, perfusion type showed the best diagnostic performance. The pooled estimated sensitivity, specificity, positive likelihood, negative likelihood ratio, and diagnostic odds ratio of perfusion type in contrast-enhanced ultrasound for detecting lymph node metastasis were 0.95 (0.91, 0.97), 0.87 (0.69, 0.96), 7.51 (2.80, 20.14), 0.06 (0.03, 0.10), and 124.17 (42.78, 360.46), respectively. Heterogeneity was moderate.

**Conclusion:** The perfusion type in contrast-enhanced ultrasound has good diagnostic performance for cervical lymph nodes metastasis in papillary thyroid carcinoma patients.

## Key Words

- ▶ papillary thyroid carcinoma
- ▶ cervical lymph node metastasis
- ▶ contrast-enhanced ultrasound
- ▶ meta-analysis

Endocrine Connections  
(2023) 12, e220341

## Introduction

Papillary thyroid carcinoma (PTC) is the most common thyroid carcinoma, accounting for 84% of all thyroid cancers (1). The majority of PTCs have a low tumor growth rate and a favorable prognosis, but few of them are highly invasive, presenting with cervical lymph node metastasis (CLNM) and extracapsular extension. The conventional

approach in situations of CLNM involvement is central/lateral compartment neck dissection in addition to thyroidectomy (2). PTC metastasis to the cervical region increases the probability of local or regional recurrence and the requirement for further surgery (3). The cervical soft tissue adhesions and ruined normal architecture make

the second surgery for the postoperative CLNM difficult. As a result, preoperative lymph node metastatic detection is critical for surgical strategy selection (4).

In individuals with PTC, conventional ultrasound (US) examination was the preferred preoperative examination. Because the standard US has a high prevalence of false negatives for metastatic lymph nodes, new objectives and precise approaches are needed to predict CLNM in patients with PTC. Contrast-enhanced ultrasound (CEUS) is a new tool that reflects the microvascular conditions inside tumors and offers new ways for thyroid cancer differential diagnosis (5, 6). Previous research has shown that CEUS can help distinguish between benign and malignant thyroid nodules and can detect external thyroidal extension more accurately than conventional US (5, 7). CEUS has been suggested as a possible adjunct diagnostic technique for evaluating PTC metastatic lymph nodes in several studies (8, 9, 10, 11).

Our review found many studies investigating the CLNM with CEUS by dynamic phase features in the thyroid nodules but not the lymph node. So we carried out a meta-analysis to compare the feature patterns of the lymph node. Although we incorporated seven studies, the indicators used to assess the diagnostic value of CEUS in the included studies were inconsistent. There is no generally accepted indicator in the diagnostic field of the lymph node. We believe there is a need to conduct a comprehensive-updated systematic review and meta-analysis to synthesize the evidence on this important topic. To address this, we carried out a meta-analysis to compare the diagnostic efficacy of these approaches. To our knowledge, this is the first research to focus on analyzing the diagnostic accuracy of different indicators of CEUS for evaluating PTC metastatic lymph nodes.

## Methods

### Literature search strategy

A systematic search for eligible studies was undertaken using relevant keywords on PubMed, Embase, OVID, and Web of Science from January 2000 to May 2022. The keywords 'contrast-enhanced ultrasound', 'thyroid', and 'lymph node' were combined with the Boolean operators 'AND' and 'OR' to search the literature. No restrictions on the language of publication existed in the literature search. To increase the retrieval's specificity and sensitivity, the author should check through the list of

recovered references for other retrieval procedures that have not been found in comparable studies.

### Study selection

We included articles that met the following inclusion criteria:

1. pTC patients who were diagnosed with or without CLNM;
2. study outcomes with the following available data: true positive, false positive, false negative, and true negative;
3. patients in whom the diagnosis of CLNM was based on the gold standard: pathological diagnosis;
4. full text was available.

We excluded the study for the following reasons:

1. studies that did not meet the inclusion criteria;
2. relevant results were not reported or cannot be used;
3. review, abstract, or duplicate publication.

### Data extraction

A panel of two reviewers independently screened all titles and abstracts identified by a literature search, obtained full-text documents that may meet the inclusion criteria, assessed their eligibility, and extracted the following data from each eligible study: first author's name, year of publication, country of origin, language, sample size, patient's age, reference standard, and primary outcome (true positive, false positive, false negative, and true negative). The basic characteristics of the included literature are shown in Table 1.

### Quality assessment

Two reviewers assessed the quality of individual trials using the diagnostic accuracy study quality assessment-2 (QUADAS-2) criteria recommended by the Cochrane Diagnostic Test Accuracy Working Group. There were 14 standards in QUADAS-2, which were evaluated one by one with 'yes', 'no', or 'unclear'. Any differences in domain assignments were resolved by consensus.

### CEUS indicators

The indicators involved were perfusion type, enhancement homogeneous, hilum absent, and

**Table 1** Characteristics of the included studies and patients.

Study	Year of publication	Country	Language	Sample size	Age (year)	Instrument	Contrast agent	Studies design	The gold standard for lymph node assessment
Fang	2022	China	English	201	NA	Siemens Acuson S3000	SonoVue	Prospective	Surgical pathology
Wei	2022	China	English	34	39.1 ± 11.3	GE LOGIQ E9	Sonazoid	Prospective	Surgical pathology
Luo	2020	China	English	134	42.9 ± 15.3	Mindray Resona 7	SonoVue	Retrospective	Surgical pathology
Chen	2020	China	English	55	47.11 ± 13.87	GE LOGIQ E9	SonoVue	Retrospective	Surgical/core needle biopsy pathology
Hong	2017	China	English	319	49.5 ± 13.8	Esaote MyLab Twice	SonoVue	Prospective	Surgical/core needle biopsy pathology or cytology
Liu	2021	China	English	190	44.37 ± 13.88	iU22 Phillip	SonoVue	Retrospective	Surgical pathology
Wei	2021	China	English	48	39.9 ± 10.9	GE LOGIQ E9	Sonazoid	Prospective	Surgical pathology

perfusion defect. The enhancement patterns were intense or moderate homogeneous enhancement, heterogeneous enhancement with a local perfusion defect, or none. Perfusion types were classified as centrifugal or centripetal. Centrifugal perfusion was defined as a contrast agent filling from a central vessel to the peripheral region. Centripetal perfusion was defined as a contrast agent filling from the periphery to the central region. Hilum absent was defined as the hilum not enhanced perfused by the contrast agent. Perfusion defect was defined as an absent perfusion area in the lymph node and was distinguished as present or absent.

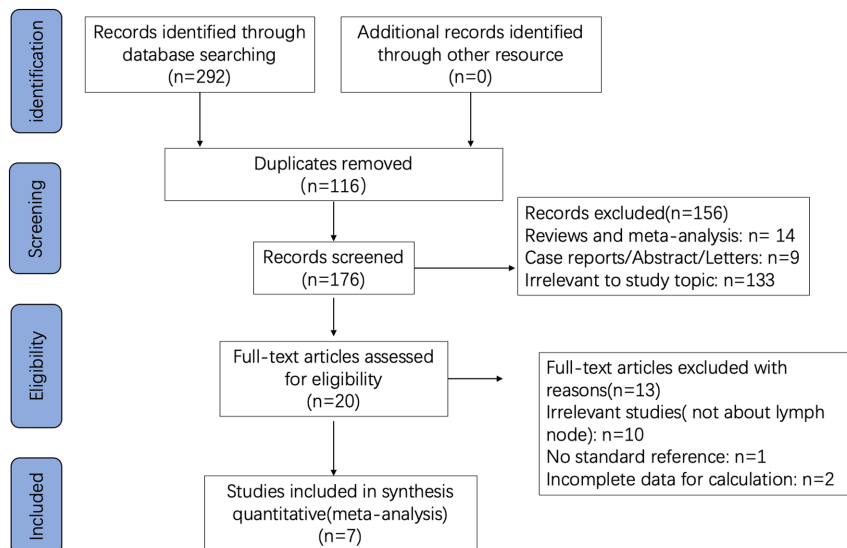
### Statistical analysis

Meta-analysis was performed using Review Manager 5.3 and Stata 17.0. A bivariate random-effects model was used for summary estimates of sensitivity and specificity with 95% CIs. We also derived the diagnostic odds ratio (DOR), positive likelihood ratio (PLR), negative likelihood ratio (DLR), and summary receiver operating characteristic curve (SROC) from the pooled estimates. SROC curves and the area under the curve (AUC) obtained from the fitted bivariate random effects model were used to summarize the overall test performance. The chi-square test and  $I^2$  statistics were used to test the heterogeneity. If  $I^2 < 50\%$  and  $P < 0.05$ , the homogeneity of the included literature was considered to be good and the fixed-effects model was used; if  $I^2 > 50\%$  or  $P \geq 0.05$ , it was considered that there was heterogeneity between the studies, the random effects.

### Results

#### Search process

A total of 292 studies were identified by database search. One hundred and sixteen duplicates were removed after careful reading. Twenty studies meeting the inclusion criteria were identified. Among the remaining 176, 156 were further excluded due to different research designs (case reports/ abstract/letters) or irrelevant to the topic. Finally, 20 studies meeting the inclusion criteria were identified. Thirteen studies were excluded due to incomplete data, no standard reference or irrelevant studies (not about lymph node). Finally, seven studies were included in this meta-analysis (8, 9, 10, 11, 12, 13, 14). Further information about the search process and inclusion and exclusion criteria was shown in Fig. 1.



**Figure 1**  
Search results and flow chart of the meta-analysis.

The final assessment results consider the quality and risk of bias of each study acceptable.

### Characteristics of studies

The descriptive characteristics of the included studies are listed in Table 1. The studies were published between 2017 and 2022. Four studies enrolled patients prospectively and three were retrospective. The sample size in each study ranged from 12 to 266. Contrast agents varied across studies, with five using Sonovue and two Sonazoid. Reference standards varied among studies, with five using surgical pathology, one surgical/core needle biopsy pathology, and one surgical/core needle biopsy pathology or cytology.

### Quality assessment

According to QUADAS-2, the quality assessment of the included articles was independently evaluated by two reviewers (15). When the two reviewers did not agree on the result, the final result would be determined by discussion. If discrepancies exist, a third researcher would independently perform proofreading. Discrepancies were further discussed to achieve a high level of an agreement if necessary. The overall quality assessment was shown in Fig. 2.

### Diagnostic performance of different indicators in the CEUS

The studies included in our meta-analysis by different indicators were listed in Table 2. The detailed analysis

by perfusion type, enhancement homogeneous, hilum absent, and perfusion defect was shown respectively (Fig. 3 and Table 3). The perfusion type subgroup expressed higher sensitivity, specificity, AUC, and DOR than the other three indicators used in CEUS for evaluating CLNM.

The pooled sensitivity and specificity of perfusion type were 0.95 (0.91, 0.97) and 0.87 (0.69, 0.96), respectively. The AUC of perfusion type in CEUS was 0.96 (0.94, 0.98). PLR, NLR, and DOR of perfusion type were 7.51 (2.80, 20.14), 0.06 (0.03, 0.10), and 124.17 (42.78, 360.46), respectively.

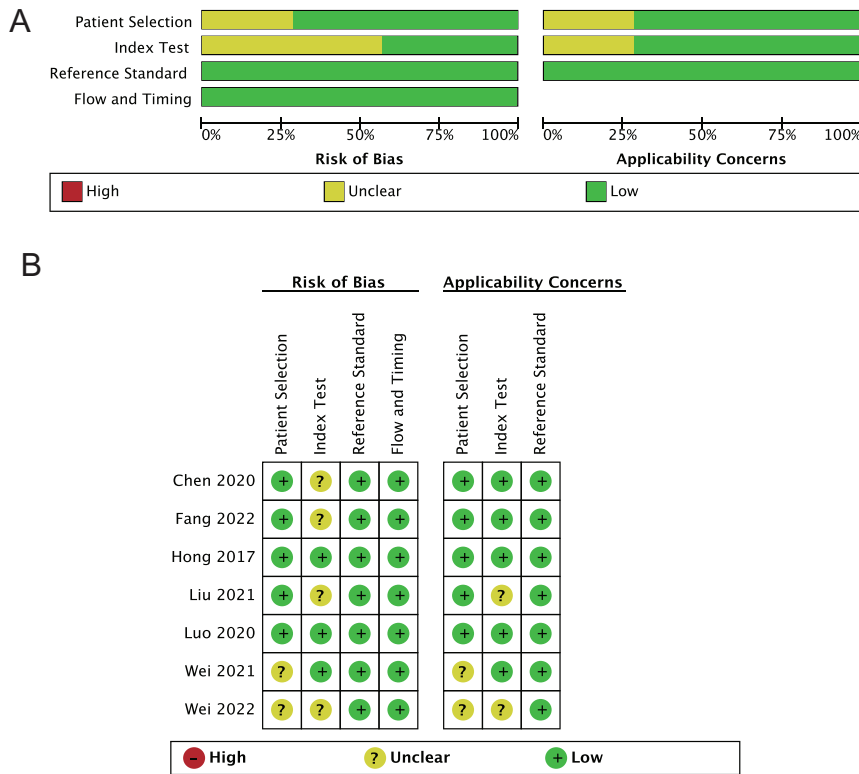
Regarding enhancement homogeneous, the pooled sensitivity, specificity, and AUC were 0.83 (0.70, 0.91), 0.60 (0.51, 0.68), and 0.73 (0.69, 0.77) respectively. PLR, NLR, and DOR of perfusion type were 2.07 (1.76, 2.45), 0.28 (0.17, 0.47), and 7.33 (4.23, 12.72), respectively.

With respect to hilum absent, the pooled sensitivity, specificity, and AUC were 0.77 (0.68, 0.84), 0.63 (0.44, 0.78), and 0.78 (0.74, 0.81), respectively. The corresponding PLR, NLR, and DOR were 2.05 (1.33–3.14), 0.37 (0.27–0.51), and 5.48 (2.85–10.53), respectively.

And one more indicator, perfusion defect, was conducted in the analysis. The sensitivity, specificity, and AUC of perfusion defect in CEUS were 0.95 (0.89, 0.98), 0.57 (0.52, 0.61), and 0.91 (0.88, 0.93). PLR, NLR, and DOR of perfusion defect were 2.19 (1.96–2.46), 0.08 (0.04–0.20), and 26.32 (10.51–65.91), respectively.

### Publication bias and heterogeneity test

Deeks' funnel plot asymmetry test revealed no asymmetry in perfusion type, enhancement homogeneous, hilum



**Figure 2** Methodological assessment of studies included on the QUADAS-2 tool. QUADAS-2 is the quality of individual trials using the diagnostic accuracy study quality assessment-2.

absent, and perfusion defect (*P* values of 0.61, 0.73, 0.74, and 0.98, respectively) which revealed that there was no possible publication bias in the pooled analysis in all the analysis by all the indicators (Fig. 4).

## Discussion

PTC metastasis to the cervical region increases the probability of local or regional recurrence and the requirement for further surgery (3). Early accurate diagnosis of CLNM is crucial for the selection of treatment for PTC patients. Thus, a significant challenge for clinicians is to identify those lymph nodes harboring a clinically relevant malignancy. Ultrasound is currently the most commonly used diagnostic method for CLNM of PTC. However, ultrasound is subjective and easily leads to a missed diagnosis or misdiagnosis (16, 17). CEUS is an accurate imaging method in the evaluation of lymph node status, thus influencing the choice of further examinations, as well as being useful in obtaining an immediate and faster diagnosis which is used in the lymph node related to solid tumors and diffuse large B-cell lymphoma (18), cervical tuberculous lymphadenitis (19). Our review found many studies investigating the CLNM

by assessing the features of the primary thyroid tumor. So we carried out a meta-analysis to compare the feature patterns of the lymph node itself.

The present meta-analysis of the literature aimed to assess and determine the value of CEUS in the study of PTC metastatic lymph nodes and its possible applications in everyday clinical practice, generalizing the results in the use of CEUS for the diagnosis and characterization of PTC metastatic lymph nodes. Although we incorporated seven studies, the indicators used to assess the diagnostic value of CEUS in the included studies were inconsistent. The index in CEUS to assess CLNM in the research was not certain and sole. So one of the crucial goals of our research is to determine the suitable indicator of CEUS for assessing CLNM in PTC patients. To address this, we carried out a meta-analysis to compare the diagnostic efficacy of these approaches. To our knowledge, some of these dimensions have not been discussed in relevant meta-analysis (20). In the meta-analysis grouped by different indicators, the diagnostic accuracy in the analysis by perfusion type was the highest revealing a pooled sensitivity, specificity, and AUC of 0.95 (0.91, 0.97), 0.87 (0.69, 0.96), and 0.96 (0.94, 0.98), respectively. The analysis by perfusion type supported a great capability of CEUS to characterize and distinguish the metastatic lymph node from the normal

**Table 2** Results of analysis based on different indicators.

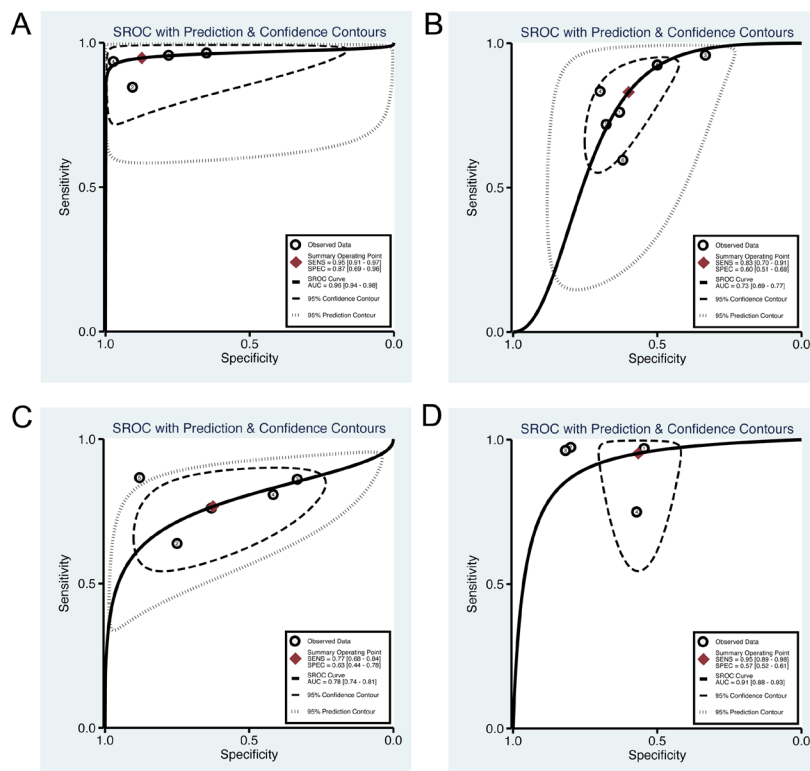
	Author	Year	TP	FP	FN	TN
Perfusion type	Fang	2022	136	21	5	39
	Luo	2020	11	3	2	29
	Chen	2020	21	6	0	24
	Hong	2017	72	3	5	107
Enhancement homogeneous	Hong	2017	86	76	27	130
	Liu	2021	92	20	36	42
	Wei	2021	23	16	1	8
	Hong	2017	105	57	21	132
	Fang	2022	123	34	10	34
Hilum absent	Luo	2020	25	35	17	57
	Hong	2017	86	76	27	130
	Liu	2021	106	6	60	18
	Wei	2021	31	8	5	4
Perfusion defect	Fang	2022	143	14	34	10
	Chen	2020	26	3	4	22
	Hong	2017	32	130	1	156
	Wei	2021	37	2	1	8
	Wei	2022	25	1	0	8
Luo	2020	6	54	2	72	

FN, false negative; FP, false positive; TN, true negative; TP, true positive.

ones, thus allowing correct management of PTC. The heterogeneity observed across the studies was moderate. The sensitivity and specificity of perfusion type were the highest among the four indicators involved in our analysis. Perfusion defect is an indicator with high sensitivity

and low specificity leading to overtreatment due to the increased false-positive results, which indicated that perfusion defect is not a suitable indicator in CEUS.

CEUS can also be used to show clear visualization differences in the vascularization patterns of benign and malignant CLN, with one of the most common US-B-Mode criteria for malignancy being the absence of the hilum sign. An explanation for the absence of conclusive CEUS results could be the large amount of metastatic CLN with partial necrosis, which understandably has an influence on the quantitative determination of the vascularization patterns and parametric assessment of whole-lesion perfusion. Although metastatic CLN may differ optically from benign CLN, the software only registers the amount of contrast-enhanced bubbles and the perfusion pattern appearing in the region of interest. This imbalance of necrosis and different inflow characteristics influences the post-processing analysis. That might explain why the sensitivity and specificity of Hilum Absent are not high and the size of the lymph node may influence the CEUS type. Despite areas of in larger CLNs tend to have necrosis which was manifested as perfusion defect in CEUS, while smaller CLNs potentially have full contrast enhancement without necrotic areas. We suggested lymph node size should be considered in



**Figure 3** SROC for CEUS in the diagnosis of CLNM in PTC patients by (A) perfusion type, (B) enhancement homogeneous, (C) hilum absent, and (D) perfusion defect. SROC, summary receiver operating characteristic curve; CEUS, contrast-enhanced ultrasound; CLNM, cervical lymph node metastasis; PTC, papillary thyroid carcinoma.

**Table 3** Diagnostic performance of CEUS by perfusion type, enhancement homogeneous, hilum absent, and perfusion defect for the detection of CLNM from PTC patients.

Index	Sensitivity (95% CI)	Specificity (95% CI)	AUC (95% CI)	NLR (95% CI)	PLR (95% CI)	DOR (95% CI)
Perfusion type	0.95 (0.91–0.97)	0.87 (0.69–0.96)	0.96 (0.94–0.98)	0.06 (0.03–0.10)	7.51 (2.80–20.14)	124.17 (42.78–360.46)
Enhancement homogeneous	0.83 (0.70–0.91)	0.60 (0.51–0.68)	0.73 (0.69–0.77)	0.28 (0.17–0.47)	2.07 (1.76–2.45)	7.33 (4.23–12.72)
Hilum absent	0.77 (0.68–0.84)	0.63 (0.44–0.78)	0.78 (0.74–0.81)	0.37 (0.27–0.51)	2.05 (1.33–3.14)	5.48 (2.85–10.53)
Perfusion defect	0.95 (0.89–0.98)	0.57 (0.52–0.61)	0.91 (0.88–0.93)	0.08 (0.04–0.20)	2.19 (1.96–2.46)	26.32 (10.51–65.91)

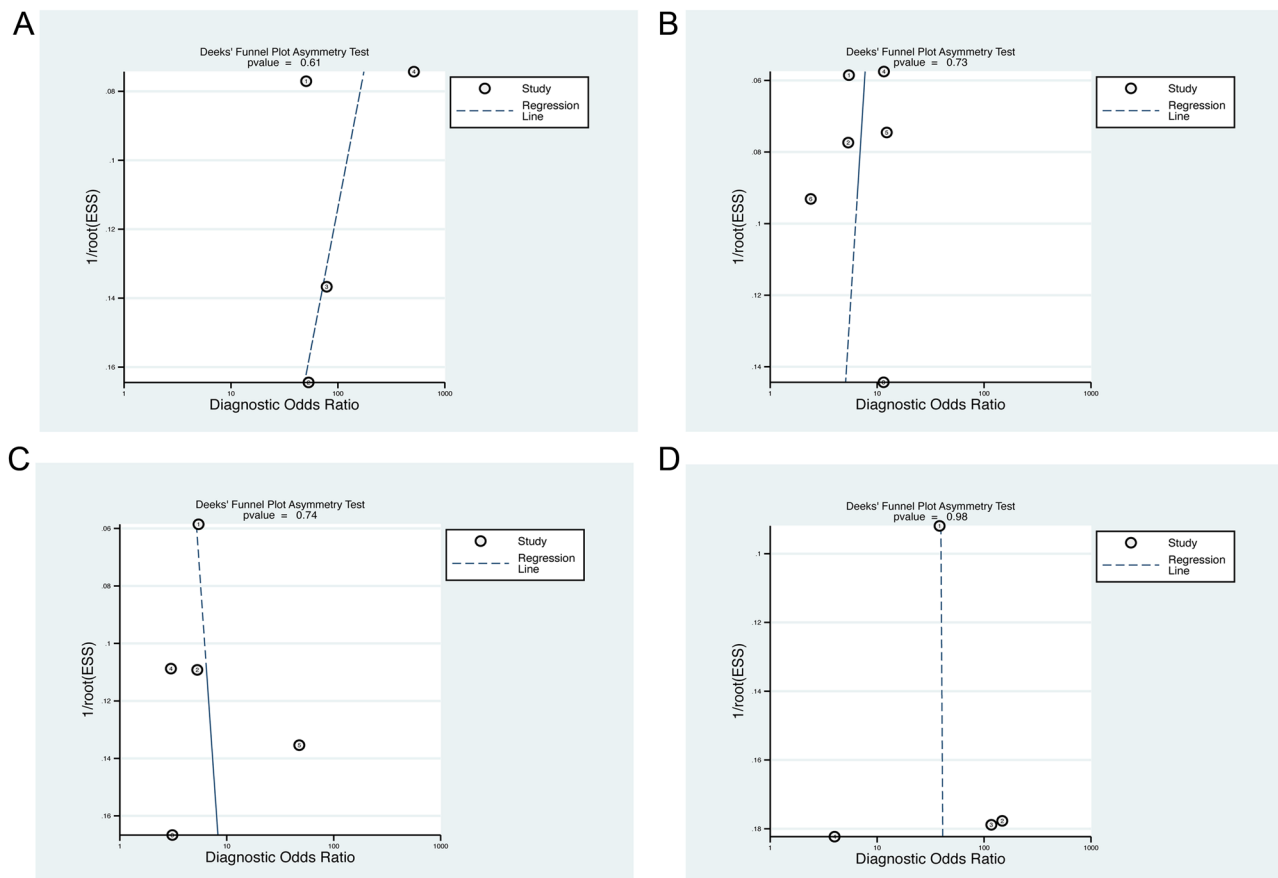
AUC, area under the curve; CEUS, contrast-enhanced ultrasound; CLNM, cervical lymph node metastasis; DOR, diagnostic odds ratio; NLR, negative likelihood ratio; PLR, positive likelihood ratio; PTC, papillary thyroid carcinoma.

the further study of CEUS. This might be the reason that perfusion defect and enhancement homogeneous have low diagnostic accuracy rate.

As shown in the analysis, no standard indicator of CEUS was used in the diagnostic field of the lymph node. Although a meta-analysis on a similar topic was performed in the same year, these reviews failed to analyze the pooled studies by different indicators and to obtain a conclusion to suggest a reliable indicator for

CEUS. The main study outcome was based on the four indicators we included. Actually, some other parameters were used in the studies included or the studies excluded. The data were limited to performing a pooled study to evaluate these parameters.

Our meta-analysis demonstrated that CEUS is a non-invasive method of CLNM in PTC patients with a relatively high-diagnostic sensitivity and specificity. The potential source of heterogeneity between studies may



**Figure 4** Deeks' funnel plot asymmetry test for CEUS in the diagnosis of CLNM in PTC patients by (A) perfusion type, (B) enhancement homogeneous, (C) hilum absent, and (D) perfusion defect. CEUS, contrast-enhanced ultrasound; CLNM, cervical lymph node metastasis; PTC, papillary thyroid carcinoma.

be the demographic characteristic of participants, study design, type of contrast agent, and type of equipment. Some limitations should be considered in this meta-analysis. We believe the main one is the small number of studies and patients included. Additionally, the criteria of the levels in the indicators related to CEUS are not objective, and most of the studies included do not give details which may lead to inconsistency between different studies. Concerning further research, detailed and specific evaluation criteria in the measurement of perfusion type should be listed in the further research of CEUS.

#### Declaration of interest

The authors declare that there is no conflict of interest that could be perceived as prejudicing the impartiality of the research reported.

#### Funding

The work was supported by the Natural Science Foundation of Shandong Province (grant number ZR2021QH047) and the Clinical Science and Technology Innovation Development Program of Jinan (grant number 202134036).

#### Data availability statement

The data that support the findings of this study are available on request from the corresponding author. The data are not publicly available due to privacy or ethical restrictions.

#### Author contribution statement

YY and LS conceived the idea for the article. QW drafted the manuscript. HZ approved the final version of the manuscript. All authors contributed to the article and approved the submitted version.

## References

- Giordano TJ. Genomic hallmarks of thyroid neoplasia. *Annual Review of Pathology* 2018 **13** 141–162. (<https://doi.org/10.1146/annurev-pathol-121808-102139>)
- Adam MA, Pura J, Goffredo P, Dinan MA, Reed SD, Scheri RP, Hyslop T, Roman SA & Sosa JA. Presence and number of lymph node metastases are associated with compromised survival for patients younger than age 45 years with papillary thyroid cancer. *Journal of Clinical Oncology* 2015 **33** 2370–2375. (<https://doi.org/10.1200/JCO.2014.59.8391>)
- Haugen BR, Alexander EK, Bible KC, Doherty GM, Mandel SJ, Nikiforov YE, Pacini F, Randolph GW, Sawka AM, Schlumberger M, *et al.* 2015 American Thyroid Association management guidelines for adult patients with thyroid nodules and differentiated thyroid cancer: the American Thyroid Association guidelines task force on thyroid nodules and differentiated thyroid cancer. *Thyroid* 2016 **26** 1–133. (<https://doi.org/10.1089/thy.2015.0020>)
- Kim SK, Woo JW, Lee JH, Park I, Choe JH, Kim JH & Kim JS. Prophylactic central neck dissection might not be necessary in papillary thyroid carcinoma: analysis of 11,569 cases from a single institution. *Journal of the American College of Surgeons* 2016 **222** 853–864. (<https://doi.org/10.1016/j.jamcollsurg.2016.02.001>)
- Nemec U, Nemec SF, Novotny C, Weber M, Czerny C & Krestan CR. Quantitative evaluation of contrast-enhanced ultrasound after intravenous administration of a microbubble contrast agent for differentiation of benign and malignant thyroid nodules: assessment of diagnostic accuracy. *European Radiology* 2012 **22** 1357–1365. (<https://doi.org/10.1007/s00330-012-2385-6>)
- Zhan J & Ding H. Application of contrast-enhanced ultrasound for evaluation of thyroid nodules. *Ultrasonography* 2018 **37** 288–297. (<https://doi.org/10.14366/usg.18019>)
- Zhang Y, Zhang X, Li J, Cai Q, Qiao Z & Luo YK. Contrast-enhanced ultrasound: a valuable modality for extracapsular extension assessment in papillary thyroid cancer. *European Radiology* 2021 **31** 4568–4575. (<https://doi.org/10.1007/s00330-020-07516-y>)
- Luo ZY, Hong YR, Yan CX, Wang Y, Ye Q & Huang P. Utility of quantitative contrast-enhanced ultrasound for the prediction of lymph node metastasis in patients with papillary thyroid carcinoma. *Clinical Hemorheology and Microcirculation* 2022 **80** 37–48. (<https://doi.org/10.3233/CH-200909>)
- Chen L, Chen L, Liu J, Wang B & Zhang H. Value of qualitative and quantitative contrast-enhanced ultrasound analysis in preoperative diagnosis of cervical lymph node metastasis from papillary thyroid carcinoma. *Journal of Ultrasound in Medicine* 2020 **39** 73–81. (<https://doi.org/10.1002/jum.15074>)
- Wei Y, Niu Y, Zhao ZL, Cao XJ, Peng LL, Li Y & Yu MA. Effectiveness of lymphatic Contrast Enhanced ultrasound in the diagnosis of Cervical lymph node metastasis from papillary thyroid carcinoma. *Scientific Reports* 2022 **12** 578. (<https://doi.org/10.1038/s41598-021-04503-1>)
- Fang F, Gong Y, Liao L, Ye F, Zuo Z, Li X, Zhang Q, Tang K, Xu Y, Zhang R, *et al.* Value of contrast-enhanced ultrasound for evaluation of cervical lymph node metastasis in papillary thyroid carcinoma. *Frontiers in Endocrinology (Lausanne)* 2022 **13** 812475. (<https://doi.org/10.3389/fendo.2022.812475>)
- Hong YR, Luo ZY, Mo GQ, Wang P, Ye Q & Huang PT. Role of contrast-enhanced ultrasound in the pre-operative diagnosis of cervical lymph node metastasis in patients with papillary thyroid carcinoma. *Ultrasound in Medicine and Biology* 2017 **43** 2567–2575. (<https://doi.org/10.1016/j.ultrasmedbio.2017.07.010>)
- Liu N, Tang L, Chen Y, Wang Y, Huang W, Du Z, Shen Y, Wu Z, He T, Su G, *et al.* A combination of contrast-enhanced ultrasound and thyroglobulin level in fine needle aspirates improves diagnostic accuracy for metastatic lymph nodes of papillary thyroid carcinoma. *Journal of Ultrasound in Medicine* 2022 **41** 2431–2443. (<https://doi.org/10.1002/jum.15926>)
- Wei Y, Yu MA, Niu Y, Hao Y, Di JX, Zhao ZL, Cao XJ, Peng LL & Li Y. Combination of lymphatic and intravenous contrast-enhanced ultrasound for evaluation of cervical lymph node metastasis from papillary thyroid carcinoma: a preliminary study. *Ultrasound in Medicine and Biology* 2021 **47** 252–260. (<https://doi.org/10.1016/j.ultrasmedbio.2020.10.003>)
- Whiting PF, Rutjes AW, Westwood ME, Mallett S, Deeks JJ, Reitsma JB, Leeflang MM, Sterne JA, Bossuyt PM & QUADAS-2 Group. QUADAS-2: a revised tool for the quality assessment of diagnostic accuracy studies. *Annals of Internal Medicine* 2011 **155** 529–536. (<https://doi.org/10.7326/0003-4819-155-8-201110180-00009>)
- Hwang HS & Orloff LA. Efficacy of preoperative neck ultrasound in the detection of cervical lymph node metastasis from thyroid cancer. *Laryngoscope* 2011 **121** 487–491. (<https://doi.org/10.1002/lary.21227>)
- Nam SY, Shin JH, Han BK, Ko EY, Ko ES, Hahn SY & Chung JH. Preoperative ultrasonographic features of papillary thyroid carcinoma predict biological behavior. *Journal of Clinical*



- Endocrinology and Metabolism* 2013 **98** 1476–1482. (<https://doi.org/10.1210/jc.2012-4072>)
- 18 Duan S, Zhang Y, Xu S, Jiang P & Qi Q. Contrast-enhanced ultrasound parameters and D-dimer: new prognostic parameters for diffuse large B-cell lymphoma. *Cancer Management and Research* 2022 **14** 2535–2544. (<https://doi.org/10.2147/CMAR.S326173>)
- 19 Zhang Y, Yu T, Su D, Tang W & Yang G. Value of contrast-enhanced ultrasound in the ultrasound classification of cervical tuberculous lymphadenitis. *Frontiers in Medicine* 2022 **9** 898688. (<https://doi.org/10.3389/fmed.2022.898688>)
- 20 Li QL, Ma T, Wang ZJ, Huang L, Liu W, Chen M, Sang T, Ren XG, Tong J, Cao CL, *et al.* The value of contrast-enhanced ultrasound for the diagnosis of metastatic cervical lymph nodes of papillary thyroid carcinoma: a systematic review and meta-analysis. *Journal of Clinical Ultrasound* 2022 **50** 60–69. (<https://doi.org/10.1002/jcu.23073>)

Received in final form 8 December 2022

Accepted 16 December 2022

Accepted Manuscript published online 16 December 2022