

Capsular augmentation in Colonna arthroplasty for the management of chronic hip dislocation

Matthew Sloan and Atul F. Kamath*

Department of Orthopedic Surgery, University of Pennsylvania, Philadelphia, PA, USA

*Correspondence to: A. F. Kamath, Department of Orthopedic Surgery, Center for Hip Preservation, Penn Medicine, 800 Spruce Street, Pennsylvania Hospital, 8th Floor Preston, Philadelphia, PA 19107, USA. E-mail: akamath@post.harvard.edu

Submitted 1 March 2017; Revised 12 November 2017; revised version accepted 12 December 2017

ABSTRACT

Colonna capsular arthroplasty represents an option for the management of chronic hip dislocation in young patients with dysplasia. In the appropriate patient, modern capsular arthroplasty procedures may provide an opportunity for hip preservation in patients with preserved femoral head cartilage and not appropriate for total hip arthroplasty. Here, we review our experience with surgical dislocation of the hip and capsular arthroplasty in a 27-year-old female with congenital hip dysplasia and chronic superior hip dislocation. Due to inadequate native capsular tissue, a decellularized dermal allograft was used for interposition and capsular arthroplasty augmentation. The femoral head with preserved articular cartilage was reduced into the enlarged native acetabulum using a parachute technique to hold the allograft in position. Post-operatively, the patient was placed in a hip abduction brace and made non-weight bearing for six weeks. A conservative physical therapy protocol was implemented to allow gradual increase in weight bearing and range of motion over the first 12 weeks post-operatively.

INTRODUCTION

Capsular arthroplasty has been performed for over 100 years as a treatment for complete hip dislocation in children and young adults. It was first described by Codivilla in 1901, then later reported by Hey Groves in 1926 and Colonna in 1932. The technique involves wrapping the femoral head within the hip capsule prior to performing hip reduction into the true acetabulum.

This procedure was historically complicated by high rates of osteonecrosis and need for further procedures. Improved outcomes with total hip arthroplasty (THA) additionally diminished enthusiasm for the capsular arthroplasty technique. Ganz et al. reviewed a contemporary one-stage procedure with safe surgical hip dislocation and capsular arthroplasty in nine patients with chronic hip dislocations. The authors found a mean Harris Hip Score (HHS) of 84 at a mean of 7.5 years follow-up, with one patient proceeding to THA after 27 years [1]. The patients did require repeat surgery 18–30% of the time to address persistent mechanical issues or for repeated hip reduction.

Other series have reported promising outcomes in selected patients [2, 3].

Here, we review our experience with surgical dislocation of the hip and capsular arthroplasty for congenital hip dysplasia and chronic superior hip dislocation. This technical note describes the use of a decellularized dermal allograft for interposition and capsular arthroplasty augmentation, due to inadequate native capsular tissue volume. The femoral head with preserved articular cartilage was reduced into the enlarged native acetabulum using a parachute technique to hold the allograft in position.

SURGICAL TECHNIQUE

This is a 27-year-old female who presented with left hip pain and chronic high femoral head dislocation. She presented to clinic with a limp, pelvic obliquity, and leg length discrepancy. She had no prior hip surgery. Her pain was located in the groin and buttocks. The patient had a 2 cm leg length discrepancy, with the left leg shorter. The left hip ranged from 10° of extension to 110° of flexion. Hip

internal rotation was 50°, and external rotation was 40°. Hip abduction was 40°, and hip adduction was 20°. Her abductor muscle strength was intact when tested in the standing and lateral decubitus positions.

From preoperative planning, it was clear that the patient's capsular volume was low and stretched superiorly due to chronic dislocation. Due to the nature of the patient's chronic superior dislocation position, we had an Arthrex Arthroflex® Dermal Allograft (Naples, FL, USA) available as an alternative capsular arthroplasty material. This graft is made from human donor dermal tissue that undergoes a decellularizing process, which removes >97% of donor DNA (less than 1 viable particle per million). The tissue is stored at room temperature and retains the biomechanical properties of the dermis without detriment to the elastin and collagen structure. The graft provides a collagen scaffold for vascular and fibrous tissue ingrowth [4].

For treatment of leg length discrepancy and potential sciatic nerve traction injury, we considered femoral shortening osteotomy. If this procedure were performed, the osteotomized bone could be used for the shelf autograft. Alternatively graft would be drawn from the iliac crest if no femoral shortening osteotomy was performed. A straight plate can affix a shortening osteotomy (usually up to 3 cm), with or without derotation to accommodate abnormal femoral version. Finally, a varusization proximal femoral osteotomy with blade plate fixation was considered in the event that reduction into the native acetabulum was complicated by instability or extra-articular impingement. Trochanteric advancement can also reduce any residual extra-articular impingement, and improve abductor functional length. Pre-operative imaging and planning diagrams are shown in Fig. 1.

The approach for surgical dislocation of the hip has been described previously [5]. During the Gibson approach in our case patient, the abductor musculature demonstrated no signs of atrophy. Capsulotomy is performed carefully to avoid injury to the medial femoral circumflex artery that runs posterosuperiorly to the lesser trochanter and provides the main blood supply to the femoral head [6]. Long anterior- and posterior-based leaflets of native capsule were fashioned from the existing capsular sleeve. In our case, there was attenuation in both volume and thickness of the capsule, so that complete coverage of the femoral head was not possible. We also sought to increase the volume of capsule that would serve as the final capsular interposition arthroplasty surface. Therefore, the dermal graft was chosen to augment the central and superior aspects of the femoral head.

The articular cartilage of the femoral head can be assessed circumferentially (Fig. 2). A sizing template is laid over the femoral head to estimate appropriate cup size.

Intra-operative templated head size in our patient, for example, was 40 mm. Lactated ringer irrigation is used to bathe the cartilage to avoid cartilage desiccation during exposure.

After the cartilage is evaluated and deemed adequate for preservation, attention is turned to identification of the native acetabulum. Chronic dislocation leads to scar formation and capsular attenuation. Careful dissection inferiorly toward the native acetabulum is performed and tactile feel is used to identify the dysplastic acetabular rim. A radio-opaque instrument is placed in the inferior border and a fluoroscopic image is taken to confirm alignment relative to the teardrop. The native acetabulum is then reamed and compared in volume with the templated native femoral head size. Preliminary reduction is performed with a moistened lap sponge covering the femoral head cartilage. If the head is too large for the native acetabulum, head reduction is performed.

In our presented case, the sciatic nerve was not under excessive tension with the hip reduced and knee fully extended, and the soft tissues appeared appropriately tensioned. With adequate femoral head reduction, the decision was made to forego femoral shortening osteotomy and perform iliac crest bone graft harvest for shelf autograft acetabuloplasty to supplement the dysplastic superior rim [7]. The graft was sized at the superior acetabular rim for adequate coverage and extracted en bloc from the iliac crest. The shelf graft was fashioned, and excess bone was saved for autograft packing about the shelf. The shelf was then secured in place with two cannulated screws.

The patient's native anatomy afforded a low-volume socket. At this time, with the shelf in place, the acetabulum was reamed to form a concentric socket, starting with a 36-mm reamer centrally to clear the remnant pulvinar tissue. Serially reaming was performed to expand the socket orifice, up to one millimeter larger than the femoral head measurement. Reaming continued sequentially to medialize and optimize abduction and anteversion of the native acetabulum with the new shelf. Frequent assessment of the thickness of the anterior and posterior walls of the acetabulum was performed, in order to avoid iatrogenic thinning out of the walls. Several millimeters of cortical wall thickness remained after reaming. The shelf graft was used to augment the total acetabular volume.

Next, the capsule is assessed for capsular arthroplasty, to provide interposed tissue and prevent adhesion between the reamed native acetabulum (now devoid of articular cartilage) and the femoral head. Native capsule may not always be sufficient, and capsular adequacy must be carefully evaluated to determine if augmentation is necessary. In some instances of chronic high dislocation the capsule may be stretched, but not attenuated and, thus, viable for this purpose. In our case,

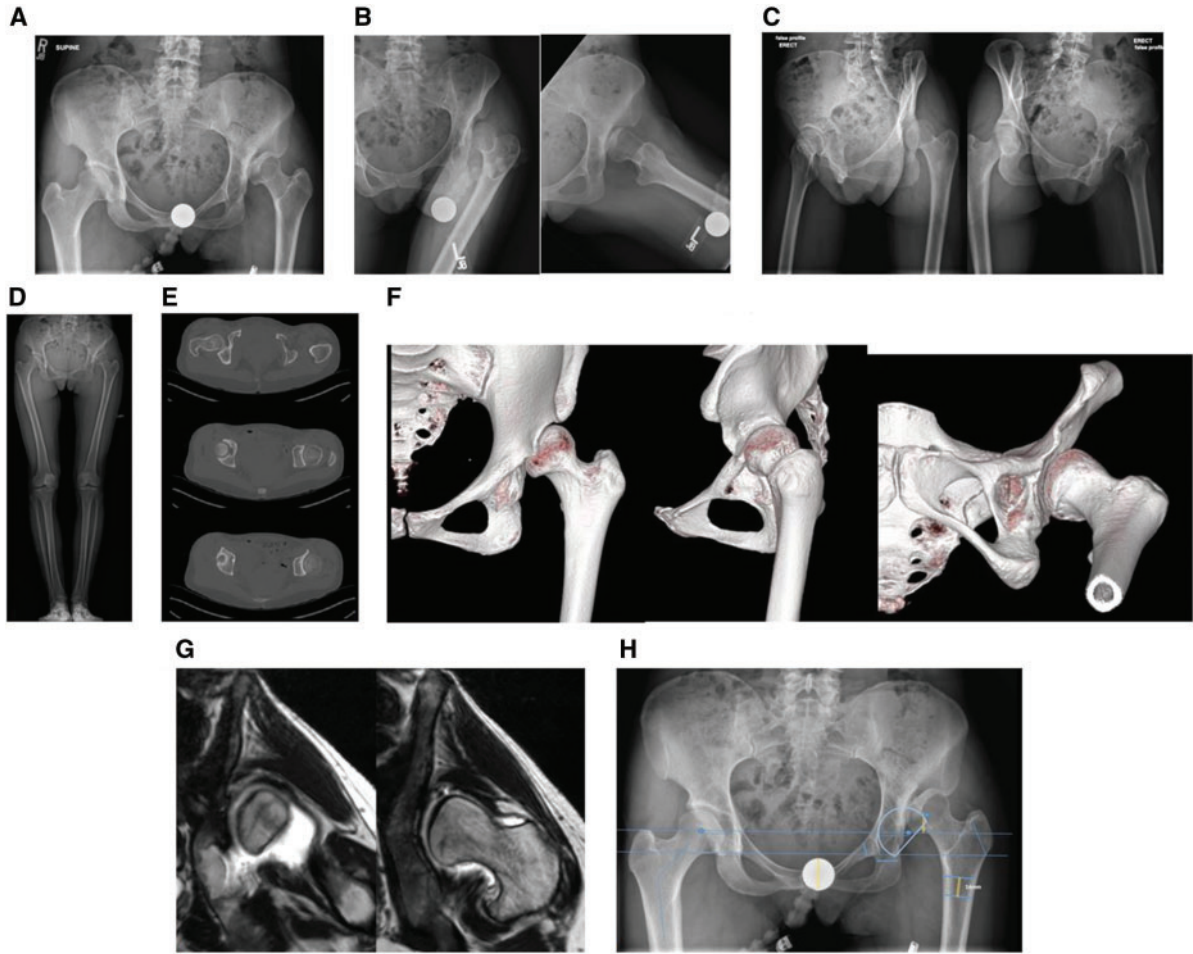


Fig. 1. Pre-operative imaging: (A) anteroposterior (AP) pelvis X-ray. (B) Left hip AP and lateral X-ray. (C) Right and left hip false profile views. (D) Bilateral leg-length scanogram. (E) Pelvis CT axial cuts. The calculated femoral anteversion was 9°. (F) Left hip CT 3D reconstructions. (G) Left hip MRI arthrogram demonstrating low hip capsule volume despite high dislocation. (H) AP pelvis with preoperative template for native acetabulum location, trochanteric osteotomy, and possible femoral shortening osteotomy.

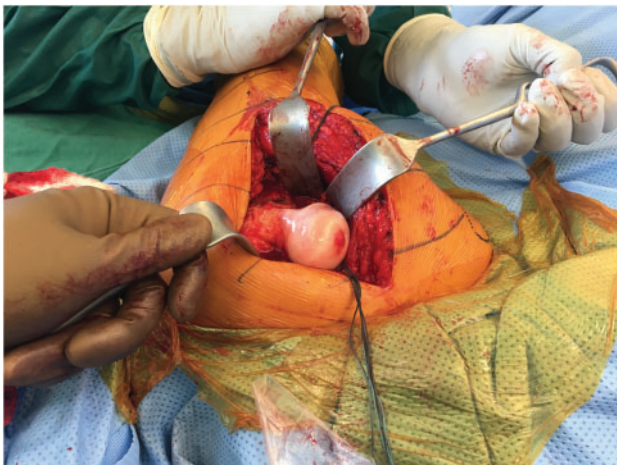


Fig. 2. Exposure of the intact articular cartilage of the femoral head.

the capsule was too attenuated over the length of the chronic dislocation area to cover the femoral head adequately and of insufficient thickness to provide a durable interposition bearing surface. Therefore, a dermal allograft of 40 mm × 70 mm in size, and 3.0 mm in thickness, was used to augment coverage of the femoral head. We placed stay sutures in each corner of the allograft to effect a parachute technique into the acetabulum and to hold the graft in place during the reduction maneuver (Fig. 3). The dermal side [4] of the graft apposes the femoral head to provide a soft, gliding interposed surface intra-articularly. With the allograft draped over the acetabulum, the stay sutures attached anteriorly were used to hold the graft in place. The posterior stay sutures were positioned with one inferior to the femoral neck and one superior to the femoral neck to provide tension that keeps the graft from bunching underneath the femoral head. In this




Fig. 3. Stay sutures placed in each corner of the dermal allograft to allow appropriate tensioning and positioning within the acetabulum during the final femoral head reduction maneuver.

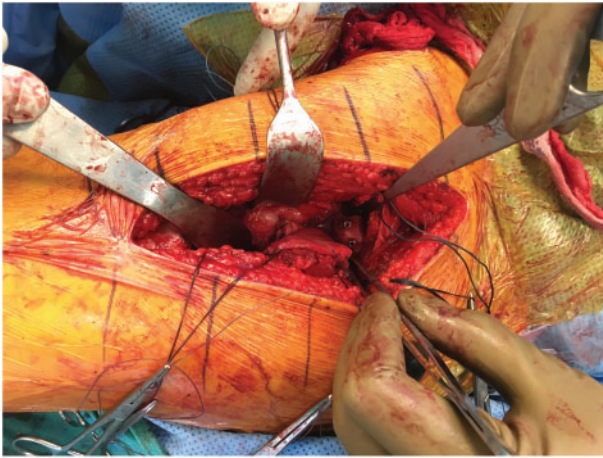


Fig. 4. Femoral head reduced via a parachute of interposed dermal allograft. The superior rim shelf autograft affixed with two screws is also visible. Cranial side of body is to the right of the image.

manner, we could control the tension and coverage over the articulating surface of the femoral head during delivery into the native socket. The native anterior and posterior capsular leaflets were secured to the dermal graft. Graft thickness obtained was ~ 2 mm in thickness after preparation (saline soak, serial stretching, and gentle tensioning over the femoral head). The graft is pliable and has the ability to conform to the acetabular cavity created. We sought to place the thick graft material in the superior weight-bearing zone instead of the attenuated host capsule for durability of the articulation.

The femoral head is then reduced as described earlier into this interposed allograft parachute. Due to the compressible nature of the graft, it conformed snugly to the acetabulum and allowed for femoral head reduction. The stay sutures can then be tied down to remnant capsule using a free needle with interrupted sutures in circumferential fashion about the femoral head and neck. Supplemental 0-vicryl partial-thickness sutures allow for full integration of host capsule to the allograft tissue, to engulf the femoral head in the capsular arthroplasty (Fig. 4). A final assessment of tension on the sciatic nerve is made, as well as length and rotation of the limb,

with the head in the reduced position and capsule secured. Deep closure was then performed, and the trochanteric flip osteotomy was repaired with two cortical screws. On-table range of motion in our patient demonstrated hip stability in full extension, extension and external rotation, as well as combined hip flexion to 90° and internal rotation to 50° .

POST-OPERATIVE PROTOCOL

After sterile closure and dressing, the patient is immediately placed in a hip abduction brace and post-operative imaging is performed (Fig. 5A and B). The patient is made non-weight bearing for at least 6 weeks. We prefer a regimen with serial decreases in degree of abduction over the first few weeks as healing progresses to prevent dislocation/subluxation. The patient is maintained in an abduction brace for 3 months post-operatively. The patient's weight bearing was progressed to weight-bearing as tolerated by 4 months post-operatively. A detailed post-operative physical therapy program has been previously described [1] and found useful in our practice for this augmentation procedure as well as the 'standard' Colonna procedure. We choose to use a hip abduction brace, instead of spica casting, in compliant patients to aid with hygiene and wound care needs. Increase of abductor strengthening is developed throughout the rehabilitation period. We do not use a continuous passive motion machine in our protocol, though one could consider this an option to improve hip range of motion after the passage of adequate time for healing.

The patient continues to do well at 8 months post-operatively, with maintenance of reduction and the femoral head centered under the stable, healed shelf osteotomy (Fig. 5C). The patient's most recent hip range of motion is from 10° of extension to 100° of flexion, and she currently walks without any assistive device and no limp.

DISCUSSION

The practice of capsular arthroplasty has long been described, with variable results in the historical literature. Recent series, however, have reported promising outcomes in selected patients. Chung et al. reported satisfactory HHS in over half of Colonna's patients at 17 years follow-up [2]. Pozo et al. found that nearly three-quarters of patients had an HHS over 80 at 20-year follow-up [3]. As THA has demonstrated an increased failure rate in patients under 50 years old [8, 9], continued development of hip preservation techniques in the young patient, with adequate femoral head cartilage despite hip dislocation, is needed.

Capsular arthroplasty, in conjunction with modern hip preservation techniques, may offer a viable option for chronic hip dislocation, and allograft capsular augmentation may help to address capsular deficiency. In order for this to

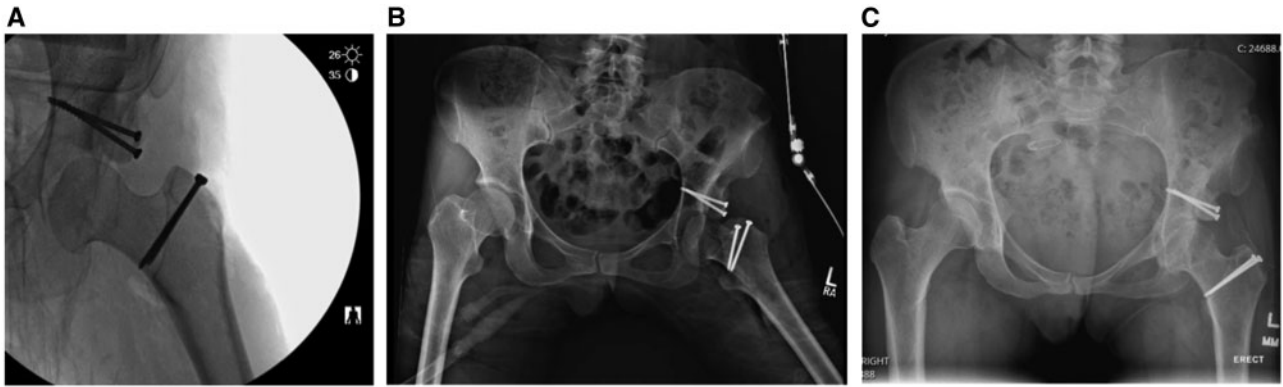

Fig. 5. Post-operative X-rays. (A) Intra-operative left hip AP fluoroscopic view demonstrating adequate femoral head reduction. (B) Post-operative AP pelvis X-ray in hip abduction brace. (C) 8-Month post-operative AP pelvis X-ray.

be a viable option, the candidate must have functional abductor musculature and preferably no prior surgery to the hip or abductors, which could interfere with hip biomechanics upon hip reduction. When performing this procedure, it is imperative to evaluate preoperative advanced imaging for capsular deficiency and repeat intraoperative evaluation to determine whether capsular arthroplasty without augmentation is feasible. For such cases where there is concern for deficient capsular tissue, we recommend having an allograft available to provide augmentation for femoral head coverage if necessary. Other interposition options for capsular augmentation could include autograft or allograft fascia lata, though one must select these materials carefully as volume and thickness can be donor dependent. We have described the dermal allograft augmentation parachute technique as one way to maneuver the allograft around the femoral head during the reduction maneuver, and to completely encompass the femoral head when native tissue is deficient.

FUNDING

This work was not supported by any outside funding source.

CONFLICT OF INTEREST STATEMENT

None declared.

REFERENCES

1. Ganz R, Slongo T, Siebenrock KA *et al.* Surgical technique: The capsular arthroplasty: a useful but abandoned procedure for young patients with developmental dysplasia of the hip. *Clin Orthop Relat Res* 2012; **470**: 2957–67.
2. Chung SM, Scholl HW, Ralston EL, Pendergrass EP. The Colonna capsular arthroplasty. A long-term follow-up study of fifty-six patients. *J Bone Joint Surg Am* 1971; **53**: 1511–27.
3. Pozo JL, Cannon SR, Catterall A. The Colonna–Hey Groves arthroplasty in the late treatment of congenital dislocation of the hip. A long-term review. *J Bone Joint Surg Br* 1987; **69**: 220–8.
4. Achilles Tendon Reinforcement with ArthroFlex® Decellularized Dermis. Package Insert 2015.
5. Ganz R, Gill TJ, Gautier E *et al.* Surgical dislocation of the adult hip a technique with full access to the femoral head and acetabulum without the risk of avascular necrosis. *J Bone Joint Surg Br* 2001; **83**: 1119–24.
6. Kalhor M, Beck M, Huff TW, Ganz R. Capsular and pericapsular contributions to acetabular and femoral head perfusion. *J Bone Joint Surg Am* 2009; **91**: 409–18.
7. Nishimatsu H, Iida H, Kawanabe K *et al.* The modified Spitzzy shelf operation for patients with dysplasia of the hip. A 24-year follow-up study. *J Bone Joint Surg Br* 2002; **84**: 647–52.
8. Siebenrock KA, Schöll E, Lottenbach M, Ganz R. Bernese periacetabular osteotomy. *Clin Orthop Relat Res* 1999; **363**: 9–20.
9. Ramiah RD, Ashmore AM, Whitley E, Bannister GC. Ten-year life expectancy after primary total hip replacement. *J Bone Joint Surg Br* 2007; **89**: 1299–302.