Original Article

Effectiveness of the supraomohyoid neck dissection in clinically N0 neck patients with squamous cell carcinoma of buccal mucosa and gingivobuccal sulcus

S. A. K. Uroof Rahamthulla, P. Vani Priya[1], S. M. D. Javeed Hussain[2], Fazil Arshad Nasyam[3], Syed Akifuddin[4], Velpula Sasidhar Srinivas[5]

Department of Oral and Maxillofacial Surgery, CKS Theja Institute of Dental Sciences and Research, [1]Department of Oral and Maxillofacial Surgery, Sri Venkateswara Institute of Medical Sciences, Sri Padhmavati Medical College, Tirupati, Andhra Pradesh, [2]Department of Oral and Maxillofacial Surgery, Saraswati Dhanwantari Dental College, Parbhani, Maharashtra, [3]Department of Oral and Maxillofacial Surgery, Daswani Dental College, Kota, Rajasthan, India, [4]Department of Oral and Maxillofacial Surgery, Diagnostic Sciences College of Dentistry, Prince Sattam Bin Abdul Aziz University, Al-Kharj, Kingdom of Saudi Arabia, [5]Department of Oral and Maxillofacial Surgery, RVS Hospital, RVS Nagar, Tirupati road, Chittoor, Andhra Pradesh, India.

Corresponding author (email: <dr.uroof@gmail.com>)
Dr. S. A. K. Uroof Rahamthullah, Department of Oral and Maxillofacial Surgery, CKS Theja Institute of Dental Sciences and Research, Renigunta Road, Tirupati - 517 501, Andhra Pradesh, India.

Abstract

Background: To evaluate the effectiveness of the supraomohyoid neck dissection in clinically N0 neck patients with squamous cell carcinoma of buccal mucosa and gingivobuccal sulcus. **Materials and Methods:** This was a prospective study of five patients with squamous cell carcinoma of gingivobuccal mucosa of oral cavity with clinically N0 neck, conducted over a period of 2 years from July 2007 to Oct 2009 in the Department of Oral and Maxillofacial Surgery, Narayana Dental College and Hospital. The study was conducted in patients irrespective of age, sex, size, thickness, and type of differentiation of the lesion. All patients have clinically non-palpable lymphnodes (N0 neck), while patients with palpable lymphnodes, patients with previous surgery, and patients with previous radiotherapy were excluded from the study. **Results:** Level I was the commonest site of neck metastasis in our study. Among the five patients, two (40%) patients (case 2 and 3) had occult cervical metastasis (level IB nodes are histopathologically positive nodes) and the remaining three patients (60%) had no occult cervical metastasis. The recurrence rate was 20% for patients who received postoperative radiotherapy. There was no morbidity and postoperative dysfunction and the mortality rate was only 20% in our study. **Conclusion:** Supraomohyoid neck dissection is the therapeutic procedure in clinically N0 neck patients with squamous cell carcinoma of buccal mucosa and gingivobuccal sulcus of mandible. Supraomohyoid neck dissection, when indicated, contributes to the concept of less-invasive surgery and offers functional and aesthetic advantages without compromising the clearance with minimal morbidity.

Key words: *PN−, PN+, PN− histopathologically negative node, PN+ histopathologically positive node, SCM, supraomohyoid neck dissection, sternocleidomastoid, supraomohyoid neck dissection*

Access this article online	
Quick Response Code:	Website: www.jispcd.org
	DOI: 10.4103/2231-0762.155740

INTRODUCTION

Oral cancer is the sixth most common cancer worldwide, with a high prevalence in South Asia. Cancer of the oral cavity is an important global health concern that accounts for an estimated 275,000 cases and 128,000 deaths annually.[1] Tobacco and alcohol consumption remain the most dominant etiologic

factors in oral cancer.[2] The oral cavity is the predominant location for malignant tumors in the head and neck.

George Crile systematically described the technique of radical neck dissection in 1906.[3] Suarez[4] was the first to describe modified radical neck dissection and Bocca[5] popularized modified radical neck dissection. By the late 20th century, the concept of selective neck dissection, consisting of resection of only the nodal groups at greatest risk for metastasis from a given primary site, was studied and developed. In general, node levels I–III [supraomohyoid neck dissection (SOHND)] are removed for primary tumors of the oral cavity and oropharynx.

The surgical technique of neck dissections has evolved from radical neck dissection to modified or functional neck dissection and then to selective neck dissection.[6] The classic radical neck dissection, first described by Crile and popularized by Martin,[7] was the "gold standard" for patients with identifiable cervical lymph node metastasis. It seemed to be unacceptable for patients with negative neck because of the morbidity associated with it, such as pain, shoulder disability, and long-term adverse cosmetic effects.

The purpose of selective neck dissection is to selectively remove the lymphatic groups at high risk for metastasis and to decrease morbidity by preserving the sternocleidomastoid muscle, internal jugular vein, and accessory nerve. Supraomyohyoid neck dissection is a subtype of selective neck dissection that dissects only at-risk level I, II, and III nodes.

This study was done to evaluate the effectiveness of the SOHND technique in clinically N0 neck patients who reported to the Department of Oral and Maxillofacial Surgery, Narayana Dental College, Nellore with squamous cell carcinoma of buccal mucosa and gingivobuccal sulcus of the mandible.

MATERIALS AND METHODS

Materials

This was a prospective study of five patients with squamous cell carcinoma of gingivobuccal mucosa of the oral cavity with clinically N0 neck over the period of 2 years from July 2007 to Oct 2009 in the Department of Oral And Maxillofacial Surgery, Narayana Dental College and Hospital.

Methods

Criteria of inclusion

This study was conducted in patients irrespective of age, sex, size, thickness, and type of differentiation of the lesion. All patients had clinically non-palpable lymphnodes (N0 neck) and they had undergone ipsilateral SOHND with or without myocutaneous pedicle flap reconstruction followed by radiotherapy. All patients had negative margins at the time of primary resections and a minimum of 2 years of follow-up. Staging of the primary tumor and neck nodes was done according to the (2002) American Joint Committee on Cancer/Union Internationale Contre le Cancer (AJCC/UICC)[8] criteria, and the classification system of cervical lymph nodes developed by the Committee for Head and Neck Surgery and Oncology of the American Academy of Otolaryngology-Head and Neck Surgery (AAO-HNS)[9] was used.

Criteria of exclusion

Patients with palpable lymph nodes, patients with previous surgery, and patients with previous radiotherapy were excluded from the study.

Preoperative evaluation of the patient

Preoperative staging of the neck lymphatic metastases was based on physical palpation and thorough examination of the neck.

Surgical technique

Technique of SOHND

Skin involvement with perforation was present in case 1 [Figures 1-3], and 2 cm of safe margin was left at the primary site.[10] Reconstruction of the surgical defect was done by sternocleidomastoid myocutaneous flap in case 2 [Figures 4-6], case 3 [Figures 7-9] and case 4 [Figures 10-12], but in case 1 and case 5 [Figures 13-15] primary suturing was done. There was no intraoperative complication. The patient was positioned with the top of the head even with the head of the table. A shoulder roll was placed, and the neck was extended and turned to the contralateral side. After sterile skin preparation and draping, an incision was made in a natural skin crease. The incision extended from the midline to the posterior aspect of the sternomastoid muscle and should be at a level just inferior to the hyoid bone. It could be curved anteriorly toward the chin and posteriorly toward the mastoid. The skin along the incision line might be infiltrated with 1% lidocaine with 1:200,000 epinephrine for hemostasis. This incision provides an excellent cosmetic

Figure 1: Preoperative

Figure 2: Preoperative

Figure 3: Postoperative

Figure 4: Preoperative

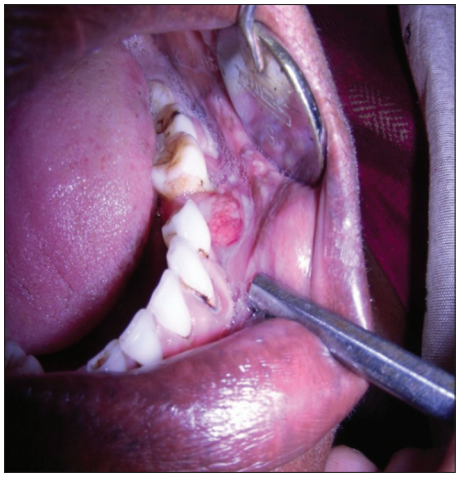

Figure 5: Preoperative

Figure 6: Postoperative

result in most cases and adequate surgical access to levels I–III. The incision was made sharply through the skin and platysma muscle. Injury to the anterior and external jugular veins and greater auricular nerve should be avoided. The superior skin flap was elevated in the subplatysmal plane superficial to the anterior jugular vein, and external jugular vein and greater auricular nerve upto the inferior border of the mandible.

Figure 7: Preoperative

Figure 8: Preoperative

Figure 9: Postoperative

Figure 10: Preoperative

Figure 11: Preoperative

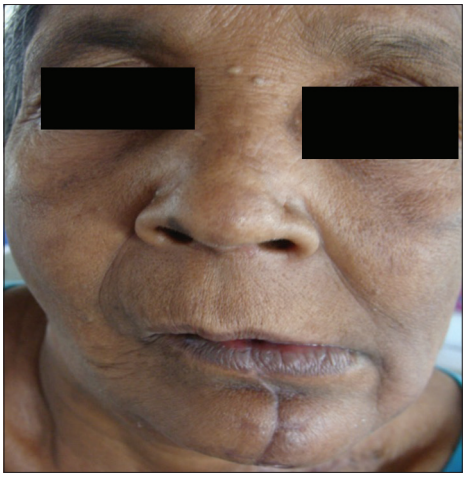

Figure 12: Postoperative

The marginal mandibular branch of the facial nerve was located within the fascia deep to the platysma and just superior to the submandibular salivary gland. The inferior skin flap was also elevated in the subplatysmal plane until the omohyoid muscle was identified. At this point, neck dissection can proceed with dissection of level I node. Level I can be subdivided into levels IA and IB, corresponding to the submental triangles and

Figure 13: Preoperative

Figure 14: Preoperative

Figure 15: Postoperative

submandibular, respectively. The facial vein was ligated and divided. Because the facial vein lies just below the marginal mandibular nerve, reflecting it superiorly "protects" the nerve. A similar maneuver was performed with the facial artery at this level. A node was frequently encountered at the inferior border of the mandible adjacent to the facial vein and in close proximity to the marginal mandibular nerve. Care was taken to include nodes in this area with the specimen while protecting the nerve. Once the marginal mandibular nerve was dissected and protected, attention was directed to the submental triangle (level IA). The level I lymph node are removed. Lingual nerve and hypoglossal nerve can be preserved if they are not involved in the tumor. The duct of the submandibular gland was ligated.

The dissection now proceeds to level II. The greater auricular nerve can be preserved. The external jugular vein was divided and ligated. The spinal accessory nerve was identified. The lymph node pad superior to the nerve (level IIB) was then separated from the sternomastoid muscle and dissected off the deep neck musculature from superior to inferior. The spinal accessory nerve was gently freed from the underlying tissue. Complete removal of the upper 1/3rd and middle 1/3rd jugular lymphnodes (levels II and III lymphnodes along the interjugular vein). Care was taken to avoid injury to the phrenic nerve. The carotid artery and vagus nerve were identified and preserved. After removal, the specimen was immediately labeled to identify the lymph node levels and sent to the pathology laboratory for evaluation.

Total level I, II, and III lymphnodes were selectively removed; hemimandibulectomy with disarticulation was done on the left side in case 2, 3, 4, and 5, but the same procedure was done on the right side in case 1. Except in one case (case 3), the superior thyroid artery branch for sternomastoid muscle was severed intraoperatively while raising the flap and postoperatively the whole flap had undergone necrosis in the same patient.

RESULTS

Pathologic reports were reviewed for patients (all patients were clinically N0 neck) who underwent ipsilateral SOHND treatment from July 2007 to Oct 2009.

Level I was the commonest site of neck metastasis in our study. Among five patients, two (40%) patients (case 2 and 3) had occult cervical metastasis (level IB nodes were histopathologically positive nodes) and the remaining three patients (60%) had no occult cervical metastasis. The metastasis rate according to T stage is listed in Table 1. One patient (case 4) (20%)

Table 1: Occult cervical metastases according to T stage

T stage	No. of patients	PN−	PN+
T2	1	1	0
T3	1	0	1
T4	3	2	1
Total	5	3 (60%)	2 (40%)

was with T2 stage disease, one patient (20%) (case 3) had T3 stage disease, and three patients (case 1, 2, and 5) (60%) were with T4 stage disease. The occult metastatic rate was found to increase according to the T stage of primary tumors. The occult metastasis rate was 40%. No extracapsular spread of disease was seen in all node-positive cases. All 5 (100%) patients had well-differentiated tumor. One patient (case 3) (20%) developed regional recurrences (neck failure) that were in the ipsilateral neck dissected (level IIA, B) region. The interval for recurrence was 6 months. The same patient developed distant metastasis in the sacral region of the spine and died. Disease-free survival (DFS) rate was 80% for a period of 2 years, and the overall survival (OS) rate was 80% for a period of 2 years. All patients received postoperative radiotherapy and the recurrence rate was 20% for patients who received postoperative radiotherapy. There was no morbidity and postoperative dysfunction, and only 20% mortality was observed in our study.

Master chart

All patients had squamous cell carcinoma in the gingivobuccal complex of the oral cavity and all were with clinically N0 neck and they had undergone ipsilateral SOHND treatment for neck from July 2007 to Oct 2009.

DISCUSSION

The classic radical neck dissection, first described by Crile[3] and popularized by Martin,[7] was the "gold standard" for patients with identifiable cervical lymph node metastasis. Swarez[4] first described the technique of "functional neck dissection." This was popularized by Ettore Bocca, who recommended the functional neck dissection for comprehensive clearance of regional cervical lymph nodes in the lateral neck in a monoblock fashion preserving the sternocleidomastoid muscle, internal jugular vein, and spinal accessory nerve.

The surgical technique of neck dissections has evolved from radical neck dissection to modified or functional neck dissection and then to selective neck dissection.[11] Gavilan[12] described that functional neck dissection decreased the morbidity associated with radical neck dissection, but also improved the functional outcome. Functional neck dissection was considered as effective as radical neck dissection in the treatment of N0 and N1 disease without extracapsular spread.

The purpose of selective neck dissection is to selectively remove the lymphatic groups at high risk for metastasis and to decrease morbidity by preserving the sternocleidomastoid muscle, internal jugular vein, and accessory nerve. Supraomyohyoid neck dissection is a subtype of selective neck dissection that dissects only at-risk level I, II, and III nodes.

The gingivobuccal complex is composed of the buccal mucosa, gingivobuccal sulcus, lower gingiva, and retromolar trigone. It is the most common subsite of oral cancer in the Indian population, closely linked to the habit of chewing betel quid containing tobacco, and this mixture is highly irritating to the oral mucosa and results in a variety of lesions, ranging from premalignant lesions to frank malignancies.

Pathak *et al.*[13] described that even in T3 and T4 tumors, less than half (46%) the tumors have nodal metastasis and occur most frequently at level I in gingivobuccal cancer. The first echelon nodes for squamous cell carcinoma of the buccal mucosa are at level I or II.[14] Rao *et al.*[15] described skip metastasis of 9–13% in gingivobuccal cancer patients, but it is usually not at levels IV and V.

In our study, level I was the commonest site of neck metastasis. Among our five patients, case 4 (20%) was with T2 stage disease without any occult cervical metastasis, case 3 (20%) was with T3 stage disease with occult cervical metastasis (level IB nodes are histopathologically positive nodes), and the remaining three patients (case 1, 2, and 5) (60%) were with T4 stage disease and among them, only one patient (case 2) (20%) had occult cervical metastasis (level IB nodes are histopathologically positive nodes). Two patients (40%) had occult cervical metastasis (level IB nodes are histopathologically positive nodes). The occult metastatic rate was found to increase according to the T stage of the primary tumors. The occult metastasis rate in this study was 40%.

Pinoselle *et al.*[16] found severe shoulder dysfunction in radical neck dissection (51%), while it is considerable in functional neck dissection (34%) but very minimal in supraomohyoid neck dissections (7%). Temporary

Name of the patient and age/sex	Clinical staging of tumor size and Grading of the tumor	Bony changes seen in OPG	Treatment done	Reconstruction of the surgical defect	Intraoperative and postoperative complications	Histopathological positivity or negativity of lymphnodes	Recurrence of the tumor	Distant metastasis
Venkataratnamma	T4 lesion and T4N0M0 Grade IV tumor	Destruction of the cortical bone at the site of the tumor	Hemimadibulectomy with disarticulation of left-side mandible and SOHND was done	Sternomastoid flap used at the surgical defect	There was no intraoperative and postoperative complication seen	Histopathologically level IB lymphnodes were positive	No regional recurrence seen	No distant metastasis seen
Venkatamma	T4 lesion and T4N0M0 Grade IV tumor	There was no destruction of the cortical bone at the site of the tumor	Hemimadibulectomy with disarticulation of left-side mandible and SOHND was done	Reconstruction was not done and primary suturing done for the closure of the surgical defect	There was no intraoperative and postoperative complication seen	Histopathologically lymphnodes were negative	No regional recurrence seen	No distant metastasis seen
Imtiaz Ahemed	T3 lesion and T3N0M0 Grade III tumor	There was no destruction of the cortical bone at the site of the tumor	Hemimadibulectomy with disarticulation of left-side mandible and SOHND was done	Sternomastoid flap used at the surgical defect	There was no intraoperative complication seen and postoperatively, the whole flap had undergone necrosis	Histopathologically level IB lymphnodes were positive	Regional recurrence (level IIA)	Distant metastasis seen in the sacral part of the spine
Annapurna	T2 lesion and T2N0M0 Grade II tumor	There was no destruction of the cortical bone at the site of the tumor	Hemimadibulectomy with disarticulation of left-side mandible and SOHND was done	Sternomastoid flap used at the surgical defect	There was no intraoperative and postoperative complication seen	Histopathologically lymphnodes were negative	No regional recurrence seen	No distant metastasis seen
Ramanamma	T4 lesion and T4N0M0 Grade IV tumor	Destruction of the cortical bone present at the site of the tumor	Hemimadibulectomy with disarticulation of left-side mandible and SOHND was done	Reconstruction was not done and primary suturing was done for the closure of the surgical defect	There was no intraoperative and postoperative complication seen	Histopathologically lymphnodes were negative	No regional recurrence seen	No distant metastasis seen

SOHND = Supraomohyoid neck dissection, OPG = Orthopantomogram

Lesion

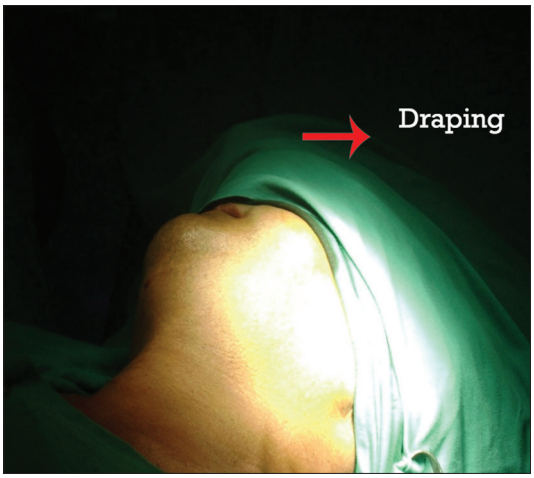

Draping

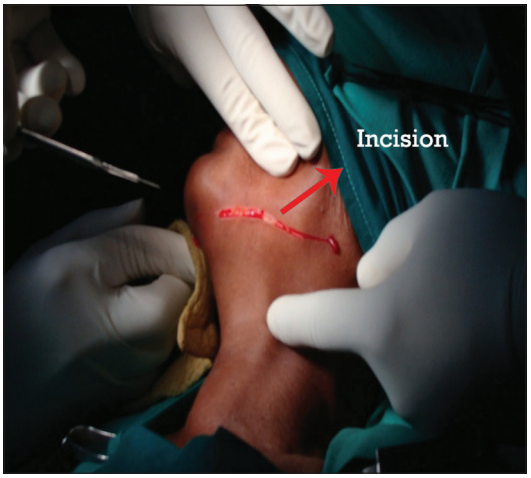

Incision

Subplatysmal dissection

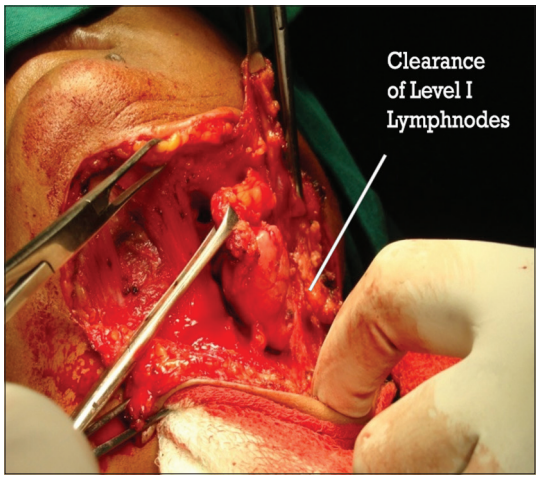

Clearance of level I lymph nodes

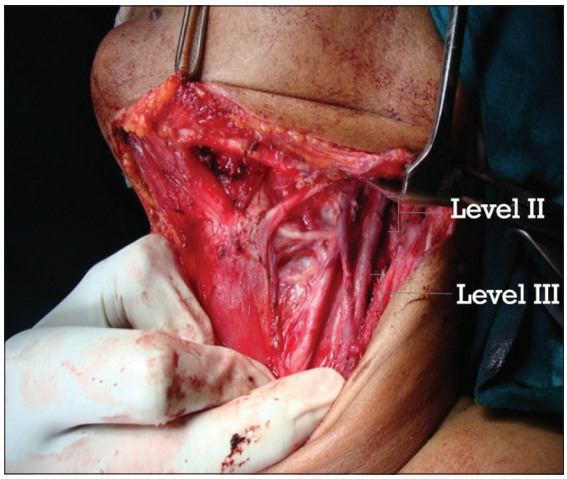

Clearance of level II and III lymph nodes

dysfunction is noticed even after supraomohyoid neck dissections; this usually recovers in 6 months.[17]

In our study, the shoulder dysfunction rate was 0%. The DFS rate was 80% for a period of 2 years. The OS rate was 80% for a period of 2 years. All patients received postoperative radiotherapy and the recurrence rate was 20%. There was no morbidity and postoperative dysfunction, and only 20% neck failure (level IB) was seen; there was no single node with extracapsular spread.

Sternocleidomastoid (SCM) flap raised

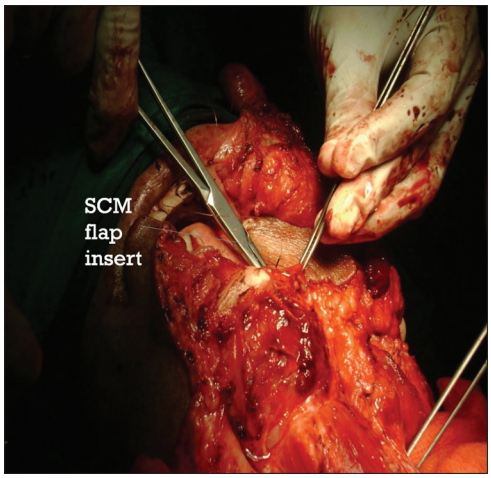

Sternocleidomastoid (SCM) flap insert

Closure

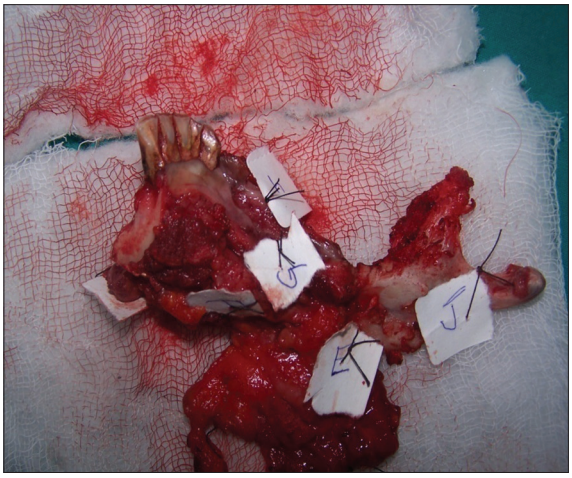

Specimen

Recurrence after supraomohyoid neck dissections can be either in the field of dissection or out of the field. Carvalho *et al.*[18] found 57.1% of them to be within the limits of dissection. Similarly, two-thirds of recurrences following supraomohyoid neck dissections were in the field of dissection.[19]

In our study, regional recurrence was found in one patient (20%) that was within the field of neck dissection (level IIA, B), and the recurrence may be due to using of sternomastoid myocutaneous flap for reconstruction of the defect in the oral cavity. While raising the sternomastoid myocutaneous flap, the sternomastoid branch of superior thyroid artery was severed accidentally. Due to that, a careful dissection to preserve the only vascular supply (branch from occipital artery) to the flap possibly resulted in inadequate removal of the lymph nodes (level IIA, IIB), which could have resulted in recurrence. Postoperatively, the same patient got total sternomastoid myocutaneous flap necrosis and infection.

The patient was a diabetic and hypertensive, and it took sufficient time to control the infection. Because of that, there was a delay for postoperative radiotherapy, which may be the cause for recurrence. The same patient got distant metastasis in the sacral region of the spine and died 1 year after surgery.

In our study, none of the patients had intraoperative complications; but postoperatively, one patient had total flap necrosis (sternomastoid myocutaneous flap).

CONCLUSION

The surgical technique of neck dissections has evolved from radical neck dissection to modified or functional neck dissection and then to selective neck dissection. The first echelon nodes for squamous cell carcinoma of the buccal mucosa are at level I or II. Thus, supraomohyoid neck dissection is an appropriate procedure for the N0 neck.

Cancer of the gingivobuccal sulcus involves neck nodes in a predictive fashion, with nodal involvement restricted to levels I–III. Thus, supraomohyoid neck dissections may have a therapeutic role in gingivobuccal cancers with no nodal involvement. The main advantage is that selective approaches further reduce postoperative disfigurement and dysfunction, which can still be significant.

In our study, level I was the commonest site of neck metastasis. All five patients (clinically all patients were N0 neck) underwent ipsilateral supraomohyoid neck dissection; among them, 2 (40%) patients had occult cervical metastasis (level IB nodes are histopathologically positive nodes) and the others did not have occult cervical metastasis (histopathologically negative nodes). There was no morbidity and postoperative dysfunction, and the mortality rate was only 20%.

Supraomohyoid neck dissection is the therapeutic procedure in clinically N0 neck patients with squamous cell carcinoma of buccal mucosa and gingivobuccal sulcus of mandible. Supraomohyoid neck dissection, when indicated, contributes to the concept of less-invasive surgery, and offers functional and aesthetic advantages without compromising the clearance with minimal morbidity.

REFERENCES

1. Jemal A, Bray F, Center MM, Ferlay J, Ward E, Forman D. Global cancer statistics. CA Cancer J Clin 2011;61:69-90.
2. Sankaranarayanan R. Oral cancer in India: An epidemiologic and clinical review. Oral Surg Oral Med Oral Pathol 1990;69:325-30.
3. Crile G. Excision of cancer of the head and neck, with special reference to the plan of dissection based on 132 patients. JAMA 1906;47:1780-4.
4. Suárez O. Le problème chirurgical du cancer du larynx. Ann Otolaryngol 1962;79:22-34.
5. Bocca E, Pignataro O. A conservation technique in radical neck dissection. Ann Otol Rhinol Laryngol 1967;76:975-87.
6. Myers EN, Gastman BR. Neck dissection: An operation in evolution: Hayes Martin lecture. Arch Otolaryngol Head Neck Surg 2003;129:14-25.
7. Martin H, Del Valle B, Ehrlich HE, Cahan WG. Neck dissection. Cancer 1951;4:441-99.
8. Greene FL, Page DL, Fleming ID, Fritz A, Balch CM, Haller DG, *et al.* AJCC Cancer Staging Manual. 6th ed. Berlin, Heidelberg, New York, London, Paris, Tokyo, Hong Kong: Springer-Verlag; 2002. p. 435.
9. Robbins KT, Clayman G, Levine PA, Medina J, Sessions R, Shaha A, *et al.*; American Head and Neck Society; American Academy of Otolaryngology-Head and Neck Surgery. Neck dissection classification update: Revisions proposed by the American Head and Neck Society and the American Academy of Otolaryngology-Head and Neck Surgery. Arch Otolaryngol Head Neck Surg 2002;128:751-8.
10. Chindavijak S. Micrometastasis and recurrent neck node in supraomohyoid neck dissection field. J Med Assoc Thai 2005;88:1287-92.
11. Myers EN, Gastman BR. Neck dissection: An operation in evolution: Hayes Martin lecture. Arch Otolaryngol Head Neck Surg 2003;129:14-25.
12. Gavilán J, Gavilán C, Herranz J. Functional neck dissection: Three decades of controversy. Ann Otol Rhinol Laryngol 1992;101:339-41.
13. Pathak KA, Gupta S, Talole S, Khanna V, Chaturvedi P, Deshpande MS, *et al.* Advanced squamous cell carcinoma of lower gingivobuccal complex: Patterns of spread and failure. Head Neck 2005;27:597-602.
14. Woolgar JA. Histological distribution of cervical lymph node metastases from intraoral/oropharyngeal squamous cell carcinomas. Br J Oral Maxillofac Surg 1999;37:175-80.
15. Rao RS, Deshmane VH, Parikh HK, Parikh DM, Sukthankar PS. Extent of lymph node dissection in T3/T4 cancer of the alveolo-buccal complex. Head Neck 1995;17:199-203.
16. Pinsolle V, Michelet V, Majoufre C, Caix P, Siberchicot F, Pinsolle J. Spinal accessory nerve and lymphatic neck dissection. Rev Stomatol Chir Maxillofac 1997;98:138-42.
17. Cheng PT, Hao SP, Lin YH, Yeh AR. Objective comparison of shoulder dysfunction after three neck dissection techniques. Ann Otol Rhinol Laryngol 2000;109:761-6.
18. Carvalho AL, Kowalski LP, Borges JA, Aguiar S Jr, Magrin J. Ipsilateral neck cancer recurrences after elective supraomohyoid neck dissection. Arch Otolaryngol Head Neck Surg 2000;126:410-2.
19. Andersen PE1, Warren F, Spiro J, Burningham A, Wong R, Wax MK, *et al.* Results of selective neck dissection in management of the node-positive neck. Arch Otolaryngol Head Neck Surg 2002;128:1180-4.

How to cite this article: Rahamthulla SU, Priya PV, Hussain SJ, Nasyam FA, Akifuddin S, Srinivas VS. Effectiveness of the supraomohyoid neck dissection in clinically N0 neck patients with squamous cell carcinoma of buccal mucosa and gingivobuccal sulcus. J Int Soc Prevent Communit Dent 2015;5:131-40.

Source of Support: Nil, **Conflict of Interest:** None declared.