

Acute Ischemic Stroke Due to Multiple Bee Stings_A Delayed Complication

Sir,

Bee and wasp stings may rarely cause acute stroke. We present a case of a 41-year-old man who had a fatal right MCA territory stroke following an attack by over 50 bees.

This particular 41-year-old man with no previous comorbidities was attacked by over 50 bees while at the fields and lost consciousness. He was taken to a hospital where the stings were removed and symptomatic treatment with analgesics, corticosteroids and antihistamines was provided. With treatment, he regained consciousness and was walking independently. He was kept under observation.

Five hours later, patient developed sudden onset left hemiparesis and dysarthria with gaze preference to the right side. CT head showed massive right MCA territory infarction [Figure 1]. He was managed with dual antiplatelets. In spite of this, his sensorium deteriorated and he was started on low molecular weight heparin on the next day. He was also given intravenous mannitol. However, the patient continued to deteriorate and had to be endotracheally intubated. He was also given hyperventilation. However, the edema related to the infarct led to midline shift and the patient relatives refused surgery for decompression hemicraniectomy. The patient succumbed on the third day following the bee stings.

Bee stings are commonly associated with local reactions like erythema, edema, redness and pain at the local site which are self-limiting. It may be associated with systemic effects such as anaphylaxis including hypotension and laryngeal edema. In a series of 322 cases^[1] of wasp and bee stings reported by Witharana and colleagues, 79% had only local reaction and 4.6% developed anaphylaxis. None of them developed stroke or renal dysfunction. Only two patients had to be referred to

tertiary care centre, of whom one had ocular stings and other had more than 1000 stings.

Bee stings are managed symptomatically. The first step is to remove the stings so that further exposure to the venom is stopped. Adrenaline, antihistamines and corticosteroids are usually administered to counteract local reaction as well as anaphylaxis. Patients who recover from anaphylaxis usually do not develop further symptoms. Rarely patients may develop organ dysfunction such as acute kidney injury, rhabdomyolysis, cardiac dysfunction including heart block, Takotsubo cardiomyopathy, myocardial infarction etc.^[2,3]

Stroke associated with bee stings are limited to a handful of case reports only.^[4-13] It may occur in the post-acute phase within 4 to 10 hours. Most of the reported cases are due to multiple bee stings.

The exact etiology of stroke following bee sting has not been elucidated. Proposed mechanisms are 1. Due to hypotension and reduced cerebral perfusion due to anaphylaxis, 2. Hypercoagulable state and platelet aggregation due to thromboxane A₂ and phospholipase activation, 3. Vasoconstriction due to retrograde stimulation of the superior cervical ganglion and carotid spasm etc.

Stroke following bee sting is very rare. Clinical history and examination is of utmost importance in diagnosing the etiology of altered sensorium and stroke. In cases of multiple bee stings, patients often become unconscious and may not be able to provide history. Our patient was brought to the hospital in an unconscious state by the passersby. In such cases, careful general examination would reveal insect bite marks which would lead to the diagnosis. Awareness of

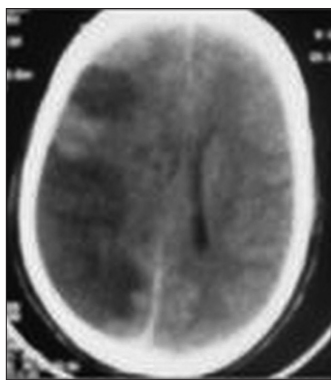


Figure 1: CT head showing hypodensity in the right middle cerebral artery territory suggesting infarction

this rare entity can lead to appropriate diagnosis and prevent unnecessary evaluation for the cause of stroke.

Declaration of patient consent

The authors certify that they have obtained all appropriate patient consent forms. In the form the patient(s) has/have given his/her/their consent for his/her/their images and other clinical information to be reported in the journal. The patients understand that their names and initials will not be published and due efforts will be made to conceal their identity, but anonymity cannot be guaranteed.

Financial support and sponsorship

Nil.

Conflicts of interest

There are no conflicts of interest.

Arunmozhimaran Elavarasi, Thekkumpurath M. Haq, Thekkumpurath Thahira, Cheminikkara Bineesh, Laxmana B. Kancharla

Department of Neurology, EMS Memorial Cooperative Hospital, Perinthalmanna, Kerala, India

Address for correspondence: Dr. Thekkumpurath M. Haq, Department of Neurology, EMS Memorial Cooperative Hospital, Perinthalmanna - 679 322, Kerala, India.
E-mail: drhaq1971@yahoo.com

REFERENCES

1. Witharana EW, Wijesinghe SK, Pradeepa KS, Karunaratne WA, Jayasinghe S. Bee and wasp stings in Deniyaya; a series of 322 cases. *Ceylon Med J* 2015;60:5-9.
2. Ghanim D, Adler Z, Qarawani D, Kusniec F, Amir O, Carasso S. Takotsubo cardiomyopathy caused by epinephrine-treated bee sting anaphylaxis: A case report. *J Med Case Reports* 2015;9:247.
3. Gupta PN, Kumar BK, Velappan P, Sudheer MD. Possible complication of bee stings and a review of the cardiac effects of bee stings. *BMJ Case Rep* 2016;2016. doi: 10.1136/bcr-2015-213974.
4. Dechyapirom W, Cevik C, Nugent K. Concurrent acute coronary syndrome and ischemic stroke following multiple bee stings. *Int J Cardiol* 2011;151:e47-52.
5. Bilir O, Ersunan G, Kalkan A, Ozmen T, Yigit Y. A different reason for cerebrovascular disease. *Am J Emerg Med* 2013;31:891.e5-6.
6. Guzel M, Akar H, Erenler AK, Baydin A, Kayabas A. Acute ischemic stroke and severe multiorgan dysfunction due to multiple bee stings. *Turk J Emerg Med* 2016;16:126-8.
7. Mahale R, Mehta A, Shankar AK, Buddaraju K, John AA, Javali M, *et al.* Isolated posterior circulation stroke following honey-bee sting. *Neurol India* 2016;(64 Suppl):S116-8.
8. Rajendiran C, Puvanalingam A, Thangam D, Ragunathanan S, Ramesh D, Venkatesan S, *et al.* Stroke after multiple bee sting. *J Assoc Physicians India* 2012;60:122-4.
9. Schiffman JS, Tang RA, Ulysses E, Dorotheo N, Singh SS, Bahrani HM. Bilateral ischaemic optic neuropathy and stroke after multiple bee stings. *Br J Ophthalmol* 2004;88:1596-8.
10. Temizoz O, Celik Y, Asil T, Balci K, Unlu E, Yilmaz A. Stroke due to bee sting. *The Neurologist* 2009;15:42-3.
11. Viswanathan S, Muthu V, Singh AP, Rajendran R, George R. Middle cerebral artery infarct following multiple bee stings. *J Stroke Cerebrovasc Dis Off J Natl Stroke Assoc* 2012;21:148-50.
12. Wani M, Saleem S, Verma S, Yousuf I, Wani M, Asimi R, *et al.* Multiple cerebral infarctions with severe multi-organ dysfunction following multiple wasp stings. *Ann Indian Acad Neurol* 2014;17:125.
13. Jain J, Banait S, Srivastava AK, Lodhe R. Stroke intracerebral multiple infarcts: Rare neurological presentation of honey bee bite. *Ann Indian Acad Neurol* 2012;15:163-6.

This is an open access journal, and articles are distributed under the terms of the Creative Commons Attribution-NonCommercial-ShareAlike 4.0 License, which allows others to remix, tweak, and build upon the work non-commercially, as long as appropriate credit is given and the new creations are licensed under the identical terms.

DOI: 10.4103/aian.AIAN_118_19