

Dermatomyositis

Muscle Pathology According to Antibody Subtypes

Jantima Tanboon, MD, Michio Inoue, MD, PhD, Yoshihiko Saito, MD, PhD, Hisateru Tachimori, PhD, Shinichiro Hayashi, PhD, Satoru Noguchi, PhD, Naoko Okiyama, MD, PhD, Manabu Fujimoto, MD, PhD, and Ichizo Nishino, MD, PhD

Correspondence
Dr. Nishino
nishino@ncnp.go.jp

Neurology® 2022;98:e739-e749. doi:10.1212/WNL.0000000000013176

Abstract

Background and Objectives

Discoveries of dermatomyositis-specific antibodies (DMSAs) in patients with dermatomyositis raised awareness of various myopathologic features among antibody subtypes. However, only perifascicular atrophy and perifascicular myxovirus resistant protein A (MxA) overexpression were officially included as definitive pathologic criteria for dermatomyositis classification. We aimed to demonstrate myopathologic features in MxA-positive dermatomyositis to determine characteristic myopathologic features in different DMSA subtypes.

Methods

We performed a retrospective pathology review of muscle biopsies of patients with dermatomyositis diagnosed between January 2009 and December 2020 in a tertiary laboratory for muscle diseases. We included all muscle biopsies with sarcoplasmic expression for MxA and seropositivity for DMSAs. MxA-positive muscle biopsies that tested negative for all DMSAs were included as seronegative dermatomyositis. We evaluated histologic features stratified according to 4 pathology domains (muscle fiber, inflammatory, vascular, and connective tissue) and histologic features of interest by histochemistry, enzyme histochemistry, and immunohistochemical study commonly used in the diagnosis of inflammatory myopathy. We performed ultrastructural studies of 54 available specimens.

Results

A total of 256 patients were included. Of these, 249 patients were positive for 1 of the 5 DMSAs (seropositive patients: 87 anti-transcription intermediary factor 1- γ [TIF1- γ], 40 anti-complex nucleosome remodeling histone deacetylase [Mi-2], 29 anti-melanoma differentiation gene 5 [MDA5], 83 anti-nuclear matrix protein 2 [NXP-2], and 10 anti-small ubiquitin-like modifier-activating enzyme [SAE] dermatomyositis) and 7 patients were negative for all 5 DMSAs (seronegative patients). Characteristic myopathologic features in each DMSA subtype were as follows: anti-TIF1- γ with vacuolated/punched out fibers (64.7%; $p < 0.001$) and perifascicular enhancement in HLA-ABC stain (75.9%; $p < 0.001$); anti-Mi-2 with prominent muscle fiber damage (score 4.9 ± 2.1 ; $p < 0.001$), inflammatory cell infiltration (score 8.0 ± 3.0 ; $p = 0.002$), perifascicular atrophy (67.5%; $p = 0.02$), perifascicular necrosis (52.5%; $p < 0.001$), increased perimysial alkaline phosphatase activity (70.0%; $p < 0.001$), central necrotic peripheral regenerating fibers (45.0%; $p = 0.002$), and sarcolemmal membrane attack complex deposition (67.5%; $p < 0.001$); anti-MDA5 with scattered/diffuse staining pattern of MxA (65.5%; $p < 0.001$) with less muscle pathology and inflammatory features; anti-NXP-2 with microinfarction (26.5%; $p < 0.001$); and anti-SAE and seronegative dermatomyositis with HLA-DR expression (50.0%; $p = 0.02$ and 57.1%; $p = 0.02$, respectively).

MORE ONLINE

 **CME Course**
NPub.org/cmelist

From the Department of Neuromuscular Research, National Institute of Neuroscience (J.T., M.I., Y.S., S.H., S.N., I.N.), Department of Genome Medicine Development, Medical Genome Center (J.T., M.I., Y.S., S.H., S.N., I.N.), and Department of Clinical Epidemiology, Translational Medical Center (H.T.), National Center of Neurology and Psychiatry (NCNP); Endowed Course for Health System Innovation (H.T.), Keio University School of Medicine, Tokyo; Department of Dermatology, Faculty of Medicine (N.O.), University of Tsukuba, Ibaraki; and Department of Dermatology (M.F.), Graduate School of Medicine, Osaka University, Japan.

Go to [Neurology.org/N](https://www.neurology.org/N) for full disclosures. Funding information and disclosures deemed relevant by the authors, if any, are provided at the end of the article.

This manuscript was prepublished in MedRxiv (doi: doi.org/10.1101/2021.06.03.21258156).

The Article Processing Charge was funded by NCNP.

This is an open access article distributed under the terms of the Creative Commons Attribution-NonCommercial-NoDerivatives License 4.0 (CC BY-NC-ND), which permits downloading and sharing the work provided it is properly cited. The work cannot be changed in any way or used commercially without permission from the journal.

Glossary

ACP = acid phosphatase; AHC = agglomerative hierarchical clustering; ALP = alkaline phosphatase; CFR = capillary to muscle fiber ratio; CK = creatine kinase; CNPR = centrally necrotic and peripherally regenerating; COX = cytochrome C oxidase; DM = dermatomyositis; DMSAs = dermatomyositis-specific antibodies; DMSD = dermatomyositis sine dermatitis; ENMC = European Neuromuscular Centre; ILD = interstitial lung disease; MAC = membrane attack complex; MCA = multiple correspondence analysis; MDA5 = melanoma differentiation gene 5; MHC = major histocompatibility complex; MHCn = neonatal myosin heavy chain; MxA = myxovirus resistant protein A; NCNP = National Center of Neurology and Psychiatry; NXP-2 = nuclear matrix protein 2; PFA = perifascicular atrophy; PFN = perifascicular necrosis; SAE = small ubiquitin-like modifier-activating enzyme; TIF1- γ = transcription intermediary factor 1- γ ; TRI = tubuloreticular inclusion.

Discussion

We describe a comprehensive serologic–pathologic correlation of dermatomyositis primarily using MxA expression as an inclusion criterion. In our study, DMSAs were associated with distinctive myopathologic features suggesting different underlying pathobiologic mechanisms in each subtype.

The discovery of dermatomyositis-specific antibodies (DMSAs) has transformed the clinically oriented dermatomyositis (DM) classification criteria (primarily based on the presence of skin lesions and muscle weakness described by Bohan and Peter in 1975) to clinical-serologic-pathologic criteria proposed by the European Neuromuscular Centre (ENMC) in 2018 (2018 ENMC-DM).¹⁻³ In the 2018 ENMC-DM consensus, the following 5 DMSAs were included as serologic criteria: anti-transcription intermediary factor 1- γ (TIF1- γ), anti-complex nucleosome remodeling histone deacetylase (Mi-2), anti-melanoma differentiation gene 5 (MDA5), anti-nuclear matrix protein 2 (NXP-2), and anti-small ubiquitin-like modifier-activating enzyme (SAE).² DMSA-associated clinical phenotypes have been characterized, including anti-TIF1- γ DM with DM skin lesions, dysphagia, and malignancy⁴⁻⁶; anti-Mi-2 DM with high creatine kinase (CK) level, myalgia, and muscle weakness⁷⁻⁹; anti-MDA5 DM with mechanic hands and interstitial lung disease (ILD) but low CK levels and less muscle involvement^{10,11}; and anti-NXP-2 DM with muscle weakness but less skin involvement.^{12,13} DMSA-associated pathologic phenotypes were also recognized and proposed to be included as an “integrated” pathologic system for DM.^{14,15} However, most of these phenotypes were limited to small studies and were not included in the 2018 ENMC-DM.^{2,4,7,9,16,17} In the 2018 ENMC-DM, only perifascicular atrophy (PFA, the best known pathologic feature of DM) and myofiber expression of myxovirus resistant protein A (MxA, a surrogate marker for type I interferon pathway activation) were included as definitive pathologic criteria.¹⁸⁻²¹ This study aimed to investigate and characterize DMSA-specific pathologic features in MxA-positive muscle biopsies.

Methods

Patients

Muscle biopsies from 256 patients pathologically diagnosed with DM at the National Center of Neurology and Psychiatry

(NCNP), a nationwide referral center for muscle disease in Japan, from January 2009 to December 2020 were evaluated by confirming the sarcoplasmic MxA expression of neither necrotic nor regenerating muscle fibers.¹⁹⁻²² Because of the existence of DM sine dermatitis (DMSD),¹² we regarded all MxA-positive muscle biopsies as DM regardless of the presence of skin lesion. This study was an expansion of the DM cohort from our previous studies^{7,12} and consisted of 249 muscle biopsies from patients positive for 1 of the 5 DMSAs (seropositive DM) and 7 muscle biopsies from patients who tested negative for all the 5 DMSAs (seronegative DM). We defined patients <18 years as juvenile patients.

Serologic Information

ELISA for autoantibodies against TIF1- γ , Mi-2, and MDA5 were covered by the national health insurance system in Japan and were performed according to the manufacturer’s instructions (MESACUP kit, Medical & Biological Laboratories Co, Ltd.). Patients testing negative for anti-TIF1- γ , Mi-2, and MDA5 antibodies were evaluated by immunoprecipitation and western blotting for autoantibodies against NXP-2 and SAE.²³⁻²⁵

Histochemical and Immunohistochemical Evaluation

Histochemical and immunohistochemical staining for routine diagnostic purposes was performed, including hematoxylin & eosin, modified Gomori trichrome, acid phosphatase (ACP), alkaline phosphatase (ALP), cytochrome C oxidase (COX), Oil Red O, nicotinamide adenine dinucleotide tetrazolium reductase (NADH-TR), MxA (Mx 1/2/3; Santa Cruz Biotechnology), Class I human major histocompatibility complex (MHC) (HLA-ABC; clone W6/32; Thermo Fisher Scientific), MHC Class II (HLA-DR; clone B308; Affinity BioReagents), membrane attack complex (MAC; C5b-9, clone aE11; Dako), neonatal myosin heavy chain (MHCn; clone WB-MHCn; Leica), utrophin (clone DRP3/20C65; Leica), CD3 (polyclonal; Abcam), CD8 (clone DK25; Dako), CD20

(clone L26; eBioscience), and CD68 (clone KP1; Dako). J.T. performed pathologic evaluation and was blinded to the antibody results at the time of evaluation.

The histochemical and immunohistochemical stained slides, prepared at the time of pathologic diagnosis at the NCNP, were evaluated based on 4 domains (muscle fiber, inflammatory, vascular, and connective tissue domains) using the same scoring system as our previous studies modified from the pathology scoring system originally used for juvenile DM (eTable 1, links.lww.com/WNL/B691).^{7,26} The scoring system for the muscle fiber domain was based on the presence and extent of necrotic fibers, regenerating fibers, atrophic fibers separated from the perifascicular area, and fibers with internalized nuclei. The inflammatory domain scoring was by CD3, CD20, and CD68-positive inflammatory cells in the endomysium and perimysium, and the presence of perivascular inflammatory cell infiltration. The vascular domain scoring was based on the capillary to muscle fiber ratio. The connective tissue domain scoring was based on endomysium fibrosis and perimysium pathology, which included fragmentation and alkaline phosphatase expression.⁷ Sarcoplasmic MAC deposition and MHCn expression were used as supporting findings to identify and confirm necrotic and regenerating fibers, respectively. Utrophin was used as a surrogate endothelial marker to evaluate the capillary-to-muscle fiber ratio.

Alongside the PFA, perifascicular necrosis (PFN), decreased COX activity in perifascicular area, perivascular inflammation, vasculitis, CD8 and ACP/CD68 infiltration in non-necrotic fiber, and CD20 aggregation, we included microinfarction, centrally necrotic-and-peripherally regenerating (CNPR) fibers, and vacuolated/punched-out fiber as histopathologies of interest for DM. Microinfarction was defined by the aggregate of at least 3 necrotic fibers without inflammatory cell infiltration into the necrotic fiber accompanied by decreased/absent sarcoplasmic oxidative enzymatic activity on NADH-TR. CNPR fibers were defined as fibers presenting necrosis in the central part of the sarcoplasm surrounded by crescent-shaped regenerating portions. Vacuolated/punched-out fibers were defined by degenerative non-necrotic fiber with vacuolations.⁴ For MxA staining, 3 patterns were documented: (1) perifascicular pattern if the sarcoplasmic staining was limited to the PFA, (2) scattered/diffuse pattern if there was no specific localization, and (3) mixed pattern. The evaluation criteria for histochemical and immunohistochemical staining are described elsewhere.⁷ Ultrastructural evaluation for tubuloreticular inclusions (TRIs) was performed in 54 patients' biopsies.

Statistical Analysis

We explored histologic features by performing multiple correspondence analysis (MCA) followed by agglomerative hierarchical clustering (AHC) using XLSTAT version 2021.2.1 (XLSTAT.com). For continuous variables, Welch 1-way analysis of variance followed by Dunnett T3 multiple

comparisons test was performed. Welch *t* test and Fisher exact test were used for continuous and categorical variables to compare findings in 1 antibody subtype against other antibody subtypes (e.g., anti-TIF1- γ DM vs non-TIF1- γ DM); the tests were 2-tailed. A *p* value < 0.05 was regarded as statistically significant. These analyses were performed using GraphPad Prism version 9.1.0 (216) for Mac OS (GraphPad Software).

Standard Protocol Approvals, Registrations, and Patient Consents

This study was approved by the institutional review boards of the NCNP. All clinical information and materials derived from diagnostic testing was permitted for research use with written informed consent from the patients.

Data Availability

Anonymized data not published within this article will be made available by request from any qualified investigator.

Results

Patient Characteristics

Of the 256 patients diagnosed pathologically with DM by sarcoplasmic MxA expression, 249 patients were DMSA-positive (249 seropositive DM: 87 anti-TIF1- γ , 40 anti-Mi-2, 29 anti-MDA5, 83 anti-NXP-2, and 10 anti-SAE DM) and 7 patients were seronegative. Clinical information of patients with DM is summarized in Table 1. There were differences in patient ages among DMSA subtypes ($p < 0.001$) (eFigure 1a). The patients who tested positive for anti-TIF1- γ , anti-Mi-2, and anti-SAE antibodies were older than those with non-TIF1- γ DM (42.3 ± 26.2 years; $p < 0.001$), non-Mi-2 DM (45.3 ± 27.6 years; $p = 0.03$), or non-SAE DM (45.6 ± 26.8 years; $p < 0.001$), respectively. Patients with anti-TIF1- γ and anti-Mi-2 DM were younger than patients with anti-SAE DM ($p = 0.003$ and $p = 0.002$, respectively). Patients who were anti-NXP-2 positive and DM-seronegative were younger (non-NXP-2 DM 51.8 ± 24.9 years; $p < 0.001$ and seropositive DM 47.4 ± 26.4 years; $p = 0.007$, respectively). This was reflected by the larger number of juvenile patients with anti-NXP-2 (42.2% vs non-NXP-2 18.5%; $p < 0.001$) and seronegative DM (85.7% vs seropositive 24.5%; $p = 0.002$). Disease duration, the proportion of patients receiving systemic immunotherapy within 6 weeks of the time of muscle biopsy, the sex ratio of the affected patients, and the biopsy site did not significantly differ among DMSA subtypes (eTable 2, links.lww.com/WNL/B691). In anti-TIF1- γ DM, biopsies obtained from the biceps brachii (42.5%) were slightly less common than in non-TIF1- γ DM (52.5%; $p = 0.05$). The serum CK levels differed among DMSA subtypes ($p < 0.001$; eFigure 1b). Anti-Mi-2 DM was associated with higher CK levels ($8,113.7 \pm 14,314.2$ vs non-Mi-2 $2,758.2 \pm 5,566.7$ U/L; $p = 0.03$), while anti-MDA5, anti-SAE, and anti-TIF1- γ DM were associated with lower CK levels ($394.6 \pm$

Table 1 Clinical Features of All Dermatomyositis Cases in This Study

Clinical features	All DM (n = 256)	Anti-TIF1- γ (n = 87)	Anti-Mi-2 (n = 40)	Anti-MDA5 (n = 29)	Anti-NXP-2 (n = 83)	Anti-SAE (n = 10)	Seronegative (n = 7)
Age at biopsy, y	46.5 \pm 26.7	54.8 \pm 25.8 ^{e*}	53.2 \pm 20.0 ^{e*}	42.5 \pm 23.7	35.6 \pm 27.1 ^{et}	70.4 \pm 8.1 ^{e*}	17.3 \pm 19.9 ^{et}
Juvenile (<18 y)	67 (26.2)	15 (17.2) ^{et}	3 (7.5) ^{et}	8 (27.6)	35 (42.2) ^{e*}	0	6 (85.7) ^{e*}
Sex, female	139 (54.3)	48 (55.2)	18 (45.0)	16 (55.2)	47 (56.6)	7 (70.0)	3 (42.9)
CK, U/L	3,598.2 \pm 7,834.3 ^a	1881.2 \pm 4,414.3 ^{a,et}	8,113.7 \pm 14,314.2 ^{e*}	394.6 \pm 481.9 ^{et}	4,685.2 \pm 7,035.0	492.8 \pm 357.0 ^{et}	3,710.4 \pm 7,248.1
Skin lesions ^b	232 (90.6)	85 (97.7) ^{e*}	37 (92.5)	29 (100.0)	64 (77.1) ^{et}	10 (100.0)	7 (100.0)
DM skin lesions ^c	180 (70.3)	78 (89.7) ^{e*}	29 (72.5)	25 (86.2)	37 (44.6) ^{et}	9 (90.0)	2 (28.6) ^{et}
Mechanic hands	45 (17.6)	16 (18.4)	8 (20.0)	15 (51.7) ^{e*}	3 (3.6) ^{et}	3 (30.0)	0
Muscle weakness	229 (89.5)	75 (86.2)	40 (100.0) ^{e*}	20 (69.0) ^{et}	79 (95.2) ^{e*}	9 (90.0)	6 (85.7)
Myalgia	175 (68.9) ^d	59 (67.8)	23 (57.5)	15 (53.6) ^a	69 (84.1) ^{a,e*}	4 (40.0)	5 (71.4)
Dysphagia	88 (34.5) ^a	41 (47.1) ^{e*}	8 (20.5) ^a	8 (27.6)	25 (30.1)	6 (60.0)	0
Interstitial lung disease	47 (18.4) ^a	11 (12.6)	3 (7.7) ^a	23 (79.3) ^{e*}	7 (8.4) ^{et}	3 (30.0)	0
Malignancy	55 (21.5)	36 (41.4) ^{e*}	7 (17.5)	1 (3.4) ^{et}	7 (8.4) ^{et}	4 (40.0)	0
Malignancy, age \leq 40 y (n = 90)	2/90 (2.2)	2/19 (10.5) ^{e*}	0/10 (0)	0/11 (0)	0/44 (0)	0	0/6 (0)

Abbreviations: CK = creatine kinase; DM = dermatomyositis; MDA5 = melanoma differentiation-associated gene 5; Mi-2 = complex nucleosome remodeling histone deacetylase antibody; NXP-2 = nuclear matrix protein 2; SAE = small ubiquitin-like modifier activating enzyme; TIF1- γ = transcription intermediary factor 1- γ antibody.

Continuous data are shown as mean \pm SD; categorical data are shown as n (%).

^a Information was not available for 1 patient.

^b Any type of skin lesion.

^c DM skin lesions as defined by the 239th European Neuromuscular Centre workshop: presence of Gottron sign/papule or heliotrope rash.

^d Information was not available for 2 patients.

^e $p < 0.05$ (vs other antibody subtypes; *higher score/percentage; ^tlower score/percentage).

481.9 vs non-MDA5 4,009.3 \pm 8,232.0 U/L; $p < 0.001$; 492.8 \pm 357.0 vs non-SAE 3,725.0 \pm 7,967.2 U/L; $p < 0.001$; and 1881.2 \pm 4,414.3 vs non-TIF1- γ 4,472.0 \pm 8,981.1 U/L; $p = 0.002$, respectively). Patients with anti-TIF1- γ DM more commonly presented with skin lesions of any kind (97.7% vs non-TIF1- γ 87.0% DM; $p = 0.005$) as well as DM-specific skin lesions defined by the 2018 ENMC-DM criteria (89.7% vs non-TIF1- γ 60.4%; $p < 0.001$). Anti-TIF1- γ DM was also associated with dysphagia (47.1% vs non-TIF1- γ 28.0%; $p = 0.003$) and malignancy (41.4% vs non-TIF1- γ 11.2%; $p < 0.001$, eFigure 1c). Notably, anti-TIF1- γ DM was associated with malignancy in patients below age 40 (10.5% vs non-TIF1- γ 0%; $p = 0.04$); the youngest patient was 36 years old. Patients with anti-Mi-2 DM more frequently presented with muscle weakness (100% vs non-Mi-2 87.5%; $p = 0.01$). Anti-MDA5 DM was associated with mechanic's hands (51.7% vs non-MDA5 13.2%; $p < 0.001$) and ILD (79.3% vs non-MDA5 10.6%; $p < 0.001$), but was less associated with muscle weakness (69.0% vs non-MDA5 92.1%; $p = 0.001$) and malignancy (3.5% vs non-MDA5 23.8%; $p = 0.008$). Anti-NXP-2 DM was less likely to be associated with skin lesions of any kind (77.1% vs non-NXP-2 97.1%; $p < 0.001$), DM-specific skin lesions (44.6% vs non-NXP-2 82.7%; $p < 0.001$), me-

chanic's hands (3.6% vs non-NXP-2 24.3%; $p < 0.001$), ILD (8.4% vs non-NXP-2 23.3%; $p = 0.003$), and malignancy (8.4% vs non-NXP-2 27.8%; $p < 0.001$). Myalgia was more common in anti-NXP-2 DM (84.2%) than non-NXP-2 DM (61.6%; $p < 0.001$). Skin ulcers were documented in 4 patients, 2 anti-MDA5 (6.9%) and 2 anti-TIF1- γ DM (2.3%), but were not distinctively associated with specific antibody subtype. Anti-SAE was not associated with any distinctive clinical feature. Seronegative DM was less associated with typical DM skin lesions (28.6%) than was seropositive DM (71.5% $p = 0.03$).

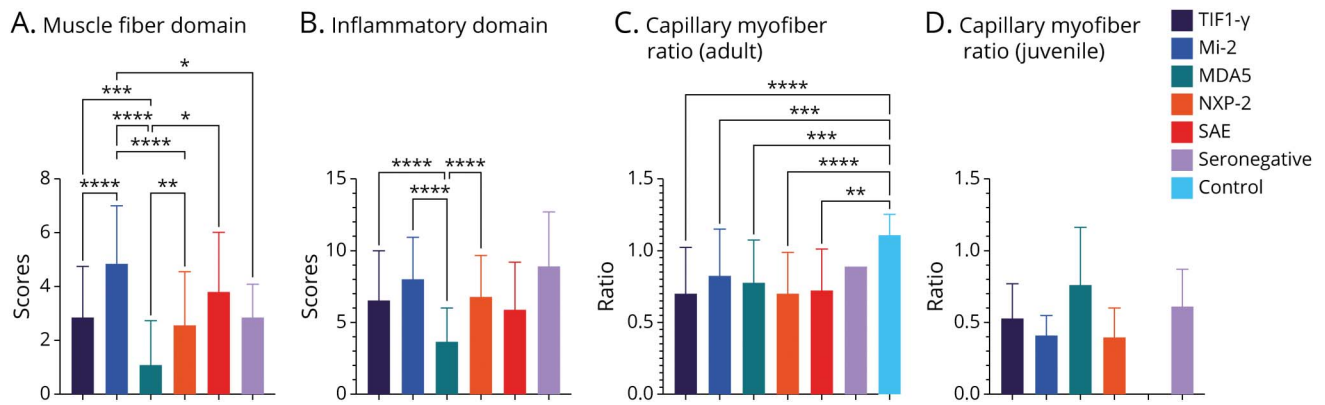
Ultrastructural Study

TRIs were observed in all 54 muscle biopsies (17 anti-TIF1- γ , 7 anti-Mi-2, 5 anti-MDA5, 22 anti-NXP-2, 1 anti-SAE, and 2 seronegative DM).

Histologic Features and Clustering

We performed MCA on 6 antibody subtypes (5 DMSA and 1 seronegative) and 23 histologic variables by AHC (eFigure 2, eTable 3, and eTable 4, [links.ww.com/WNL/B691](https://www.ww.com/WNL/B691)) and considered the principal coordinates of observations as a set of variables for AHC. The AHC algorithm computed

Figure 1 Pathology Domains Among Dermatomyositis-Specific Antibodies Subtypes



(A) Muscle fiber domain: anti-complex nucleosome remodeling histone deacetylase (Mi-2) dermatomyositis (DM) presented a higher muscle fiber domain score than anti-transcription intermediary factor 1-γ (TIF1-γ), anti-melanoma differentiation gene 5 (MDA5), anti-nuclear matrix protein 2 (NXP-2), and seronegative DM. (B) Inflammatory domain: anti-MDA5 DM was associated with a lower inflammatory domain score than anti-TIF1-γ, anti-Mi-2, and anti-NXP-2 DM. (C) Vascular domain: adult capillary:myofiber ratio. The ratio in adult DM was lower than controls. The ratio was not distinctively different among dermatomyositis-specific antibodies (DMSAs) subtypes. (D) Vascular domain: juvenile capillary: myofiber ratio. The ratio in juvenile DM was not different across DMSA subtypes. Bar = mean ± SD, analysis of variance with Dunnett T3 multiple comparison: *p* value 0.0332 (*), 0.0021 (**), 0.0002 (***), < 0.0001 (****). SAE = small ubiquitin-like modifier-activating enzyme.

dissimilarities of the variables by Euclidean distance and used the Ward method to successively merge variables into clusters with minimal variance. Because there were 6 antibody subtypes, we proposed 6 pathology classes by truncation. Pathologic features in anti-Mi-2, anti-MDA5, anti-SAE, and seronegative DM were more distinctive, with 74.4% of anti-Mi-2 cases categorized as class 1, 72.4% of anti-mDA5 class 3, and 90.0% and 100% of anti-SAE and seronegative DM, respectively, class 6. The features in anti-TIF1-γ and anti-NXP-2 DM were more similar (eTable 5).

Muscle Pathology Reevaluation by Histology Domains

The muscle fiber domain scores and inflammatory domain scores were different among DMSA subtypes (*p* < 0.001) (Figure 1, A and B). Compared with the other DMSA groups, muscle biopsies from anti-Mi-2 DM showed higher muscle fiber domain scores (4.9 ± 2.1 vs non-Mi-2 2.6 ± 2.0 ; *p* < 0.001) and higher inflammatory domain scores (8.0 ± 3.0 vs non-Mi-2 6.3 ± 3.3 ; *p* = 0.002) (Table 2). Anti-MDA5 DM showed a lower muscle fiber domain score (1.1 ± 1.6 vs non-MDA5 3.2 ± 2.1 ; *p* < 0.001) and a lower inflammatory domain score (3.7 ± 2.4 vs non-MDA5 6.9 ± 3.2 ; *p* < 0.001). In normal children, the capillary to muscle fiber ratio (CFR) was lower than the ratio in adults.²⁷ Thus, we evaluated the vascular domain in juvenile and adult patients separately. The CFR value in all adult DM cases (0.7 ± 0.3) was lower than the value in 12 normal adult muscle biopsies (1.1 ± 0.1 ; *p* < 0.001).⁷ The CFR did not significantly differ among DMSA subtypes (Figure 1, C and D). Anti-Mi-2 DM was more commonly associated with increased ALP activity in the perimysium (70.0% vs non-Mi-2 29.6%; *p* < 0.001).

Histologic Features

The characteristic features of each DM subtype are shown in Table 3, Figure 2, eFigure 3, eFigure 4, and eFigure 5a, links. www.com/WNL/B691. Compared with non-TIF1-γ DM, anti-TIF1-γ DM was associated with vacuolated/punched-out fibers (64.7% vs non-TIF1-γ 34.3%; *p* < 0.001) (Figure 2A). Vacuolated/punched-out fibers were not associated with anti-TIF1-γ DM with malignancy (74.3% vs non-malignancy 58.0%; *p* = 0.17). The following features were associated with anti-Mi-2 DM: PFA (67.5% vs non-Mi-2 46.3%; *p* = 0.02), PFN (52.5% vs non-Mi-2 3.3%; *p* < 0.001) (Figure 2 B), CD8 infiltration in non-necrotic fibers (7.7% vs non-Mi-2 0.9%; *p* = 0.03), ACP/CD68 infiltration in non-necrotic fibers (20.0% vs non-Mi-2 2.8%; *p* < 0.001), CD20 aggregation (28.2% vs non-Mi-2 13.0%; *p* = 0.03), and the presence of CNPR (45.0% vs non-Mi-2 20.8%; *p* = 0.002). Anti-MDA5 DM showed less common PFA (24.1%, vs non-MDA5 52.9%; *p* = 0.005) (Figure 2C), decreased COX activity in perifascicular areas (17.2% vs non-MDA5 50.0%; *p* < 0.001), perivascular inflammatory cell infiltration (13.8% vs non-MDA5 48.0%; *p* < 0.001), and vacuolated fiber (20.7% vs non-MDA5 47.6%; *p* = 0.009). Anti-NXP-2 DM was associated with microinfarction (26.5% vs non-NXP-2 9.3%; *p* < 0.001) (Figure 2D), and this finding was significant for both adult and juvenile patients. While there was a difference between the percentages of microinfarction affecting adults (12.2%) and juvenile patients with DM (22.4%; *p* = 0.05), the percentage of microinfarctions in adults (20.8%) and juvenile anti-NXP-2 DM (34.3%) was not different (*p* = 0.21). In our study, anti-SAE DM did not show any distinctive association with the above-mentioned items (eFigure 4). Seronegative DM was associated with perivascular inflammation (85.7% vs seropositive 43.0%; *p* = 0.05) and vasculitis (57.1% vs seropositive 14.1%; *p* = 0.01).

Table 2 Evaluation of Pathology Domains

	All DM (n = 256)	Anti-TIF1-γ (n = 87)	Anti-Mi-2 (n = 40)	Anti-MDA5 (n = 29)	Anti-NXP-2 (n = 83)	Anti-SAE (n = 10)	Seronegative (n = 7)
Muscle fiber domain							
Muscle fiber domain score	2.9 ± 2.1	2.9 ± 1.9	4.9 ± 2.1 ^{e*}	1.1 ± 1.6 ^{et}	2.6 ± 2.0	3.8 ± 2.2	2.9 ± 1.2
Necrotic fiber score	0.9 ± 0.9	0.8 ± 0.8	1.8 ± 0.5 ^{e*}	0.3 ± 0.6 ^{et}	0.9 ± 0.9	1.0 ± 0.8	0.4 ± 0.5 ^{et}
Regenerating fiber score	0.5 ± 0.5	0.4 ± 0.5 ^{et}	0.8 ± 0.4 ^{e*}	0.2 ± 0.4 ^{et}	0.5 ± 0.5	0.6 ± 0.5	0.9 ± 0.4 ^{e*}
Atrophic fiber score	0.5 ± 0.8	0.5 ± 0.7	0.9 ± 0.9 ^{e*}	0.2 ± 0.6 ^{et}	0.4 ± 0.6 ^{et}	0.7 ± 0.8	0.3 ± 0.8
PFA score	0.8 ± 0.9	0.9 ± 0.9	1.2 ± 0.9 ^{e*}	0.3 ± 0.7 ^{et}	0.7 ± 0.9	1.3 ± 0.9	1.0 ± 1.0
Fiber with internalized nuclei >3% score	0.2 ± 0.4	0.2 ± 0.4 ^{e*}	0.2 ± 0.4	0.0 ± 0.2 ^{et}	0.1 ± 0.3	0.2 ± 0.4	0.3 ± 0.5
Inflammatory domain							
Inflammatory domain score	6.6 ± 3.3 ^a	6.6 ± 3.4	8.0 ± 3.0 ^{a,e*}	3.7 ± 2.4 ^{et}	6.8 ± 2.9	5.9 ± 3.3	8.9 ± 3.8
Endomysial CD3 infiltration score	1.0 ± 0.7 ^a	1.0 ± 0.7	1.3 ± 0.6 ^{a,e*}	0.6 ± 0.6 ^{et}	1.0 ± 0.6	0.9 ± 0.6	1.6 ± 0.8
Perimysial CD3 infiltration score	0.5 ± 0.7 ^a	0.6 ± 0.8	0.7 ± 0.7 ^a	0.1 ± 0.4 ^{et}	0.5 ± 0.7	0.6 ± 0.8	1.0 ± 1.0
Endomysial CD20 infiltration score	1.0 ± 0.8 ^a	1.0 ± 0.8	1.5 ± 0.7 ^{a,e*}	0.3 ± 0.6 ^{et}	1.0 ± 0.7	0.6 ± 0.7	1.1 ± 0.9
Perimysial CD20 infiltration score	0.5 ± 0.7 ^a	0.6 ± 0.7	0.6 ± 0.7 ^a	0.1 ± 0.4 ^{et}	0.5 ± 0.7	0.4 ± 0.8	0.9 ± 0.7
Endomysial CD68 infiltration score	1.8 ± 0.4 ^a	1.8 ± 0.5	1.9 ± 0.3 ^a	1.6 ± 0.5 ^{et}	1.8 ± 0.4	1.8 ± 0.4	1.9 ± 0.4
Perimysial CD68 infiltration score	1.2 ± 0.7 ^a	1.2 ± 0.8	1.5 ± 0.6 ^{a,e*}	0.8 ± 0.7 ^{et}	1.3 ± 0.7	1.4 ± 0.5	1.6 ± 0.5
Perivascular inflammatory cell infiltration score	0.4 ± 0.5	0.5 ± 0.5	0.5 ± 0.5	0.1 ± 0.4 ^{et}	0.5 ± 0.5	0.2 ± 0.4	0.9 ± 0.4 ^{e*}
Vascular domain							
Capillary: fiber ratio, adult patients	0.7 ± 0.3 ^{ft}	0.7 ± 0.3 ^{ft}	0.8 ± 0.3 ^{ft}	0.8 ± 0.3 ^{ft}	0.7 ± 0.3 ^{ft}	0.7 ± 0.3 ^{ft}	0.9
Capillary: fiber ratio, juvenile patients	0.5 ± 0.3 ^b	0.5 ± 0.2 ^b	0.4 ± 0.1	0.8 ± 0.4	0.4 ± 0.2 ^{et}	NA	0.6 ± 0.3
Connective tissue domain							
Perimysium fragmentation	182 (71.9) ^c	61 (71.8) ^d	33 (84.6) ^b	11 (37.9) ^{et}	63 (75.9)	7 (70.0)	7 (100.0)
Perimysium ALP activity, increased	92 (35.9)	21 (24.1) ^{et}	28 (70.0) ^{e*}	4 (13.8) ^{et}	33 (39.8)	2 (20.0)	4 (57.1)
Endomysial fibrosis	37 (14.6) ^c	12 (14.1) ^d	9 (23.1) ^b	1 (3.4)	10 (12.0)	1 (10.0)	4 (57.1) ^{e*}

Abbreviations: ALP = alkaline phosphatase; CD = cluster of differentiation; DM = dermatomyositis; MDA5 = melanoma differentiation-associated gene 5; Mi-2 = complex nucleosome remodeling histone deacetylase antibody; NA = not available; NXP-2 = nuclear matrix protein 2; PFA = perifascicular atrophy; SAE = small ubiquitin-like modifier activating enzyme; TIF1-γ = transcription intermediary factor 1-γ antibody. Continuous data are shown as mean ± SD; categorical data are shown as number (%).

^a Not evaluated in 1 patient due to insufficient tissue for additional staining.

^b Not evaluated in 1 patient due to tissue artifacts.

^c Not evaluated in 3 patients due to tissue artifacts.

^d Not evaluated in 2 patients due to tissue artifacts.

^e $p < 0.05$ vs other antibody subtypes (*higher score/percentage/ratio; †lower score/percentage/ratio).

^f $p < 0.05$ vs normal specimen (*higher score/percentage/ratio; †lower score/percentage/ratio).

CNPR fibers were commonly present in muscle biopsies with microinfarction (57.9% vs 18.8%; $p < 0.001$) and 36.8% (14/63) of CNPR were present in the infarcted region (Figure 2D and eFigure 6, links.lww.com/WNL/B691).

Immunohistochemical Features of Interest

All muscle biopsies in this study expressed both MxA and HLA-ABC. MxA expression showed 37.5% pure perifascicular staining pattern, 25.4% scattered/diffuse pattern, and 37.1% mixed pattern (Figure 3 and eFigure 4, links.lww.com/WNL/

B691). Pure perifascicular MxA staining was associated with anti-Mi-2 DM (67.5% vs non-Mi-2 31.9%; $p < 0.001$), while a pure scattered/diffuse staining pattern was associated with anti-MDA5 DM (65.5% vs non-MDA5 20.3%; $p < 0.001$). HLA-DR positivity, either scattered or perifascicular patterns, were associated with anti-SAE (50.0% vs non-SAE 16.7%; $p = 0.02$) and seronegative DM (57.1% vs seropositive 16.9%; $p = 0.02$). Anti-TIF1-γ and anti-NXP-2 DM were associated with capillary MAC deposition (96.6% vs non-TIF1-γ 86.4%; $p = 0.009$ and 98.8% vs non-NXP-2 85.6%; $p < 0.001$), capillary

Table 3 Histologic Features of Interest

Histologic features of interest	All DM (n = 256)	Anti-TIF1- γ (n = 87)	Anti-Mi-2 (n = 40)	Anti-MDA5 (n = 29)	Anti-NXP-2 (n = 83)	Anti-SAE (n = 10)	Seronegative (n = 7)
Perifascicular atrophy	127 (49.6)	49 (56.3)	27 (67.5) ^{dx}	7 (24.1) ^{dt}	33 (39.8) ^{dt}	7 (70.0)	4 (57.1)
Perifascicular necrosis	28 (10.9)	3 (3.4) ^{dt}	21 (52.5) ^{dx}	0	2 (2.4) ^{dt}	0	2 (28.6)
Decreased COX activity in perifascicular area	118 (46.3) ^a	47 (54.7) ^a	21 (52.5)	5 (17.2) ^{dt}	37 (44.6)	4 (40.0)	4 (57.1)
Perivascular inflammatory cell infiltration	113 (44.1)	41 (47.1)	18 (45.0)	4 (13.8) ^{dt}	42 (50.6)	2 (20.0)	6 (85.7) ^{dx}
Vasculitis	39 (15.2)	10 (11.5)	10 (25.0)	0	15 (18.1)	0	4 (57.1) ^{dx}
CD8 infiltration in non-necrotic fiber	5 (2.0) ^b	2 (2.3)	3 (7.7) ^{b,dx}	0	0	0	0
ACP/CD68 infiltration in non-necrotic fiber	14 (5.5)	4 (4.6)	8 (20.0) ^{dx}	0	1 (1.2) ^{dt}	0	1 (14.3)
CD20 aggregation	39 (15.3) ^b	10 (11.5)	11 (28.2) ^{b,dx}	1 (3.5)	13 (15.7)	1 (10.0)	3 (42.9)
Microinfarction	38 (14.8)	11 (12.6)	0	3 (10.3)	22 (26.5) ^{dx}	2 (20.0)	0
Microinfarction, adult patients	23 (12.2)	10 (13.9)	0	1 (4.8)	10 (20.8) ^{dx}	2 (20.0)	0
Microinfarction, juvenile patients	15 (22.4)	1 (6.7)	0	2 (25.0)	12 (34.3) ^{dx}	0	0
Central necrotic-peripheral regenerating fibers	63 (24.6)	21 (24.1)	18 (45.0) ^{dx}	3 (10.3)	18 (21.7)	2 (20.0)	1 (14.3)
Vacuolated, punched-out fiber	113 (44.5) ^c	55 (64.7) ^{c,dx}	3 (7.5) ^{dt}	6 (20.7) ^{dt}	40 (48.2)	7 (70.0)	2 (28.6)

Abbreviations: ACP = acid phosphatase; CD = cluster of differentiation; COX = cytochrome C oxidase; DM = dermatomyositis; MDA5 = melanoma differentiation-associated gene 5; Mi-2 = complex nucleosome remodeling histone deacetylase antibody; NXP-2 = nuclear matrix protein 2; SAE = small ubiquitin-like modifier activating enzyme; TIF1- γ = transcription intermediary factor 1- γ antibody. Continuous data are shown as mean \pm SD; categorical data are shown as number (%).

^a Not evaluated in 1 patient due to tissue artifacts.

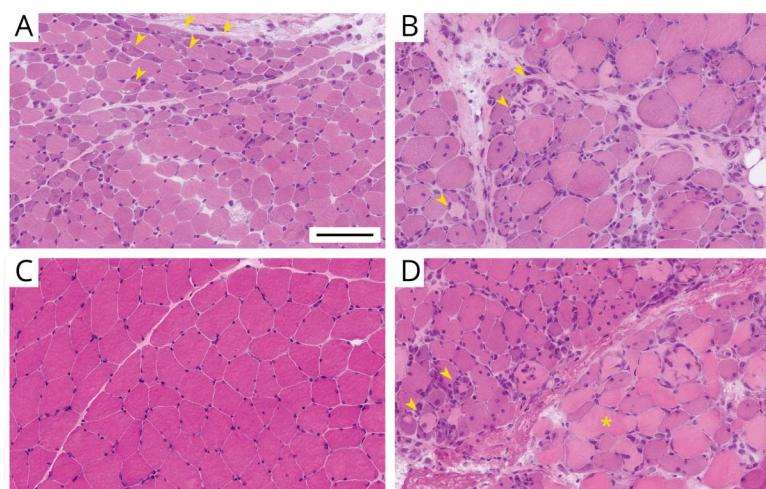
^b Not evaluated in 1 patient due to insufficient tissue for additional staining.

^c Not evaluated in 2 patients due to tissue artifacts.

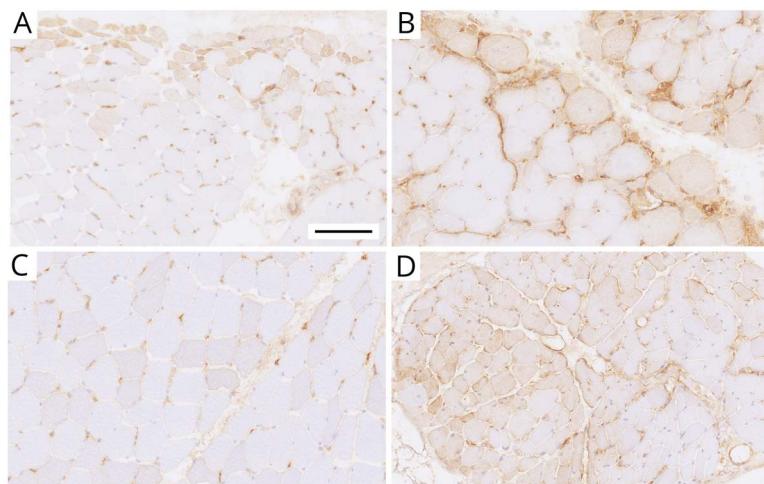
^d $p < 0.05$ vs other antibody subtypes (*higher percentage; [†]lower percentage).

MAC deposition with perifascicular pattern (74.7% vs non-TIF1- γ 57.4%; $p = 0.006$ and 78.3% vs non-NXP-2 56.1%; $p < 0.001$), and distinct capillary MAC deposition in perifascicular areas (71.3% vs non-TIF1- γ 55.0%; $p = 0.01$ and 75.9% vs non-NXP-2 53.2%; $p < 0.001$). Distinct capillary

MAC deposition in anti-TIF1- γ DM was not associated with malignancy (69.4% vs non-malignancy-associated TIF1- γ 72.6%; $p = 0.81$). Sarcolemmal MAC deposition of any pattern or with some area showing perifascicular pattern was present in anti-Mi-2 DM (67.5% vs non-Mi-2 19.0%;

Figure 2 Pathology Features of Major Dermatomyositis-Specific Antibodies Subtypes

On hematoxylin & eosin staining, anti-transcription intermediary factor 1- γ (TIF1- γ) dermatomyositis showed perifascicular atrophy with vacuolated/punched-out fibers (A, yellow arrowheads); anti-complex nucleosome remodeling histone deacetylase (Mi-2) was associated with perifascicular necrosis (B); anti-melanoma differentiation gene 5 (MDA5) with near normal appearance (C); and anti-nuclear matrix protein 2 (NXP-2) with microinfarction (D, yellow asterisk). Central necrotic-peripheral regenerating fibers were present in anti-Mi-2 and anti-NXP-2 subtypes (B and D, yellow arrowheads). Bar = 100 μ m.



Perifascicular pattern (A, B) and scattered (C)/diffuse (D) pattern. Bar = 100 μ m.

$p < 0.001$ and 50.0% vs non-Mi-2 5.6%; $p < 0.001$, respectively) (Table 4, eFigure 3, eFigure 4, and eFigure 5b, links.lww.com/WNL/B691).

Because the features in anti-TIF1- γ and anti-NXP-2 DM tended to overlap, we compared the features in both subtypes (eTable 5, links.lww.com/WNL/B691). Anti-TIF1- γ DM was associated with PFA ($p = 0.03$), vacuolated/punched-out fiber ($p = 0.04$), and HLA-ABC expression with perifascicular enhancement ($p < 0.001$). Anti-NXP-2 DM was associated with ALP activity in perifascicular area ($p = 0.03$) and microinfarction ($p = 0.03$).

Discussion

This was a comprehensive study on serologic–pathologic correlations of different DMSA subtypes. The sarcoplasmic MxA expression was used as a diagnostic finding of DM on muscle pathology as it has been proven to be highly sensitive (71%–77%) and specific (98%–100%) for DM.^{19,20} We also confirmed that the presence of MxA expression was more sensitive than PFA for the diagnosis of DM (100% vs 49.6%).¹⁹ However, as only MxA with perifascicular pattern is mentioned in the 2018 ENMC-DM classification, this may result in underdiagnosis or misclassification of 25.4% of DM muscle biopsies. We thus propose that sarcoplasmic MxA expression in non-necrotic/regenerating fibers should be regarded as diagnostic of DM, regardless of the pattern of the distribution of MxA-positive fibers. Using MxA expression as a criterion, we identified 7 seronegative DMs that warrant further study and have yet to be identified as DMSA or as truly seronegative.

We regarded DMSD as a form of DM.¹² Thus, unlike the 2018 ENMC-DM classification, which requires identification of cutaneous DM features either clinically or pathologically,² we

included all qualified muscle biopsies in our serologic–pathologic criteria regardless of the cutaneous features. In this extended cohort,¹² 19 anti-NXP-2 antibody-positive patients (19/83 [22.9%]) presented no skin lesion of any kind at the time of diagnosis and were classified as DMSD. The proportion was comparable with cases recently reported in a separate study (8/76 [10.5%]; $p = 0.06$).²⁴

In addition to the DMSA-associated clinical phenotypes that are described above, in our cohort, anti-TIF1- γ and anti-Mi-2 were associated with adult patients while anti-NXP-2 was associated with juvenile patients. We confirmed that anti-TIF1- γ was distinctively associated with malignancy. Presence of anti-TIF1- γ antibody in individuals below the age of 40 should also warrant malignancy workup. Anti-SAE DM was associated with elderly patients and a low CK level and showed a trend for DM skin lesions, muscle weakness, dysphagia, and concurrent malignancy, albeit not significantly, which may be at least partly due to the limited number of patients in this study. Seronegative DM was associated with juvenile patients with less frequent DM skin lesions.

Due to the retrospective nature of this study, the clinical information was limited. Thus, we cannot exclude the possibility of malignancy-associated myositis- and DM-specific skin lesions that may develop after muscle biopsy diagnosis. This may affect the prevalence in each antibody subtype. The small number of anti-SAE DM in our study was likely because of the lower prevalence of anti-SAE DM in Japanese populations.²³

We used MCA and AHC to explore similarities and differences among DMSA subtypes. We proposed to use 6 as a number for AHC truncation because we believe that different DMSA subtypes (5 DMSAs and seronegative DM) are

Table 4 Immunohistochemical Features of Interest

Immunohistochemical features	All DM (n = 256)	Anti-TIF1- γ (n = 87)	Anti-Mi-2 (n = 40)	Anti-MDA5 (n = 29)	Anti-NXP-2 (n = 83)	Anti-SAE (n = 10)	Seronegative (n = 7)
MxA positivity	256 (100.0)	87 (100.0)	40 (100.0)	29 (100.0)	83 (100.0)	10 (100.0)	7 (100.0)
MxA, perifascicular pattern	96 (37.5)	35 (40.2)	27 (67.5) ^{a*}	5 (17.2) ^{a†}	23 (27.7) ^{a†}	3 (30.0)	3 (42.9)
MxA, scattered/diffuse	65 (25.4)	14 (16.1) ^{a†}	5 (12.5) ^{a†}	19 (65.5) ^{a*}	24 (28.9)	0	3 (42.9)
MxA, mixed pattern	95 (37.1)	38 (43.7)	8 (20.0) ^{a†}	5 (17.2) ^{a†}	36 (43.4)	7 (70.0) ^{a*}	1 (14.3)
HLA-ABC positivity	256 (100.0)	87 (100.0)	40 (100.0)	29 (100.0)	83 (100.0)	10 (100.0)	7 (100.0)
HLA-ABC, perifascicular enhancement	149 (58.2)	66 (75.9) ^{a*}	26 (65.0)	5 (17.2) ^{a†}	41 (49.4)	8 (80)	3 (42.9)
HLA-DR positivity	46 (18.0)	16 (18.4)	5 (12.5)	1 (3.4) ^{a†}	15 (18.1)	5 (50.0) ^{a*}	4 (57.1) ^{a*}
HLA-DR, perifascicular pattern	27 (10.5)	8 (9.2)	1 (2.5)	0	10 (12.0)	5 (50.0) ^{a*}	3 (42.9) ^{a*}
MAC capillary deposition	230 (89.8)	84 (96.6) ^{a*}	23 (57.5) ^{a†}	25 (86.2)	82 (98.8) ^{a*}	10 (100)	6 (85.7)
MAC capillary deposition with perifascicular pattern	162 (63.3)	65 (74.7) ^{a*}	11 (27.5) ^{a†}	7 (24.1) ^{a†}	65 (78.3) ^{a*}	9 (90.0)	5 (71.4)
Distinct MAC capillary deposition in perifascicular area	155 (60.5)	62 (71.3) ^{a*}	8 (20.0) ^{a†}	9 (31.0) ^{a†}	63 (75.9) ^{a*}	8 (80.0)	5 (71.4)
MAC sarcolemmal deposition	68 (26.6)	14 (16.1) ^{a†}	27 (67.5) ^{a*}	2 (6.9) ^{a†}	16 (19.3)	5 (50.0)	4 (57.1)
MAC sarcolemmal deposition with perifascicular pattern	32 (12.5)	8 (9.2)	20 (50.0) ^{a*}	0	2 (2.4) ^{a†}	2 (20.0)	0

Abbreviations: DM = dermatomyositis; HLA = human leukocyte antigen; MAC = membrane attack complex; MDA5 = melanoma differentiation-associated gene 5; Mi-2 = complex nucleosome remodeling histone deacetylase antibody; MxA = myxovirus resistant protein A; NXP-2 = nuclear matrix protein 2; SAE = small ubiquitin-like modifier activating enzyme; TIF1- γ = transcription intermediary factor 1- γ antibody. Continuous data are shown as mean \pm SD; categorical data are shown as number (%).

^a $p < 0.05$ vs other antibody subtypes (*higher percentage; [†]lower percentage).

associated with different pathologic mechanisms and pathologic features. We later identified pathologic characteristics of each DM subtype classified by DMSAs; some were previously described in smaller studies. Histologic features in anti-Mi-2 DM were compatible with those previously described in immune myopathy with perimysial pathology.^{7,16} By comparing each DMSA with other subtypes, anti-Mi-2 was associated with PFA,^{7,9} PFN,^{7,16} PM-ALP,^{7,16} inflammatory features,⁷⁻⁹ perifascicular MxA expression, and sarcolemmal MAC expression.^{7,9,16} We confirmed that anti-TIF1- γ DM was associated with vacuolated fibers,⁴ HLA-ABC expression with perifascicular enhancement, and distinctive capillary MAC deposition.⁴ Vacuolated/punched-out fibers and distinctive capillary MAC deposition were suggested to associate with malignancy-associated anti-TIF1- γ DM.⁴ However, we could not demonstrate an association between these features and malignancy. Although anti-TIF1- γ and anti-NXP-2 DM were very similar, anti-TIF1- γ DM has a higher association with PFA and HLA-ABC expression with perifascicular enhancement, features described for DM with vasculopathy.^{28,29}

Anti-NXP-2 was associated with microinfarctions described in regional ischemic immune myopathy.²⁸ Although few cases

have been reported describing muscle ischemia or clustered necrosis in juvenile anti-NXP-2 DM,^{16,17} we provide evidence that adult and juvenile anti-NXP-2 DM were equally affected by microinfarction. Because the percentages of microinfarctions in adult and juvenile anti-NXP-2 DM were not significantly different, this phenomenon could not simply be explained by different CFRs between the 2 age groups. In a recent study of inflammatory myopathies, anti-NXP-2 and anti-TIF1- γ were categorized as myovascular myopathy because they both showed loss of endomysial capillaries or positive MAC deposition.³⁰ In our study, while the percentage of MAC deposition on capillaries in anti-NXP-2 DM was virtually equal to the percentage in anti-TIF1- γ DM, the percentages of microinfarction in these 2 entities were significantly different. Thus, microinfarction could not be explained by complement deposition and warrants further study.

CNPR fibers are peculiar necrotic-regenerating fibers, described as rare in muscular dystrophies,³¹ but their presence has never been fully studied. In our experience, CNPR was not observed in 140 muscle biopsies with genetically confirmed muscular dystrophies (eTable 6, links.lww.com/WNL/B691), although these muscular dystrophies may sometimes show

myositis-mimicking pathology.³² It appears that crescent-shaped small regenerating fibers are present at the periphery of necrotic fibers although detailed morphologic analysis could not be performed as samples were not available for electron microscopy for the patients with CNPR fibers.

In muscular dystrophies and necrotizing myopathies, necrotic fibers are often invaded by macrophages, which are believed to clean up the liquefied sarcoplasm, while regeneration is initiated in parallel. In our study, CNPR fibers were significantly associated with microinfarction and some of the neighboring fibers contained lipid droplets or cytoplasmic bodies. These findings, together with their hypoxia-inducible factor expression, suggested that they reflect hypoxic injury. Of note, infarcted fibers do not usually accompany macrophage invasion, which may partly explain why CNPR fibers did not undergo phagocytosis. CNPR fibers were more commonly present in anti-Mi-2 DM, which was not associated with microinfarction. Further studies are necessary to better understand whether CNPR fibers in anti-Mi-2 are developed through a mechanism different from those in anti-NXP-2 DM. Anti-MDA5 DM was associated with near normal pathology^{16,17,33} and scattered/diffuse MxA positivity,²⁰ while anti-SAE DM was distinctively associated with HLA-DR expression. Seronegative DM showed a trend toward inflammation and was associated with significant HLA-DR expression. Because HLA-DR expression is a marker of the type II interferon,³⁴ there may well be more prominent type II interferon activation in these antibody subtypes.

Our study demonstrated distinctive myopathologic features associated with DMSA subtypes, which may well indicate the presence of different underlying pathobiologic mechanisms. Inclusion of these features into classification criteria would not only increase diagnostic yield but also help classify DM subtypes.

Acknowledgment

The authors thank Kazu Iwazawa, Kaoru Tatezawa, Naho Fushimi, Miyuki Matsuda, and Hisayoshi Nakamura for technical assistance.

Study Funding

This study was supported by Intramural Research Grant 29-4 for Neurologic and Psychiatric Disorders of the National Center of Neurology and Psychiatry.

Disclosure

The authors report no disclosures relevant to the manuscript. Go to Neurology.org/N for full disclosures.

Publication History

Received by *Neurology* June 25, 2021. Accepted in final form November 24, 2021.

Appendix Authors

Name	Location	Contribution
Jantima Tanboon, MD	Department of Neuromuscular Research, National Institute of Neuroscience, National Center of Neurology and Psychiatry (NCNP); Department of Genome Medicine Development, Medical Genome Center, National Center of Neurology and Psychiatry (NCNP), Tokyo, Japan	Drafting/revision of the manuscript for content, including medical writing for content; major role in the acquisition of data; study concept or design; analysis or interpretation of data
Michio Inoue, MD, PhD	Department of Neuromuscular Research, National Institute of Neuroscience, National Center of Neurology and Psychiatry (NCNP); Department of Genome Medicine Development, Medical Genome Center, National Center of Neurology and Psychiatry (NCNP), Tokyo, Japan	Drafting/revision of the manuscript for content, including medical writing for content; major role in the acquisition of data
Yoshihiko Saito, MD, PhD	Department of Neuromuscular Research, National Institute of Neuroscience, National Center of Neurology and Psychiatry (NCNP); Department of Genome Medicine Development, Medical Genome Center, National Center of Neurology and Psychiatry (NCNP), Tokyo, Japan	Drafting/revision of the manuscript for content, including medical writing for content; major role in the acquisition of data
Hisateru Tachimori, PhD	Department of Clinical Epidemiology, Translational Medical Center, National Center of Neurology and Psychiatry (NCNP); Endowed Course for Health System Innovation, Keio University School of Medicine, Tokyo, Japan	Drafting/revision of the manuscript for content, including medical writing for content
Shinichiro Hayashi, PhD	Department of Neuromuscular Research, National Institute of Neuroscience, National Center of Neurology and Psychiatry (NCNP); Department of Genome Medicine Development, Medical Genome Center, National Center of Neurology and Psychiatry (NCNP), Tokyo, Japan	Drafting/revision of the manuscript for content, including medical writing for content
Satoru Noguchi, PhD	Department of Neuromuscular Research, National Institute of Neuroscience, National Center of Neurology and Psychiatry (NCNP); Department of Genome Medicine Development, Medical Genome Center, National Center of Neurology and Psychiatry (NCNP), Tokyo, Japan	Drafting/revision of the manuscript for content, including medical writing for content

Appendix (continued)

Name	Location	Contribution
Naoko Okiyama, MD, PhD	Department of Dermatology, Faculty of Medicine, University of Tsukuba, Ibaraki, Japan	Drafting/revision of the manuscript for content, including medical writing for content; major role in the acquisition of data
Manabu Fujimoto, MD, PhD	Department of Dermatology, Graduate School of Medicine, Osaka University, Japan	Drafting/revision of the manuscript for content, including medical writing for content; major role in the acquisition of data
Ichizo Nishino, MD, PhD	Department of Neuromuscular Research, National Institute of Neuroscience, National Center of Neurology and Psychiatry (NCNP); Department of Genome Medicine Development, Medical Genome Center, National Center of Neurology and Psychiatry (NCNP), Tokyo, Japan	Drafting/revision of the manuscript for content, including medical writing for content; major role in the acquisition of data; study concept or design; analysis or interpretation of data

References

- Bohan A, Peter JB. Polymyositis and dermatomyositis (first of two parts). *N Engl J Med*. 1975;292(7):344-347.
- Mammen AL, Allenbach Y, Stenzel W, Benveniste O. ENMC 239th Workshop Study Group. 239th ENMC international workshop: classification of dermatomyositis, Amsterdam, The Netherlands, 14-16 December 2018. *Neuromuscul Disord*. 2020;30(1):70-92.
- Tanboon J, Uruha A, Stenzel W, Nishino I. Where are we moving in the classification of idiopathic inflammatory myopathies? *Curr Opin Neurol*. 2020;33(5):590-603.
- Hida A, Yamashita T, Hosono Y, et al. Anti-TIF1- γ antibody and cancer-associated myositis: a clinicohistopathologic study. *Neurology*. 2016;87(3):299-308.
- Mugii N, Hasegawa M, Matsushita T, et al. Oropharyngeal dysphagia in dermatomyositis: associations with clinical and laboratory features including autoantibodies. *PLoS One*. 2016;11(5):e0154746.
- Betteridge Z, Tansley S, Shaddick G, et al. Frequency, mutual exclusivity and clinical associations of myositis autoantibodies in a combined European cohort of idiopathic inflammatory myopathy patients. *J Autoimmun*. 2019;101:48-55.
- Tanboon J, Inoue M, Hirakawa S, et al. Pathologic features of anti-Mi-2 dermatomyositis. *Neurology*. 2021;96(3):e448-e459.
- Pinal-Fernandez I, Mecoli CA, Casal-Dominguez M, et al. More prominent muscle involvement in patients with dermatomyositis with anti-Mi-2 autoantibodies. *Neurology*. 2019;93(19):e1768-e1777.
- Fornaro M, Girolamo F, Cavagna L, et al. Severe muscle damage with myofiber necrosis and macrophage infiltrates characterize anti-Mi-2 positive dermatomyositis. *Rheumatology*. 2021;60(6):2916-2926.
- Allenbach Y, Uzunhan Y, Toquet S, et al. Different phenotypes in dermatomyositis associated with anti-MDA5 antibody: study of 121 cases. *Neurology*. 2020;95(1):e70-e78.
- Mamyrova G, Kishi T, Shi M, et al. Anti-MDA5 autoantibodies associated with juvenile dermatomyositis constitute a distinct phenotype in North America. *Rheumatology*. 2021;60(4):1839-1849.
- Inoue M, Tanboon J, Hirakawa S, et al. Association of dermatomyositis sine dermatitis and with anti-nuclear matrix protein 2 autoantibodies. *JAMA Neurol*. 2020;77(7):872-877.
- Albayda J, Pinal-Fernandez I, Huang W, et al. Antinuclear matrix protein 2 autoantibodies and edema, muscle disease, and malignancy risk in dermatomyositis patients. *Arthritis Care Res*. 2017;69(11):1771-1776.
- Allenbach Y, Benveniste O, Goebel HH, Stenzel W. Integrated classification of inflammatory myopathies. *Neuropathol Appl Neurobiol*. 2017;43(1):62-81.
- Benveniste O, Goebel HH, Stenzel W. Biomarkers in inflammatory myopathies—an expanded definition. *Front Neurol*. 2019;10:554.
- Nguyen M, Do V, Yell PC, et al. Distinct tissue injury patterns in juvenile dermatomyositis auto-antibody subgroups. *Acta Neuropathol Commun*. 2020;8(1):125.
- Yasin SA, Schutz PW, Deakin CT, et al. Histological heterogeneity in a large clinical cohort of juvenile idiopathic inflammatory myopathy: analysis by myositis autoantibody and pathologic features. *Neuropathol Appl Neurobiol*. 2019;45(5):495-512.
- Greenberg SA, Pinkus JL, Pinkus GS, et al. Interferon-alpha/beta-mediated innate immune mechanisms in dermatomyositis. *Ann Neurol*. 2005;57(5):664-678.
- Uruha A, Nishikawa A, Tsuburaya RS, et al. Sarcoplasmic MxA expression: a valuable marker of dermatomyositis. *Neurology*. 2017;88(5):493-500.
- Uruha A, Allenbach Y, Charuel JL, et al. Diagnostic potential of sarcoplasmic myxovirus resistance protein A expression in subsets of dermatomyositis. *Neuropathol Appl Neurobiol*. 2019;45(5):513-522.
- Soponkanaporn S, Deakin CT, Schutz PW, et al. Expression of myxovirus-resistance protein A: a possible marker of muscle disease activity and autoantibody specificities in juvenile dermatomyositis. *Neuropathol Appl Neurobiol*. 2019;45(4):410-420.
- Inoue M, Tanboon J, Okubo M, et al. Absence of sarcoplasmic myxovirus resistance protein A (MxA) expression in antisynthetase syndrome in a cohort of 194 cases. *Neuropathol Appl Neurobiol*. 2019;45(5):523-524.
- Fujimoto M, Matsushita T, Hamaguchi Y, et al. Autoantibodies to small ubiquitin-like modifier activating enzymes in Japanese patients with dermatomyositis: comparison with a UK Caucasian cohort. *Ann Rheum Dis*. 2013;72(1):151-153.
- Ichimura Y, Konishi R, Shobo M, et al. Anti-nuclear matrix protein 2 antibody-positive idiopathic inflammatory myopathies represent extensive myositis without dermatomyositis-specific rash. *Rheumatol*. Epub 2021 June 21.
- Kishi T, Tani Y, Okiyama N, et al. Anti-SAE autoantibody-positive Japanese patient with juvenile dermatomyositis complicated with interstitial lung disease: a case report. *Pediatr Rheumatol Online J*. 2021;19(1):34.
- Wedderburn LR, Varsani H, Li CK, et al. International consensus on a proposed score system for muscle biopsy evaluation in patients with juvenile dermatomyositis: a tool for potential use in clinical trials. *Arthritis Rheum*. 2007;57(7):1192-1201.
- Carry MR, Ringel SP, Starcevic JM. Distribution of capillaries in normal and diseased human skeletal muscle. *Muscle Nerve*. 1986;9(5):445-454.
- Cai C, Alshehri A, Choksi R, Pestronk A. Regional ischemic immune myopathy: a paraneoplastic dermatomyopathy. *J Neuropathol Exp Neurol*. 2014;73(12):1126-1133.
- Bucelli RC, Pestronk A. Immune myopathies with perimysial pathology: clinical and laboratory features. *Neurol Neuroimmunol Neuroinflamm*. 2018;5(2):e434.
- Pestronk A, Choksi R. Pathology features of immune and inflammatory myopathies, including a polymyositis pattern, relate strongly to serum autoantibodies. *J Neuropathol Exp Neurol*. 2021;80(9):812-820.
- Dubowitz V, Sewry CA, Oldfors A, eds. *Muscle Biopsy: A Practical Approach*, 5th ed. Elsevier; 2020.
- Allenbach Y, Mammen AL, Benveniste O, Stenzel W. Immune-Mediated Necrotizing Myopathies Working Group. 224th ENMC international workshop: clinico-seropathologic classification of immune-mediated necrotizing myopathies Zandvoort, the Netherlands, 14-16 October 2016. *Neuromuscul Disord*. 2018;28(1):87-99.
- Allenbach Y, Leroux G, Suárez-Calvet X, et al. Dermatomyositis with or without anti-melanoma differentiation-associated gene 5 antibodies: common interferon signature but distinct NOS2 expression. *Am J Pathol*. 2016;186(3):691-700.
- Carey BS, Poulton KV, Poles A. Factors affecting HLA expression: a review. *Int J Immunogenet*. 2019;46(5):307-320.