

Wilm's tumor with intracardiac extension causing dynamic tricuspid valve obstruction: An anesthetic challenge

ABSTRACT

Wilms' tumor (WT) is the most common pediatric renal tumor that often spreads to inferior vena cava and sometimes up to right atrium (RA). We describe successful management of 3-year-old child diagnosed with WT having extension up to RA. He was operated under cardiopulmonary bypass and extubated on postoperative day 2 and discharged. Perioperative anesthesia concerns were shock from dynamic tricuspid valve obstruction, intraoperative massive blood loss, and a higher risk of pulmonary thromboembolism during tumor manipulation.

Key words: Cardiopulmonary bypass; tricuspid valve obstruction; Wilms' tumour

Introduction

Written informed consent was obtained from the parent of the patient for publication of this report. Wilms' tumor (WT) is the most common pediatric renal tumor, which can spread as tumor thrombus to inferior vena cava (IVC) and rarely (in 1% of cases) up to the heart.^[1] We are describing successful management of 3-year-old child diagnosed with WT having an extension up to right atrium causing dynamic obstruction across tricuspid valve (TV). He was operated under cardiopulmonary bypass (CPB) and extubated on postoperative day 2 and discharged.

Case Report

A 3-year-old male child (height 102 cm, weight 15.6 kg, body surface area 0.66 m²) was diagnosed with WT of the

right kidney. His physical examination was unremarkable except for raised jugular venous pressure. Transthoracic echocardiography (TTE) revealed large mass filling IVC extending up to TV with no flow across the valve. Contrast-enhanced computed tomography demonstrated additional features of tumor blocking the ostium of the middle hepatic vein (HV). The patient received three cycles of neoadjuvant chemotherapy. While in hospital, the child suffered an episode of shock probably attributed to dynamic TV obstruction due to tumor mass. Resuscitation was done in Trendelenburg position with fluid bolus. Emergency radical nephrectomy and removal of tumor extension under CPB was planned. Preoperative laboratory investigations were within normal limits except mildly elevated hepatic enzymes reflecting mild hepatic dysfunction. Inhalational induction

This is an open access article distributed under the terms of the Creative Commons Attribution-NonCommercial-ShareAlike 3.0 License, which allows others to remix, tweak, and build upon the work non-commercially, as long as the author is credited and the new creations are licensed under the identical terms.

For reprints contact: reprints@medknow.com

How to cite this article: Kajal K, Munirathinam GK, Mandal B, Gandhi K, Singh H, Kanojia R. Wilm's tumor with intracardiac extension causing dynamic tricuspid valve obstruction: An anesthetic challenge. Saudi J Anaesth 2018;12:321-3.

Access this article online	
Website: www.saudija.org	Quick Response Code 
DOI: 10.4103/sja.SJA_472_17	

KAMAL KAJAL, GANESH KUMAR MUNIRATHINAM, BANASHREE MANDAL, KOMAL GANDHI, HARKANT SINGH¹, RAVI KANOJIA²

Departments of Anaesthesia and Intensive Care, ¹Cardiothoracic and Vascular surgery and ²Paediatric Surgery, Postgraduate Institute of Medical Education and Research, Chandigarh, India

Address for correspondence: Dr. Kamal Kajal, Department of Anaesthesia and Intensive Care, Fourth Floor, Nehru Hospital, Postgraduate Institute of Medical Education and Research, Chandigarh - 160 012, India.
E-mail: kamal.kajal@gmail.com

done by slow titration of sevoflurane in oxygen; subsequent muscle relaxation was achieved with injection atracurium 0.5 mg/kg for tracheal intubation. Balanced anesthesia before CPB was maintained with fentanyl infusion 15 µg/h, isoflurane in oxygen and atracurium infusion 0.2 mg/kg/h. Central venous catheter 5.5 Fr was inserted from the right internal jugular vein under ultrasonographic guidance along with 18 gauge cannula in the left external jugular vein. Transoesophageal echocardiography (TOE) probe was inserted for continuous monitoring during tumor handling [Figure 1a-c]. CPB was kept on standby, and abdominal exploration was carried out first. It took approximately 1 h 30 min for tumor isolation and ligation of the right renal vessels. Blood loss before CPB was about 100 ml. Ascending aorta, superior vena cava, and intra-abdominal IVC distal to right renal vein were then cannulated after heparinization (400 IU/kg) and mild hypothermic CPB was initiated without aorta cross-clamping [Figure 2]. Further, hepatic venous blood was drained into CPB after the right atrium (RA) incision. Cell saver was used in view of massive blood loss. Tumor thrombus was found to be nonadherent to RA wall. Longitudinal cavotomy was performed, and tumor thrombus was removed en bloc from IVC and RA. The patient was uneventfully weaned from CPB with injection Noradrenaline (0.08 µg/kg/min). CPB time was 35 min with urine output of 30 ml. Blood loss was estimated to be 350 ml. Two units packed RBCs were given on CPB and 300 ml cell saver blood was also transfused during total operative time of 4 h 18 min. Postsurgery TOE [Figure 1d] showed IVC free from mass. The child was shifted to the Intensive Care Unit, and tracheal extubation was done on postoperative day 2. Histopathologically, tumor was involving renal vein without involvement of retroperitoneal lymph nodes and tumor thrombus extending from IVC to the right atrium with morphology similar to Wilm's tumor establishing stage IV Grade according to National Wilms'

Study Group.^[1] On microscopic examination, findings were consistent with WT showing predominant solid and few cystic areas with no necrosis and atypical mitosis.

Discussion

WT accounts for 95% of all renal malignancies in children younger than 15 years of age. Intravascular extension occurred in 4.5% and 6% of patients with National WT study.^[1,2] Majority of patients have limited extension to IVC with an atrial extension in only 1% of total cases.^[1] Reported risks of atrial extension are TV obstruction and pulmonary embolism necessitating aggressive surgical management of these tumors.^[3] Suspicion of TV obstruction was raised in our case since the occurrence of sudden onset shock and no flow across TV in preoperative TTE. Hence, urgent radical nephrectomy and removal of tumor extension were planned under CPB. Ultrasonographic evaluation of all major veins was done preinduction and for facilitating central venous access. Adequate vascular access was obtained as massive blood loss was expected during procedure requiring aggressive interventions. About 4%–8% of patients can have acquired von-Willebrand disease warranting screening for coagulation abnormalities. Our patient also had features of HV obstruction indicating Budd-Chiari syndrome-like state as an additional contributory factor for bleeding. We used cell saver for reducing the need for allogeneic blood transfusion although its use has been under question with active malignancy. In 2012, a meta-analysis with 10 controlled (not randomized) studies demonstrated no increase in cancer recurrence or development of metastasis compared with those receiving allogeneic blood.^[4] TOE is essential for monitoring in these high-risk cases. In our case, patent foramen ovale (PFO) was closed with no color flow from the left atrium to RA. Hence, tumor mass was removed

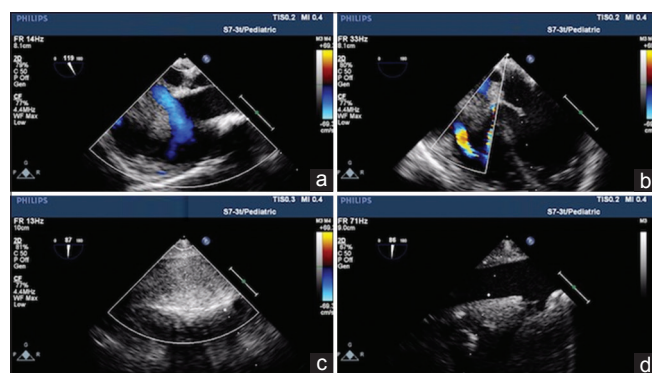


Figure 1: (a) Modified bicaval view showing mass protruding into right atrium measuring 3 cm × 2 cm with flow around the mass indicating that mass is nonadherent to the right atrium wall. (b) Midesophageal four-chamber view showing mass extending up to tricuspid valve with flow across it. (c) Inferior vena cava and hepatic vein were filled with mass measuring 2.5 cm. (d) Postoperatively, inferior vena cava free from mass

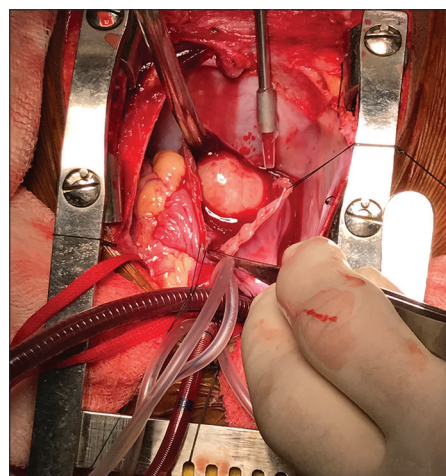


Figure 2: Tumor seen in the right atrium with venous and arterial cannulas *in situ*

without aortic cross-clamping. Otherwise, cross-clamping is sometimes necessary for closing the PFO and removing the tumor. TOE also demonstrated flow across the TV that was not detected on TTE. This finding gave a clue that mass was nonadherent to RA wall and perhaps to IVC also. This finding changed surgical approach in our patient as tumor was removed *en bloc* through the abdominal IVC.

Conclusion

- WT is common childhood renal tumor that often spreads to IVC and rarely up to RA
- TOE is helpful in managing and altering the plan of management in such complex tumor
- Close communication between anesthesiologists, cardiovascular surgeon, pediatric surgeons, and perfusionists is imperative for better outcome.

Declaration of patient consent

The authors certify that they have obtained all appropriate patient consent forms. In the form, the parent of patient has

given consent for his child's images reported in the journal. The parent of patient understood that his child's name and initials will not be published and due efforts will be made to conceal identity, but anonymity cannot be guaranteed.

Financial support and sponsorship

Nil.

Conflicts of interest

There are no conflicts of interest.

References

1. Shamberger RC, Ritchey ML, Haase GM, Bergemann TL, Loecheit-Yoshioka T, Breslow NE, *et al.* Intravascular extension of Wilms tumor. *Ann Surg* 2001;234:116-21.
2. Ritchey ML, Kelalis PP, Breslow N, Offord KP, Shochat SJ, D'Angio GJ, *et al.* Intracaval and atrial involvement with nephroblastoma: Review of National Wilms Tumor Study-3. *J Urol* 1988;140:1113-8.
3. Takeda K, Sawamura S, Tamai H. Reversible tricuspid valve obstruction during removal of renal cell carcinoma with intracardiac tumor extension. *Anesth Analg* 2000;91:1137-8.
4. Waters JH, Yazer M, Chen YF, Kloke J. Blood salvage and cancer surgery: A meta-analysis of available studies. *Transfusion* 2012;52:2167-73.