

High-Grade Intraventricular Astroblastoma in a Young Adult: A Rare and Controversial Tumor to Manage

Abstract

Astroblastoma is a rare primary central nervous system tumor of controversial site of origin. They account for 0.45-2.8% of all primary neuroepithelial central nervous system. It has been reported in paediatric age group with bimodal age distribution affecting more females with male to female ratio being 1:11. Astroblastomas are controversial and challenging tumors in terms of diagnosis and therapeutics. Since it carries an unpredictable disease course it needs a regular follow up even for low grade tumor. Authors have tried various schedules of post op radiotherapy after maximum safe resection. Various chemotherapeutic drugs combination have also been tried without much success. We here report a 35 years old female patient who was diagnosed with high grade astroblastoma referred for post-operative radiotherapy after gross total resection. Since it is extremely rare tumor, its treatment still not well defined and also makes it difficult conduct studies to examine tumor characteristics.

Keywords: *Adjuvant radiotherapy, astroblastoma, brain tumor, intraventricular tumor*

Introduction

Astroblastoma is an extremely rare and challenging neuroepithelial primary tumor of uncertain origin. It accounts for 0.45%–2.8% of all neuroglial tumors, and it is mainly located in the cerebral hemispheres, mainly occupying frontoparietal hemisphere, although other locations such as brainstem, cerebellum, hypothalamus, and intraventricular have also been documented.^[1] Astroblastoma shows a bimodal age incidence with cases being reported in young adults as well as older patients. It was initially described by Bailey and Cushing in 1926 as a separate glial tumor and further characterized by Bailey and Bucy in 1930. Controversies exist regarding its cellular origin; it shares features of both astrocytomas and ependymomas.^[2] It has been listed among “other neuroepithelial tumors” in the WHO classification of tumors of the central nervous system. The most recent revision describes astroblastoma as a high-grade (Grade 4) neuroepithelial tumor of unknown origin.^[3] They generally present with symptoms suggestive of raised intracranial tension, focal neurological deficits, and epileptic episodes. This tumor

is prone to misdiagnosis as it shares radiologic and histopathologic features with other glial tumors. The standard of care treatment is not well defined and hence represents a challenging tumor in terms of diagnosis, classification, and further treatment. Maximum safe resection is the treatment of choice as like for other primary brain malignancies. For high-grade lesions, adjuvant radiotherapy can be added for local control. Oncologists have tried cyclophosphamide-, cisplatin-, and etoposide-based regimens for these tumors. Treatment with vascular endothelial growth factor inhibitors in the form of bevacizumab has also been attempted without much success. Hence, the role of chemotherapy for this tumor is still not clear.^[4] Here, we present a case of high-grade astroblastoma in a 35-year-old female referred to us for postoperative adjuvant radiation therapy.

Case Report

A 35-year-old female presented to the outpatient department with the chief complaints of severe headache, recurrent episodes of projectile vomiting, and generalized weakness for 15 days. The patient had evidence of weak gag and

**Karuna Singh,
Shipra Garg¹,
Shilp Rani²,
Parvinder Sandhu³**

Department of Radiation oncology, ²Department of Pathology, ³Department of Surgical, Advanced Cancer Institute, Bathinda, ¹Department of Radiation Oncology, Guru Gobind Singh Medical College, Faridkot, Punjab, India

Address for correspondence:

*Dr. Karuna Singh
Department of Radiation oncology, Advanced Cancer Institute, Bathinda, Punjab, India. E-mail: karuna.mamc@gmail.com*

Access this article online

Website: www.asianjns.org

DOI: 10.4103/ajns.AJNS_430_20

Quick Response Code:



How to cite this article: Singh K, Garg S, Rani S, Sandhu P. High-grade intraventricular astroblastoma in a young adult: A rare and controversial tumor to manage. *Asian J Neurosurg* 2021;16:567-74.

Submitted: 13-Sep-2020

Revised: 09-Jan-2021

Accepted: 02-Mar-2021

Published: 14-Sep-2021

This is an open access journal, and articles are distributed under the terms of the Creative Commons Attribution-NonCommercial-ShareAlike 4.0 License, which allows others to remix, tweak, and build upon the work non-commercially, as long as appropriate credit is given and the new creations are licensed under the identical terms.

For reprints contact: WKHLRPMedknow_reprints@wolterskluwer.com

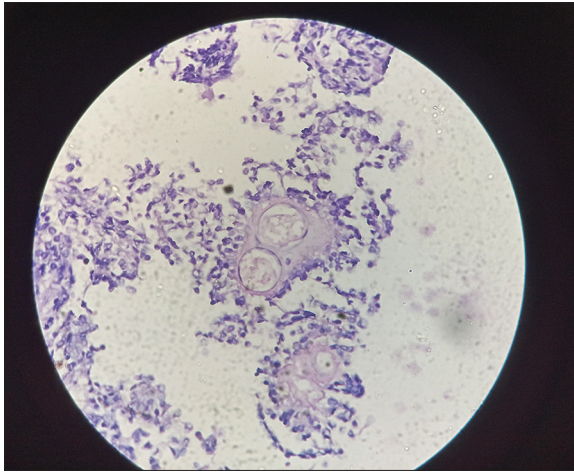


Figure 1: $\times 400$ Magnification showing tumor with vascular hyalinization

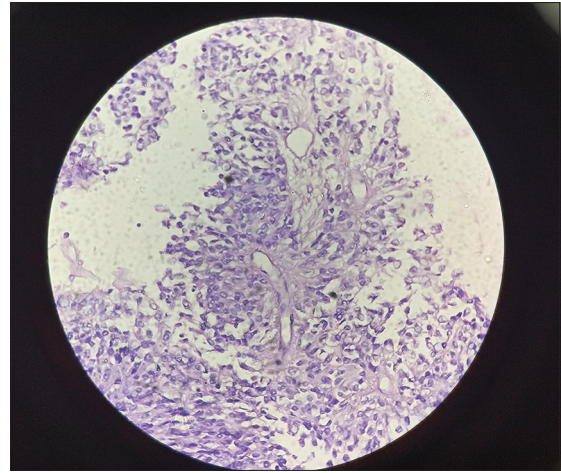


Figure 2: $\times 200$ Magnification showing tumor cells arranged in perivascular pseudorosettes with short and eosinophilic cytoplasmic processes

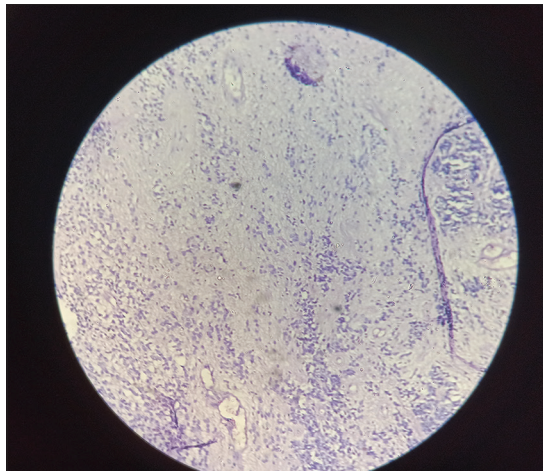


Figure 3: Glial tissue infiltrated by the tumor cells in $\times 100$

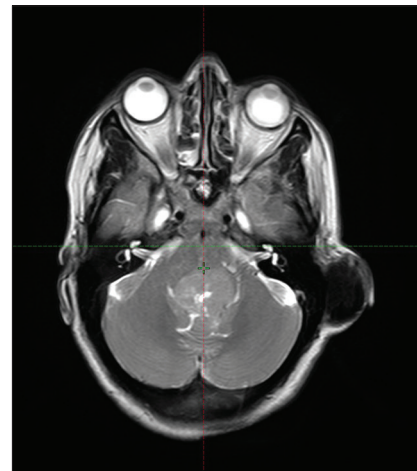


Figure 4: Magnetic resonance imaging T1 axial image showing the lesion of size 3.5 cm \times 3 cm \times 4.5 cm in the midline posterior fossa in relation to the fourth ventricle

swallowing. She also had an absent cough, and the patient was not able to expel out the excessive secretions, hence she underwent tracheostomy and started on nasogastric tube feeding.

She was clinically evaluated and advised to undergo magnetic resonance imaging (MRI) brain [Figures 1, 2 and 3] which revealed altered signal intensity lesion of size approximately 3.5 cm \times 3.0 cm \times 4.5 cm in the midline posterior fossa in relation to the fourth ventricle/vermis anteriorly indenting over the inferior part of the pons and cervicomedullary region with resultant mild proximal dilatation of the supratentorial ventricular system. Lesion was isointense to mildly hyperintense on fluid -attenuated inversion recovery diffusion-weighted imaging (FLAIR) and T2 images. It was isointense to slightly hypointense on T1W1 images. Inferiorly the lesion was extending till cervicomedullary region with concern raised for neoplastic etiology.

The patient underwent a midline suboccipital craniotomy and tumor decompression with placement of ventriculoperitoneal shunt within 15 days of presentation.

Cerebrospinal fluid culture was also done with no growth. Postoperative histopathology [Figures 4, 5 and 6] revealed tumor cells arranged in perivascular pseudorosettes with short and thick eosinophilic cytoplasmic processes extending toward vessel wall. Vascular hyalinization and perivascular sclerosis were also noted. Individual tumor cells were round, oval to epithelioid, pleomorphic, hyperchromatic with high N:C ratio, coarse chromatin, and eosinophilic cytoplasm. Mitotic figures noted 2/10 hpf. Area of fibrillarity, hemorrhage calcification, and congested hyalinized vessels were noted. On immunohistochemistry, tumor cells were positive for glial fibrillary acidic protein (GFAP). The histopathological features were suggestive of high-grade astroblastoma.

Postoperative noncontrast computed tomography brain showed postoperative changes with extra-axial subdural pneumocephalus along the vermis and bilateral cerebellar convexity with mass effect in the form of compression of the vermis and bilateral cerebellum, brainstem, and fourth

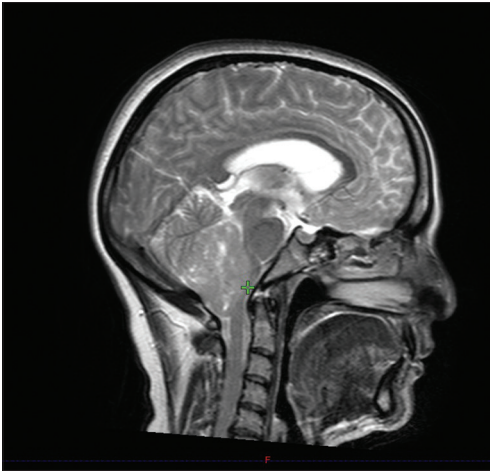


Figure 5: Sagittal magnetic resonance imaging image showing the craniocaudal extent of the tumor up to the cervicomedullary region

ventricle with draining shunt extending from the fourth and third ventricles with mass effect in the form of compression of the fourth ventricle and cisternal effacement.

The postoperative patient was referred to the radiation oncology department for radiotherapy. We had planned for 60 Gy in 30 fractions for a period of 6 weeks at 2 Gy per fraction.

Discussion

Astroblastoma is an extremely rare and uncommon glial tumor encountered in routine clinical practice. It is predominantly observed in cerebral hemispheres (significantly in the frontal lobe, parietal lobe, and temporal lobe) of young adults but also affects other sites such as brainstem, cerebellum, optic nerve, cauda equina, and hypothalamus.^[5] It accounts for approximately 0.45%–2.8% of all neurological tumors.^[6] It can occur at any age and has been reported during childhood period (5–10 years) and in young adults (21–30 years). Females being diagnosed more with male-to-female ratio reported to be 1:11.^[7] The mechanism of tumorigenesis is still not well defined. It is a unique tumor and shares features of both astrocytoma and ependymoma. Since Bailey and Bucy reported the condition for the first time in 1930, this tumor has been reported sporadically in the literature. Astroblastoma is associated with variable outcomes and is a highly debatable entity. Brain tanycytes are believed to the source of origin of these tumors. Tanycytes are involved in neuropeptide transport. Tanycytes have resemblance with some rare brain tumors such as subependymoma and astroblastoma. These tumors are sometimes referred to as tanycytomas.^[8]

Histologically, spindle-shaped cells with short, broad tapering processes are arranged in a perivascular pattern forming pseudo rosettes, reminiscent of ependymomas.^[9] These tumors stain positive for vimentin and S-100, which are more characteristic of astrocytic origin.^[2,10]

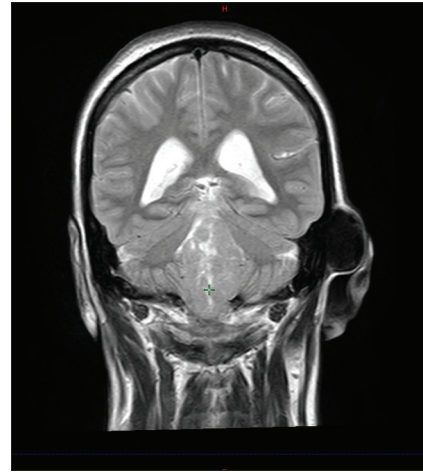


Figure 6: Magnetic resonance imaging T2 coronal image showing iso- to hyperintense tumor with proximal dilatation of the supratentorial ventricular system

Astroblastomas are also GFAP, epithelial membrane antigen, cytokeratin, and Olig2 positive and negative for isocitrate dehydrogenase (IDH) and TP53 mutations. Differentiation into low grade and high grade is based on the features such as mitotic rate and degree of cellular atypia and necrosis. There is existence of two distinct zones.^[11] The first zone comprises cells around blood vessels with extensive sclerosis (astroblastoma pseudo rosettes). These cells are GFAP and S-100 positive and demonstrate a low Ki-67 index. The second zone is highly cellular with distinctly fewer rosettes and contains noncohesive cells depicting a more rhabdoid appearance. This is positive for S-100 and negative for GFAP and has a higher KI-67 index. The second zone confers a higher grade to the diagnosis.

Brat *et al.* have demonstrated some data on its molecular genetics of astroblastoma. They exhibit chromosomal aberrations in the form of gain of chromosomes 19 and 20.^[12] Other alterations such as losses on 9q, 10 and X chromosome have also been observed. Shuangshoti found loss of heterozygosity at the D19S412 locus on 19q in a cerebral astroblastoma.^[13] More recently, an absence of IDH^{1/2} and TP53 mutations, which are known to be involved in the development of low-grade gliomas, was shown in astroblastoma.^[11]

Imaging finding can offer help in the diagnosis and prognosis. Astroblastomas often demonstrate T1 and T2 prolongation relative to white matter, with well-circumscribed boundaries and heterogeneous contrast enhancement. The enhancement characteristics can set it apart from meningiomas, which tend to exhibit a homogenous enhancement. Their characteristic supratentorial location also helps set them apart from ependymomas which usually involve the posterior fossa. Calcifications are consistent imaging finding and would be unusual for glioblastoma multiformes (GBMs) and Atypical teratoid and rhabdoid tumors (ATRTs).

Table 1: The various case reports presented till date

Reference	Gender male/female	Age	Symptoms	Radiology/location	Surgery	Radiotherapy	Chemotherapy	Grade
de Reuck <i>et al.</i> , 1975 ^[19]	1	61	Cognitive disturbance	Solid/frontal	-	-	-	Low
Husain and Leestma, 1986 ^[20]	1	3	Seizures, hemiparesis	Solid/frontal	-	-	Vincristine Methotrexate	Low
Bonnin and Rubinstein, 1989 ^[21]	10/13	5-58 mean 21.2	Headache Vomiting Hemiparesis Seizures	Solid cystic/17 lobar 2 pineal 1 suprasellar 1 subcortical 1 cerebellar 1 fourth ventricle	12 total 11 subtotal	11 patients	5 patients	13 low 8 high 2 intermediate
Pizer <i>et al.</i> , 1995 ^[14]	1	17 days	Irritability Vomiting	Solid cystic/frontal	Subtotal		Vincristine Etoposide	Low
Thiessen <i>et al.</i> , 1998 ^[22]	1/6	1.2-51 Mean 12.67	Headache Hemiparesis Seizures	3 frontal 3 parietal 1 temporal	4 total 3 subtotal	3 patients 5940 cGy		3 low 4 high
Brat <i>et al.</i> , 2000 ^[12]	4/16	3-46 mean 14	Headache Seizures Vomiting	Solid cystic/9 frontal 7 parietal 2 temporal 1 occipital 1 midbrain	18 total 2 subtotal	10 patients 38 Gy-72 Gy Mean 52.5		10 LG 10 HG
Port <i>et al.</i> , 2002 ^[2]	1/5	3-46 mean 20.5	Headache Vomiting Motor deficit	Solid cystic/3 frontal 1 temporal 1 parieto-occipital 1 corpus callosum	5 total 1 subtotal	3 patients 5400 cGy		3 LG 3 HG
Sugita <i>et al.</i> , 2002 ^[23]	1	33	Seizures	Frontal	Total			LG
Catalán-Uribarrena <i>et al.</i> , 2002 ^[24]	1	17	Headache Seizures	Solid cystic/frontal	Total			LG
Kim <i>et al.</i> , 2004 ^[25]	1	7	Headache Seizures	Solid/brainstem	Total	Yes		LG
Kim <i>et al.</i> , 2004 ^[26]	1	15	Headache Diplopia	Solid cystic/frontal	Total	4500 cGy		HG
Caroli <i>et al.</i> , 2004 ^[27]	1	30	Coma	Solid/temporal	Total	Yes		HG
Navarro <i>et al.</i> , 2005 ^[28]	3/5	1.8-14.5 mean 7	Headache Vomiting Seizures	4 solid 4 cystic/4 frontal 1 parietal 1 temporal 1 third ventricle 1 fourth ventricle	6 total 2 subtotal	6 patients	5 patients	4 LG 4 HG
Kaji <i>et al.</i> , 2006 ^[29]	1	17	Headache Hemiparesis	Solid/frontal	Total	60 Gy	Etoposide Vincristine	HG
Kubota <i>et al.</i> , 2006 ^[30]	1	8	Headache	Hemorrhagic solid cystic/frontal	Total	40 Gy		HG
Miranda <i>et al.</i> , 2006 ^[31]	1	43	Headache Seizures	Solid/frontal	Total			LG
Lau <i>et al.</i> , 2006 ^[32]	1	21	Headache	Solid cystic/parietal	Total			LG
Hata <i>et al.</i> , 2006 ^[33]	1	16	Headache	Cystic/parietal	Total			LG

Contd...

Table 1: Contd...

Reference	Gender male/female	Age	Symptoms	Radiology/location	Surgery	Radiotherapy	Chemotherapy	Grade
Alaraj <i>et al.</i> , 2007 ^[34]	1	33	Headache Nausea	Hemorrhagic Solid/temporal	Total	54 Gy		LG
Tumialán <i>et al.</i> , 2007 ^[35]	1	33	Headache Nausea	Hemorrhagic solid/ frontal	Subtotal	36 GyLg		
Bell <i>et al.</i> , 2007 ^[10]	1/11	0-50 mean 20	Headache Seizures	9 solid cystic 2 solid 4 frontal 5 parietal 3 extra-axial 1 temporal 2 intraventricular	7 total 4 subtotal	2 patients	1 patient	
Fathi <i>et al.</i> , 2008 ^[36]	1	53	Headache Vomiting	Solid cystic/parietal	Total	66 Gy	Temozolomide	HG
Denaro <i>et al.</i> , 2008 ^[37]	1	6	Headache Seizures	Solid cystic/ intraventricular	Total			LG
Eom <i>et al.</i> , 2008 ^[38]	1	20	Headache	Solid cystic/temporal	Total			LG
Unal <i>et al.</i> , 2008 ^[39]	1	4	Hemiparesis	Solid cystic/ frontoparietal	Total	54 Gy	Cisplatin Etoposide	HG
Ganapathy <i>et al.</i> , 2009 ^[15]	1	12	Headache Vomiting	Solid/intraventricular	Total	Yes		LG
Notarianni <i>et al.</i> , 2008 ^[9]	1	20	Diplopia Ataxia	Cystic/brainstem	Total			LG
Kantar <i>et al.</i> , 2009 ^[40]	1	7	Headache Ataxia	Solid cystic/parietal	Subtotal	59.4 Gy	Cisplatin Etoposide Vincristine	HG
Kemerdere <i>et al.</i> , 2009 ^[41]	2	6-7 mean 6.5	Headache Vomiting Seizures Motor deficit	Solid cystic/1 frontoparietal 1 parietal	2 total			2 HG
Salvati <i>et al.</i> , 2009 ^[4]	2/4	27-50 mean 37	Headache Vomiting Motor deficit	Solid cystic/2 frontal 2 occipital 2 temporal	4 total 2 subtotal	60 Gy	2 temozolomide	3 LG 3 HG
Mastrangelo <i>et al.</i> , 2010 ^[42]	2	12-21	Headache Vomiting Seizures	Solid/1 frontoparietal 1 temporal	1 total 1 subtotal	Yes		HG
Bergkasa <i>et al.</i> , 2011 ^[43]	1	50	Seizures	Solid/frontal	Total	54 Gy	Procarbazine CCNU Vincristine	HG
Bhattacharjee <i>et al.</i> , 2011 ^[44]	1	4	Headache	Solid cystic/ parieto-occipital	Total			HG
Agarwal <i>et al.</i> , 2012 ^[5]	1	12	Headache Diplopia	Solid/parietal	Total			LG
Khosla <i>et al.</i> , 2012 ^[45]	1	11	Headache Vomiting	Solid cystic/ frontoparietal	Total	Yes		HG
Nasit and Trivedi 2013 ^[46]	1	10	Headache Seizures	Solid cystic/frontal parietal	Total			LG

Contd...

Table 1: Contd...

Reference	Gender male/female	Age	Symptoms	Radiology/location	Surgery	Radiotherapy	Chemotherapy	Grade
De la Garma <i>et al.</i> , 2014 ^[47]	1	9	Headache Nausea Vomiting Hemiparesis Seizures Aphasia	Cystic solid/ frontoparietal	Total			HG
Janz and Buhl, 2014 ^[16]	2	16-24	Headache Vomiting Seizures	Solid cystic/1 parieto-occipital 1 temporal	2 total	1 yes		LG LG
Singh <i>et al.</i> , 2014 ^[48]	1	12	Seizures	Solid cystic	Total	Yes		LG
Yao <i>et al.</i> , 2015 ^[49]	1	36	Headache Nausea Vomiting	Occipitotemporal	Subtotal			LG
Narayan <i>et al.</i> , 2015 ^[50]	1	16	Headache Vomiting	Solid cystic/ temporo-occipital	Total	No		LG
Barakat <i>et al.</i> , 2016 ^[6]	1	40	Headache Vomiting Confusion	Solid cystic/frontal	Total			
Singla <i>et al.</i> , 2016 ^[51]	1/1	11-30	Headache Weakness Seizures	Solid cystic/frontal and frontoparietal	Total Subtotal			1 LG 1 HG
Yuzawa <i>et al.</i> , 2016 ^[52]	1	18	Headache Nausea Numbness	Solid cystic	Total			LG
Yeo <i>et al.</i> , 2016 ^[53]	1	35	Numbness Weakness	Solid/lateral ventricle	Total			LG
Samples <i>et al.</i> , 2016 ^[54]	1	30	Headache Vision acuity	Solid cystic/ temporoparietal	Subtotal			LG
Hammas <i>et al.</i> , 2018 ^[7]	1	8	Seizures Headache Vision acuity	Solid cystic/ occipitotemporal	Subtotal			LG

CCNU - 1-(2-chloroethyl)-3-cyclohexyl-1-nitrosourea; LG - Low grade; HG - High grade

Astroblastoma tends to be peripherally oriented and may involve from the ventricular system.^[14] In these instances, additional imaging of neural axis should be considered to rule out drop metastasis.^[15] Although rim enhancement seen around its cystic components may resemble that of a necrotic GBM, astroblastomas usually have a minimal peritumoral white matter T2 prolongation. Janz and Buhl refer the extent of peritumoral edema as carrying an unfavorable radiological feature that suggested early recurrence or progression in astroblastoma, even when if pathology is consistent with low grade. The authors showed a recurrence rate of 23.5% in high grade and 60% in low grade.^[16]

In a review of 85 patients by Sughrue *et al.*, those undergoing gross total resection (GTR) experienced improved survival

compared to those undergoing subtotal resection with 85% survival at 5 years in the GTR group versus 55% in the subtotal resection group.^[17] Mangano *et al.* analyzed outcomes and treatment strategies in low- and high-grade astroblastomas: among the patients with high-grade tumors, those who received surgery and radiotherapy had the highest survival rate.^[18] Table 1 summarizes the various case report and literature since 1975.

Features suggestive of high-grade/malignant lesions include the extent of peritumoral T2 signal on MRI, cytological atypia, high Ki-67 index, tumor necrosis, increased cellularity, and vascular proliferation.^[11,32] These prognostic factors are not always applicable. Janz and Buhl present a case in which there was an early recurrence of a low-grade

variant that required postoperative radiotherapy with no further recurrence.^[16] Lau *et al.* and Yao *et al.* described a low-grade astroblastoma treated with GTR that recurred at 12 and 20 months requiring another surgery followed by postoperative radiotherapy.^[32,49] Dereck *et al.* have demonstrated a case of low grade astroblastoma showing signs of recurrence with leptomeningeal spread and in that case radiotherapy was delivered.

Optimal treatment modality for astroblastomas is not clear since it being a rare tumor. GTR is the best treatment offered to the patients whenever possible since it provides excellent tumor control rates and subtotal resection should be avoided.^[17,38] Addition of post operative adjuvant focal radiotherapy after subtotal resection does not compensate for gross tumor resection and hence gross tumor resection is the standard as far as safely achievable. Adjuvant therapy for high-grade and recurrent cases is recommended.^[17] The authors have tried various chemotherapeutic drugs in the form of temozolomide, cisplatin, etoposide, cyclophosphamide, and bevacizumab without much success. Regular follow-up is necessary even in low-grade variants due to unpredictable disease course. Well-circumscribed tumors which have undergone total resection carry a favorable prognosis. Ahmed *et al.* have published the largest series of 239 patients and concluded that supratentorial location, age >60 years at diagnosis, and treatment before 1990 were correlated with decreased survival.^[55]

Conclusion

Astroblastoma is an extremely rare primary brain neoplasm. Since it shares features with other brain tumors, the diagnosis is often challenging. Its histogenesis is still not clear and confusion persists regarding its classification among other brain tumors. Because of its rarity of occurrence, it is difficult to conduct studies to explore its tumor characteristics. The treatment is variable without any standardization. Although the surgical resection in terms of GTR is recommended, there is variable use of postoperative adjuvant radiotherapy and chemotherapy. It has an unpredictable biological course with an increased risk of recurrence and rapid progression. Case reports like this help disseminate knowledge on uncommon tumors with insights on diagnostic and treatment challenges.

Declaration of patient consent

The authors certify that they have obtained all appropriate patient consent forms. In the form the patient(s) has/have given his/her/their consent for his/her/their images and other clinical information to be reported in the journal. The patients understand that their names and initials will not be published and due efforts will be made to conceal their identity, but anonymity cannot be guaranteed.

Financial support and sponsorship

Nil.

Conflicts of interest

There are no conflicts of interest.

References

- Bailey P, Bucy PC. Astroblastomas of the brain. *Acta Psychiatr Neurol* 1930;5:439-61.
- Port JD, Brat DJ, Burger PC, Pomper MG. Astroblastoma: Radiologic-pathologic correlation and distinction from ependymoma. *AJNR Am J Neuroradiol* 2002;23:243-7.
- Sadiq M, Ahmad I, Shuja J, Ahmad Z, Ahmed R, Ahmad K. Astroblastoma in a young female patient: A case report and literature review of clinicopathological, radiological and prognostic characteristics and current treatment strategies. *Brain Tumor Res Treat* 2017;5:120-6.
- Salvati M, D'Elia A, Brogna C, Frati A, Antonelli M, Giangaspero F, *et al.* Cerebral astroblastoma: Analysis of six cases and critical review of treatment options. *J Neurooncol* 2009;93:369-78.
- Agarwal V, Mally R, Palande DA, Velho V. Cerebral astroblastoma: A case report and review of literature. *Asian J Neurosurg* 2012;7:98-100.
- Barakat MI, Ammar MG, Salama HM, Abuhashem S. Astroblastoma: Case report and review of literature. *Turk Neurosurg* 2016;26:790-4.
- Hammam N, Senhaji N, Alaoui Lamrani MY, Bennis S, Chaoui EM, El Fatemi H, *et al.* Astroblastoma – A rare and challenging tumor: A case report and review of the literature. *J Med Case Rep* 2018;12:102.
- Lieberman KA, Wasenko JJ, Schelper R, Swarnkar A, Chang JK, Rodziewicz GS. Tanycytomas: A newly characterized hypothalamic-suprasellar and ventricular tumor. *AJNR Am J Neuroradiol* 2003;24:1999-2004.
- Notarianni C, Akin M, Fowler M, Nanda A. Brainstem astroblastoma: A case report and review of the literature. *Surg Neurol* 2008;69:201-5.
- Bell JW, Osborn AG, Salzman KL, Blaser SI, Jones BV, Chin SS. Neuroradiologic characteristics of astroblastoma. *Neuroradiology* 2007;49:203-9.
- Fu YJ, Taniguchi Y, Takeuchi S, Shiga A, Okamoto K, Hirato J, *et al.* Cerebral astroblastoma in an adult: An immunohistochemical, ultrastructural and genetic study. *Neuropathology* 2013;33:312-9.
- Brat DJ, Hirose Y, Cohen KJ, Feuerstein BG, Burger PC. Astroblastoma: Clinicopathologic features and chromosomal abnormalities defined by comparative genomic hybridization. *Brain Pathol* 2000;10:342-52.
- Shuangshoti S, Mitphraphan W, Kanvisetsri S, Griffiths L, Navalitloha Y, Pornthanakasem W, *et al.* Astroblastoma: Report of a case with microsatellite analysis. *Neuropathology* 2000;20:228-32.
- Pizer BL, Moss T, Oakhill A, Webb D, Coakham HB. Congenital astroblastoma: An immunohistochemical study. Case report. *J Neurosurg* 1995;83:550-5.
- Ganapathy S, Kleiner LI, Mirkin DL, Broxson E. Unusual manifestations of astroblastoma: A radiologic-pathologic analysis. *Pediatr Radiol* 2009;39:168-71.
- Janz C, Buhl R. Astroblastoma: Report of two cases with unexpected clinical behavior and review of the literature. *Clin Neurol Neurosurg* 2014;125:114-24.

17. Sughrue ME, Choi J, Rutkowski MJ, Aranda D, Kane AJ, Barani IJ, *et al.* Clinical features and post-surgical outcome of patients with astroblastoma. *J Clin Neurosci* 2011;18:750-4.
18. Mangano FT, Bradford AC, Mittler MA, Valderrama E, Schneider SJ. Astroblastoma: Case report, review of the literature, and analysis of treatment strategies. *J Neurosurg Sci* 2007;51:21-7.
19. de Reuck J, van de Velde E, vander Eecken H. The angioarchitecture of the astroblastoma. *Clin Neurol Neurosurg* 1975;78:89-98.
20. Husain AN, Leestma JE. Cerebral astroblastoma: Immunohistochemical and ultrastructural features. Case report. *J Neurosurg* 1986;64:657-61.
21. Bonnin JM, Rubinstein LJ. Astroblastomas: A pathological study of 23 tumors, with a post operative follow up in 13 patients. *Neurosurgery* 1989;25:6-13.
22. Thiessen B, Finlay J, Kulkarni R, Rosenblum MK. Astroblastoma: Does histology predict biologic behavior? *J Neurooncol* 1998;40:59-65.
23. Sugita Y, Terasaki M, Shigemori M, Morimatsu M, Honda E, Oshima Y. Astroblastoma with unusual signet-ring-like cell components: A case report and literature review. *Neuropathology* 2002;22:200-5.
24. Catalán-Uribarrena G, de Las Heras-Echeverría P, Catón-Santaren B, Martínez-Soto LJ, Torrecilla-Sardón MV, Ramos-González A. Cerebral astroblastoma: Report of a case and literature review. *Neurocirugía (Astur)* 2002;13:378-84.
25. Kim BS, Kothbauer K, Jallo G. Brainstem astroblastoma. *Pediatr Neurosurg* 2004;40:145-6.
26. Kim DS, Park SY, Lee SP. Astroblastoma: A case report. *J Korean Med Sci* 2004;19:772-6.
27. Caroli E, Salvati M, Esposito V, Orlando ER, Giangaspero F. Cerebral astroblastoma. *Acta Neurochir (Wien)* 2004;146:629-33.
28. Navarro R, Reitman AJ, de León GA, Goldman S, Marymont M, Tomita T. Astroblastoma in childhood: Pathological and clinical analysis. *Childs Nerv Syst* 2005;21:211-20.
29. Kaji M, Takeshima H, Nakazato Y, Kuratsu J. Low-grade astroblastoma recurring with extensive invasion. *Neurol Med Chir (Tokyo)* 2006;46:450-4.
30. Kubota T, Sato K, Arishima H, Takeuchi H, Kitai R, Nakagawa T. Astroblastoma: Immunohistochemical and ultrastructural study of distinctive epithelial and probable tanycytic differentiation. *Neuropathology* 2006;26:72-81.
31. Miranda P, Lobato RD, Cabello A, Gómez PA, Martínez de Aragón A. Complete surgical resection of high-grade astroblastoma with long time survival: Case report and review of the literature. *Neurocirugía (Astur)* 2006;17:60-3.
32. Lau PP, Thomas TM, Lui PC, Khin AT. 'Low-grade' astroblastoma with rapid recurrence: A case report. *Pathology* 2006;38:78-80.
33. Hata N, Shono T, Yoshimoto K, Mizoguchi M, Kawamura T, Nagata S, *et al.* An astroblastoma case associated with loss of heterozygosity on chromosome 9p. *J Neurooncol* 2006;80:69-73.
34. Alaraj A, Chan M, Oh S, Michals E, Valyi-Nagy T, Hersonsky T. Astroblastoma presenting with intracerebral hemorrhage misdiagnosed as dural arteriovenous fistula: Review of a rare entity. *Surg Neurol* 2007;67:308-13.
35. Tumulán LM, Brat DJ, Fountain AJ, Barrow DL. An astroblastoma mimicking a cavernous malformation: Case report. *Neurosurgery* 2007;60:E569-70.
36. Fathi AR, Novoa E, El-Koussy M, Kappeler A, Mariani L, Vajtai I. Astroblastoma with rhabdoid features and favorable long-term outcome: Report of a case with a 12-year follow-up. *Pathol Res Pract* 2008;204:345-51.
37. Denaro L, Gardiman M, Calderone M, Rossetto M, Ciccarino P, Giangaspero F, *et al.* Intraventricular astroblastoma. Case report. *J Neurosurg Pediatr* 2008;1:152-5.
38. Eom KS, Kim JM, Kim TY. A cerebral astroblastoma mimicking an extra-axial neoplasm. *J Korean Neurosurg Soc* 2008;43:205-8.
39. Unal E, Koksall Y, Vajtai I, Toy H, Kocaogullar Y, Paksoy Y. Astroblastoma in a child. *Childs Nerv Syst* 2008;24:165-8.
40. Kantar M, Ertan Y, Turhan T, Kitis O, Anacak Y, Akalin T, *et al.* Anaplastic astroblastoma of childhood: Aggressive behavior. *Childs Nerv Syst* 2009;25:1125-9.
41. Kemerdere R, Dashti R, Ulu MO, Biçeroğlu H, Demiröz AS, Albayram S, *et al.* Supratentorial high grade astroblastoma: Report of two cases and review of the literature. *Turk Neurosurg* 2009;19:149-52.
42. Mastrangelo S, Lauriola L, Coccia P, Puma N, Massimi L, Riccardi R. Two cases of pediatric high-grade astroblastoma with different clinical behavior. *Tumori* 2010;96:160-3.
43. Bergkasa M, Sundstrom S, Gulati S, Torp SH. Astroblastoma – A case report of a rare neuroepithelial tumor with complete remission after chemotherapy. *Clin Neuropathol* 2011;30:301-6.
44. Bhattacharjee S, Pulligopu AK, Uppin MS, Sundaram C. Astroblastoma with bone invasion. *Asian J Neurosurg* 2011;6:113-5.
45. Khosla D, Yadav BS, Kumar R, Agrawal P, Kakkar N, Patel FD, *et al.* Pediatric astroblastoma: A rare case with a review of the literature. *Pediatr Neurosurg* 2012;48:122-5.
46. Nasit JG, Trivedi P. Recurrent low-grade astroblastoma with signet ring-like cells and high proliferative index. *Fetal Pediatr Pathol* 2013;32:284-92.
47. de la Garma VH, Arcipreste AA, Vázquez FP, Aguilar RR, Castruita UO, Guerra RM. High-grade astroblastoma in a child: Report of one case and review of literature. *Surg Neurol Int* 2014;5:111.
48. Singh DK, Singh N, Singh R, Husain N. Cerebral astroblastoma: A radiopathological diagnosis. *J Pediatr Neurosci* 2014;9:45-7.
49. Yao K, Wu B, Xi M, Duan Z, Wang J, Qi X. Distant dissemination of mixed low-grade astroblastoma-arteriovenous malformation after initial operation: A case report. *Int J Clin Exp Pathol* 2015;8:7450-6.
50. Narayan S, Kapoor A, Singhal MK, Jakhar SL, Bagri PK, Rajput PS, *et al.* Astroblastoma of cerebrum: A rare case report and review of literature. *J Cancer Res Ther* 2015;11:667.
51. Singla N, Dhandapani SS, Kapoor A, Chatterjee D, Vashishta RK. Hemorrhage in astroblastoma: An unusual manifestation of an extremely rare entity. *J Clin Neurosci* 2016;25:147-50.
52. Yuzawa S, Nishihara H, Tanino M, Kimura T, Moriya J, Kamoshima Y, *et al.* A case of cerebral astroblastoma with rhabdoid features: A cytological, histological, and immunohistochemical study. *Brain Tumor Pathol* 2016;33:63-70.
53. Yeo JJ, Low YY, Putti TC, Koh KM. Adult intraventricular astroblastoma. *Singapore Med J* 2016;57:53-4.
54. Samples DC, Henry J, Yu FF, Bazan C, Tarasiewicz I. A case of astroblastoma: Radiological and histopathological characteristics and a review of current treatment options. *Surg Neurol Int* 2016;7:S1008-12.
55. Ahmed KA, Allen PK, Mahajan A, Brown PD, Ghia AJ. Astroblastomas: A Surveillance, Epidemiology, and End Results (SEER)-based patterns of care analysis. *World Neurosurg* 2014;82:e291-7.