

Canal Straightening Following Overinstrumentation with Three Nickel-Titanium Rotary Instruments

Salwa Yammine¹, Edgard Jabbour¹, Franck Diemer², Zeina Majzoub³

¹Department of Endodontics, Faculty of Dental Medicine, Lebanese University, Hadath, Beirut, Lebanon, ²Université Paul Sabatier, Institut Clément Ader, CHU de Toulouse, France, ³Department of Periodontology, Faculty of Dental Medicine, Lebanese University, Hadath, Beirut, Lebanon

Received : 11-01-18.

Accepted : 30-01-18.

Published : 17-05-18.

INTRODUCTION

The chemomechanical preparation is an essential step in root canal treatment. Root canal preparation should achieve a conical shape from the apex to the coronal portion, preserve the apical foramen in its original shape and position, and maintain the canal curvature.^[1] Cleaning and shaping should, therefore, keep the final canal form superimposed to the original one but with a wider diameter.^[1] Difficulties arise during the shaping of curved canals which tend to deviate from their original axis.^[2,3] This can be worsened with the use of manual or rotary instruments with insufficient flexibility or the uncontrolled use of rotary instruments.^[4] Rotary

ABSTRACT

Aim: The aim of the present *in vitro* study to compare canal straightening following shaping of curved canals with three types of new generation nickel-titanium (NiTi) rotary instruments-ProTaper Next (PTN)[®], BT RaCe (BTR)[®], and WaveOne Gold (WOG)[®]- and three different levels of protrusion beyond the major apical foramen.

Materials and Methods: Forty-five extracted human maxillary and mandibular molars with at least one curved canal were distributed in three comparable groups of 15 canals each. The canals were instrumented to the major foramen and then overinstrumented with the final file 0.5 mm, 1 mm, and 1.5 mm beyond the foramen using PTN (Group PTN = 15), BTR (Group BTR = 15), and WOG (Group WOG = 15). Standardized pre- and post-instrumentation radiographs of the root canal were obtained for all groups using digital intraoral radiographs coupled with software. Differences in the degree of curvature were regarded as straightening and canal curvature was evaluated based on Schneider technique using the AmScope software for measurements and compared between groups and levels of instrumentation applying Mixed-model ANOVA. Significance was set at 0.05.

Results: Canal curvature tended to gradually straighten out as the level of instrumentation increased in all three groups without statistically significant difference among the groups ($P = 0.826$).

Conclusion: Overinstrumentation in curved canals resulted in straightening of the canal curvature.

KEYWORDS: Canal straightening, curved canals, nickel-titanium rotary instruments, overinstrumentation

nickel-titanium (NiTi) instruments with improved cutting efficiency, rotational resistance, and flexibility have been reported to result in better-centered preparations of curved root canals.^[5,6] The newer fifth generation of NiTi rotary systems, including ProTaper Next[®] (PTN Dentsply Maillefer, Ballaigues, Switzerland), BT Race[®] (BTR FKG, La Chaux-de-Fonds, Switzerland), and WaveOne Gold[®] (WOG Dentsply Maillefer, Ballaigues,

Address for correspondence: Dr. Salwa Yammine, Department of Endodontics, Lebanese University, Faculty of Dental Medicine, Rafic Hariri Campus, P.O. Box 4, Hadath, Beirut, Lebanon.
E-mail: salwa.yammine@hotmail.com

Access this article online

Quick Response Code:



Website: www.jispcd.org

DOI: 10.4103/jispcd.JISPCD_18_18

This is an open access article distributed under the terms of the Creative Commons Attribution-NonCommercial-ShareAlike 3.0 License, which allows others to remix, tweak, and build upon the work non-commercially, as long as the author is credited and the new creations are licensed under the identical terms.

For reprints contact: reprints@medknow.com

How to cite this article: Yammine S, Jabbour E, Diemer F, Majzoub Z. Canal straightening following overinstrumentation with three nickel-titanium rotary instruments. J Int Soc Prevent Communit Dent 2018;8:245-51.

Switzerland), has increased flexibility and improved resistance to cyclic fatigue.^[7-9] PTN[®] instruments manufactured from M-wire alloy have an innovative off-centered rectangular cross section that allows a snake-like continuous movement as they advance in the canal.^[10] The WOG[®] reciprocating file was developed as a single-file technique with post-manufacturing gold process in which the ground NiTi file is heat-treated and slowly cooled. The reciprocation motion of this file system consists of a counterclockwise cutting motion and a clockwise release with the angle of the counterclockwise cutting direction being greater than the angle of the reverse direction.^[6] A glide path with ProGlider[®] file (Dentsply Maillefer) is recommended according to manufacturer's guidelines for the use of PTN[®] and WOG[®] instruments. The BTR[®] consists of single-use files working in continuous rotation with 3 sequences: BT1 (10 taper 0.06), BT2 (35 taper 0.00), BT3 (35 taper 0.04). A glide path should also be performed with small stainless steel or NiTi files up to ISO 15 K-file before using the BTR sequence as per manufacturer's recommendations.

The limits of instrumentation and obturation of the root canal system have been subject to controversies.^[11,12] While some authors proposed that instrumentation should end at the apical constriction if present,^[11,13] others suggested that it should be set at the radiographic apex^[1] or 0.5–1 mm coronally to it.^[2,14,15] Intentional overinstrumentation extending the length of instrumentation to or beyond the foramen has been proposed for efficient disinfection in cases of apical periodontitis.^[16,17] Unintentional overinstrumentation is commonly observed during endodontic procedures even when electronic apex locators are used^[18,19] and specially in curved canals.^[20] Whether overinstrumentation is intentional or unintentional, it does result in apical transportation.^[21,22]

Canal straightening defined as the difference between canal curvature before and after instrumentation^[6] is a universal finding following instrumentation of curved root canals with various NiTi rotary instruments including the new generation systems such as PTN[®] and BTR[®].^[20,23,24] To the best of our knowledge, there is no information related to the shaping ability and amount of canal straightening following overinstrumentation with the fifth generation of NiTi rotary instruments. The aim of the present *in vitro* study was to compare canal straightening following overinstrumentation with 3 NiTi rotary instruments-PTN[®], BTR[®], and WOG[®]-in curved canals with the instruments protruding at different levels beyond the major foramen. The null hypothesis tested was that there is no significant difference in canal straightening among the three above-mentioned systems.

MATERIALS AND METHODS

SAMPLE SELECTION AND PREPARATION

Forty-five extracted human maxillary and mandibular molars were selected for this preliminary study based on the following inclusion criteria: (1) complete apex formation; (2) absence of apical resorption or cracks; (3) presence of at least one canal with a moderate to severe angle of curvature (20° to 40°) as measured radiographically according to Schneider's technique,^[25] (4) no history of endodontic treatment. Teeth with calcification, internal or external root resorption, open apices, and cracked roots were not included in this study. Maxillary molars with two mesiobuccal canals were also excluded from the study. The study was approved by the Institutional Scientific Board of the faculty of Dental Medicine of the Lebanese University, Hadath, Lebanon (No. 137/14). The study protocol was in full accordance with the principles of the Declaration of Helsinki of 1975 as revisited in 2000. The patients were informed about the study objectives and procedures and signed a written consent to use their extracted teeth for research purposes.

Immediately after extraction, the teeth were cleaned under continuous water flow and all debris from the periodontal ligament were eliminated using an ultrasonic device. Subsequently, the teeth were stored at room temperature in a 0.9% normal saline solution supplemented with 0.1% thymol (Sigma Chemical Co., St Louis, MO, USA) for antibacterial activity.^[21] The storage solution was changed weekly to maintain cleanliness, hydration, and disinfection.

All crowns were sectioned coronally to the cemento-enamel junction to obtain roots with 16 mm uniform length. Standardized access cavities were made and sealed with cotton pellets and modeling wax. Subsequently, the specimens were positioned in the center of a customized 2-cm-high plexiglas cylinder with the apices facing upward [Figure 1]. Fast setting acrylic resin (Paladur Heraeus Kulzer, Inc., South Bend, IN, USA) was poured into the cylinder leaving 2 mm of the apices uncovered. After setting, the cylinders were fixed onto a custom-made plexiglas apparatus equipped with an X-ray sensor slot. This device allowed a constant distance of 20 mm from canal axis-to-sensor and was used to standardize the radiographic documentation of the root canal throughout the experimental procedures [Figure 1]. The tooth-holding plexiglas cylinder was provided with a notch at its base to allow easy and reproducible positioning after each instrumentation and 90°-rotation when taking buccolingual and mesiodistal radiographs [Figure 1]. A baseline X-ray was taken to confirm the absence of cracks and the presence of canals with moderate-to-severe curvature.

The cylinders containing the specimens were transferred into a second prefabricated light-cured resin mount to stabilize the samples during canal preparation. The curved mesiobuccal canal of the maxillary molars and the mesiobuccal or mesiolingual canal of the mesial root of mandibular molars was selected to receive treatment while the remaining canals were left uninstrumented. The canals were localized using an endodontic probe (DG16, Hu Friedy, USA) and negotiated with a size 8 or 10 K file (FlexoFile, Dentsply Maillefer) in the presence of a viscous chelator Glyde® (Glyde File Prep, Dentsply Maillefer) until the tip was just visible and tangent to the apical foramen under a stereomicroscope (SM-1TSSZ-144S, Irvine, CA, USA) at $\times 45$ magnification. The silicone stop was adjusted to the nearest flat anatomical landmark and the distance between the file's tip and the rubber stopper was measured with an endodontic ruler (Dentsply Maillefer). The working length (WL) was recorded as the reference landmark-file tip measurement minus 0.5 mm.

EXPERIMENTAL DESIGN

The 45 selected canals were randomly assigned into three groups according to the type of rotary NiTi system: Group PTN ($n = 15$) instrumented with PTN®, Group BTR ($n = 15$) with BTR®, and Group WOG ($n = 15$) with WOG®. A mechanical glide path was obtained with rotary Proglider 0.16 file while a manual glide path was created with 10 K hand files for the BTR group as per manufacturers guidelines. The preprogrammed endodontic motor (X-SMART Plus™-Dentsply-Maillefer) was set for each group of NiTi instruments using the specific settings (torque, speed, and movement) recommended by the manufacturer. One set of new instruments was used for each canal. During instrumentation, canals were irrigated using 3 ml of 5%

NaOCl solution after each file and the Glyde® chelator was used as lubricant. Final irrigation was carried out with 1 ml of 17% EDTA for 1 min, then by a final rinse of 3 ml of NaOCl. The final apical preparation was standardized to size 25 for the PTN and WOG instruments and to size 35 for BTR. Root canal instrumentation was performed by one single experienced endodontist according to the sequence illustrated in Table 1.

In all specimens, the canals were instrumented to the WL, then to the major foramen (WL plus 0.5 mm), and subsequently overinstrumented up to 0.5 mm, 1 mm, and 1.5 mm beyond the foramen. The WL was recalculated when increasing the file sizes and levels of instrumentation/overinstrumentation to avoid file protrusion beyond the desired amount.

RADIOGRAPHIC DOCUMENTATION

A total of 10 radiographs were taken for each canal using the digital Xgenus® X-ray machine (de Götzen®, Olgiate Olona, VA, Italy) and applying standardized exposure parameters (70 kV, 0.16 s, and 8 mA). The radiographic sensor (Ez Sensor i 1.5 Vatech, Korea) was placed into the dedicated slot in the plexiglas mounting device and the X-ray cone positioned directly against the opposing flat surface of the mount at a constant source-to-sensor distance of 70 cm [Figure 1]. The X-ray beam was aligned perpendicularly to the root canal. All specimens were radiographed in a buccolingual and mesiodistal directions^[26] before instrumentation (baseline), after instrumentation to the foramen, and following the different levels of overinstrumentation (0.5 mm, 1 mm, and 1.5 mm beyond the foramen) [Figure 2].

The digital radiographs were transferred as JPEG files to a personal computer and the canal curvature evaluated using the AmScope image analysis software (AmScope, Irvine, CA, USA) according to Schneider's method^[25] modified by Zhu *et al.*^[27] Briefly, two reference points were identified in the middle of the file at the level of the canal orifice (point A) and at the apical foramen (point C). A straight line parallel to the file profile was traced from point A to a point where the instrument deviated from the line (point B). The angle formed by the intersection of the two lines AB and BC was recorded as the canal curvature in buccolingual and mesiodistal directions and expressed in degrees with two decimal digits. Canal straightening was measured as the difference between canal curvature before and after instrumentation. Postinstrumentation radiographs were superimposed onto baseline images to evaluate changes in canal curvature.

Radiographic measurements of canal curvature were carried out by an independent examiner blinded to the experimental design and study objectives. Intraobserver



Figure 1: Plexiglas cylinder containing a centrally positioned specimen with the apices facing upward. The cylinder is fixed onto a prefabricated plexiglas mount to standardize radiographic documentation

reliability was assessed based on 10 repeated canal curvature angles of five canals before and following instrumentation. High intraobserver agreement with intraclass correlation coefficient of 0.962 was calculated.

STATISTICAL ANALYSIS

Descriptive statistics with means and standard deviations were reported. One-way ANOVA was used to compare the canal curvature and the degree of canal straightening between groups at each level (preinstrumentation, instrumentation at the foramen, at 0.5 mm, at 1 mm, and at 1.5 mm) and between levels in each group. Mixed-model ANOVA was applied for multiple comparisons and interaction among the explanatory variables: the first with the endodontic system (group) as the between-subject effect and the level of instrumentation as the within-subject effect. *P* value was set at 0.05 for statistical significance. Statistical analysis was performed using SPSS Statistical Package for Social Sciences version 21.0 (SPSS, Inc., Chicago, IL, USA).

RESULTS

No instrument fracture occurred throughout the experimental procedures. A loss of WL ranging between 0.4 and 0.5 mm was observed from baseline to the final level of overinstrumentation. Descriptive and comparative statistics of canal curvature are summarized in Table 2. At baseline, mean canal curvature was not significantly different among the three groups both in the buccolingual ($27.94^\circ \pm 6.22^\circ$ for PTN, $27.57^\circ \pm 7.29^\circ$ for BTR and $27.14^\circ \pm 6.10^\circ$ for WOG; $P = 0.938$) and mesiodistal ($24.05^\circ \pm 6.10^\circ$ for PTN, $22.59^\circ \pm 7.95^\circ$ for BTR and $22.77^\circ \pm 5.91^\circ$ for WOG; $P = 0.812$) directions. All groups showed significant changes in buccolingual and mesiodistal canal curvatures following each level of instrumentation and overinstrumentation; however, the difference between groups continued to be

nonsignificant ($P > 0.05$) [Table 2]. Mixed-model ANOVA confirmed the significant impact of instrumentation level on buccolingual and mesiodistal canal curvatures ($P < 0.0001$). The endodontic system used did neither significantly affect the buccolingual ($P = 0.826$) nor the mesiodistal ($P = 0.679$) canal curvature. There was no significant interaction between instrumentation level and the endodontic system.

The descriptive and comparative results of canal straightening are reported in Table 3. The amount of canal straightening between baseline and instrumentation to the foramen were similar between the three groups in the buccolingual ($P = 0.718$) and mesiodistal ($P = 0.556$) directions. Canal straightening between each pair of successive instrumentation levels was not significantly different between groups ($P > 0.05$). The amount of canal straightening between the successive levels of instrumentation was significantly different within each group ($P = 0.05$) [Figure 3].

DISCUSSION

This study was performed to assess the effect of overinstrumentation on canal curvature and straightening using periapical radiographs. The null hypothesis

Table 1: Sequence of instruments used for canal preparation in the three groups

	PTN group	BTR group	WOG group
Canal negotiation	8-10 K-file	8-10 K-file	8-10 K-file
Instrument to working length	Proglider	BT1	Proglider
Instrument to foramen	X1	BT2	Primary
	X2	BT3	
0.5 mm beyond foramen	X2	BT3	Primary
1 mm beyond foramen	X2	BT3	Primary
1.5 mm beyond foramen	X2	BT3	Primary

PTN: ProTaper Next[®], BTR: BT Race[®], WOG: WaveOne Gold[®]

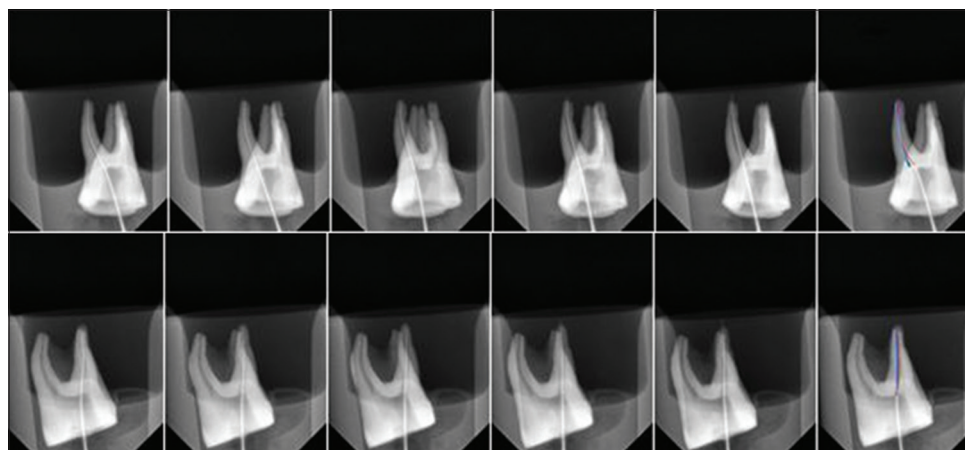


Figure 2: Radiographs of five levels of instrumentation and their superimposition in buccolingual and mesiodistal direction

was accepted in that no significant differences were demonstrated between the three endodontic systems.

In the present study, significant canal straightening occurred with all 3 endodontic systems as the canals were progressively instrumented to the foramen and beyond. This finding is in agreement with other studies where straightening of root canals was demonstrated during instrumentation with hand instruments and NiTi rotary systems including the more recently introduced,^[6,20,28,29] particularly in curved canals.^[2] While canal straightening has been demonstrated with most endodontic systems when the root canal was prepared to the WL,^[6,20,23,24,28] no current documentation is available relative to overinstrumentation beyond the foramen. Direct comparisons cannot be made with previously published data reporting the effect of PTN[®] and BTR[®] rotary systems on canal straightening when instrumentation was stopped at the WL^[20] due to differences in WL determination and the size of the final instrument tip used. However, it could be extrapolated that overinstrumentation is likely to result in a great amount of canal straightening especially when the results showed that the greatest canal straightening occurred

following canal instrumentation to the foramen in all three groups with nearly double values when compared to the subsequent curvature changes associated with the following levels of overinstrumentation.

In addition, the mean loss of WL that occurred during instrumentation with the use of Ni-Ti rotary files was

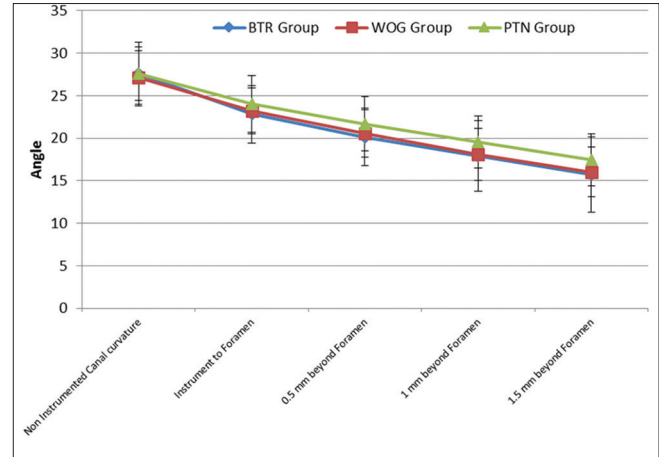


Figure 3: Significant difference between levels within each group is evident in this chart, with no significant difference between the three groups

Table 2: Descriptive and comparative statistics of canal curvature according to group and level of instrumentation

	Buccolingual direction			P ^{a,*}	Mesiodistal direction			P ^{a,*}
	Mean±SD (°)				Mean±SD (°)			
	PTN group (n=15)	BTR group (n=15)	WOG group (n=15)		PTN group (n=15)	BTR group (n=15)	WOG group (n=15)	
Baseline	27.94±6.22	27.57±7.29	27.14±6.10	0.938	24.05±6.10	22.59±7.95	22.77±5.91	0.812
Instrument to foramen	24.02±6.47	22.81±6.55	23.19±5.21	0.859	21.23±6.34	19.20±7.43	19.97±5.57	0.689
0.5 mm beyond foramen	21.67±6.17	20.12±6.54	20.59±5.40	0.774	19.59±6.18	17.31±7.56	18.16±5.69	0.629
1 mm beyond foramen	19.56±5.86	17.91±8.03	18.08±5.96	0.762	18.11±6.04	15.78±8.75	16.40±6.10	0.648
1.5 mm beyond foramen	17.46±5.86	15.73±8.51	16.02±5.70	0.758	16.67±6.10	14.23±9.11	14.93±0.95	0.637
P ^{b,**}	<0.0001	<0.0001	<0.0001		0.017	0.042	0.005	
P	<0.0001 ^c	0.826 ^d	0.981 ^e		<0.0001 ^c	0.679 ^d	0.901 ^e	

*ANOVA test comparing the different groups at each level, **ANOVA test comparing the levels within each group, ^aStatistical differences between the three groups based on one way ANOVA, ^bStatistical differences between the five levels based on one way ANOVA, ^cStatistical differences within participants effect (level) based on mixed model ANOVA, ^dStatistical differences between participants effect (group) based on mixed-model ANOVA, ^e Interaction levels/groups based on mixed-model ANOVA. PTN: ProTaper Next[®], BTR: BT Race[®], WOG: WaveOne Gold[®], SD: Standard deviation

Table 3: Descriptive and comparative statistics of canal straightening between the successive levels of instrumentation

Canal straightening	Buccolingual direction				P [*]	Mesiodistal direction			
	Mean±SD (°)			P [*]		Mean±SD (°)			P [*]
	PTN group (n=15)	BTR group (n=15)	WOG group (n=15)			PTN group (n=15)	BTR group (n=15)	WOG group (n=15)	
Between baseline and instrumentation to foramen	3.92±2.35	4.75±2.70	3.95±2.18	0.718	2.81±1.69	3.40±1.92	2.80±1.51	0.556	
Between foramen and 0.5 mm beyond foramen	2.35±1.91	2.69±2.01	2.60±1.48	0.866	1.64±1.36	1.89±1.38	1.81±1.02	0.864	
Between 0.5 mm and 1 mm beyond foramen	2.11±1.73	2.21±1.73	2.51±1.58	0.874	1.48±1.20	1.53±2.03	1.76±1.10	0.858	
Between 1 mm and 1.5 mm beyond foramen	2.09±1.58	2.18±1.46	2.06±1.40	0.974	1.45±1.10	1.55±1.05	1.48±0.99	0.963	
P ^{**}	0.032	0.011	0.021		0.022	0.008	0.018		

*ANOVA test comparing the different groups at each level, **ANOVA test comparing the levels within each group. PTN: ProTaper Next[®], BTR: BT Race[®], WOG: WaveOne Gold[®], SD: Standard deviation

evaluated to be 0.5 mm, and is in agreement with other studies.^[14,15] These changes in WL probably are because of canal straightening during overinstrumentation.

The experimental design in the present study attempted to provide conditions that better simulate clinical situations using extracted human teeth and operator-driven instruments that allow adjustment of digital pressure according to canal anatomy and perceived stress on the endodontic files.^[30] Care was also taken during sample selection to include teeth with comparable canal curvature as confirmed by the lack of statistically significant differences in baseline Schneider's angle between the three groups. Radiographic documentation was also rigorously standardized in terms of exposure conditions and positional reproducibility of the sensor, X-ray beam, and tooth. Intraobserver reliability of the examiner that performed radiographic measurements was also very high confirming the ability. A limitation of the study is the use of two-dimensional periapical radiographs which show curvatures in one single plane and fail to identify curvatures in the other dimension.^[31] This was overcome by taking radiographs in the buccolingual and mesiodistal directions to ensure that at least some three-dimensional information is obtained. Although microcomputed tomography (micro-CT) has been demonstrated to yield more accurate and less distorted images of the root canal system when compared to conventional radiographs,^[32,33] it has not been specifically compared to periapical radiography in the assessment of canal curvature. In addition, micro-CT is more costly and requires a complex device.^[33,34] Therefore, periapical radiographs continue to be used in recent publications.^[35,36] Another limitation of the study is that the final file diameter of the BTR endodontic set is larger than that of the other two groups resulting in lack of standardization. BTR is not available in size 25.^[20] It is important to emphasize that the modifications in canal curvature were not influenced by the final apical diameter of the files since the results were not significant between the three groups.

CONCLUSION

Within the experimental conditions and results of the present study, it could be concluded that PTN[®], BTR[®], and WOG[®] - systems straightened the canal curvature but can be safely used in curved canals instrumentation at the major foramen with preservation of the original canal shape. Care should be taken to recalculate the WL to prevent overinstrumentation beyond the foramen. Therefore, other studies may be needed regarding the changes of WL and canal curvature caused by rotary systems.

FINANCIAL SUPPORT AND SPONSORSHIP

Nil.

CONFLICTS OF INTEREST

There are no conflicts of interest.

REFERENCES

- Schilder H. Cleaning and shaping the root canal. *Dent Clin North Am* 1974;18:269-96.
- Weine FS, Kelly RF, Lio PJ. The effect of preparation procedures on original canal shape and on apical foramen shape. *J Endod* 1975;1:255-62.
- Oliveira CA, Meurer MI, Pascoalato C, Silva SR. Cone-beam computed tomography analysis of the apical third of curved roots after mechanical preparation with different automated systems. *Braz Dent J* 2009;20:376-81.
- Madani Z, Soleymani A, Bagheri T, Moudi E, Bijani A, Rakhshan V, *et al.* Transportation and centering ability of neoniti and ProTaper instruments; A CBCT assessment. *Iran Endod J* 2017;12:43-9.
- Berutti E, Chiandussi G, Paolino DS, Scotti N, Cantatore G, Castellucci A, *et al.* Effect of canal length and curvature on working length alteration with WaveOne reciprocating files. *J Endod* 2011;37:1687-90.
- Bürklein S, Hinschitzka K, Dammaschke T, Schäfer E. Shaping ability and cleaning effectiveness of two single-file systems in severely curved root canals of extracted teeth: Reciproc and WaveOne versus Mtwo and ProTaper. *Int Endod J* 2012;45:449-61.
- Uygun AD, Kol E, Topcu MK, Seckin F, Ersoy I, Tanriver M, *et al.* Variations in cyclic fatigue resistance among ProTaper Gold, ProTaper Next and ProTaper Universal instruments at different levels. *Int Endod J* 2016;49:494-9.
- Zan R, Tunc T, Hubbezoglu I, Sumera Z. Apical extrusion of intracanal biofilm using ProTaper Gold, WaveOne Gold, Twisted File Adaptive, OneShape new generation and K3XF. *Eur Endod J* 2016;1:3.
- de Menezes SE, Batista SM, Lira JO, de Melo Monteiro GQ. Cyclic fatigue resistance of WaveOne Gold, ProDesign R and ProDesign logic files in curved canals *in vitro*. *Iran Endod J* 2017;12:468-73.
- Türker SA, Uzunoğlu E. Apical root canal transportation of different pathfinding systems and their effects on shaping ability of ProTaper Next. *J Clin Exp Dent* 2015;7:e392-5.
- Ricucci D. Apical limit of root canal instrumentation and obturation, part 1. Literature review. *Int Endod J* 1998;31:384-93.
- Schaeffer MA, White RR, Walton RE. Determining the optimal obturation length: A meta-analysis of literature. *J Endod* 2005;31:271-4.
- Dummer PM, McGinn JH, Rees DG. The position and topography of the apical canal constriction and apical foramen. *Int Endod J* 1984;17:192-8.
- Vasconcelos BC, Bastos LM, Oliveira AS, Bernardes RA, Duarte MA, Vivacqua-Gomes N, *et al.* Changes in root canal length determined during mechanical preparation stages and their relationship with the accuracy of root ZX II. *J Endod* 2016;42:1683-6.
- Yılmaz F, Kamburoğlu K, Şenel B. Endodontic working length measurement using cone-beam computed tomographic images obtained at different voxel sizes and field of views, periapical radiography, and apex locator: A comparative *ex vivo* study. *J Endod* 2017;43:152-6.
- Aminoshariae A, Kulild J. Master apical file size-smaller or larger: A systematic review of microbial reduction. *Int Endod J* 2015;48:1007-22.
- Silva EJ, Ferreira VM, Silva CC, Herrera DR, De-Deus G, Gomes BP, *et al.* Influence of apical enlargement and complementary canal preparation with the self-adjusting file on endotoxin reduction in retreatment cases. *Int Endod J* 2017;50:646-51.
- Saatchi M, Irvani S, Akhavan Khaleghi M, Mortaheb A. Influence of root canal curvature on the accuracy of root ZX electronic

- foramen locator: An *in vitro* study. Iran Endod J 2017;12:173-8.
19. Jafarzadeh H, Beyrami M, Forghani M. Evaluation of conventional radiography and an electronic apex locator in determining the working length in C-shaped canals. Iran Endod J 2017;12:60-3.
 20. Bürklein S, Mathey D, Schäfer E. Shaping ability of ProTaper NEXT and BT-RaCe nickel-titanium instruments in severely curved root canals. Int Endod J 2015;48:774-81.
 21. González Sánchez JA, Duran-Sindreu F, de Noé S, Mercadé M, Roig M. Centring ability and apical transportation after overinstrumentation with ProTaper Universal and ProFile Vortex instruments. Int Endod J 2012;45:542-51.
 22. Hu W, Whitten B, Sedgley C, Svec T. Effect of three NiTi files on transportation of the apical foramen. Int Endod J 2014;47:1064-71.
 23. Celik D, Taşdemir T, Er K. Comparative study of 6 rotary nickel-titanium systems and hand instrumentation for root canal preparation in severely curved root canals of extracted teeth. J Endod 2013;39:278-82.
 24. Saber SE, Nagy MM, Schäfer E. Comparative evaluation of the shaping ability of ProTaper Next, iRaCe and Hyflex CM rotary NiTi files in severely curved root canals. Int Endod J 2015;48:131-6.
 25. Schneider SW. A comparison of canal preparations in straight and curved root canals. Oral Surg Oral Med Oral Pathol 1971;32:271-5.
 26. Cumbo E, Russo R, Gallina G. Assessment of root canal enlargement using Mtwo and BioRace rotary files. ScientificWorldJournal 2015;2015:859693.
 27. Zhu YQ, Gu YX, Du R, Li C. Reliability of two methods on measuring root canal curvature. Int Chin J Dent 2003;3:118-21.
 28. Gekelman D, Ramamurthy R, Mirfarsi S, Paqué F, Peters OA. Rotary nickel-titanium GT and ProTaper files for root canal shaping by novice operators: A radiographic and micro-computed tomography evaluation. J Endod 2009;35:1584-8.
 29. Vahid A, Roohi N, Zayeri F. A comparative study of four rotary NiTi instruments in preserving canal curvature, preparation time and change of working length. Aust Endod J 2009;35:93-7.
 30. Ounsi HF, Franciosi G, Paragliola R, Al-Hezaimi K, Salameh Z, Tay FR, *et al.* Comparison of two techniques for assessing the shaping efficacy of repeatedly used nickel-titanium rotary instruments. J Endod 2011;37:847-50.
 31. Habib AA, Taha MI, Farah EM. Methodologies used in quality assessment of root canal preparation techniques: Review of the literature. J Taibah Univ Med Sci 2005;10:123-31.
 32. Paqué F, Ganahl D, Peters OA. Effects of root canal preparation on apical geometry assessed by micro-computed tomography. J Endod 2009;35:1056-9.
 33. Balani PN, Niazi F, Rashid H. A brief review of the methods used to determine the curvature of root canals. J Res Dent 2015;3:57-63.
 34. Michetti J, Basarab A, Diemer F, Kouame D. Comparison of an adaptive local thresholding method on CBCT and μ CT endodontic images. Phys Med Biol. 2017;63:015020.
 35. Aminsobhani M, Razmi H, Nozari S. Ex *vivo* comparison of Mtwo and RaCe rotary file systems in root canal deviation: One file only versus the conventional method. J Dent (Tehran) 2015;12:469-77.
 36. Bürklein S, Jäger PG, Schäfer E. Apical transportation and canal straightening with different continuously tapered rotary file systems in severely curved root canals: F6 SkyTaper and OneShape versus Mtwo. Int Endod J 2017;50:983-90.