

Flow-through arterialized venous free thenar flaps for palmar soft tissue defects in fingers

Journal of International Medical Research
49(2) 1–8

© The Author(s) 2021

Article reuse guidelines:

sagepub.com/journals-permissions

DOI: 10.1177/0300060521991032

journals.sagepub.com/home/imr



Song Gu* , Huichao Fu*, Yinjun Huang and Renguo Xie

Abstract

Objective: To evaluate the efficacy of venous free thenar flaps for reconstructing palmar soft tissue defects in fingers.

Methods: From December 2018 to October 2019, 11 patients with palmar soft tissue defects in fingers were treated using venous free thenar flaps. At the final follow-up, the range of thumb radial and palmar abduction on the injured side and opposite side was calculated. The total active movement (TAM) of the injured and opposite fingers and flap sensibility recovery were also recorded.

Results: The mean follow-up time was 13.4 months, all flaps survived, and all wounds at the donor sites healed with no skin necrosis. At the last follow-up, the average range of thumb radial abduction and thumb palmar abduction on the injured side was 96.6% and 95.9% of the value on the opposite side, respectively. The average TAM of the injured fingers was 98.2% of the value of the opposite fingers. Sensation in the flaps was restored to grade S2 to S3.

Conclusion: Venous free thenar flaps can be alternatives for reconstructing palmar soft tissue defects in fingers.

Keywords

Palmar skin, thenar flap, soft tissue defect, venous flap, finger injury, total active movement

Date received: 7 November 2020; accepted: 5 January 2021

Trauma Center, Shanghai General Hospital, Shanghai Jiao Tong University School of Medicine, Shanghai, People's Republic of China

*These authors contributed equally to this work.

Corresponding author:

Renguo Xie, Trauma Center, Shanghai General Hospital, Shanghai Jiao Tong University School of Medicine, No. 650 Xin Songjiang Road, Shanghai 201620, People's Republic of China.

Email: 13862906768@163.com



Creative Commons Non Commercial CC BY-NC: This article is distributed under the terms of the Creative Commons Attribution-NonCommercial 4.0 License (<https://creativecommons.org/licenses/by-nc/4.0/>) which permits non-commercial use, reproduction and distribution of the work without further permission provided the original work is attributed as specified on the SAGE and Open Access pages (<https://us.sagepub.com/en-us/nam/open-access-at-sage>).

Palmar soft tissue defects in fingers are very common in hand injuries. Owing to its unique features, such as a thick epidermal layer and poor mobility, the palmar skin of the finger helps humans achieve various functions, such as holding and grasping. Because of its importance, many methods have been used to repair palmar soft tissue defects to achieve better recovery.¹⁻³ With societal developments, patients have higher requirements regarding their appearance, and sensory and functional recovery after surgeries.⁴ Therefore, when flaps are selected to repair soft tissue defects, not only coverage, but also function and aesthetics should be considered.⁵⁻⁷

Compared with the palmar skin of the finger, the thenar skin has a similar texture, which makes it an ideal source for repairing palmar soft tissue defects of the finger.⁸ Common thenar flaps used for reconstructing soft tissue defects of the fingers are pedicled thenar flaps⁹ and free thenar flaps with arteries.¹⁰ However, these flaps have inevitable shortcomings; pedicled thenar flaps may require second-stage operations, and creating free arterial flaps may lead to more damage to the healthy tissues.

Venous flaps have been applied clinically for some time.¹¹ The veins in the thenar region are superficial and widely distributed, which makes them easy to observe and harvest. Therefore, considering the skin texture and anatomical features, we made good use of the superficial veins and improved the traditional free thenar flap for reconstructing soft tissue defects in fingers. The purpose of this study was to evaluate the use of venous free thenar flaps for repairing palmar wounds in fingers.

Materials and methods

From December 2018 to October 2019, 11 patients with palmar soft tissue defects of the hands were treated with venous free thenar flaps. The inclusion criteria were

(1) acute or chronic palmar soft tissue defect(s) of the finger; (2) defects no larger than 4.0 cm in length and 2.5 cm in width; and (3) no obvious infection. Exclusion criteria were (1) defects larger than 4.0 cm long or larger than 2.5 cm wide; (2) bone or tendon injury that could affect the accuracy of postoperative joint range of motion; (3) injury to the thenar area of the hand; and (4) concurrent diabetes or vascular disease that could affect flap survival. Table 1 lists the demographic data of the 11 patients. This study was approved by the institutional review board of Shanghai General Hospital, and each patient provided signed informed consent before participating in the study.

Surgical technique

All patients were placed in the supine position under general anesthesia. A tourniquet was placed at the upper third of the upper arm on the injured side, with a pressure of 250 mmHg. After thorough debridement (Figure 1a), the wound area was measured, and satisfactory arteries and veins were detected using an operating microscope, for future use. The radial base of the proximal phalanx of the thumb and the scaphoid tubercle were palpated and marked. These two points were then connected with a line, and the midpoint was marked. With this midpoint as the center and the line as the longitudinal axis, the flap was designed to be slightly larger than the wound (Figure 1b). The skin along the edge of the flap was incised, and the number and positions of veins at the flap edge were observed and marked. The veins were carefully detected along the opposite direction of the flap for approximately 5 mm and then cut (Figure 2a). The flap was then harvested along the surface of the thenar muscles. The entire process was performed using an operating microscope. The donor site was sutured directly with 3-0

Table I. Demographic data of the 11 patients receiving free thenar grafts.

Patient	Age, Years	Gender	Dominant/Non-Dominant	Cause	Follow-up, months	Defect Size (cm×cm)	Flap Size (cm×cm)
1	48	M	ND	Avulsion	20	1.3 × 1.8	1.5 × 2.0
2	31	F	D	Crush	19	1.8 × 2.7	2.0 × 3.0
3	53	M	ND	Avulsion	16	1.2 × 2.3	1.5 × 2.5
4	43	M	D	Avulsion	13	2.2 × 2.8	2.5 × 3.0
5	48	M	ND	Avulsion	12	1.3 × 2.3	1.5 × 2.5
6	41	M	D	Avulsion	12	1.3 × 1.7	1.5 × 2.0
7	55	M	D	Crush	12	1.2 × 1.7	1.5 × 2.0
8	48	M	D	Crush	11	1.8 × 2.3	2.0 × 2.5
9	50	F	D	Crush	11	1.3 × 1.7	1.5 × 2.0
10	52	M	ND	Crush	11	2.3 × 2.8	2.5 × 3.0
11	51	M	D	Crush	10	2.4 × 3.2	2.5 × 3.5
Mean	47.3				13.4	1.6 × 2.3	1.9 × 2.5

M, male; F, female.

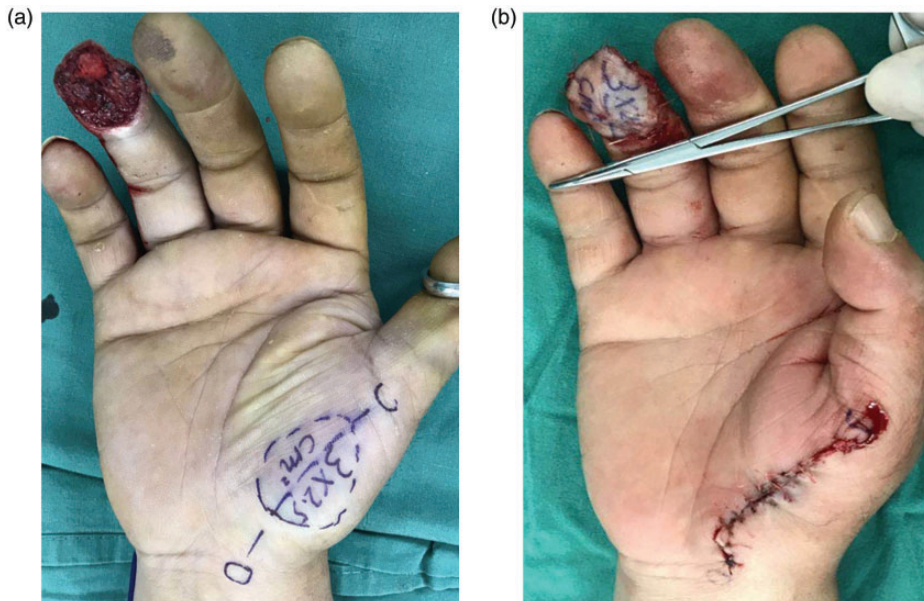


Figure 1. (a) Frontal appearance of the wound and design of the flap (patient 4). (b) Immediate appearance after surgery (patient 4).

coated Vicryl Plus antibacterial suture (Ethicon Inc., Somerville, NJ, USA). After the flap was transferred to the wound, one artery in the recipient site was anastomosed to one vein in the flap using 10-0 Prolene

(Ethicon Inc.). Then, one vein in the recipient site was anastomosed to one vein in the flap (Figure 2b). Each vascular anastomosis was performed using an operating microscope.

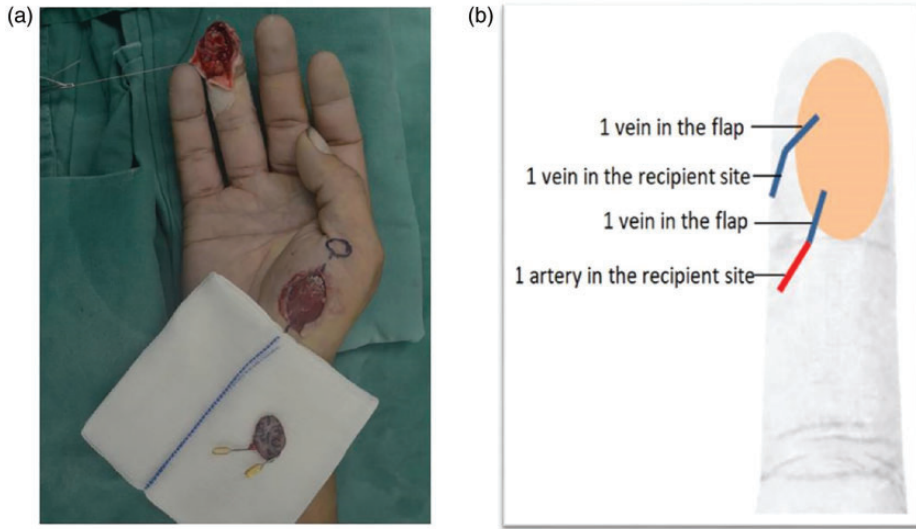


Figure 2. (a) The donor site appearance and the marked veins of the flap after the flap was harvested (patient 5). (b) Schematic diagram showing the vascular anastomosis of the flow-through arterialized venous free thenar flap.

Postoperative management

The color, capillary refill, and temperature of the flaps were evaluated daily. If venous crisis occurred, heparin was wiped along the flap edge until the effusion turned to fresh blood. Dressings were kept loose to avoid compressing the flaps and obstructing blood flow. After the wounds had healed, the patients began rehabilitation and exercises under the guidance of a physiotherapist.

Outcome evaluation

In this study, each patient's gender, age, cause of injury, defect size, flap size, and follow-up time were recorded. Postoperative complications, such as skin necrosis at the donor sites and flap necrosis at the recipient sites were recorded. We evaluated the scar at the donor site according to the Vancouver scar scale (VSS). The range of thumb radial and palmar abduction of the injured side and opposite side

was calculated, as well as total active movement (TAM) (metacarpophalangeal plus interphalangeal) of the injured finger and opposite finger. According to the British Medical Research Council's sensibility recovery grading standard, the sensibility recovery was described as S4, S3+, S3, S2, S1, or S0, from excellent to poor. Another group of hand surgeons who did not participate in the surgeries performed these assessments.

Results

The mean follow-up time was 13.4 months (range: 10–20 months); all flaps survived (Figure 3a), and all wounds at the donor sites healed with no skin necrosis. Five flaps (45.5%) in the 11 cases had some degree of swelling, which resolved after symptomatic treatment within 2 to 3 days after the operations. At the last follow-up, the average VSS score at the donor sites was 4.5 (range: 4–6). The average range of thumb radial abduction and thumb

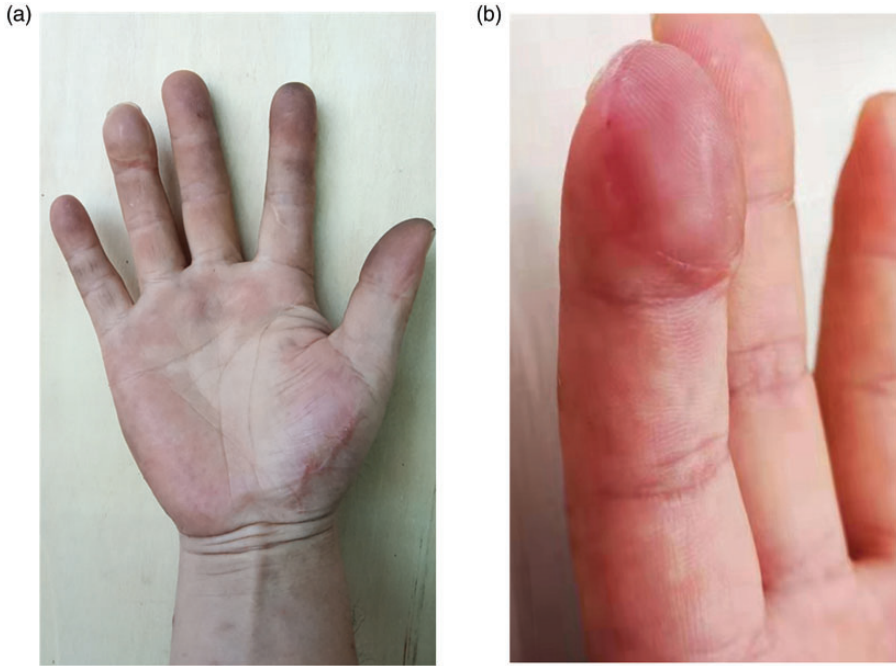


Figure 3. (a) Appearance 8 months after surgery (patient 4). (b) Reconstructed fingerprint (patient 4).

palmar abduction of the injured sides was 96.6% and 95.9% of the value of the opposite sides, respectively (Table 2). The average TAM of the injured fingers was 98.2% of the value for the opposite fingers, and the sensibility recovery of the flaps was restored to grade S2 to S3 (Table 3).

Discussion

Thenar flaps were first used for soft tissue defects of the hands by Flatt¹² in 1957. Subsequently, Neuman¹³ and Kamei¹⁴ made further improvements, and the application of thenar flaps was gradually popularized. Pedicled thenar flaps are relatively easy to harvest to repair soft tissue defects of the finger, but a second-stage surgery is usually necessary to remove the pedicle. Furthermore, prolonged flexion of the fingers can cause intense discomfort to patients. When harvesting free thenar flaps, including the superficial branch of

the radial artery, more damage may be caused to the surrounding healthy tissues. The propeller perforator flap is also often used to repair soft tissue defects; however, its disadvantage for palmar soft tissue defects in the fingers is that skin grafting is often required at the donor site.¹⁵ Since the successful animal experiments involving flaps nourished by arterial inflow through the venous system that were performed by Nakayama¹⁶ in 1981, greater numbers of venous flaps^{17–21} have been reported for repairing soft tissue defects, although the mechanism of flap survival remains unclear, and complications may occur, such as pigmentation.²² In our study, all flaps survived without the common disadvantages of conventional venous flaps, such as swelling and pigmentation, and the flap survival progression was similar to that of arterial flaps.

It is important to remain close to the surface of the thenar muscles when harvesting thenar flaps to protect the thenar

Table 2. Postoperative assessment of the donor sites in the 11 patients receiving free thenar grafts.

Patient	Skin Necrosis	VSS	Thumb Radial Abduction			Thumb Palmar Abduction		
			Injured Side (degrees)	Opposite Side (degrees)	Injured/Opposite (%)	Injured Side (degrees)	Opposite Side (degrees)	Injured/Opposite (%)
1	No	4	45	46	97.8	48	50	96.0
2	No	5	45	45	100.0	50	52	96.2
3	No	6	43	45	95.6	51	53	96.2
4	No	4	42	45	93.3	50	53	94.3
5	No	4	45	47	95.7	48	52	92.3
6	No	5	48	49	98.0	52	53	98.1
7	No	4	45	47	95.7	51	53	96.2
8	No	4	43	46	93.5	52	55	94.5
9	No	5	45	46	97.8	55	56	98.2
10	No	4	46	47	97.9	54	55	98.2
11	No	4	44	45	97.8	53	56	94.6
Mean		4.5	44.6	46.2	96.6	51.3	53.5	95.9

VSS, Vancouver scar scale.

Table 3. Postoperative assessment of the recipient sites in the 11 patients receiving free thenar grafts.

Patient	Flap Necrosis	TAM (Metacarpophalangeal Plus Interphalangeal)			Flap Sensibility Recovery
		Injured Finger (degrees)	Opposite Finger (degrees)	Injured/Opposite (%)	
1	No	255	260	98.1	S3
2	No	260	265	98.1	S3
3	No	255	260	98.1	S2
4	No	245	250	98.0	S3
5	No	250	255	98.0	S3
6	No	245	250	98.0	S2
7	No	250	250	100.0	S2
8	No	250	250	100.0	S2
9	No	245	250	97.3	S2
10	No	250	260	96.2	S2
11	No	255	260	98.1	S2
Mean		250.9	255.5	98.2	

TAM, total active movement.

muscles and ensure that their function remains unaffected. The ranges of thumb radial abduction of the injured side and the opposite side were nearly the same in our study, as were the ranges of thumb

palmar abduction. We encountered no skin necrosis at any donor sites, and the donor site wounds healed completely with only linear scars. The average VSS score was 4.5, and no patients reported

discomfort. The intact thenar muscles played a role in natural skin dilation and ensured satisfactory fullness of the thenar area. None of the flaps developed edema, and all fingers had smooth appearances. Compared with the opposite finger, the joint function of the injured finger was almost completely restored in all cases.

In all 11 cases, we performed precise vascular anastomosis of two vessels, namely one artery and one vein. Although all of the flaps survived, we found that the survival progression of the flaps differed. Five flaps (45.5%) in the 11 cases had some degree of swelling that resolved after symptomatic treatment within 2 to 3 days after the operations; the other flaps did not develop swelling and healed successfully. In the postoperative observation, we found that more vascular crises in the flaps occurred in the veins rather than in the arteries. Even though the diameter of the peripheral vessels is very small, as long as we ensure the anastomosis quality, the blood supply can meet the needs of flap survival because of the small area of the flap. However, the possibility of flap necrosis caused by venous crisis requires more attention. It is worth mentioning that thenar flaps can be used to reconstruct the lost fingerprint (Figure 3b) owing to the original injury and improve the quality of life of patients with soft tissue defects in the pulp, which is required in modern society.

The maximum width of the flaps in our study was 2.5 cm, and further study is needed to explore whether wider donor site flaps can heal successfully after direct suturing. When performing vascular anastomosis, the arteries in the wound at the recipient area should be fully utilized. If available arteries matching the diameter of the veins in the flap can be found, it is not necessary to make another skin incision to search for available arteries, which causes additional damage to the healthy arteries and skin.

The recovery of sensibility is an important index to evaluate the flap,²³ especially for repairing palmar soft tissue defects of the finger. In our study, sensibility in four cases reached grade S3, and sensibility in the other seven cases reached grade S2 according to the British Medical Research Council's sensibility recovery grading standard, at the last follow-up. To test whether sensibility recovery can be further improved, in a future study, we will conduct long-term follow-up of sensibility recovery of the flaps, using the Semmes–Weinstein monofilament (SWM) and static two-point discrimination (2-PD) evaluations. Although the assessment of sensibility recovery requires long-term follow-up, we believe that venous free thenar flaps have great potential in the reconstruction of palmar soft tissue defects in fingers.

Venous free thenar flaps are reliable owing to the constancy of the veins and ease of dissection. Dissecting these flaps causes little damage to the healthy tissues, which ensures that postoperative hand function is satisfactory, the color and texture of the flap is close to that of the palmar skin of the finger, and good aesthetic appearance can be achieved. The disadvantages of the method are the need for skilled microscopic technique during the operation and strict observation and nursing after the operation because postoperative swelling and congestion might occur.

Declaration of conflicting interest

The authors declare that there is no conflict of interest.

Funding

This research received no specific grant from any funding agency in the public, commercial, or not-for-profit sectors.

ORCID iD

Song Gu  <https://orcid.org/0000-0001-8589-4573>

References

1. Iwuagwu FC, Orkar SK and Siddiqui A. Reconstruction of volar skin and soft tissue defects of the digits including the pulp: experience with the free SUPBRA flap. *J Plast Reconstr Aesthet Surg* 2015; 68: 26–34.
2. Rose EH, Norris MS and Kowalski TA. Microsurgical management of complex fingertip injuries: comparison to conventional skin grafting. *J Reconstr Microsurg* 1988; 4: 89–98.
3. Koshima I, Urushibara K, Inagawa K, et al. Free medial plantar perforator flaps for the resurfacing of finger and foot defects. *Plast Reconstr Surg* 2001; 107: 1753–1758.
4. Gu JX, Regmi S, Zhang NC, et al. Second toe microsurgical free-flap for aesthetic and sensory reconstruction of palmar soft tissue defects of fingers. *J Plast Reconstr Aesthet Surg* 2016; 69: 323–327.
5. Jeon BJ, Yang JW, Roh SY, et al. Microsurgical reconstruction of soft-tissue defects in digits. *Injury* 2013; 44: 356–360.
6. Ni F, Appleton SE, Chen B, et al. Aesthetic and functional reconstruction of fingertip and pulp defects with pivot flaps. *J Hand Surg Am* 2012; 37: 1806–1811.
7. Zheng DW, Li ZC, Shi RJ, et al. Thumb reconstruction via a pedicled flap based on the superficial palmar branch of the radial artery from the wrist crease area. *J Plast Reconstr Aesthet Surg* 2015; 68: 1581–1587.
8. Barr JS, Chu MW, Thanik V, et al. Pediatric thenar flaps: a modified design, case series and review of the literature. *J Pediatr Surg* 2014; 49: 1433–1438.
9. Kanaya K, Wada T, Iba K, et al. Innervated thenar pedicle flap with the palmar cutaneous branch of the median nerve for treating a thumb pulp defect: a case report. *J Reconstr Microsurg* 2014; 30: 363–366.
10. Tsai TM, Sabapathy SR and Martin D. Revascularization of a finger with a thenar mini-free flap. *J Hand Surg Am* 1991; 16: 604–606.
11. Kawakatsu M, Ishikawa K and Sawabe K. Free arterialised flow-through venous flap with venous anastomosis as the outflow (A-A-V flap) for reconstruction after severe finger injuries. *J Plast Surg Hand Surg* 2013; 47: 66–69.
12. Flatt AE. The thenar flap. *J Bone Joint Surg Br* 1957; 39B: 80–85.
13. Neuman Z. The lateral thenar flap. *Lsr Med J* 1963; 22: 125–127.
14. Kamei K, Ide Y and Kimura T. A new free thenar flap. *Plast Reconstr Surg* 1993; 92: 1380–1384.
15. Georgescu AV and Matei IR. Propeller perforator flaps for finger reconstruction. *J Xiangya Med* 2018; 3: 20.
16. Nakayama Y, Soeda S and Kasai Y. Flaps nourished by arterial inflow through the venous system. *Plast Reconstr Surg* 1981; 67: 328–334.
17. Chen HC, Tang YB and Noordhoff MS. Four types of venous flaps for wound coverage: a clinical appraisal. *J Trauma* 1991; 31: 1286–1293.
18. Fukui A, Inada Y, Maeda M, et al. Venous flap—its classification and clinical applications. *Microsurgery* 1994; 15: 571–578.
19. Goldschlager R, Rozen WM, Ting JW, et al. The nomenclature of venous flow-through flaps: updated classification and review of the literature. *Microsurgery* 2012; 32: 497–501.
20. Kantarci U, Cepel S and Gurbuz C. Venous free flaps for reconstruction of skin defects of the hand. *Microsurgery* 1998; 18: 166–169.
21. Kong BS, Kim YJ, Suh YS, et al. Finger soft tissue reconstruction using arterialized venous free flaps having 2 parallel veins. *J Hand Surg Am* 2008; 33: 1802–1806.
22. Kawakatsu M. Free medial pedis venous flap transfer for reconstruction of volar finger defects: Clinical application and esthetic evaluation. *J Plast Reconstr Aesthet Surg* 2019; 72: 459–466.
23. Sobanko JF, Fischer J, Etkorn J R, et al. Local fasciocutaneous sliding flaps for soft-tissue defects of the dorsum of the hand. *JAMA Dermatol* 2014; 150: 1187–1191.