

Case Report

Spontaneous Resolution of a Large Chronic Subdural Hematoma Which Required Surgical Decompression

Gun Seok Lee, M.D., Young Seok Park, M.D., Kyung Soo Min, M.D., Mou Seop Lee, M.D., Ph.D.

Department of Neurosurgery, Chungbuk National University School of Medicine & Medical Research Institute, Cheongju, Korea

We report on a case of an 87-year-old woman who showed spontaneous resolution of a large chronic subdural hematoma which required surgical decompression. She had suffered from confused mentality and right side weakness of motor grade II for 10 days. The initial brain CT scan showed a 22 mm thick low density lesion located in the left fronto-temporo-parietal region with midline shift (12 mm) which required emergency decompression. However, because she and her family did not want surgery, she was followed up in the outpatient clinic. Five months later, follow up brain CT showed that the CSDH had disappeared and the patient became neurologically normal. The reasons for spontaneous resolution of CSDH remain unclear. We discuss the possible relation between mechanisms of physio-pathogenesis and spontaneous resolution of a large chronic subdural hematoma (CSDH) in an elderly patient.

Key Words : Chronic subdural hematoma · Craniotomy · Burr hole · Observation.

INTRODUCTION

Chronic subdural hematoma (CSDH) is a common disease in the neurosurgical field, particularly in the elderly.

The most common cause of chronic subdural hematoma is head trauma; other causes include coagulopathy, anticoagulant therapy, metastatic tumor, vascular malformations, and alcoholism^{2,10}. Symptoms vary, including headache, motor weakness, amnesic deficit, and lack of concentration.

Surgical treatment of CSDH in symptomatic patients is still the “gold standard” of therapy because it enables immediate decompression of the space-occupying lesion and significantly improves outcome. Nonsurgical treatment of CSDH could be administered in situations such as poor general condition or elderly patients who favor nonsurgical treatment.

The reasons for spontaneous resolution of CSDH are unclear. Herein, we report on a case that showed spontaneous resolution of a large CSDH and review the literatures on spontaneous resolution and nonsurgical treatment of CSDH.

CASE REPORT

An 87-year-old woman presented with confused mentality and right side weakness of motor grade II for 10 days. She had a

history of head trauma one month ago. She had no history of alcoholism or anticoagulant therapy. After visiting a local hospital and undergoing computed tomographic (CT) scan, she was diagnosed as CSDH and transferred to our hospital for surgery.

When she visited our hospital, her Glasgow coma scale score was 14, mental state was light drowsy, motor grade was right hemiparesis of grade II, and Mini-Mental State Examination score was 11/30.

She had no underlying disease and a previously healthy state. Initial laboratory studies and vital signs were all within normal range.

The initial CT scan showed a 22 mm thick low density lesion located in the left fronto-temporo-parietal region with 12 mm midline shift to the right (Fig. 1A). Based on the CT scan and the patient's status, it was a definite indication for surgical treatment. Although we recommended surgical management to the patient's family, they refused because of the patient's old age and the risk of surgery. Therefore, we prescribed anticonvulsant (valproate sodium) only and planned on close observation of the patient with follow up brain CT.

The patient underwent 5 CT scans. Follow up brain CT scan after 1 month showed a decreased amount of hematoma (Fig. 1B). The thickness of SDH in the left fronto-temporo-parietal convexity was 12 mm. The patient's mental status was improved

• Received : May 7, 2015 • Revised : August 4, 2015 • Accepted : August 5, 2015

• Address for reprints : Mou Seop Lee, M.D., Ph.D.

Department of Neurosurgery, Chungbuk National University School of Medicine & Medical Research Institute, 776 1sunhwan-ro, Seowon-gu, Cheongju 28644, Korea
Tel : +82-43-269-6087, Fax : +82-43-273-1614, E-mail : mslee@chungbuk.ac.kr

• This is an Open Access article distributed under the terms of the Creative Commons Attribution Non-Commercial License (<http://creativecommons.org/licenses/by-nc/3.0>) which permits unrestricted non-commercial use, distribution, and reproduction in any medium, provided the original work is properly cited.

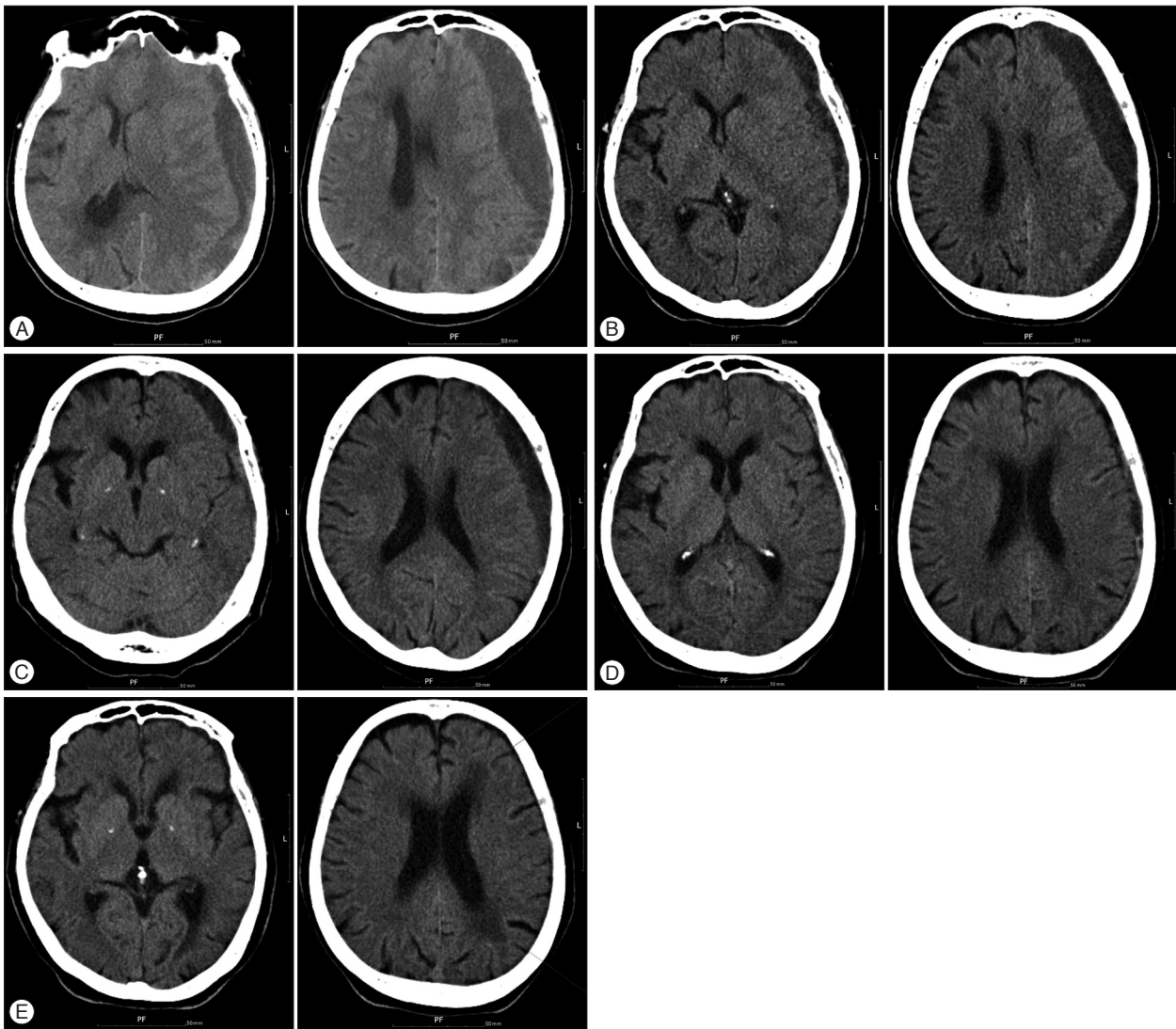


Fig. 1. A : Initial brain CT scans showed thick crescent low density lesions in left fronto-temporo-parietal regions with midline shift. B : Follow-up CT scan 1 month later showed a decreased amount of subdural hematoma. C and D : Follow-up CT scan 2 and 3 months later showed gradual resolution of the hematoma. E : Follow-up CT scan 5 months later showed disappearance of the hematoma.

to alert and the right side hemiparesis symptom improved to motor grade 4. The brain CT after 2 and 3 months showed a gradual subsiding of the SDH (Fig. 1C, D). Patient's right hemiparesis had disappeared and self-ambulation was possible. Follow up brain CT scan after 5 months showed disappearance of the CSDH and the patient was neurologically normal (Fig. 1E).

DISCUSSION

In the literature, spontaneous resolution of CSDH has rarely been reported and the reason for spontaneous resolution of CSDH remains unclear. However, several theories have been proposed to explain the mechanisms of resolution of CSDH.

According to Nakamura et al.^{7),} the decreased fibrinolytic activity of the hematoma and its capsule might have caused spontaneous resolution. Kawano and Suzuki⁶⁾ investigated the possi-

bility that presence of smooth muscle cells in the outer membrane of hematoma might play a role in the resolution of CSDH. Glover and Labadie¹⁾ demonstrated a reduced rate of membrane formation in an animal model with corticosteroid treatment in which the effect of dexamethasone was thought to be anti-inflammatory or antiangiogenic³⁾.

Several non-operative treatments have been described, including observation only, mannitol and ACE inhibitors or corticosteroids, however justification for treatment using ACE inhibitors or steroids has mainly been theoretical, and further research is clearly warranted¹¹⁾. In a recent study, Kageyama et al.⁵⁾ suggested that Tranexamic acid might simultaneously inhibit the fibrinolytic and inflammatory (kinin-kallikrein) systems, which might consequently lead to resolution of CSDH. In our patient, we prescribed only anticonvulsant (valproate sodium) without other medication.

Table 1. Literature data regarding spontaneously resolved chronic subdural hematomas

Age/sex	Symptoms (neurologic deficits)	Midline shift* (mm)	Resolution time (day)	Anticoagulation therapy	Trauma Hx.	Reference
41/M	No	0	174	-	Yes	Nakamura et al. ⁷⁾
21/M	No	0	78	-	Yes	Nakamura et al. ⁷⁾
75/F	Headache	5	150	No	Yes	Horikoshi et al. ⁴⁾
69/M	Dizziness	-	150	No	Yes	Horikoshi et al. ⁴⁾
68/M	No	5	-	-	-	Horikoshi et al. ⁴⁾
75/F	Headache	0	-	-	-	Horikoshi et al. ⁴⁾
79/M	Headache	0	50	No	Yes	Parlato et al. ¹⁰⁾
68/M	No	0	45	No	Yes	Parlato et al. ¹⁰⁾
76/F	No	0	45	No	Yes	Parlato et al. ¹⁰⁾
72/M	No	0	43	No	Yes	Parlato et al. ¹⁰⁾
71/F	No	0	42	No	Yes	Parlato et al. ¹⁰⁾
35/M	Speech Disturbance	0	135	No	No	Göksu et al. ²⁾
87/F	Confused mentality, right side weakness (Gr II)	12	140	No	Yes	Our case

*Maximal midline displacement

Some case reports on CT characteristics of spontaneous resolution of chronic subdural hematoma showed that the hematoma density becomes low with decreasing size^{4,7-9)}. Nakamura et al.⁷⁾ reported that every CSDH that resolved without surgery showed low density on follow-up CT and these authors also indicated that the fibrinolytic activity of low density hematomas decreased with regression of the thickness of the cavity.

In the previously reported cases, radiologic characteristics of spontaneously resolved CSDH were small size of subdural hematoma, low or iso density of hematoma⁷⁾, and absence of midline shifting or severe mass effect⁴⁾, and its clinical characteristics were asymptomatic and mild transient headache^{4,10)}. The radiologic and clinical characteristics of our case are completely different from those of the previously reported cases. In our case, the subdural hematomas were large and the midline shifting was more than 12 mm. In addition, the patient showed severe hemiparesis clinically (Table 1).

CONCLUSION

This is a previously unreported rare case of spontaneous resolution of a large CSDH which required surgical decompression with hemiparesis and severe midline shift. Surgical treatment is still the gold standard and the first option in large CSDH with ventricular compression with mid-line shift having a distinct neurologic deficit. The possibility of conservative treatment is not indicated, however, there is probably another chance of spontaneous recovery as in our case. Persistent and close follow up of the patient is required in such CSDH cases.

• Acknowledgements

This work was supported by the research grant of the Chungbuk Na-

tional University in 2012.

References

- Glover D, Labadie EL : Physiopathogenesis of subdural hematomas. Part 2 : Inhibition of growth of experimental hematomas with dexamethasone. *J Neurosurg* 45 : 393-397, 1976
- Göksu E, Akyüz M, Uçar T, Kazan S : Spontaneous resolution of a large chronic subdural hematoma : a case report and review of the literature. *Ulus Travma Acil Cerrahi Derg* 15 : 95-98, 2009
- Hohenstein A, Erber R, Schilling L, Weigel R : Increased mRNA expression of VEGF within the hematoma and imbalance of angiopoietin-1 and -2 mRNA within the neomembranes of chronic subdural hematoma. *J Neurotrauma* 22 : 518-528, 2005
- Horikoshi T, Naganuma H, Fukasawa I, Uchida M, Nukui H : Computed tomography characteristics suggestive of spontaneous resolution of chronic subdural hematoma. *Neurol Med Chir (Tokyo)* 38 : 527-532; discussion 532-533, 1998
- Kageyama H, Toyooka T, Tsuzuki N, Oka K : Nonsurgical treatment of chronic subdural hematoma with tranexamic acid. *J Neurosurg* 119 : 332-337, 2013
- Kawano N, Suzuki K : Presence of smooth-muscle cells in the subdural neomembrane. *J Neurosurg* 54 : 646-651, 1981
- Nakamura N, Ogawa T, Hashimoto T, Yuki K, Kobayashi S : [Reevaluation on resolving subdural hematoma (author's transl)]. *Neurol Med Chir (Tokyo)* 21 : 491-500, 1981
- Nomura S, Kashiwagi S, Fujisawa H, Ito H, Nakamura K : Characterization of local hyperfibrinolysis in chronic subdural hematomas by SDS-PAGE and immunoblot. *J Neurosurg* 81 : 910-913, 1994
- Park CK, Choi KH, Kim MC, Kang JK, Choi CR : Spontaneous evolution of posttraumatic subdural hygroma into chronic subdural haematoma. *Acta Neurochir (Wien)* 127 : 41-47, 1994
- Parlato C, Guarracino A, Moraci A : Spontaneous resolution of chronic subdural hematoma. *Surg Neurol* 53 : 312-315; discussion 315-317, 2000
- Santarius T, Kirkpatrick PJ, Koliass AG, Hutchinson PJ : Working toward rational and evidence-based treatment of chronic subdural hematoma. *Clin Neurosurg* 57 : 112-122, 2010