

The clinical features, treatment, and prognosis of primary mediastinal malignant melanoma

A case report

ZiHai Li, M.MED^{a,c}, Hui Jia, MD^b, Baijiang Zhang, M.MED^c, Yongming Zhang, M.MED^c, Hui Li, M.MED^c, Pingping Song, MD^{c,*}

Abstract

Rationale: Primary malignant melanoma (MM) of the mediastinum is exceedingly rare; a review of the English-language literature reveals only a small number of case reports. In this paper, we discuss a case of primary mediastinal MM and present a review of the relevant literature on its clinical features and treatment.

Patient concerns: A 52-year-old male presenting with back pain was admitted to our hospital for treatment. Imaging examination revealed an anterior mediastinal mass and no evidence of other metastatic or primary lesions.

Diagnoses: After complete resection by video-assisted thoracoscopic surgery (VATS), histopathologic examination showed evidence of brown melanin pigment in the tumor cells, which were immunohistochemically positive for antimelanoma antibodies (HMB-45, Melan-A, S-100, and Ki67).

Interventions: Given the diagnosis of MM after surgery, the tumor was tested for the mutation in the BRAF gene (which encodes the serine/threonine-protein kinase B-raf) that leads to a V600E amino acid substitution, and the tumor was found to be wild type. Then the patient has been given immunotherapy.

Outcomes: The patient completed 4 cycles of immunotherapy, and no recurrence or metastasis has been detected to date.

Lessons: In such cases, it is difficult to prove the primary nature of the intrathoracic melanoma. Moreover, preoperative identification of this disease is challenging, making misdiagnosis likely. Due to fast progression and poor prognosis, timely and effective systemic treatment is necessary to improve the outcomes for patients with primary mediastinal MM.

Abbreviations: BRAF = serine/threonine-protein kinase B-raf, HMB-45 = human melanoma black-45, Ki67 = nuclear antigen, MM = malignant melanoma, Melan-A = melanoma antigen, S-100 = astroglial protein, VATS = video-assisted thoracoscopic surgery.

Keywords: clinical features, malignant melanoma, primary mediastinal, thoracic surgery, treatment, video-assisted

Editor: Maohua Xie.

A signed written consent was obtained from the patient for this case report. An ethical approval was not necessary because of the routine health care.

This work was supported by the Shandong Province Natural Science Foundation of China to Hui Jia (No. ZR2012HL37) and to Pingping Song (No. ZR2013HL046).

The authors have no conflicts of interest to disclose.

^a School of Medicine and Life Sciences, University of Jinan-Shandong Academy of Medical Sciences, ^b Department of Medical Oncology, ^c Department of Thoracic Surgery, Shandong Cancer Hospital Affiliated to Shandong University, Shandong Academy of Medical Sciences, Jinan, Shandong Province, People's Republic of China.

* Correspondence: Pingping Song, Department of Thoracic Surgery, Shandong Cancer Hospital Affiliated to Shandong University, Shandong Academy of Medical Sciences, Jinan, Shandong Province 250117, People's Republic of China (e-mail: spp128@126.com).

Copyright © 2017 the Author(s). Published by Wolters Kluwer Health, Inc. This is an open access article distributed under the Creative Commons Attribution-NoDerivatives License 4.0, which allows for redistribution, commercial and non-commercial, as long as it is passed along unchanged and in whole, with credit to the author.

Medicine (2017) 96:17(e6436)

Received: 6 November 2016 / Received in final form: 6 February 2017 /

Accepted: 25 February 2017

<http://dx.doi.org/10.1097/MD.0000000000006436>

1. Introduction

Malignant melanoma (MM) is a highly malignant tumor derived from melanocytes, accounting for 1.5% of all malignant tumors.^[1] The pathogenesis of MM is associated with both environmental and genetic factors. Melanoma most commonly occurs in the skin and mucous membranes, while metastatic MM of unknown primary origin accounts for 1% to 8% of all melanomas.^[2] Primary MM of the mediastinum is extremely rare. Previous reports^[1,3–15] indicate an age of onset ranging from 11 to 72 years old, with a mean age of 45 years, a male-to-female ratio of approximately 2:1, and no obvious inherited tendency. Fifty percent of mediastinal masses are anterior.^[9]

MM is thought to originate from neural crest cells during embryonic development^[1,14] and is related to ganglion and Schwann cells, and possibly also residual embryonic neuroectodermal tissue, although another theory of MM origination from transitional stem cells has also been discussed,^[16] hence, the histological origin of mediastinal MM remains unclear at present. A limited number of cases of primary mediastinal MM have been reported. Vlodavsky et al,^[6] reported a rare case of primary MM in the anterior mediastinum of an 11-year-old child, where an aggregation of nevus cells in the thymus or mediastinal lymph

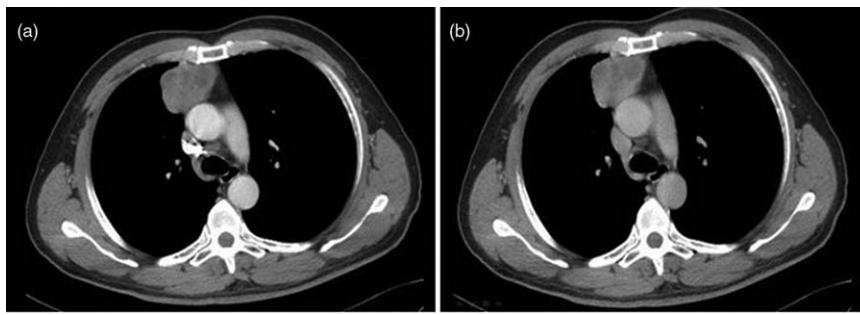


Figure 1. Contrast-enhanced computed tomography (CT) scan revealing a soft tissue density mass lesion on the right side of the anterior mediastinum. (A) Contrast-enhanced image. (B) Delayed CT image. The tumor was lobulated with a cross-section measuring 5.3×4.2 cm. The enhanced scan showed a moderate inhomogeneous mass, with a small area of low density within the tumor. No obvious enlarged lymph nodes were identified in the double hilar artery or mediastinum.

nodes was considered as the origin of disease. In a case of primary MM in the posterior mediastinum, Krausz et al,^[17] postulated origin from a nevus cell aggregate in the mediastinal nodes and sympathetic chain in the posterior mediastinum. McNab et al,^[18] reported the first clinical case of mediastinal MM arising in the respiratory epithelium of a teratomatous germ cell tumor of the mediastinum, considering neuroendocrine cells as the origin of the melanoma arising in the respiratory epithelium; however, Hannan et al^[19] considered that this case could have resulted from transformation of dermal elements, or de-differentiation of germ cells, to melanoma.

2. Case presentation

A 52-year-old male presenting with back pain for a month (no other symptoms) was admitted to our hospital for treatment in April 2016, with no relevant family history and no history of smoking or alcohol use. Physical examination showed an average build with no superficial lymphadenopathy, vitiligo, or pigmentation. A computed tomography scan of the thorax was performed and revealed a soft tissue density mass lesion on the right side of the anterior mediastinum. The tumor was lobulated, with a cross-section measuring 5.3×4.2 cm. An enhanced scan showed a moderate inhomogeneous mass, with a small low-density area within the tumor. No obvious enlarged lymph nodes were found in the double hilar artery or mediastinum (Fig. 1). Extensive clinical and radiological investigation revealed no evidence of other metastatic or primary lesions. Due to a suspicion of thymoma, based on the computed tomography (CT) scan, a resection of the mediastinal tumor and thymus gland was performed under general anesthesia by video-assisted thoracoscopic surgery (VATS) in May 2016, with curative intention. During surgery, the tumor was observed to be located in the right anterior upper mediastinum and found to measure $5 \times 4 \times 3.5$ cm. The surface of the tumor was smooth and uneven, appearing dark black. The tumor was an elastic, hard mass with a complete capsule and had a vague margin with the thymus, which involved the mediastinal pleura. Tumor tissue sections were grayish red, grayish brown, and black, with an inflexible and uniform texture. Anterior mediastinal lymph nodes were approximately 0.3 to 1.0 cm in size and black in color. There was a small pleural adhesion in the right side of the chest cavity, and no metastasis to pleural nodules or pleural effusion was observed.

Histopathologic examination revealed an MM of the mediastinum with tumor-free lymph nodes (0/1). No tumor tissue was found in the thymus. Immunohistochemistry staining revealed

atypical pleomorphic melanocytes with prominent nucleoli and melanin pigment (Fig. 2), confirming a final diagnosis of MM. The tumor cell phenotype was human melanoma black-45 (HMB-45)+, melanoma antigen (Melan-A)+, astroglial protein (S-100)+, cytokeratin (CKpan)+, cellular adhesion molecule 5.2 (CAM5.2)+, and nuclear antigen (Ki67)+ (40%–50%) (Fig. 3).

The tumor was tested after surgery for the mutation in the *BRAF* gene (which encodes the serine/threonine-protein kinase B-raf), that causes the V600E amino acid substitution and found to be negative/wild type. The patient refused chemotherapy and was treated with immunotherapy, using recombinant human interferon $\alpha 2b$ by intramuscular injection 3 times per week, with 2-week cycles. Having completed 4 cycles of immunotherapy, the patient now visits our hospital for routine medical check-ups to allow for early detection of any tumor recurrence. Timeline of diagnostic and therapeutic procedures are summarized in Table 1.

3. Discussion

3.1. Clinical symptoms

The morbidity associated with primary MM of the mediastinum can be hidden, and the majority of its clinical signs and symptoms are nonspecific. Our observations of symptoms of the disease,

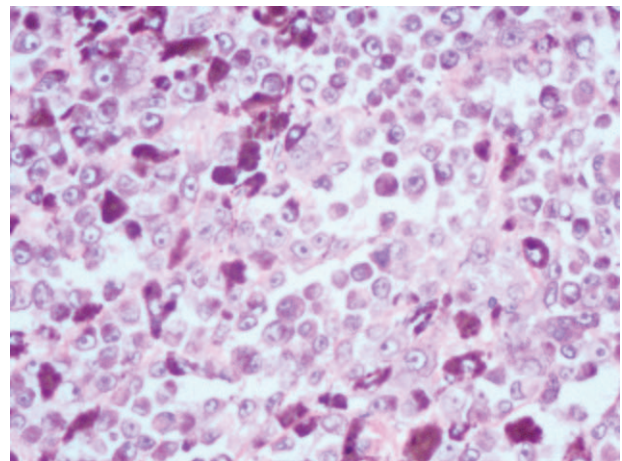


Figure 2. Immunohistochemistry staining showing atypical pleomorphic melanocytes with prominent nucleoli and melanin pigment. Hematoxylin and eosin stain; magnification, $\times 200$.

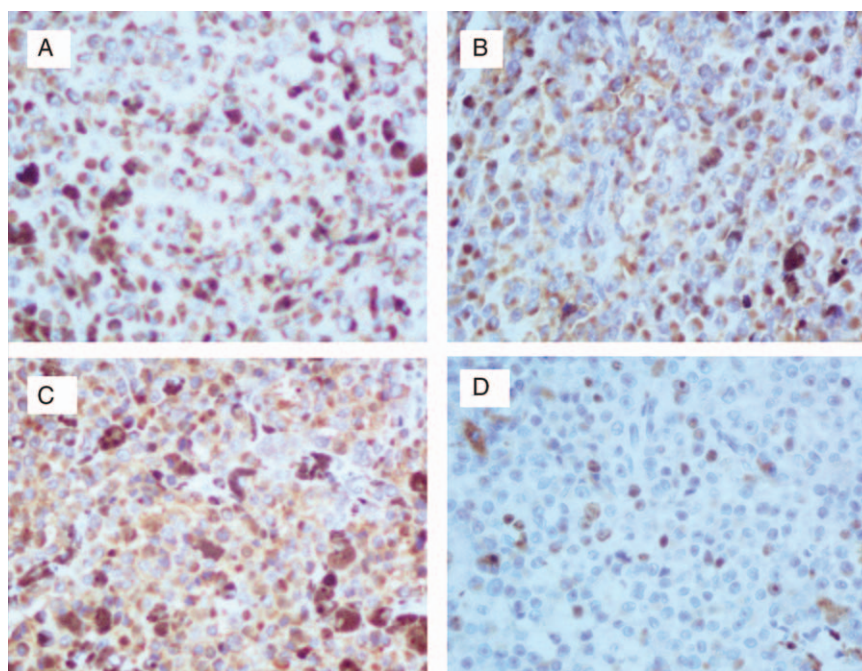


Figure 3. Immunohistochemical analysis demonstrating that tumor cells were positive for (A) HMB-45, (B) Melan-A, (C) S-100, and (D) Ki67 (40%–50%). Streptavidin peroxidase staining; magnification, $\times 200$. HMB-45=human melanoma black-45, Ki67=nuclear antigen, Melan-A=melanoma antigen, MM=malignant melanoma, S-100=astroglial protein.

combined with the relevant literature, can be summarized as follows:

- (1) Local compression symptoms: the constriction of cardiac tissue by a mediastinal tumor can lead to persistent precordial pain^[1]; and if an adjacent bronchus or the esophagus are compressed by the tumor, symptoms of progressive dyspnea and dysphagia are observed.^[1,7,14]
- (2) Local invasion symptoms: when a tumor invades the thymus, it can lead to symptoms of myasthenia gravis; invasion of the recurrent laryngeal nerve or the superior laryngeal nerve can result in a hoarse voice or a cough during drinking^[8,9]; superior vena cava syndrome occurs when tumors invade the superior vena cava^[10,11]; and when the pleura is involved, chest and back pain occurs, as observed in the case detailed in this paper.

3.2. Imaging features

Noncutaneous MM presents as a lump or nodular lesion on imaging, with occasional local lymph node enlargement, and adjacent tissues and organs are frequently involved. Generally,

Table 1

Timeline.

2016.03–2016.04: back pain (no other symptoms)
2016.04.25: Suspicion of thymoma based on the CT scan
2016.05.04: Performed resection of the mediastinal tumor and thymus gland by VATS
2016.05.09: Histopathologic examination revealed an MM of the mediastinum
2016.06.14–2016.10.07: Completed 4 cycles of immunotherapy
2016.10-up to now: No local recurrence has been detected

CT=computed tomography, MM=malignant melanoma, VATS=video-assisted thoracoscopic surgery.

such tumors have no obvious specific features, other than concealment and invasion. Chest X-ray often reveals a large volume mediastinal lump occupying a widened mediastinum, which can be obtuse and convex relative to the lung. In CT images, the tumor presents as a single, large focus. Enhanced scan reveals a significant, inhomogeneous mass. CT images can also reveal the degree of vascularization and the anatomical relationships between the mass and the mediastinal structure.^[20] Occasionally, X-ray barium meal examination or CT images acquired under endoscopy reveal signs of esophageal or adjacent trachea constriction by the tumor, without mucosal invasion, excluding the possibility of primary esophageal or intratracheal lesions.^[7,14] MRI examination provides more specific information in primary mediastinal MM. The mass appears mildly hyperintense relative to muscle on T1-weighted images and heterogeneously hypointense relative to muscle on T2-weighted images. When correlated with pathology findings, the focal areas of T1 hyperintensity and T2 hypointensity are found to be composed of melanocytes, rich with melanin granules.^[12] Whole body [18F]fluorodeoxyglucose-positron emission tomography scan is also a useful imaging method for the evaluation of various primary mediastinal masses and distant metastases; however, diagnosis is rarely established prior to biopsy or surgery.^[20] Park et al,^[1] reported a case of primary mediastinal MM with a high standardized uptake value (16.8) through PET/CT, while Xing et al^[21] confirmed that PET/CT is the most accurate imaging modality in screening for distant metastases of MM, with sensitivity and specificity both >95%.

3.3. Diagnosis and differential diagnosis

There are no obvious specific clinical or imaging manifestations of primary mediastinal MM; therefore, preoperative diagnosis of this disease is difficult, and misdiagnosis likely. Hence, final

diagnosis is still based on percutaneous or surgical biopsy. A case of primary mediastinal small cell melanoma diagnosed by endobronchial ultrasound-guided transbronchial needle aspiration has been reported.^[13] Relevant reports have demonstrated that the acquisition of pathological tissue samples by chest CT guided percutaneous aspiration biopsy and endobronchial ultrasound-guided transbronchial needle aspiration is an effective method for the diagnosis of primary mediastinal MM^[7,11,14]; however, noncutaneous MM is typically heterogeneous and biologically diverse, and its broad spectrum of histological features makes morphological diagnosis challenging. A case of primary mediastinal MM misdiagnosed as spindle cell thymoma after fine-needle aspiration cytology was reported.^[22] Given the deep position of the mediastinal mass, puncture biopsy poses a high risk of causing tumor dissemination; therefore, surgical pathology remains necessary for final diagnoses.

Compared with the traditional operative approach of thoracotomy or a T-shaped transverse incision of the neck and splitting of the sternum, we present a case of primary mediastinal MM that was treated by VATS. In this way, a complete resection of the mediastinal mass and thymus tissue was performed, and a clear pathological diagnosis was easily obtained. This approach has the advantage of producing a relatively small wound, and good healing and rapid recovery were achieved; the physical function of the patient was completely recovered on the 7th day postoperation. Hence, VATS has clear advantages for the diagnosis and treatment of mediastinal tumors.

Mediastinal tumors account for 50% of mediastinal masses^[23] and the most common primary mediastinal tumors include thymoma, teratoma, and lymphoma. Histopathological features and immunohistochemical staining are helpful for the diagnosis of this disease and are also the primary means to identify other MM tumors. Histologically, primary MM exhibits significant heterogeneity, with a growth pattern consisting of isolated clusters and the pathological features of mediastinal MM are the same as those of MM tumors in other parts of the body. The main features observed by light microscopy of tumor tissue sections include a large number of spindle shaped cells and coarse pigment granules. The tumor cells can be arranged in nests, sheets, and cords, and exhibit obvious cellular atypia, with cells ranging in size and morphology, including rounded or polygonal cells with distinct boundaries, abundant and red-stained cytoplasm, melanin granules in the cytoplasm, centered or deviated nuclei, clearly identifiable nucleoli, and apparent pathological mitosis. There are abundant vessels among the extracellular matrix. The immune phenotype is investigated using the monoclonal antibody, S-100, which is the most sensitive marker for melanoma; however, it has low specificity, while HMB-45 can identify melanoma cells with a high specificity, and Ki67 is the most useful marker for differentiating benign from MM. Combined with Melan-A, these markers can effectively prevent misdiagnosis.

Accurate diagnosis helps to evaluate patients and avoid unnecessary surgery when the tumor represents a metastasis to the mediastinum derived from a primary malignancy elsewhere in the body. As the primary site of MM can be occult and varied, the primary nature of intrathoracic melanoma is difficult to prove. Differentiation of primary from metastatic mediastinal MM needs to be ruled out by determination of whether there is black pigmentation in any area of skin or mucous membranes of the whole body, or a history of any prior surgical resection of a mole, and exclusion of the possibility of primary MM in other organs.^[14] In the present case, imaging indicated an isolated

mediastinal mass with no evidence of primary melanoma in other organs. No pigmentation of the skin or mucous membranes of the patient's whole body was observed on preoperative physical examination. Histopathologic examination revealed an MM immunohistochemically positive for HMB-45, Melan-A, S-100, and Ki67, allowing clear diagnosis as a primary mediastinal MM.

3.4. Treatment and prognosis

There is no consensus regarding the treatment of metastatic mediastinal or primary mediastinal MM; therefore, current treatment guidelines for cutaneous melanoma are generally followed. If possible, complete surgical resection to reduce the tumor mass is advocated for patients with early stage disease, before chemotherapy or radiotherapy.^[1,7,8] Due to high-grade malignancies, the high degree of invasiveness of primary mediastinal MM, and the morbidity concealment typical of the disease, the majority of clinical reports are of advanced cases with clear external invasion of the tumors; hence, the resection rate of this disease is generally low.

Although chemotherapy or radiation therapy can be used to treat advanced MM,^[8,15] Dacarbazine is only proven to have a 3.7% rate of effectiveness as 1st-line chemotherapy.^[24] Radiotherapy has been administered to control the local spread of melanoma, but does not prolong survival rates.^[25] Given the clear immunogenicity of MM, immunotherapy is considered the most promising current treatment. Research to develop small molecule targeting drugs has greatly improved the survival rate of patients with MM and is a topic of intense investigation. The cytokines interleukin 2 and interferon alpha were the earliest immune agents to be approved by the U.S. Food and Drug Administration for the treatment of unresectable or metastatic MM. In recent years, the use of immune regulatory antibodies has been a breakthrough in the immunotherapy of MM. An antibody (ipilimumab) targeting cytotoxic T lymphocyte-associated antigen 4 (CTLA-4) was also approved by the U.S. Food and Drug Administration for the treatment of metastatic MM in March 2011, and its use significantly improves overall patient survival.^[26] Pembrolizumab and nivolumab, drugs targeting programmed death protein-1, which are expected to be approved for the treatment of metastatic MM in the near future, have also shown to produce high and persistent objective response rates when applied in the clinic.^[27] The B-Raf protein, a serine/threonine protein kinase involved cell signaling to regulate cell growth, is an important target for therapy in MM, as the *BRAF* gene frequently harbors mutations in exon 15, leading to amino acid substitutions at position 600. About half of all primary and metastatic MMs have *BRAF* mutations, with the V600E substitution (which is associated with ultraviolet radiation and intermittent sun exposure) accounting for 80% of *BRAF*-mutated melanomas; a V600K mutation is found in 10% to 20% of remaining cases.^[28,29] Dabrafenib and vemurafenib, oral targeted *BRAF*-V600E inhibitors, have been approved for the treatment of advanced MM patients or those where surgery is not indicated, who carry the V600E *BRAF* mutation, and these drugs have demonstrated some therapeutic effect in clinical application.^[27,30]

The long-term survival rates of patients with primary mediastinal MM remain unpredictable. Existing case reports indicate that the majority of patients die of short-term and noncontrolled systemic multiple metastases within a year, indicating that treatment with effective medication, combined with surgery, can improve the condition of patients, but cannot effectively improve survival rates. Considering that previous reports have primarily concerned patients with advanced disease,

their effective treatment was limited. Unfortunately, there are no reports regarding the effectiveness of immunotherapy and targeted therapy in the treatment of this disease to date.

4. Conclusion

Primary mediastinal MM is a rare tumor of uncertain histogenesis, associated with morbidity concealment. With no specific clinical manifestations or imaging features, preoperative diagnosis of this disease is difficult and it is easily misdiagnosed. Immunohistochemical examination is the main method to distinguish primary mediastinal MM from other tumors. The histopathological features of mediastinal MM are the same as those of MM in other parts of the body, and extensive clinical and radiological investigation to rule out possible metastases, and to search for another potential primary tumor, is essential. Despite the low chances of cure, if possible, complete surgical resection to reduce the tumor mass is advocated for early stage patients before chemotherapy or radiotherapy. With a fast progression and poor prognosis, timely and effective systemic treatment is necessary to improve the survival rates of patients with advanced disease. Immunotherapy and targeted therapy are the most promising treatments for unresectable or advanced stage patients; however, their effectiveness is unknown due to the rarity of the disease and evidence from additional clinical cases is required.

Acknowledgments

The authors thank Shandong Province Natural Science Foundation of China to Hui Jia (No. ZR2012HL37) and to Pingping Song (No. ZR2013HL046) for the support.

References

- [1] Park SY, Kim MY, Chae EJ. Primary malignant melanoma of the mediastinum: radiologic and pathologic correlation in two cases. *Korean J Radiol* 2012;13:823–6.
- [2] Cormier JN, Xing Y, Feng L, et al. Metastatic melanoma to lymph nodes in patients with unknown primary sites. *Cancer* 2006;106:2012–20.
- [3] Feldman L, Kricun M. Malignant melanoma presenting as a mediastinal mass. *JAMA* 1979;241:396–7.
- [4] Cordina E, Assouline PS, Krespine C, et al. Primary malignant mediastinal melanoma. Apropos of a case. *Rev Pneumol Clin* 1997;53:203–6.
- [5] Pandya B, Ramraje S, Darade A. Primary malignant melanoma of the mediastinum. *J Assoc Physicians India* 2004;52:924–5.
- [6] VLodavsky E, Ben-Izhak O, Best LA, et al. Primary malignant melanoma of the anterior mediastinum in a child. *Am J Surg Pathol* 2000;24:747–9.
- [7] Kalra A, Kalra A, Palaniswamy C, et al. Primary malignant melanoma presenting as superior mediastinal mass. *Int J Surg Case Rep* 2011;2:239–40.
- [8] Karuppiyah SV, Buchan KG. Primary malignant melanoma; a rare cause of mediastinal mass. *Jpn J Thorac Cardiovasc Surg* 2006;54:396–8.
- [9] Youn HC. A primary malignant melanoma of the mediastinum with gross surgical view. *J Thorac Dis* 2016;8:E133–6.
- [10] Shishido M, Nagao N, Miyamoto K. Mediastinal amelanotic melanoma presenting as superior vena cava syndrome. *Nihon Kyobu Shikkan Gakkai Zasshi* 1997;35:240–4.
- [11] Lau CL, Bentley RC, Gockerman JP, et al. Malignant melanoma presenting as a mediastinal mass. *Ann Thorac Surg* 1999;67:851–2.
- [12] Takao H, Shimizu S, Doi I, et al. Primary malignant melanoma of the anterior mediastinum: CT and MR findings. *Clin Imaging* 2008;32:58–60.
- [13] Fernandez-Bussy S, Labarca G, Castro A, et al. Primary mediastinal small cell melanoma achieved by EBUS-TBNA. *Thorax* 2016;71:387.
- [14] Meacci E, Mule A, Cesario A, et al. Posterior mediastinal melanoma causing severe dysphagia; a case report. *J Med Case Rep* 2008;2:316.
- [15] Kim HR, Lee JS, Kim YT, et al. Primary malignant melanoma presenting as an anterior mediastinal mass. *Korean J Thorac Cardiovasc Surg* 2002;35:697–700.
- [16] Schatton T, Frank MH. Cancer stem cells and human malignant melanoma. *Pigment Cell Melanoma Res* 2008;21:39–55.
- [17] Krausz T, Azzopardi JG, Pearse E. Malignant melanoma of the sympathetic chain: with a consideration of pigmented nerve sheath tumours. *Histopathology* 1984;8:881–94.
- [18] McNab P, Quigley B, Mendoza T, et al. The histogenic origin of melanoma arising in respiratory epithelium of a teratomatous germ cell tumor of the mediastinum: an enigma unraveled from an unlikely source. *Int J Clin Exp Pathol* 2012;5:982–90.
- [19] Hannan A, Akhter N, Kazmi AS, et al. Secondary malignant melanoma in primary mediastinal germ cell tumour. *J Pak Med Assoc* 2015;65:98–100.
- [20] Juanpere S, Cañete N, Ortuño P, et al. A diagnostic approach to the mediastinal masses. *Insights Imaging* 2013;4:29–52.
- [21] Xing Y, Bronstein Y, Ross MI, et al. Contemporary diagnostic imaging modalities for the staging and surveillance of melanoma patients: a meta-analysis. *J Natl Cancer Inst* 2011;103:129–42.
- [22] Bavi P, Shet T, Gujral S. Malignant melanoma of mediastinum misdiagnosed as a spindle cell thymoma in a fine needle aspirate: a case report. *Acta Cytol* 2005;49:424–6.
- [23] Trousse D, Avaro JP. Mediastinal tumors: introduction. *Rev Pneumol Clin* 2010;66:13–6.
- [24] Cui C, Mao L, Chi Z, et al. A phase II, randomized, double-blind, placebo-controlled multicenter trial of Endostar in patients with metastatic melanoma. *Mol Ther* 2013;21:1456–63.
- [25] Bastiaannet E, Beukema JC, Hoekstra HJ. Radiation therapy following lymph node dissection in melanoma patients: treatment, outcome and complications. *Cancer Treat Rev* 2005;31:18–26.
- [26] Maio M, Grob JJ, Aamdal S, et al. Five-year survival rates for treatment-naïve patients with advanced melanoma who received ipilimumab plus dacarbazine in a phase III trial. *J Clin Oncol* 2015;33:1191–6.
- [27] Philips GK, Atkins M. Therapeutic uses of anti-PD-1 and anti-PD-L1 antibodies. *Int Immunol* 2015;27:39–46.
- [28] Zebary A, Omholt K, Vassilaki I, et al. KIT, NRAS, BRAF and PTEN mutations in a sample of Swedish patients with acral lentiginous melanoma. *J Dermatol Sci* 2013;72:284–9.
- [29] Bradish JR, Cheng L. Molecular pathology of malignant melanoma: changing the clinical practice paradigm toward a personalized approach. *Hum Pathol* 2014;45:1315–26.
- [30] Lu AY, Patel AR, Kuzmik GA, et al. Brainstem melanomas presenting as a cavernous malformation. *Neurochirurgia* 2014;60:184–7.