

Foregut duplication cyst: a novel computed tomography finding mimicking a small bowel hernia

A case report

Ji Eun Choi, MD^a, Soyeoun Lim, MD^{a,*}, Chang Ryul Park, MD, PhD^b, Hee Jeong Cha, MD, PhD^c, Woon-Jung Kwon, MD, PhD^a

Abstract

Rationale: A foregut duplication cyst (FDC) is an uncommon congenital disease. This report presents a case of mediastinal foregut duplication cyst that mimicked a diaphragmatic small bowel hernia.

Patient concern: A 27-month-old girl was first referred for a mediastinal lesion found incidentally on a chest radiograph. At that time, our impression was cystic lung lesion such as congenital pulmonary airway malformation or pulmonary sequestration. At the age 6 years, she presented with recurrent vomiting. The physical examination and laboratory studies were within normal limits.

Diagnoses: Chest CT revealed a thin- and smooth-walled cystic mass containing an air-fluid level in the left paravertebral space. It had several inner circular folds and characteristic double-layer enhancement and inner circular fold. Our radiological impression was a type I congenital cystic adenomatoid malformation.

Interventions: The patients undergone video-assisted thoracoscopic surgery for excision. The operative finding was the cystic mass with smooth bowel-like outer surface and located between the aorta and heart. The cyst was excised and confirmed to be a foregut duplication cyst pathologically.

Outcomes: The patient was doing well with no postoperative complications during follow-up. Recurrent vomiting was improved. This is the first case report describing foregut duplication cyst mimicking a small bowel hernia.

Lessons: Foregut duplication cysts are rare congenital anomalies of primitive foregut origin. They can occur at any level of the alimentary track and comprise approximately 10% of all mediastinal tumors. Its characteristic double-layered histopathological nature, an FDC can show a double-layered enhancement pattern, which is typical in the alimentary tract.

Abbreviations: FDC = Foregut duplication cyst, CT = computed tomography.

Keywords: CT finding, foregut duplication cyst, mimicking a small bowel hernia

1. Introduction

Foregut duplication cysts (FDCs) are rare congenital anomalies of primitive foregut origin that arise during early embryonic development. FDCs comprise approximately 10% of all mediastinal tumors.^[1] FDCs are mostly diagnosed in neonates and infants,

with a slight male preponderance.^[2] They can occur at any level of the alimentary track. Computed tomography (CT) is widely used as a modality for the evaluation and diagnosis of duplication cysts.

2. Case report

A 6 year-old girl was first referred to our institution for a mediastinal lesion found incidentally on a chest radiograph at the age of 27 months. She was born healthy at full-term with a birth weight of 3400 g via caesarean section without complications during pregnancy or the delivery. At the age 6 years, she presented with recently developed recurrent vomiting. The physical examination was unremarkable and laboratory studies, including the hematological profile and serum chemistry, were within normal limits. She was again referred to us for further evaluation of the known mediastinal mass.

The chest radiograph showed a 4.2-cm-long, ovoid, thin-walled lesion in the left paravertebral space (Fig. 1). Chest CT at that time revealed a thin- and smooth-walled cystic mass containing an air-fluid level in the left paravertebral space. The cystic lesion had several inner circular folds like valvulae conniventes (Fig. 2). The inferior tip was located between the thoracic spine and left diaphragm crus. On CT, we could not find a communication between the lesion and abdominal cavity or

Editor: N/A.

The authors have no funding and conflicts of interest to disclose.

^a Department of Radiology, ^b Thoracic and Cardiovascular Surgery, ^c Pathology of Ulsan University Hospital, University of Ulsan College of Medicine, Ulsan, Republic of Korea.

* Correspondence: Soyeoun Lim, Department of Radiology, Ulsan University Hospital, University of Ulsan College of Medicine, Ulsan, Republic of Korea (e-mail: soyeoun.lim.xr@gmail.com).

Copyright © 2017 the Author(s). Published by Wolters Kluwer Health, Inc. This is an open access article distributed under the terms of the Creative Commons Attribution-Non Commercial License 4.0 (CCBY-NC), where it is permissible to download, share, remix, transform, and buildup the work provided it is properly cited. The work cannot be used commercially without permission from the journal.

Medicine (2017) 96:50(e9184)

Received: 14 September 2017 / Received in final form: 16 November 2017 /

Accepted: 18 November 2017

<http://dx.doi.org/10.1097/MD.0000000000009184>

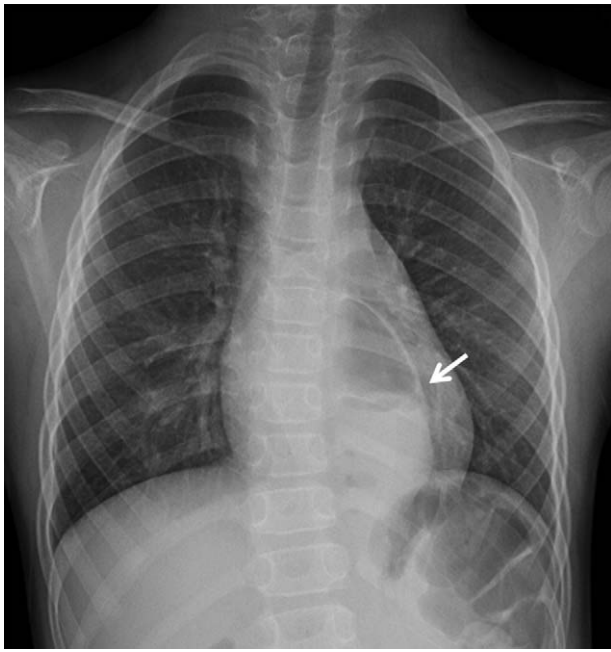

Figure 1. Chest radiograph image of a 6 year-old child who recently developed recurrent vomiting. A 7 × 3 cm sized oval mass-like lesion with internal air-fluid level is located in the posterior paravertebral region (arrow).

bowel loop. Our first radiological impression was a type I congenital cystic adenomatoid malformation because of its internal unilocular air density, or a variation of Bochdalek hernia because of its location and characteristic inner-wall enhancement. Endoscopy was performed to look for a communication between the mass and esophagus, but none was found.

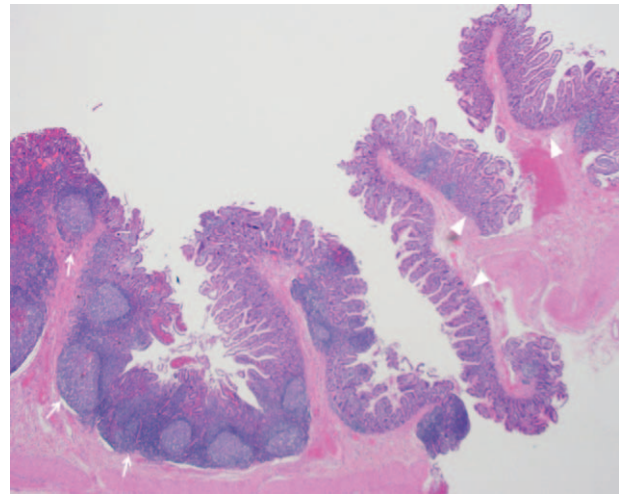


Figure 3. Microphotograph of the foregut duplication cyst showing the double-layered intestinal wall with normal intestinal mucosa (terminal ileal mucosal layer with Peyer's patch on the left side (arrow) and the jejunal mucosal layer on the right side (arrowhead)) within the muscularis (hematoxylin & eosin, 1.25×).

The patient underwent video-assisted thoracoscopic surgery. The cystic mass was located between the aorta and heart, measured 9 cm in length and 5.5 cm in diameter, and had a smooth, bowel-like outer surface and inner circular folds that looked like valvulae conniventes. No definite connection was found between the mass and any intrathoracic organ. The inferior end of the cystic lesion was not found at surgery, so we could not confirm communication with the abdominal cavity. Histopathological examination of the tissue confirmed an enteric duplication cyst (Fig. 3). The patient was doing well at follow-up with no

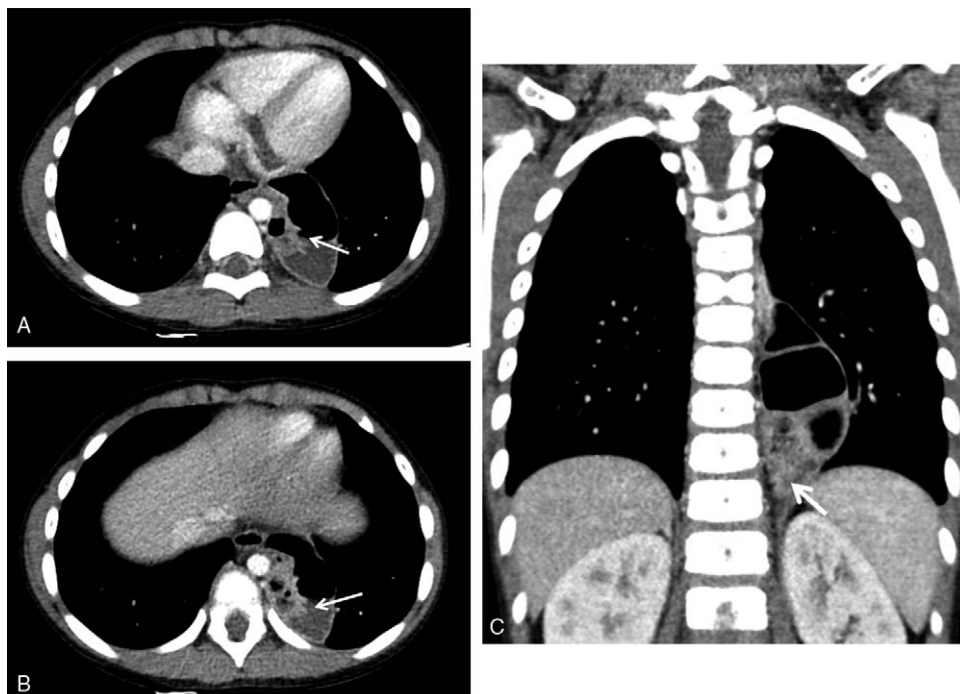

Figure 2. Computed tomography images (A, B) axial, (C) coronal planes of a mediastinal cyst in a 6 year-old child. Note that the cyst with its inner circular fold and double-layered enhancement suggests a bowel-like cystic lesion (arrows).

complications. Ethics approval was not required for this paper as it is a case report.

3. Discussion

FDCs mainly arise at 1 of 3 sites: the enteric portion of the foregut (dorsal); respiratory portion of the foregut (ventral); or an accessory lung bud, which usually occurs caudal to the normal lung bud.^[3] They can occur at any level of the alimentary track. FDCs may contain respiratory-type epithelium. Histologically, an FDC is characterized by a double-layered outer muscular layer with an inner lining of gastrointestinal mucosa, though the exact type varies from case to case.

CT is best for evaluating the shape, extent, and relationship with surrounding structures,^[4] but the detection and diagnosis of enteric cysts itself can still be difficult because the mass can appear as a nonspecific nonenhancing or slightly enhancing one-layered cystic lesion.^[5] In our case, however, the FDC presented like herniated bowel instead of a cystic mass. This CT finding might be confused with the delayed presentation of a congenital diaphragmatic hernia such as a Bochdalek hernia. With a suspected diaphragmatic hernia with no definite evidence of communication between it and the small bowel in the abdominal cavity, radiologists must include FDC in the differential diagnosis. Because of its double-layered histopathological nature, an FDC can show a double-layered enhancement pattern, which is typical in the alimentary tract.

The treatment of choice for enteric duplication cysts is complete surgical excision. In patients with these anomalies,

an early accurate diagnosis is essential, because subsequent appropriate surgical treatment can lead to a satisfactory outcome.

We presented this case because, as far as we know, no reported FDC has had characteristic CT findings that include the inner circular folds that mimic valvulae conniventes and two-layered enhancement like the intestinal wall.

4. Conclusion

It is important to include FDC in the differential diagnosis of a pediatric intrathoracic cystic mass with characteristic layered enhancement.

References

- [1] Birmole BJ, Kulkarni BK, Vaidya AS, et al. Intrathoracic enteric foregut duplication cyst. *J Postgrad Med* 1994;40:228–30.
- [2] Anagnostou E, Soubasi V, Agakidou E, et al. Mediastinal gastroenteric cyst in a neonate containing respiratory-type epithelium and pancreatic tissue. *Pediatr Pulmonol* 2009;44:1240–3.
- [3] Sharma S, Nezakatgoo N, Sreenivasan P, et al. Foregut cystic developmental malformation: new taxonomy and classification—unifying embryopathological concepts. *Indian J Pathol Microbiol* 2009; 52:461–72.
- [4] Fitch SJ, Tonkin IL, Tonkin AK. Imaging of foregut duplication cysts. *Radiographics* 1986;6:189–201.
- [5] Baumann JL, Patel C. Enteric duplication cyst containing squamous and respiratory epithelium: an interesting case of a typically pediatric entity presenting in an adult patient. *Case Rep Gastrointest Med* 2014; 2014:790326.