



Multisystem inflammatory syndrome in children (MIS-C) without antecedent clinical symptoms related to COVID-19: The increasing importance of distinguishing MIS-C in patients with Kawasaki disease-like features

Masato Ozaki^a, Tomohiro Hori^{a,b,*}, Yuki Miwa^a, Takahiro Yamamoto^a, Kazuo Kubota^{a,b}, Minako Kawamoto^a, Norio Kawamoto^a and Hidenori Ohnishi^{a,b}

^aDepartment of Pediatrics, Graduate School of Medicine, Gifu University, Gifu, Japan

^bClinical Genetics Center, Gifu University Hospital, Gifu, Japan

*Correspondence: Tomohiro Hori; hor-gif@umin.org; Department of Pediatrics, Graduate School of Medicine, Gifu University, 1-1 Yanagido, Gifu 501-1194, Japan.

Dear Editor,

Severe acute respiratory syndrome coronavirus 2 (SARS-CoV-2) infections in most children result in an asymptomatic or milder course of coronavirus disease 2019 (COVID-19) compared with infections in adults [1]. However, SARS-CoV-2 infection in children may rarely result in hyperinflammatory features similar to Kawasaki disease (KD) and toxic shock syndrome, known as ‘multisystem inflammatory syndrome in children’ (MIS-C). We report a Japanese case of MIS-C without antecedent clinical symptoms related to COVID-19.

A 9-year-old Japanese boy presented to our hospital because he had a fever 3 days prior to his visit, after which he developed conjunctival hyperaemia, redness of the lips (Figure 1(a)), and diarrhoea. He was not vaccinated against SARS-CoV-2, and he had no apparent history of illness and no respiratory symptoms or fever suggestive of COVID-19 within the preceding few months. He had not knowingly had close contact with anyone with COVID-19. However, approximately 3 weeks before the onset of fever, the numbers of cases of SARS-CoV-2 infection both in Japan as a whole and the prefecture in which he lived were at their highest since the beginning of the pandemic. (Eighteen days before the onset of his illness, the 7-day rolling average number of new daily cases of SARS-CoV-2 infection per 100,000 population was 18.3 in Japan and 16.3 in his prefecture.) The course of his clinical and laboratory findings is summarised in Figure 1(b). At the time of admission, his blood pressure was 99/60 mm Hg, heart rate 146–153 beats/minute, and body temperature 39.8–41.0°C. His laboratory findings showed evidence of an inflammatory response (including high concentrations of the pro-inflammatory cytokines interleukin-6, interleukin-18, and tumour necrosis factor- α), hyponatraemia, hypoalbuminaemia, elevated hepatic enzymes, elevated N-terminal pro-brain natriuretic peptide, thrombocytopenia, elevated urinary β 2-microglobulin,

urinary occult blood, and proteinuria. Bacterial culture was negative. Echocardiography showed no wall motion abnormalities and no coronary artery abnormalities. Chest and abdominal computed tomography findings were normal. On the fifth day of fever, nasopharyngeal reverse transcription-polymerase chain reaction (PCR) testing for SARS-CoV-2 was positive, and SARS-CoV-2 immunoglobulin testing showed negative IgM and positive IgG antibodies (serum quantitative IgG level: 1636 AU/mL; Abbott SARS-CoV-2 IgG II Quant assay; detection threshold: ≥ 50 AU/mL). Therefore, we diagnosed COVID-19-associated MIS-C in accordance with both the World Health Organization and the US Centers for Disease Control and Prevention diagnostic criteria. We administered 2 g/kg of intravenous immunoglobulin, and 60 mg/day of intravenous prednisolone, with intravenous remdesivir and oral antithrombotic therapy (flurbiprofen and subsequently, aspirin). On the day after beginning these treatments, his fever and all clinical symptoms disappeared. He had received remdesivir treatment for 5 days. The dose of prednisolone was tapered and stopped after 23 days, at which time, all laboratory findings had improved. During his clinical course, he had no other evidence of KD, such as cervical lymphadenopathy, exanthema, and subendothelial oedema, and had not been hypotensive or in shock. One month after onset, no flare-ups or development of new symptoms, and no cardiac or coronary artery abnormalities were observed.

Recently, several COVID-19-related MIS-C patients were reported in Japan [2]. MIS-C resembles KD, toxic shock syndrome, and secondary haemophagocytic lymphohistiocytosis/macrophage activation syndrome [3, 4]. It is well known that children of Asian or Pacific Island descent, such as Japanese children, have higher rates of KD. Therefore, especially in these regions, it is very important to distinguish between MIS-C and KD. Currently, the key differences between MIS-C and KD are considered the following: (1) MIS-C commonly affects older children and adolescents,

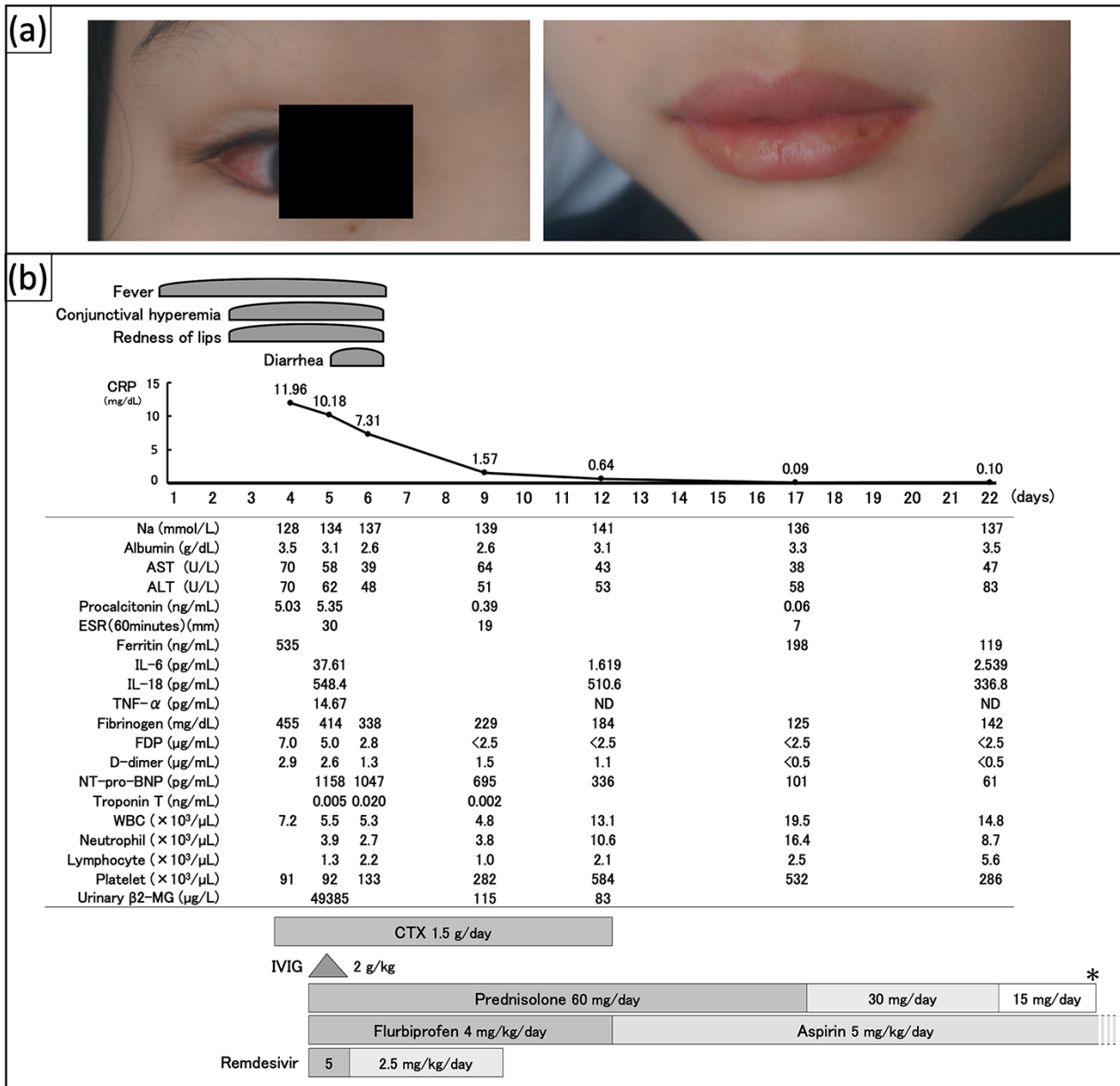


Figure 1. (a) The patient's presentation on admission (on the fourth day of fever). Conjunctival hyperaemia and redness of the lips are seen. (b) The patient's clinical course.

*Prednisolone therapy was stopped on the 27th day of fever. CRP: C-reactive protein; Na: sodium; AST: aspartate aminotransferase; ALT: alanine aminotransferase; ESR: erythrocyte sedimentation rate; IL: interleukin; TNF: tumour necrosis factor; ND: not detected; FDP: fibrin/fibrinogen degradation products; NT-pro BNP: N-terminal pro-brain natriuretic peptide; WBC: white blood cells; β 2 MG: β 2-microglobulin; CTX: cefotaxime; IVIG: intravenous immunoglobulin.

whereas KD typically affects infants and young children [4]. (2) Gastrointestinal symptoms are very common in MIS-C [4]. (3) Myocardial dysfunction and shock occur more commonly in MIS-C compared with KD [4, 5]. (4) Inflammatory markers (especially C-reactive protein, ferritin, and D-dimer) tend to be higher, and absolute lymphocyte and platelet counts tend to be lower in MIS-C compared with KD [4, 6, 7]. The above clinical features can help distinguish MIS-C with KD-like features from KD, but ultimately, designating MIS-C versus KD is based on SARS-CoV-2 testing and exposure history. In a report from the USA, the MIS-C incidence was 316 persons per one million SARS-CoV-2 infections in persons younger than 21 years of age [8]. Among the MIS-C patients,

58.2% were admitted for intensive care and 1.4% died [9]. For patients with an onset of COVID-19 at least 7 days before MIS-C onset, the median (interquartile range) number of days before MIS-C onset was 27 (21–36) days [9]. Furthermore, the geographic and temporal occurrence of MIS-C peaks followed the COVID-19 peaks by 2–5 weeks, and many of the MIS-C patients had IgG positivity [9]. These facts suggested that MIS-C was a delayed immunological phenomenon associated with inflammation following SARS-CoV-2 infection (so called “hyperinflammation phase of COVID-19”) [3]. Therefore, a previous history of COVID-19 within the past several weeks is important for the diagnosis of MIS-C. However, according to a meta-analysis, the overall estimate of the

proportion of people who become infected with SARS-CoV-2 and remain asymptomatic throughout infection was 20% [1]. Furthermore, in studies of hospitalised children, the frequency of asymptomatic SARS-CoV-2 infections was higher (27%) than in adults (11%) [1]. Thus, the existence of asymptomatic SARS-CoV-2 infections may make the diagnosis of MIS-C even more difficult. In fact, the reported detection rate of SARS-CoV-2 by PCR in MIS-C patients was approximately 34% [4]. In our case, because the SARS-CoV-2 PCR test result was positive, and the SARS-CoV-2 antibody test results indicated IgM-negative and IgG-positive, we diagnosed MIS-C caused by an asymptomatic SARS-CoV-2 infection that was contracted a few weeks earlier. To the best of our knowledge, our report is the first Japanese case of MIS-C without antecedent clinical symptoms related to COVID-19. To distinguish MIS-C from other hyperinflammatory conditions, such as KD, and to provide early and rapid diagnosis and treatment, the combination of SARS-CoV-2 PCR and antibody tests are essential. However, as the COVID-19 pandemic evolves or as more children receive the SARS-CoV-2 vaccine, distinguishing KD-like MIS-C patients from true KD patients who have positive SARS-CoV-2 antibodies will be difficult. As in our case, higher quantitative IgG levels may help make the distinction [10]. In the future, it will be extremely important to collect MIS-C cases for each ethnic group and summarise their clinical characteristics and biomarkers. Furthermore, additional laboratory markers or diagnostic methods need to be developed.

In conclusion, it is essential to distinguish MIS-C in patients with KD-like features, regardless of the presence or absence of antecedent COVID-19-related symptoms.

Conflict of interest

None.

Funding

None declared.

Patient consent

The authors have written permission from the patient's parents to report this case.

Ethical approval

Not Applicable.

References

- [1] Buitrago-Garcia D, Egli-Gany D, Counotte MJ *et al.* Occurrence and transmission potential of asymptomatic and presymptomatic SARS-CoV-2 infections: a living systematic review and meta-analysis. *PLoS Med* 2020;17:e1003346.
- [2] Fukuda S, Kaneta M, Miyake M *et al.* A case of multisystem inflammatory syndrome in children in a Japanese boy: with discussion of cytokine profile. *Mod Rheumatol Case Rep* 2021;5:442–7.
- [3] Nakra NA, Blumberg DA, Herrera-Guerra A *et al.* Multi-system inflammatory syndrome in children (MIS-C) following SARS-CoV-2 infection: review of clinical presentation, hypothetical pathogenesis, and proposed management. *Children (Basel)* 2020;7:69.
- [4] Son MBE, Friedman K. COVID-19: Multisystem Inflammatory Syndrome in Children (MIS-C) Clinical Features, Evaluation, and Diagnosis. *UpToDate [Internet]*. <https://www.uptodate.com/contents/covid-19-multisystem-inflammatory-syndrome-in-children-mis-c-clinical-features-evaluation-and-diagnosis/> (19 November 2021 date last accessed).
- [5] Feldstein LR, Rose EB, Horwitz SM *et al.* Multisystem inflammatory syndrome in U.S. children and adolescents. *N Engl J Med* 2020;383:334–46.
- [6] Whittaker E, Bamford A, Kenny J *et al.* Clinical characteristics of 58 children with a pediatric inflammatory multisystem syndrome temporally associated with SARS-CoV-2. *JAMA* 2020;324:259–69.
- [7] Henderson LA, Canna SW, Friedman KG *et al.* American college of rheumatology clinical guidance for multisystem inflammatory syndrome in children associated with SARS-CoV-2 and hyperinflammation in pediatric COVID-19: version 1. *Arthritis Rheumatol* 2020;72:1791–805.
- [8] Payne AB, Gilani Z, Godfred-Cato S *et al.* Incidence of multisystem inflammatory syndrome in children among US persons infected with SARS-CoV-2. *JAMA Netw Open* 2021;4:e2116420.
- [9] Belay ED, Abrams J, Oster ME *et al.* Trends in geographic and temporal distribution of US children with multisystem inflammatory syndrome during the COVID-19 pandemic. *JAMA Pediatr* 2021;175:837–45.
- [10] Rostad CA, Chahroudi A, Mantus G *et al.* Quantitative SARS-CoV-2 serology in children with multisystem inflammatory syndrome (MIS-C). *Pediatrics* 2020;146:e2020018242.