

Received: 2019.08.31  
Accepted: 2019.11.06  
Published: 2019.12.17

# Hemashield Vascular Graft Is a Preferable Prosthetic Graft for Middle Hepatic Vein Reconstruction in Living Donor Liver Transplantation

Authors' Contribution:  
Study Design A  
Data Collection B  
Statistical Analysis C  
Data Interpretation D  
Manuscript Preparation E  
Literature Search F  
Funds Collection G

ABCDE **Gil-Chun Park**  
ABCDEFG **Shin Hwang**  
BCD **Tae-Yong Ha**  
BCD **Gi-Won Song**  
BCD **Dong-Hwan Jung**  
BCD **Chul-Soo Ahn**  
BCD **Deok-Bog Moon**  
BCD **Ki-Hun Kim**  
BCD **Young-In Yoon**  
BCD **Hui-Dong Cho**  
BCD **Jae-Hyun Kwon**  
BCD **Yong-Kyu Chung**  
BCD **Sang-Hyun Kang**  
BCD **I-Ji Jung**  
BCD **Jin-Uk Choi**  
ACD **Sung-Gyu Lee**

Division of Hepatobiliary Surgery and Liver Transplantation, Department of Surgery, Asan Medical Center, University of Ulsan College of Medicine, Seoul, South Korea

**Corresponding Author:** Shin Hwang, e-mail: shwang@amc.seoul.kr

**Source of support:** This study was supported by the Basic Science Research Program through the National Research Foundation of Korea funded by the Ministry of Science, ICT and Future Planning (grant no. 2019039742 to Shin Hwang)

**Background:** Because of the supply shortage for homologous vein allografts, we previously used ringed Gore-Tex vascular grafts for middle hepatic vein (MHV) reconstruction in living donor liver transplantation. However, owing to the subsequent unavailability of ringed Gore-Tex grafts, we replaced them with Hemashield vascular grafts. This study aimed to compare the patency of Hemashield grafts with that of ringed Gore-Tex grafts.

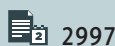
**Material/Methods:** This was a retrospective double-arm study between the study group that used Hemashield grafts (n=63) and the historical control group that used ringed Gore-Tex grafts (n=126).

**Results:** In the Gore-Tex and Hemashield groups, mean age was 53.1±6.2 and 54.3±10.4 years; model for end-stage liver disease score was 16.5±8.3 and 17.5±9.9; and graft-recipient weight ratio was 1.11±0.23 and 1.12±0.25, respectively. In the Gore-Tex graft group, V5 reconstruction was done in single (n=107, 84.9%), double (n=17, 13.5%), and none (n=2, 1.6%). V8 reconstruction was done in single (n=95, 75.4%), double (n=1, 0.8%), and none (n=30, 23.8%). In the Hemashield group, V5 reconstruction was done in single (n=43, 68.3%), double (n=19, 30.2%), and triple (n=1, 1.6%). V8 reconstruction was done in single (n=45, 71.4%), double (n=9, 14.3%), and none (n=9, 14.3%). One-year conduit patency rates in the Gore-Tex and Hemashield groups were 54.8% and 71.6%, respectively (p=0.048).

**Conclusions:** MHV reconstruction using Hemashield vascular grafts demonstrated higher short-term patency rates than those associated with ringed Gore-Tex vascular grafts. We suggest that the Hemashield vascular graft is one of the best prosthetic materials for MHV reconstruction.

**MeSH Keywords:** Hepatic Veins • Liver Transplantation • Living Donors

**Full-text PDF:** <https://www.annalsoftransplantation.com/abstract/index/idArt/919780>



2997



2



4



13



## Background

Middle hepatic vein (MHV) reconstruction with vascular graft interposition is regarded as one of the standard procedures for living donor liver transplantation (LDLT) using a modified right lobe graft. To date, various interposition conduit materials have been used, including homologous and autologous vessels and prosthetic vascular grafts [1–4]. Theoretically, homologous vein allografts are considered to be the most suitable material for MHV reconstruction. However, their supply is often limited because of the shortage of tissue donors in Asian countries, including Korea.

To overcome such a discrepancy between the demand and supply of homologous vessel allografts, prosthetic vascular grafts have been used instead. We previously presented that the patency rate of ringed expanded polytetrafluoroethylene (ePTFE; Gore-Tex vascular graft, Gore Medical; henceforth simply referred to as Gore-Tex) grafts was higher than that of cryopreserved iliac vein and aorta allografts [5]. However, ringed Gore-Tex grafts are currently not available in Korea owing to stoppage of production. Thus, we had to investigate other prosthetic vascular grafts as an alternative to ringed Gore-Tex grafts. We tested several prosthetic vascular grafts and finally chose the collagen-impregnated woven double velour polyester grafts (Hemashield Platinum, Maquet; henceforth simply referred to as Hemashield) for MHV reconstruction because their physical features and short-term patency rates did not appear to be inferior to those of ringed Gore-Tex grafts.

Here, we analyzed the short-term patency rates and complications of Hemashield vascular grafts in comparison with those of ringed Gore-Tex vascular grafts with regard to their application for MHV reconstruction in LDLT at a single high-volume liver transplantation (LT) center.

## Material and Methods

### Study design

This was a retrospective double-arm study on the outcomes of Hemashield and ringed Gore-Tex graft interposition used for MHV reconstruction. The primary purpose of this study was to assess the short-term patency rates of Hemashield grafts, and the secondary purpose was to assess the incidence of Hemashield graft-associated complications.

Because we intended to assess the outcomes of Hemashield graft interposition, we selected 63 cases that received a Hemashield vascular graft during an 18-month study period from November 2017 to April 2019. All patients subjected to MHV interposition with Hemashield vascular grafts during the

study period were included in this study, with inclusion of 3 cases of perioperative mortality. These 63 patients constituted the study group (Hemashield group).

Additionally, through 1:2 matching, we selected 126 patients who underwent MHV reconstruction using ringed Gore-Tex vascular grafts as the historical control group (Gore-Tex group). To establish reliable reference patency rates for ringed Gore-Tex grafts, we intentionally excluded the patients who survived for less than 2 years and those who had hepatocellular carcinoma recurrence. Because we started to use Hemashield grafts since November 2017 after ringed Gore-Tex grafts were no longer available in Korea, the patient selection period for each group was sequential and not overlapping. The patient selection period for the historical Gore-Tex control group was 36 months, from January 2011 to December 2013. All 126 patients were alive until the end of August 2019 and were subjected to regular follow-up at the outpatient clinic. This study protocol was approved by the Institutional Review Board of our institution.

### Selection of prosthetic vascular grafts for MHV reconstruction

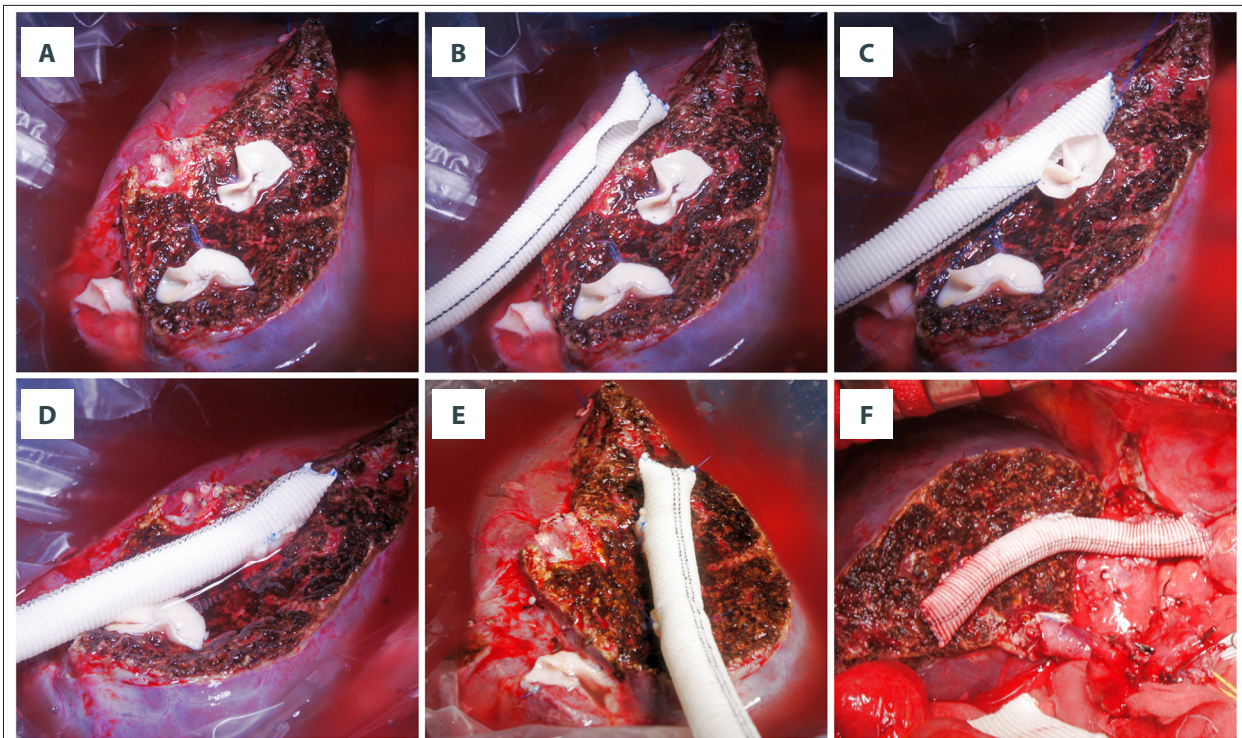
After we established the techniques for MHV reconstruction in 1997, we have tried to reconstruct most of the large MHV branches (V5 for segment V vein and V8 for segment VIII vein) having a diameter of  $\geq 5$  mm. Our indication for MHV reconstruction has been described elsewhere [1–5]. When a sufficiently large-sized vessel allograft was not found to be available after reviewing the list of vessel allografts stored at our institutional tissue bank, we had decided to use a 10-mm or 12-mm ringed Gore-Tex graft. Vessel graft material was selected after consideration of the graft-recipient weight ratio and end-stage liver disease score.

Subsequently, when ringed Gore-Tex grafts were also no longer available, we replaced them with 10-mm or 12-mm Hemashield vascular grafts. Thus, the indication for Hemashield grafts was exactly the same as that for ringed Gore-Tex grafts.

### Surgical techniques

We used the same surgical techniques for MHV reconstruction, regardless of the use of ringed Gore-Tex or Hemashield grafts. A prosthetic vascular graft with an internal diameter of 10–12 mm was used. After creating a small niche to enlarge the orifices of V5 and V8 stumps, an intervening allograft patch was attached for end-to-side anastomosis of MHV branches. A prosthetic graft was anastomosed to the middle-left hepatic vein trunk of the recipient by using either an end-to-end or side-to-end method.

We used non-absorbable 5-0 or 6-0 monofilaments made of ePTFE (Gore-Tex Suture™, Gore Medical) that helped reduce needle hole

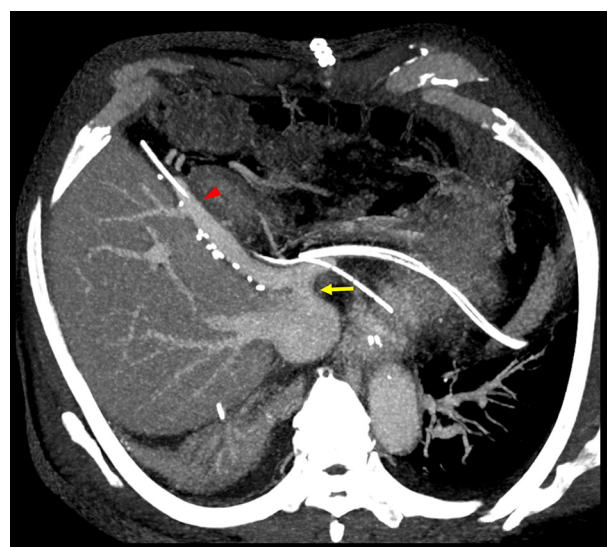


**Figure 1.** Intraoperative photographs showing the standardized techniques of middle hepatic vein reconstruction using a Hemashield vascular graft and a cryopreserved iliac artery patch. (A) A middle hepatic vein branch orifice at the liver cut surface was widened by making a ventral cut, and the arterial patch was sutured. (B) A 12-mm Hemashield graft was prepared and a hole was excised to match with the size of the arterial patches. (C, D) An end-to-side anastomosis was performed between the Hemashield graft and the arterial patch, showing a funnel-shaped intervening arterial patch. (E) Two middle hepatic vein branches were anastomosed with the Hemashield graft by end-to-side method. (F) Anastomosis of the Hemashield graft to the recipient middle-left hepatic vein stump in a side-to-side method was followed by closing of the distal end with a running suture using 5-0 Prolene.

bleeding from Gore-Tex grafts. For Hemashield grafts, we used the usual 5-0 or 6-0 Prolene sutures because the woven structure of these bovine collagen-impregnated grafts prevents needle hole bleeding. Details of the procedures carried out using ringed Gore-Tex grafts have been presented elsewhere [5], and those carried out using Hemashield grafts are depicted at Figures 1, 2.

If the orifice of V5 or V8 was greater than 8 mm and the stump cuff of V5/V8 orifice was thick, it is often unnecessary to attach an intervening allograft patch to V5/V8 orifices for facilitating direct anastomosis because the Hemashield graft wall is considerably thinner than the ringed Gore-Tex graft wall.

**Figure 2.** A dynamic computed tomography image of the patient, shown in Figure 1, taken on the 7<sup>th</sup> day after transplantation. The internal lumen of the Hemashield conduit used for middle hepatic vein reconstruction was patent without any thrombus formation. The arrow head indicates the anastomosis site to the segment V hepatic vein, while the arrow indicates the anastomosis between Hemashield graft conduit and recipient middle-left hepatic vein stump.





**Table 1.** Clinical profiles of patients who underwent middle hepatic vein reconstruction using Goretex or Hemashield vascular grafts.

	Goretex group	Hemashield group	p-Value
Case number	126	63	
Age (years)	53.1±6.2	54.3±10.4	0.36
Sex (n)			0.91
Male	91 (72.2%)	45 (71.4%)	
Female	35 (27.8%)	18 (28.6%)	
MELD score	16.5±8.3	17.5±9.9	0.47
Primary disease (n)			<0.001*
HBV-associated cirrhosis	88 (69.8%)	26 (41.3%)	
HCV-associated cirrhosis	4 (3.2%)	1 (1.6%)	
Alcoholic liver disease	18 (14.3%)	21 (33.3%)	
Cryptogenic cirrhosis	8 (6.3%)	7 (11.1%)	
Acute liver failure	4 (3.2%)	2 (3.2%)	
Polycystic liver disease	2 (1.6%)	0	
Wilson disease	2 (1.6%)	2 (3.2%)	
Autoimmune hepatitis	0	3 (4.8%)	
Primary sclerosing cholangitis	0	1 (1.6%)	
Concurrent hepatocellular carcinoma (n)	67 (53.2%)	28 (44.4%)	0.26
ABO-incompatible transplantation (n)	19 (15.1%)	17 (27.0%)	0.049
Graft-recipient weight ratio	1.11±0.23	1.12±0.25	0.67

MELD – model for end-stage liver disease; HBV – hepatitis B virus; HCV – hepatitis C virus. \* Comparison between HBV infection cases and others.

### Evaluation of prosthetic graft-interposed MHV patency and indications for interventional stenting

According to our LDLT management protocol, posttransplant dynamic computed tomography (CT) scans were taken weekly while the patients were admitted in the hospital, as well as at 1, 3, 6, and 12 months after LT. Thereafter, follow-up abdomen-pelvis CT was repeated annually for 5 years and biannually after 5 years.

We defined occlusion of MHV conduit as non-visualization of blood flow in the prosthetic graft conduit between V8 (or V5 when only V5 was reconstructed) and the inferior vena cava on dynamic liver CT scans. When V5 was occluded by thrombus but V8 was patent, we considered the MHV conduit was patent. When it was not possible to take CT scans owing to impaired renal function, Doppler ultrasonography-related data were used instead.

Interventional stenting of the thrombosed MHV conduit was indicated if significant MHV occlusion-related perfusion abnormality occurred in the graft liver [6,7]. Here, we regarded such MHV stenting as occlusion of the prosthetic conduit graft, even if MHV conduit patency was restored after stenting.

### Statistical analysis

All numerical data are presented as mean values with standard deviations. Continuous variables were compared with the *t* test and incidence variables were compared using chi-square test or Fisher's exact test. Patency rates were determined using Kaplan-Meier method and were compared using log-rank test. Statistical analyses were performed using SPSS (version 22; IBM, NY).

## Results

### Patient profiles

The clinical profiles of 189 patients who underwent LDLT, using a modified right lobe graft, along with MHV reconstruction carried out using either ringed Gore-Tex or Hemashield vascular grafts, are summarized in Table 1. In the Gore-Tex and Hemashield groups, the mean age was 53.1±6.2 and 54.3±10.4 years; the number of hepatitis B virus infection-associated patients was 88 (69.8%) and 26 (41.3%); the end-stage liver disease score was 16.5±8.3 and 17.5±9.9; ABO blood-incompatible

**Table 2.** Configuration of middle hepatic vein reconstruction performed using ringed Goretex or Hemashield vascular grafts.

	Goretex group	Hemashield group
V5 reconstruction (n)		
No reconstruction	2 (1.6%)	0
Single anastomosis	107 (84.9%)	43 (68.3%)
Double anastomoses	17 (13.5%)	19 (30.2%)
Triple anastomoses	0	1 (91.6%)
V8 reconstruction (n)		
No reconstruction	30 (23.8%)	9 (14.3%)
Single anastomosis	95 (75.4%)	45 (71.4%)
Double anastomoses	1 (0.8%)	9 (14.3%)
Triple anastomoses	0	0

LDLT was 19 (15.1%) and 17 (27.0%); and the graft-recipient weight ratio was  $1.11 \pm 0.23$  and  $1.12 \pm 0.25$ , respectively.

### Configuration of MHV reconstruction using prosthetic vascular grafts

Various vessel fragments, including cryopreserved iliac arteries, cryopreserved iliac veins, and autologous saphenous and portal veins, served as the sources for vessel patches that were attached to the V5/V8 orifices. Patch unification of 2 or 3 small V5/V8 orifices was preferentially performed because it enabled us to create a single anastomosis to the interposed prosthetic graft.

In the Gore-Tex graft group, V5 reconstruction was performed with a single anastomosis in 107 patients (84.9%, including unification venoplasty), double anastomoses in 17 patients (13.5%), and no reconstruction in 2 patients (1.6%); V8 reconstruction was also performed with a single anastomosis in 95 patients (75.4%, including unification venoplasty), double anastomoses in 1 patient (0.8%), and no reconstruction in 30 patients (23.8%). The internal diameter of the Gore-Tex vascular graft was 10 mm in 120 cases (95.2%) and 12 mm in 6 cases (4.8%).

In the Hemashield graft group, V5 reconstruction was performed with a single anastomosis in 43 patients (68.3%, including unification venoplasty), double anastomoses in 19 patients (30.2%), and triple anastomosis in 1 patient (1.6%); V8 reconstruction was performed with a single anastomosis in 45 patients (71.4%, including unification venoplasty), double

anastomoses in 9 patients (14.3%), and no reconstruction in 9 patients (14.3%). These configurations of V5 and V8 reconstruction are summarized in Table 2. The internal diameter of the Hemashield vascular graft was 10 mm in 37 cases (58.7%) and 12 mm in 26 cases (41.3%).

### Patterns of prosthetic graft occlusion

Serial follow-up CT scans showed that luminal thrombosis occurred within the prosthetic grafts around the V5 anastomosis. V5 outflow was gradually reduced, which resulted in concentric thickening of luminal thrombus. At this phase, a prosthetic graft with an internal diameter of 10 mm or 12 mm was transformed to a narrow conduit with a considerably smaller inner diameter. Finally, the lumen of a graft conduit between V5 and V8 orifices was occluded. Meanwhile, V8 outflow was maintained for a longer period than V5 outflow. The progression of MHV conduit occlusion that occurred after using a Hemashield vascular graft is depicted in Figure 3. The sequences of progressive occlusion of the interposed ringed Gore-Tex vascular grafts have been reported previously [5].

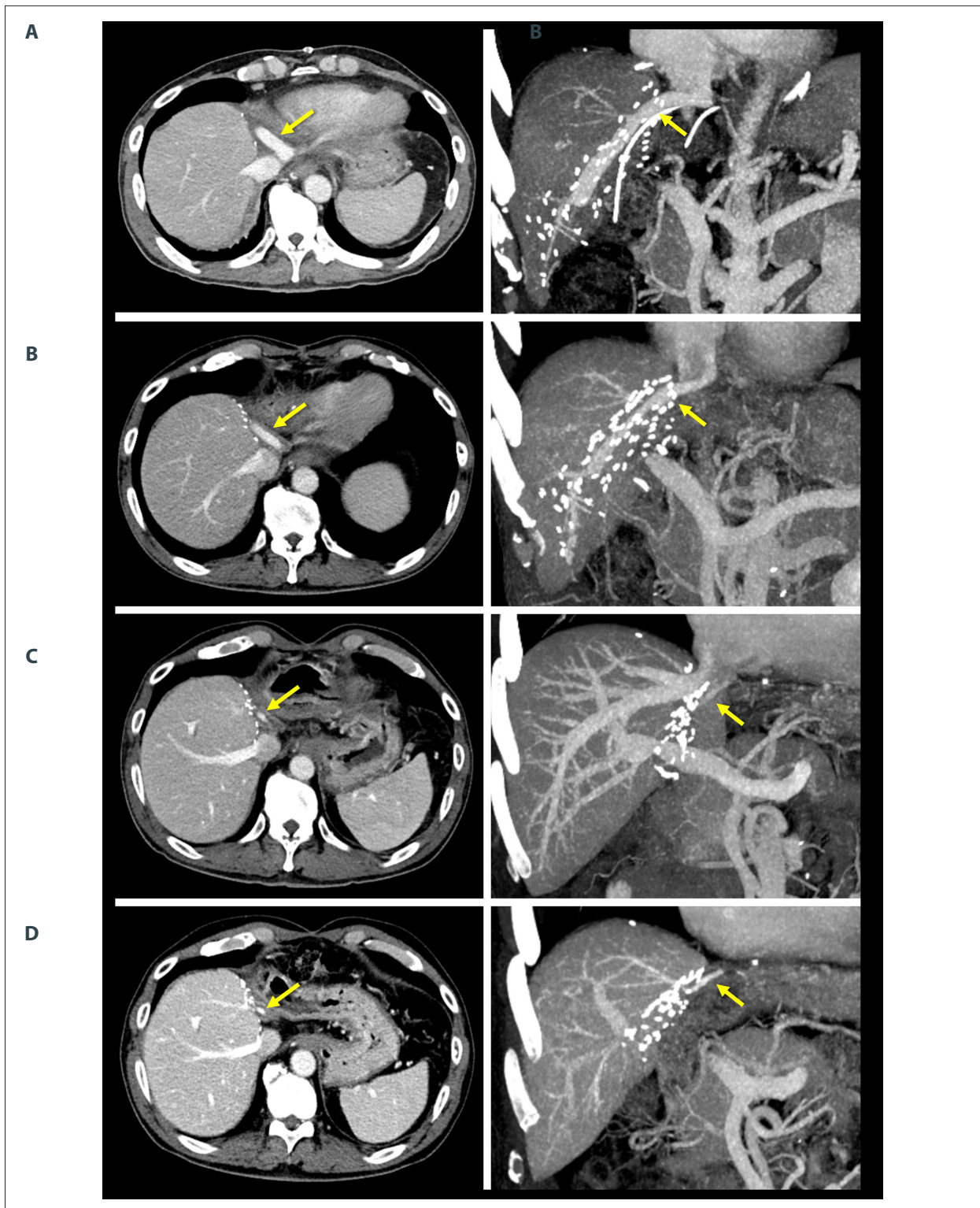
### Patency of prosthetic graft conduits

In the ringed Gore-Tex graft group, 4 patients (3.2%) required MHV stenting during a mean follow-up period of 7 years. All of them underwent early stenting within 3 weeks of LT and MHV flow was again restored. After 3 months, there were no episodes of such congestion-associated graft infarct, regardless of MHV conduit patency. The patency rates of the ringed Gore-Tex-interposed MHV conduits were 92.9% at 3 months, 54.8% at 12 months, 43.7% at 24 months, and 36.5% at 36 months (Figure 4).

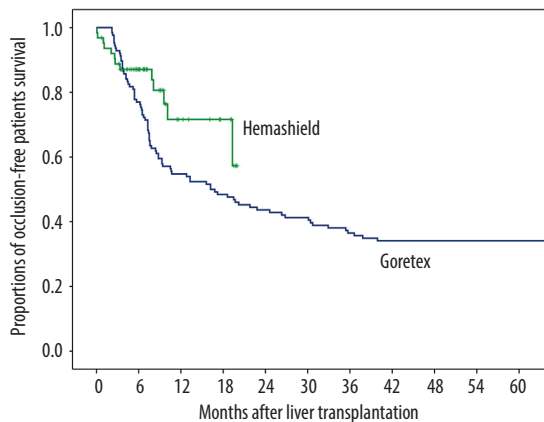
In the Hemashield graft group, 2 patients (3.2%) required MHV conduit stenting during a mean follow-up period of 9 months. All of them underwent early stenting within 2 weeks of LT and MHV conduit flow was again restored. After 2 months, there were no episodes of such congestion-associated infarct, regardless of MHV conduit patency. The patency rates of the Hemashield-interposed MHV conduits were 88.8% at 3 months, 71.6% at 12 months, and 57.3% at 18 months (Figure 4), and the patency rates in the Hemashield group were found to be superior to those in the Gore-Tex group ( $p=0.048$ ).

### Prosthetic vascular graft-associated complications

In the ringed Gore-Tex graft group, accidental migration of the ringed Gore-Tex graft into the gastric wall occurred in 2 cases, at 6 months and 3 years after LT [8]. These patients underwent exploratory laparotomy to remove the ringed Gore-Tex graft. The long-term incidence rate for such accidental migration of the ringed Gore-Tex graft was 1.6% at 5 years.



**Figure 3.** Serial computed tomography images showing progressive occlusion of the lumen within the interposed Hemashield vascular graft, taken at 1 week (A), 1 month (B), 6 months (C), and 18 months (D) after transplantation. Despite deprivation of middle hepatic vein blood outflow, no hepatic venous congestion was noted owing to the development of intrahepatic venous collaterals. In this patient, the middle hepatic vein conduit created using a Hemashield vascular graft was patent until 18 months of transplantation. Arrows indicate luminal blood flow within the interposed Hemashield graft.



**Figure 4.** Comparison of the luminal patency of the interposed middle hepatic vein conduit relative to the prosthetic vascular graft materials.

In the Hemashield graft group, accidental migration of the prosthetic graft into adjacent visceral structures did not occur over a mean follow-up period of 9 months.

No patients had prosthetic graft-related infectious complications in either group. A majority of the occluded prosthetic vascular grafts, regardless of prosthetic graft materials used, have silently persisted as foreign bodies for prolonged periods, even after the conduit lumen was completely occluded with thrombus.

## Discussion

Reconstruction of MHV resulted in new demands for vascular allografts in the field of LDLT using a modified right liver graft. The increased frequency of LDLTs has led to relative shortages in vessel allograft supply. We have used every available vessel material for MHV reconstruction. Cryopreserved iliac vein allograft has been traditionally regarded to be the most suitable conduit for MHV reconstruction. However, the most serious problem is its limited availability owing to severe supply shortage.

With regard to availability, prosthetic vascular grafts have a definite advantage of unlimited supply. The short- and long-term patency rates of the ringed Gore-Tex grafts were sufficiently high, as shown in this study. We believe that this is primarily due to the surgical techniques associated with or features of ringed Gore-Tex grafts: the presence of outer rings to protect against extrinsic compression; the offset against stenosis-inducing effects exerted by tissue reactions by placing an intervening allograft patch between the V5/V8 orifice and Gore-Tex graft; and construction of a streamlined, endothelial

cell-lined internal tunnel within the luminal thrombus of Gore-Tex grafts [5]. Such an internal pathway within the prosthetic vascular graft acts like a narrow neointima-lined conduit with a variable diameter that is hemodynamically adjusted by the blood flow volume passed [5, 9].

The physical features of Hemashield vascular grafts are similar to those of ringed Gore-Tex vascular grafts. Although they do not have outer rings, the circular pleats (Concentricrimp™, Maquet) of the Hemashield vascular grafts work effectively, similar to the outer rings of Gore-Tex vascular grafts; thus, the former grafts are resistant to extrinsic compression. Because of its thin-walled flexible structure formed using woven double velour polyester material, it is easier to handle and suture the Hemashield grafts than the ringed Gore-Tex grafts. Its bellows-like circular pleats enable flexible shortening or lengthening of the Hemashield grafts. Thus, adjustment of the conduit length during anastomosis to the left-middle hepatic vein trunk or inferior vena cava of the recipient becomes flexible, and this wide range of length adjustment accommodates the morphological changes induced by gradual graft regeneration. The woven structure of these bovine collagen-impregnated grafts also prevents needle hole bleeding; thus, use of expensive suture materials, such as Gore-Tex suture, is unnecessary. The diameter of 10–12 mm and length of 25 cm of commercially available Hemashield Platinum vascular grafts are the optimal conditions to use as an MHV conduit. Its longitudinal colored lines (Guideline Strip™, Maquet) is also useful to adjust the alignment during anastomosis. In addition, its bovine collagen-impregnated and woven double velour structure facilitates prevention of early luminal thrombus formation and tissue reaction at the anastomosis sites. Furthermore, the short-term patency rates of Hemashield grafts are superior to those of ringed Gore-Tex grafts, and the risk of accidental prosthetic graft migration appears to be lower than that associated with ringed Gore-Tex grafts. Based on our 18-month experience, we suggest that Hemashield vascular grafts are better than ringed Gore-Tex grafts for MHV reconstruction.

So far, we have tested various prosthetic vascular grafts. The ePTFE grafts with outer spiral-wound rings (Impra™, Bard) provide flexibility in length control because they permit flexible shortening and lengthening of the conduit. However, their application is limited because large-diameter (greater than 10 mm) grafts were not available due to lack of commercial production. Because of this size limit, they could not replace the ringed Gore-Tex vascular grafts at our institution. A thin-walled ePTFE with inner carbon lining (Impra Carboflo™, Bard) appears to be acceptable for MHV reconstruction, but the commercially available product is provided by a piece that is 10 cm in length; thus, such a vascular graft is too short to be used for MHV reconstruction.



Prosthetic vascular grafts have a definite advantage of unlimited supply and appear promising owing to improved luminal patency. However, we experienced accidental migration of a ringed Gore-Tex graft into the hollow viscus [9,10]. Migration of such a foreign body into the stomach or duodenum can induce life-threatening complications; thus, its surgical removal should be performed. We believe that the primary mechanism underlying accidental migration of ePTFE graft is based on foreign body-induced inflammatory reactions. Inflammation-induced adhesion can facilitate migration of ePTFE graft into the adjacent hollow viscus. Its 5-year incidence was estimated to be approximately 2% on using ringed Gore-Tex grafts. Hsu et al. reported that PTFE-related complications developed in 1.5% (4/262) of the patients. One patient developed complete thrombosis with sepsis at 24 months and died owing to multi-organ failure; the other 3 patients experienced graft migration into the second portion of the duodenum, for which surgical removal had to be performed [10]. In contrast, we have not yet experienced such accidental graft migration after using Hemashield vascular grafts. Because our observation period was relatively short and because our study did not comprise a large number of patients for whom Hemashield graft was used, long-term observation with a large number of cases is mandatory to ensure the safety of Hemashield graft use. If accidental graft migration does not occur, nearly all of the occluded prosthetic vascular grafts remain silent as foreign bodies after thrombotic luminal obliteration; however, they can be a potential source of other rare complications later.

Considering both the pros and cons of prosthetic vascular grafts, these grafts are currently regarded as vascular substitutes for “necessary evil”. Considering that massive hepatic venous congestion from MHV outflow deprivation is one of the leading causes of early graft failure following LDLT, the risk

of prosthetic vascular graft-related complication is not high enough to completely abandon the use of prosthetic vascular grafts. To the best of our knowledge, this study is the first to report the use of Hemashield vascular grafts for MHV reconstruction in LDLT.

Active attempts have been made to develop new forms of vascular grafts using tissue engineering techniques. Decellularized scaffolds made using animal vessels and acellular platforms made using absorbable components are promising biomaterials for vascular substitutes [11–13], but further research and trials are needed before they can be applied in actual clinical practice.

This study has several limitations. First, it was a single-center study, which could have introduced selection bias. Second, it was a clinical study involving a limited number of cases performed over a relatively short study period; thus, long-term outcomes could not be assessed. We intend to perform long-term follow-up studies to validate the results of the present study.

## Conclusions

MHV reconstruction using Hemashield vascular grafts demonstrated high short-term patency rates, which were superior to those of ringed Gore-Tex vascular grafts. Considering its easy handling and wide flexibility in length adjustment, we suggest that the Hemashield vascular graft is one of the best prosthetic materials for MHV reconstruction.

## Conflicts of interest

None.

## References:

- Hwang S, Lee SG, Lee YJ et al: Lessons learned from 1,000 living donor liver transplantations in a single center: How to make living donations safe. *Liver Transpl*, 2006; 12: 920–27
- Hwang S, Lee SG, Ahn CS et al: Cryopreserved iliac artery is indispensable interposition graft material for middle hepatic vein reconstruction of right liver grafts. *Liver Transpl*, 2005; 11: 644–49
- Sugawara Y, Makuuchi M, Akamatsu N et al: Refinement of venous reconstruction using cryopreserved veins in right liver grafts. *Liver Transpl*, 2004; 10: 541–47
- Hwang S, Lee SG, Song GW et al: Use of endarterectomized atherosclerotic artery allograft for hepatic vein reconstruction of living donor right lobe graft. *Liver Transpl*, 2007; 13: 306–8
- Hwang S, Jung DH, Ha TY et al: Usability of ringed polytetrafluoroethylene grafts for middle hepatic vein reconstruction during living donor liver transplantation. *Liver Transpl*, 2012; 18: 955–65
- Ko GY, Sung KB, Yoon HK et al: Endovascular treatment of hepatic venous outflow obstruction after living-donor liver transplantation. *J Vasc Interv Radiol*, 2002; 13: 591–99
- Ko GY, Sung KB, Yoon HK et al: Early posttransplant hepatic venous outflow obstruction: Long-term efficacy of primary stent placement. *Liver Transpl*, 2008; 14: 1505–11
- Ha TY, Hwang S, Jung DH et al: Complications analysis of polytetrafluoroethylene grafts used for middle hepatic vein reconstruction in living-donor liver transplantation. *Transplant Proc*, 2014; 46: 845–49
- Papanicolaou G, Beach KW, Zierler RE et al: Hemodynamics of stenotic intrahepatic vein grafts: Theoretic considerations. *Ann Vasc Surg*, 1995; 9: 163–71
- Hsu SC, Thorat A, Yang HR et al: Assessing the safety of expanded polytetrafluoroethylene synthetic grafts in living donor liver transplantation: Graft migration into hollow viscous organs – diagnosis and treatment options. *Med Sci Monit*, 2017; 23: 3284–92
- Copes F, Pien N, Van Vlierberghe S et al: Collagen-based tissue engineering strategies for vascular medicine. *Front Bioeng Biotechnol*, 2019; 7: 166
- Best CA, Szafron JM, Rocco KA et al: Differential outcomes of venous and arterial tissue engineered vascular grafts highlight the importance of coupling long-term implantation studies with computational modeling. *Acta Biomater*, 2019; 94: 183–94
- Pattanaik S, Arbra C, Bainbridge H et al: Vascular tissue engineering using scaffold-free prevascular endothelial-fibroblast constructs. *Biores Open Access*, 2019; 8: 1–15