

Subaortic membrane with rupture of sinus of Valsalva presented with infective endocarditis and its thromboembolic complications

Nirdesh Jain, Manish Gutch, Roopali Khanna¹, Rahul Arora

Departments of Internal Medicine, CSMMU and Departments of ¹Cardiology, SGPGI, Lucknow, India
Address for correspondence: Dr. Nirdesh Jain, Department of Internal Medicine, CSMMU, Lucknow, India.
E-mail: nirdeshjain8@gmail.com

ABSTRACT

Rupture of the sinus of Valsalva (RSOV) is an uncommonly encountered condition. It can present with wider manifestations ranging from an asymptomatic murmur to cardiogenic shock. The case discussed in this report also had subaortic membrane which usually presents with subvalvular aortic stenosis, left ventricular hypertrophy, myocardial ischemia and sudden death. Corrective cardiac surgery was advised, but due to financial constraints, the patient could not be operated and he died. Here, the authors report for the first time an unusual presence of both RSOV and subaortic membrane and the patient presented with thromboembolic complication resulting from infective endocarditis.

Key words: Infective endocarditis, rupture sinus of Valsalva, subaortic membrane

INTRODUCTION

Subaortic membrane is a fibrous membrane below the aortic valve that may involve the ventricular septum, the anterior leaflet of the mitral valve, and the aortic valve itself. Sinus of Valsalva is a localized bulging in the aortic root opposite to the cusps of the aortic valve. Aneurysm of the sinus is a rare condition which may be a congenital or acquired cardiac anomaly, having an incidence of 1.09% in the oriental population and 0.2% in the western population.^[1] Rupture of the sinus of Valsalva (RSOV) is an uncommon condition. The unruptured aneurysm is usually silent and often remains undiagnosed, but may cause symptoms by right ventricular outflow obstruction.^[2] The rupture may occur into any cardiac chamber, predominantly the right ventricle,^[3] the intraventricular septum,^[4] and the pericardial space.^[5]

The pathology of this condition is thought to be due to a failure of the fusion between the aortic media and the heart at the level of annulus fibrosus of the aortic valve, with subsequent aneurysmal enlargement at this weak point due to the high pressure at the root of the aorta.^[6] Aneurysms of the sinus of Valsalva are usually not clinically apparent unless perforation occurs which simulates aortic regurgitation.^[7] RSOV presents with wider manifestations ranging from an asymptomatic murmur to cardiogenic shock. Subaortic membrane usually presents with subvalvular aortic stenosis, left ventricular hypertrophy due to pressure overload, myocardial ischemia, heart failure, and sudden death. A case of infective endocarditis resulting in RSOV has been reported in the literature.^[8]

Here, the authors for the first time report an unusual presence of both RSOV and subaortic membrane, and the patient presented with thromboembolic complication resulting from infective endocarditis.

CASE REPORT

A 20-year-old male was admitted to the emergency department with complaints of fever for 15 days, increased breathlessness for 2 days and sudden onset weakness of

Access this article online	
Quick Response Code: 	Website: www.jcdonline.com
	DOI: 10.4103/0975-3583.91596

the right side of body since 1 day. Past history revealed complaints of breathlessness since the age of 2 years for which he was not investigated. On clinical examination, the patient was febrile; his pulse was 80/minute, regular, and the blood pressure was 110/70 mmHg. Cardiac apex was shifted to left 6th intercostal space lateral to midclavicular line and was hyperdynamic. Auscultation revealed continuous murmur of grade III, best heard at left sternal border and also heard all over the precordium. On chest auscultation, basal crackles were present bilaterally. Neurological examination showed complete hemiparesis of right side of the body with 3/5 power in the upper extremity and 2/5 power (MRC scale) in the lower extremity. Rest of the systemic examinations did not reveal any abnormality. Laboratory investigations showed the following results: hemoglobin 9.1 gm%; total leukocyte count 16,870/mm³ with 70% neutrophils and 25% lymphocytes; platelet count 1.08×10^5 /mm³; serum

blood sugar and electrolytes were normal; serum urea 65 mg/dl and creatinine 1.5 mg/dl. Three sets of blood culture including anaerobic culture were drawn 1 hour apart and they revealed no organism growth after an incubation period of 7 days. 2D echocardiography revealed subaortic membrane causing severe obstruction of left ventricular outflow tract (LVOT) [Figure 1a] with RSOV into right ventricle, with vegetations seen over mitral and aortic valves [Figure 1b]. There was significant aortic and mitral regurgitation. Magnetic resonance imaging (MRI) brain showed acute infarct with hemorrhagic transformation in the left parietal region, with subarachnoid bleed with mass effect. The patient was started on empirical regimen of intravenous antibiotics [Figure 2a and b]. Frusemide (60 mg/24 hours) and nitroglycerine (started at 10 µg/minute) were given for the initial 2 days and the dose was adjusted with monitoring of blood pressure. The patient had infective endocarditis with neurological complication.

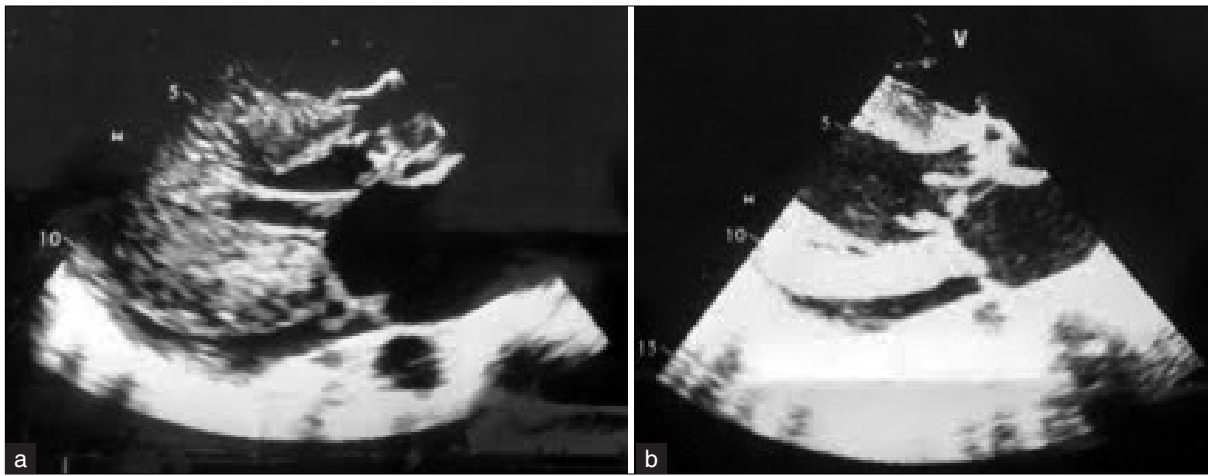


Figure 1: (a) 2D echo PLAX view showing subaortic membrane with marked left ventricular hypertrophy and mild pericardial effusion; (b) 2D echo PLAX view showing vegetation on anterior mitral leaflet, measuring 10 × 6 mm

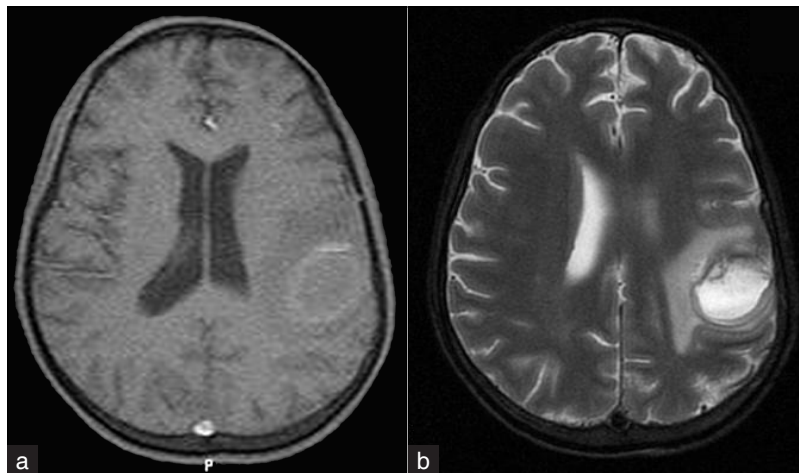


Figure 2: MRI brain axial section showing hypointense signal intensity alteration on T1WI (a) and hyperintense on T2 FLAIR (b) in left parietal region, suggestive of acute infarct. There is also perilesional edema

He was advised corrective surgery, but due to lack of finances the patient could not be operated. On the third day of treatment, the patient developed cardiogenic shock for which ionotropes were started. He died on the third day.

DISCUSSION

Ventricular septal defect (in about 50% of cases), pulmonary stenosis, tetralogy of Fallot, coarctation of aorta, bicuspid aortic valve, valvular and supravalvular aortic stenosis, left superior vena cava and even one case of anomalous origin of left coronary artery from pulmonary artery have been reported to be associated with RSOV.^[9] Subaortic membrane causes obstruction of left ventricular outflow and leads to subaortic stenosis. The resultant effects are essentially the same as valvular aortic stenosis: left ventricular hypertrophy from the pressure overload, myocardial ischemia, heart failure, and sudden death. In addition, a subaortic membrane may cause aortic insufficiency and permanent structural damage to the aortic valve due to alteration of left ventricular outflow dynamics.

Our patient fulfilled one major criterion, i.e. there was endocardial involvement by 2D echocardiogram which showed mobile oscillating intracardiac mass on mitral and aortic valves, suggestive of vegetations. Also, he fulfilled three minor criteria, i.e. presence of predisposing heart condition in the form of subaortic membrane, fever ($>100.4^{\circ}\text{F}$) and complication in the form of vascular phenomenon. He had major arterial emboli of the left middle cerebral artery. Therefore, according to modified Duke's criteria, the patient was diagnosed to have definitive infective endocarditis since he fulfilled one major and three minor criteria.^[10]

In our patient, there was infective endocarditis with its complication in the form of neurological involvement. The patient was advised to undergo valve replacement surgery along with repair of RSOV and excision of subaortic membrane. Although the valve replacement surgery was advised, due to financial constraints, he was not able to undergo surgery. This problem is faced by many patients

in India, since most of them are not under health insurance coverage.

On searching Google, Cochrane, Embase and PubMed, it was found that the presence of RSOV with subaortic membrane has not been documented till now. Infective endocarditis is a rare complication of RSOV and along with subaortic membrane makes this case the rarest one.

ACKNOWLEDGMENT

We owe thanks to the patient and his relatives for their cooperation and support without which this report would not have been possible.

REFERENCES

1. Chu SH, Hung CR, How SS, Chang H, Wang SS, Tsai CH, *et al.* Ruptured aneurysm of the sinus of Valsalva in oriental population. *J Thorac Cardiovasc Surg* 1990;99:288-98.
2. Malcolm I. Unruptured aneurysm of the sinus of Valsalva. *Can J Cardiol* 1996;12:783-5.
3. Küçükoglu S, Ural E, Mutlu H, Ural D, Sönmez B, Uner S. Ruptured aneurysm of the sinus of Valsalva into the left ventricle: Report and review of the literature. *J Am Soc Echocardiogr* 1997;10:862-5.
4. Abad C. Congenital aneurysm of the sinus of Valsalva dissecting into the intraventricular septum. *Cardiovasc Surg* 1995;3:563-4.
5. Barbram KR, Roberts WC. Fatal intrapericardial rupture of sinus of Valsalva aneurysm. *Am Heart J* 1990;120(6 Pt 1):1455-6.
6. Edwards JE, Burchell HB. The pathological anatomy of the deficiencies between the aortic root and the heart including aortic sinus aneurysms. *Thorax* 1957;12:125-39.
7. Bulkely HB, Hutchins MG, Ross SR. Aortic sinus of Valsalva simulating primary right sided valvular heart disease. *Circulation* 1975;52:696-9.
8. Vereckei A, Vándor L, Halász J, Karádi I, Lengyel M. Infective endocarditis resulting in rupture of sinus of Valsalva with a rupture site communicating with both the right atrium and right ventricle. *J Am Soc Echocardiogr* 2004;17:995-7.
9. Freedom RM, Yoo SJ. Sinus of Valsalva aneurysm In: The natural and modified history of congenital heart disease. Freedom RM, Yoo SJ, Mikailian H, William WG, editors. 1st ed. New York: Blackwell Publishing; 2004. p. 183-5.
10. Li JS, Sexton DJ, Mick N, Nettles R, Fowler VG Jr, Ryan T, *et al.* Proposed modifications to the Duke criteria for the diagnosis of infective endocarditis. *Clin Infect Dis* 2000;30:633-8.

How to cite this article: Jain N, Gutch M, Khanna R, Arora R. Subaortic membrane with rupture of sinus of Valsalva presented with infective endocarditis and its thromboembolic complications. *J Cardiovasc Dis Res* 2012;3:43-5.

Source of Support: Nil, **Conflict of Interest:** None declared.