

ARTHROPOD TRANSMISSION OF RABBIT PAPILLOMATOSIS*

By HERBERT T. DALMAT,† Ph.D.

(From the United States Department of Health, Education, and Welfare, Public Health Service, National Institutes of Health, National Institute of Allergy and Infectious Diseases,§ Bethesda, Maryland)

PLATES 1 AND 2

(Received for publication, September 25, 1957)

Papillomatosis of rabbits (1), a virus infection causing the development of warts or horns on the skin, is quite common among cottontail rabbits (*Sylvilagus floridanus* subspecies and *Sylvilagus auduboni* subspecies) in midwestern and western United States. The disease has been studied intensively in relation to cancer, since malignant transformation of the papillomas takes place in the wild rabbits in about 25 per cent of the cases and in domestic rabbits in about 75 per cent of cases that endure longer than 6 months. Virus is no longer recoverable from the majority of the cancers that ensue (2).

Since cottontail rabbits are easily infected by applying a crude suspension of papillomatous tissue of cottontail origin to the scarified skin, it is usually presumed that the mechanism of natural infection is by direct inoculation after slight injury inflicted to the skin. As the tumors occur on almost any part of the natural hosts, although most conspicuously on the head and neck, it would seem that an arthropod might be involved in the transmission. Considering this possibility, Larson *et al.* (3) attempted experimental transmission by fleas, wood ticks, and rabbit ticks. Their results were negative except in a single experiment in which some nymphs of the rabbit tick transmitted papilloma virus during an interrupted meal.

It is the purpose of the present paper to report the experimental transmission of papillomatosis by mosquitoes and assassin bugs.

Materials and Methods

Since papillomatosis of cottontail rabbits can be transferred by rubbing extracts of the tumors into the freshly scarified skin of either cottontails or domestic rabbits, whereas extracts of those from domestic rabbits are usually devoid of pathogenicity (1) and at best are relatively inactive (4-6), cottontail rabbits were used as a source of virus material, but do-

* A portion of a dissertation presented to the George Washington University in partial fulfillment of the requirements for the Ph.D. degree.

† With the technical assistance of Mr. James C. Cunningham.

§ Laboratory of Tropical Diseases.

mestic rabbits as the principal test animals. The cottontail rabbits (*S. floridanus* subspecies) were supplied by Dr. Carleton M. Herman, Chief of the Wildlife Pathology Section, Patuxent Research Refuge of the United States Fish and Wildlife Service, Laurel, Maryland, and by Mr. Paul Bruce Dowling, Resident Biologist of the Busch Memorial Wildlife Area, Missouri Conservation Commission. The domestic rabbits were the New Zealand White strain of *Oryctolagus cuniculus* which were supplied by the Animal Production Section of the National Institutes of Health.

The papilloma virus was secured from a Maryland cottontail (2-9A) infected by rubbing a 10 per cent virus-beef infusion broth suspension into an area approximately 2 inches in diameter on each of its flanks after the hair was clipped and the skin lightly abraded with sandpaper. The original tumor tissue used, which came from a Kansas cottontail, had been refrigerated for several years in 50 per cent glycerol at the National Institutes of Health. Within 5 weeks small keratinizing growths were visible, by 9 weeks there were numerous scattered papillomas, and by 6 months the discreet growths had coalesced to form a large confluent papillomatous mass. The tissue removed from this rabbit served as stock material for infecting other rabbits used in these studies.

Stock adult *Aedes aegypti* (L.) and *Anopheles quadrimaculatus* Say were maintained in lantern chimneys and fed with 5 per cent sucrose. Those to be fed on tumors were usually 2 to 5 days old and had not had a previous blood meal. All food was removed from their cage the evening before they were used. For feeding purposes, the mosquitoes were transferred to glass cylinders, $1\frac{1}{2} \times 3$ inches, both ends of which were covered with cotton netting. No more than 10 mosquitoes were placed in each cylinder. Their feeding was confined to the tumor area by covering the normal surrounding skin with heavy paper in which cutouts were made at appropriate areas to permit the tumors to protrude. The cylinders were maintained against the papillomas of the immobilized rabbit for about 30 minutes, permitting the mosquitoes to feed on whichever region of the tumors they preferred. Usually penetration was most successful at the basal region of established growths or on new growths forming amongst the old horns, but it was also accomplished along the fissures of the horns and surprisingly, through the keratinized horns themselves. When refeeding tumor-fed mosquitoes on the clipped flanks of a non-infected recipient rabbit, as many as 40 were introduced into a small lantern chimney, since it was not necessary to limit their feeding area. Mosquitoes that had fed on papillomas were also tested for their ability to pick up virus by applying a suspension of their mouthparts to the sandpapered skin of a different area of the recipient rabbit. To prepare the suspension, the intact stylets (with clypeal region attached) of 20 fed mosquitoes were ground in a mortar with the help of alundum and 1 ml. of beef infusion broth was added. The thoraces and abdomens of the mosquitoes were not used, since virus had never been recovered from these body parts.

The assassin bugs, *Rhodnius prolixus* Stål and *Triatoma infestans* Klug, were from laboratory colonies that ordinarily fed on uninfected domestic rabbits. They were fed on tumors through the netting covering their 250 ml. beaker breeding cages in a manner similar to that used for mosquitoes. Nymphs in all stages and adults that had not had a blood meal for at least 2 weeks were used. Those that took blood while feeding on a tumor were then separated into a clean beaker and kept for subsequent refeeding or for preparation of a mouthpart suspension for application to the scarified skin of a recipient rabbit.

Usually a single rabbit was utilized as recipient in each of the efforts at transmission.

Tissues were fixed in Zenker-formol, embedded by the standard paraffin technique, and the sections were stained with Mayer's hematoxylin and eosin¹.

¹ Dr. Mearl F. Stanton, Laboratory of Pathology, National Cancer Institute, kindly did the histological examinations.

TABLE I
Summary of Attempts of Insect Transmission of the Papillomas due to Infection of
Cottontail Rabbit 9-8

Age of the tumors on donor rabbit	Recipient rabbit	Insect vector*	Mode of Passage†	Interval between tumor meal and refeeding and application of mouthpart suspension	Results and time to appearance of tumors
<i>days</i>				<i>days</i>	<i>days</i>
33	Domestic 9-8A	<i>A. aegypti</i>	Interrupted meal	0	§
33	Domestic 9-8AA	<i>A. aegypti</i>	Refeeding	3	§
54	Cottontail 9-8B	<i>A. aegypti</i> <i>R. prolixus</i>	Refeeding	3	§
57	Domestic 1-12	<i>R. prolixus</i> <i>T. infestans</i>	Interrupted meal	0	§
57	Domestic 1-12A	<i>R. prolixus</i> <i>T. infestans</i>	Refeeding	4	§
71	Domestic 1-12AA	<i>A. aegypti</i> <i>R. prolixus</i>	Interrupted meal	0	§
91	Cottontail 9-8CC	<i>A. aegypti</i> <i>R. prolixus</i> <i>T. infestans</i>	Interrupted meal	0	28
91	Cottontail 9-8C	<i>A. aegypti</i> <i>R. prolixus</i>	Refeeding	4	30
91	Domestic 9-8DD	<i>A. aegypti</i> <i>R. prolixus</i>	Interrupted meal	0	12
91	Domestic 9-8D	<i>A. aegypti</i> <i>R. prolixus</i>	Refeeding	4	9
104	Cottontail 1-24	<i>T. infestans</i>	Refeeding	2	71
183	Domestic 1-42	<i>A. aegypti</i>	Refeeding	2	§
223	Domestic 1-56	<i>T. infestans</i> <i>A. aegypti</i>	Refeeding	8	§

* *A. aegypti* used in pools of 20; *R. prolixus* and *T. infestans* used in pools of 10.

† Interrupted meal indicates that the insects were permitted to take only a partial meal on the tumor, terminating it on the recipient host. Refeeding indicates an interval between the original feeding of the insects on the tumor and the attempt at passage to the recipient rabbit. In all cases a mouthpart suspension of the same insects was also applied to the scarified skin on the opposite side of the recipient rabbit.

§ Attempt at transmission unsuccessful.

|| Transmission achieved by the bite of the insects that had previously fed on the papillomas of Cottontail 9-8, as well as by application of a suspension of their mouthparts to the scarified skin.

Transmission from Primary Tumors

The results of experimental arthropod transmission of virus from cottontail papillomas to uninfected cottontail and domestic rabbits have been summarized in Table I.

The papillomas of the donor rabbit (Cottontail 9-8) had been induced by rubbing into the scarified skin of its flanks a suspension of the stock wart tissue of Cottontail 2-9A that had been stored for 9 months. Scattered growths that were visible by 2 weeks became quite large by 5 weeks, and by 8 weeks had coalesced to form confluent papillomatous masses. In some regions of the masses the growths remained fleshy for several weeks before becoming overlain with keratin. The large masses remained intact without undergoing much apparent change for 429 days when the rabbit died. The table tells when attempts at transmission were made.

It can be seen that when the papillomas of Cottontail 9-8 were 33, 54, 57, 71, 183, or 223 days old, virus was not transmitted from them by either mosquitoes or reduviid bugs, but that this took place when the tumors were 91 and 104 days old. This was shown by positive transmission from Cottontail 9-8 to Cottontails 9-8CC, 9-8C (Fig. 1), and 1-24, and to Domestic 9-8DD and 9-8D. In each of the positive efforts, the virus was successfully introduced into marked areas of one side of the recipient rabbit by the bite of the insects that had previously fed on the papillomas of the donor rabbit, and on the other side, by application of suspensions of the mouthparts of these same insects to marked, scarified areas of the skin. *A. aegypti*, *R. prolixus*, and *T. infestans* were able to transmit the virus equally well after an interval from their infectious meal as they were by feeding interruptedly with no intervening interval. The application of mouthpart suspensions of these insects to the prepared skin of the recipient hosts was as effective as their bites. Due to the proximity of the sites of virus introduction by the individual insect bites, the resulting papillomas formed a confluent mass, similar to that produced on the other side of the recipient rabbit by the application of the mouthpart suspension of the same insects.

In the first 3 unsuccessful attempts, it is likely that the virus concentration in the tumor was still insufficient for transmission, or that free virus was not present in that part of the tumor penetrated by the arthropod mouthparts. When the tumors were of 183 days duration or older and found to be non-infective for the insects, a portion of the tissue was prepared in a suspension that was applied to the scarified skin of 2 test rabbits. Negative results indicated a lack of infectious virus. This is in accord with the known experience of past investigators who have found a lack of infectious virus in cottontail papillomas during their stationary, regressive, or malignant phases.

At times, cottontails may develop papillomas that fail to yield infectious virus at any stage of development.

Transmission through Virus-Moistened Skin

Rendtorff and Wilcox (7) attempted transmission of fibroma and papilloma viruses to rabbits through the penetration of virus-moistened skin by the larvae of *Nippostrongylus muris* (Nematoda, Trichostrongylidae). Fibromas did not develop, but papillomas did. Dalmat (8) showed that neither *A. aegypti* nor *R. prolixus* could induce fibroma development by feeding through the rabbit skin moistened with a virulent virus suspension. Mosquitoes that had had their mouthparts painted with virus failed to induce fibromas upon refeeding 4 hours after the application or later (8, 9).

In each of 2 experiments, the skin of 2 domestic rabbits and 2 cottontails was moistened with a papilloma suspension through which *A. aegypti*, *An. quadrimaculatus*, and *R. prolixus* were permitted to feed. The area exposed to each species of insect was marked. Papillomas appeared after 17 days at the sites on the domestic rabbits probed by all 3 species, and after 21 days in the cottontails (Fig. 2). Why, in the case of papilloma virus, insects were effective in transmitting papillomatosis by feeding through the virus-moistened skin, while in the case of fibromatosis they were not (7, 8), has not yet been determined.

Transmission from Subcutaneous Extensions of the Papillomas

When the papillomas of cottontails 9-8 and 9-8C (9-8C had been infected by insects that had previously fed on tumors of 9-8) were 252 days and 149 days old respectively, bulging, subcutaneous growths were seen to protrude from next to the base of the main papillomatous mass of each rabbit, by that time overlain with much keratin. Growths of similar sort subsequently developed in more distant sites and appeared separate from the earlier subcutaneous growths and from the typical keratin-covered papillomas. These satellite growths appeared identical with the subcutaneous cysts already described that are due to subcutaneous extensions of papillomas along the lymphatics toward the regional glands which they occasionally reach (10). Sometimes cancer arises from them. It has been the experience of investigators working with the carcinomas derived from papillomas, that virus cannot be recovered from them or from the papillomas themselves once they are progressing toward cancer (12). It was, therefore, decided to test the ability of arthropods to extract virus from these cysts.

A summary of efforts to transmit by arthropods the virus from the sub-

cutaneous cysts associated with the cottontail papillomas is given in Table II. Only positive findings have been listed.

It can be seen that both *A. aegypti* and *R. prolixus* were able to transmit virus from the subcutaneous nodules of Cottontail 9-8 (252-day infection)

TABLE II
Insect Transmission of Virus from Satellite Growths Associated with Cottontail Papillomas*

Donor rabbit	Duration of primary infection	Recipient rabbit	Mode of passage† by insect vector	Days from tumor meal to passage	Days for appearance of tumors
Cottontail 9-8	days 252	Domestic 1-64B	Refeeding	6	9
Domestic 1-64B	14	Domestic 1-64D	Interrupted meal	0	9
Cottontail 9-8C	183	Domestic 1-64G	Interrupted meal and suspension of mouthparts	0	31
Cottontail 9-8C	198	Cottontail 9-8D	Interrupted meal	0	45
Cottontail 9-8C	215	Domestic 1-64P	Suspension of mouthparts	0	9
Cottontail 9-8C	231	Domestic 1-64S	Suspension of mouthparts	0	12
Cottontail§ 9-8C	550	Domestic 1-94A	Refeeding	4	28

* *Aedes aegypti* were employed in all cases. *Rhodnius prolixus* (10) were also used in transmission from Cottontail 9-8.

† Refeeding indicates an interval between the original feeding of the insect on the satellite growth and the attempt at passage to the recipient host by a second meal. For an interrupted meal the insect was permitted to take only a partial meal on the tumor, terminating it on the recipient host.

§ Insects transmitted from a cancerous region just bordering the remaining papillomatous horns.

when they were refed on Domestic rabbit 1-64B 6 days after their infectious meal. The resulting tumors were, in turn, infective for *A. aegypti* that transmitted infection to Domestic rabbit 1-64D by interrupted feeding. In both domestic rabbits some nodules very soon appeared that were markedly different from the usual papillomas, and they arose more rapidly (Fig. 3). The tumors of Domestic rabbit 1-64B were still intact when the animal was sacrificed 23 days after infection, and those of Domestic rabbit 1-64D were in

good condition when 24 days old, but regressed within 35 days. Since these growths resembled rabbit fibromas, it was thought that Cottontail rabbit 9-8 might have had a mixed infection. During the course of these studies, serums of Cottontails 9-8 and 9-8C, and of several of the domestic rabbits that developed atypical tumors, were tested for fibroma-neutralizing antibodies but these could not be demonstrated.

When the primary papillomas of Cottontail 9-8 were 272 days old, one of the subcutaneous growths ruptured, the dried skin over it as well as the contents being ejected. The contents appeared like a mass of yellowish white clay-like material that readily fissured and crumbled with handling, and section showed it to be keratin. When a suspension of this material was rubbed into the scarified skin of Domestic rabbit 1-64E, several large, bright pink growths arose within 7 days, which were subepidermal (Fig. 4) and distinct from either typical surface papillomas or from the subepidermal cysts. After 23 days the skin surfaces over these growths were crusting. After 29 days, they were heavily crusted, were crateriform, had fused in some instances and were becoming smaller, while typical, small, scattered papillomatous horns had arisen in the same general region (Fig. 5). After 44 days, the strange lesions had disappeared (Fig. 6), whereas the papillomas were further developed.

The bright pink nodules were not examined histologically, but the typical papillomatous horns that arose subsequently were studied 30 days after their first appearance (59 days from the date the animal was infected). The sections showed typical, multiple, superficial papillomata with adjacent intraepithelial abscesses. Mitoses were rare.

The atypical nodules that initially arose on Domestic rabbit 1-64E superficially resembled rabbit fibromas. However, undiluted serum prepared from this rabbit 43 days after infection failed to neutralize 100 infectious doses of virus, indicating the absence of fibroma virus. Thus, the nature of the rapidly appearing pink growths remains uncertain.

By the time the primary papillomas of Cottontail 9-8 were about 300 days old, all the subcutaneous cysts had ruptured and in the place of one of them a red, fleshy, raised growth developed. Within 4 months of its appearance the central portion became somewhat concave, the raised periphery rigid, and the animal succumbed. The new epidermal growth just described consisted of highly anaplastic epithelium, with many mitoses, atypical nuclear dyskaryosis, and with malignant invasion. In short it was a cancer. The lungs contained metastatic abscesses, but no metastatic tumor. Unfortunately, no attempts were made to determine whether mosquitoes could pick up virus from this lesion while it was progressing toward malignancy.

For 2 of the further attempts at arthropod transmission (Table II), 2 satellite growths of Cottontail 9-8C were utilized when its primary papillomas were 183 days old.

Transmission to Domestic rabbit 1-64G was accomplished by interrupted feeding of *A. aegypti* that had had their first meal on one of these growths, producing typical papillomas that appeared within 31 days. Growths were also induced by a mouthpart suspension of these

mosquitoes, which was applied to the scarified skin of the same recipient rabbit. By both subcutaneous inoculation of a suspension of these papillomas into a domestic rabbit and by rubbing the suspension into the scarified skin of the same recipient host, atypical growths, similar to those of Domestic 1-64B, developed within 6 days. A suspension prepared of these growths when 14 days old was rubbed into the scarified skin of a cottontail rabbit, inducing typical papillomatous horns that first became evident in about 190 days. The serums of the recipient domestic and cottontail rabbits did not contain demonstrable fibroma antibody. When the papilloma infection of Cottontail 9-8C was 198 days old, transmission was again accomplished by mosquitoes from the same satellite growth, the new tumors arising within 45 days in recipient Cottontail 9-8D. These became typical papillomatous horns. Mosquitoes transmitted virus a third time from the satellite growth when the primary papillomas were 215 days old, and also from a second, newly emerged, rapidly developing subcutaneous growth when the primary papillomas were 231 days old. When the primary tumors were 245 days old, the contents of the older satellite growth, rubbed into the prepared skin of both a domestic and cottontail rabbit, induced development of papillomatous horns. However, the contents of the second satellite growth of Cottontail 9-8C (prepared when the primary papillomas were 298 days old), when applied to the abraded skin of a domestic rabbit, resulted in nodules similar to those which had been induced in Domestic rabbit 1-64E (Fig. 4) by application of a suspension of the contents of a subcutaneous growth of Cottontail 9-8 when its primary papillomas were 252 days old.

Histological study of the 2 satellite growths of Cottontail 9-8C used in the transmission experiments just described showed them to be cystic extensions in the subcutaneous tissues, with no evidence of malignancy. The cells had maintained their polarity and showed no more mitotic activity than that in the primary tumor. The cysts were filled with keratin and had a papillary lining with well differentiated basal cells like those of the basilar layer of the primary growth.

When the papilloma infection of Cottontail 9-8C was about 400 days old, a large, fleshy, raised mass replaced the satellite cystic growths. Five months later this also was extending over much of what had formerly been papillomatous (Fig. 7). Groups of mosquitoes were permitted to feed on various regions of the fleshy area and to refeed 4 days later on a clean domestic rabbit (1-94A). Only those mosquitoes that fed along the periphery, near some remaining papillomatous horns, transmitted virus. Suspensions of the fleshy mass, the horns, and lymph nodes were also applied to the scarified skin of a rabbit, only the horn suspension inducing papillomas. Microscopic studies showed the large, fleshy growth to be a squamous cell carcinoma with metastases to the lymph nodes and lungs. The horns near which the mosquitoes had picked up virus showed marked differentiation, though with many abnormal mitotic figures and basal invasion into the underlying muscle. They had retained the ability to produce keratin.

DISCUSSION

Transmission of rabbit papilloma virus by arthropods has been reported only once before (3). The experiments presented in this paper demonstrate that mosquitoes and assassin bugs can transmit this virus from cottontail rabbit to either cottontail or domestic rabbit. There is no latent period after their infective meal. Transmission was successful by interrupted feeding, by feeding of the insects on a recipient host after an interval from the infective meal, and by application of a suspension of the insect mouthparts to the

scarified skin either immediately after the infective feed or several days later. All this indicates that transmission by arthropods probably is mechanical, similar to that achieved by application of tumor suspensions to scarified skin. Other tumor-inducing viruses of rabbits, namely those causing myxomatosis and fibromatosis, have been shown to be mechanically transmitted (13, 14, 8).

Extracts of the papillomas experimentally induced in domestic rabbits by rubbing cottontail material into scarified skin are ordinarily inactive (1) and at best produce indolent growths (4) and usually very few of these (5, 6). Many have considered that the virus in domestic rabbit papillomas is in a masked form, not recognizable by the usual techniques (15, 16), although demonstrable by serological methods (12, 15, 17, 18). However, the sensitivity of the domestic test animal can be increased by making the skin hyperplastic with methylcholanthrene or a turpentine-acetone mixture so that infectivity of wart suspensions from many domestic rabbits can be demonstrated (5, 6). In the experiments here reported, insects have been shown capable of transmitting virus from domestic rabbit to domestic rabbit without the need for special preparation of the skin of the recipient animals. Several of the tumors of the donor domestic rabbits had the gross appearance of rabbit fibromas and emerged within a short period of time, as do fibromas. However, normally sensitive fibroma neutralization tests, performed with the serums of the animals bearing the questionable growths, did not neutralize virus. Histological studies of these growths were not made.

In view of the ease with which papilloma virus is transmitted by insects, it would seem desirable to continue to employ them as a tool in further attempts to extract virus from domestic rabbit papillomas and from the carcinomas resulting from the papillomas of both cottontail and domestic rabbits. It is probable that biting insects other than mosquitoes and assassin bugs would also serve well in transmission experiments.

SUMMARY

The virus of rabbit papillomatosis, a neoplastic disease studied intensively in relation to cancer because of its tendency toward malignant transformation, has been successfully transmitted by *Aedes aegypti*, *Rhodnius prolixus*, and *Triatoma infestans* from papillomas induced in cottontail rabbits, and by the first species mentioned, from papillomas induced in domestic rabbits. This was accomplished by interrupted feeding, feeding after an interval of several days from the infective meal, or by application of a suspension of the mouthparts of the insects either immediately after their infective meal or several days later.

Insect transmission was also successful from the satellite growths resulting from subcutaneous extensions of the typical papillomas of infected cotton-

tails, and from certain peculiar, subcutaneous nodules, arising rapidly after infection, and not heretofore described. Although the latter growths resembled rabbit fibromas, antibodies to fibroma virus could not be demonstrated by neutralization tests with the sera of the animals involved.

BIBLIOGRAPHY

1. Shope, R. E., Infectious papillomatosis of rabbits. With a note on the histopathology by E. W. Hurst, *J. Exp. Med.*, 1933, **58**: 607.
2. Syverton, J. T., The pathogenesis of the rabbit papilloma-to-carcinoma sequence, in Viruses as causative agents in cancer, *Ann. New York Acad. Sc.*, 1952, **54**: 1126.
3. Larson, C. L., Schillinger, J. E., and Green, R., Transmission of rabbit papillomatosis by the rabbit tick, *Haemaphysalis leporis-palustris*, *Proc. Soc. Exp. Biol. and Med.*, 1936, **33**: 536.
4. Shope, R. E., Serial transmission of virus of infectious papillomatosis in domestic rabbits, *Proc. Soc. Exp. Biol. and Med.*, 1935, **32**: 830.
5. Friedewald, W. F., Cell state as affecting susceptibility to a virus. Enhanced effectiveness of the rabbit papilloma virus on hyperplastic epidermis, *J. Exp. Med.*, 1942, **75**: 197.
6. Friedewald, W. F., and Kidd, J. G., The recoverability of virus from papillomas produced therewith in domestic rabbits, *J. Exp. Med.*, 1944, **79**: 591.
7. Rendtorff, R. C., and Wilcox, A., The role of nematodes as an entry for viruses of Shope's fibromas and papillomas of rabbits, *J. Infect. Dis.*, 1957, **100**: 119.
8. Dalmat, H. T., Arthropod transmission of virus-induced fibroma and papilloma of cottontail rabbits, dissertation submitted to The George Washington University in partial fulfillment of the requirements for the Ph.D. degree, 1957, June 5.
9. Kilham, L., and Dalmat, H. T., Host-virus-mosquito relations of Shope fibromas in cottontail rabbits, *Am. J. Hyg.*, 1955, **61**: 45.
10. Rous, P., and Beard, J. W., The progression to carcinoma of virus-induced rabbit papillomas (Shope), *J. Exp. Med.*, 1935, **62**: 523.
11. Rous, P., Beard, J. W., and Kidd, J. G., Observations on the relation of the virus-causing rabbit papillomas to the cancers deriving therefrom. II. The evidence provided by the tumors: General considerations, *J. Exp. Med.*, 1936, **64**: 401.
12. Kidd, J. G., Beard, J. W., and Rous, P., Serological reactions with virus-causing rabbit papillomas which become cancerous. I. Tests of the blood of animals carrying the papilloma, *J. Exp. Med.*, 1936, **64**: 63.
13. Fenner, F., Day, M. F., and Woodroffe, G. M., The mechanism of the transmission of myxomatosis in the European rabbit (*Oryctolagus cuniculus*) by the mosquito *Aedes aegypti*, *Austral. J. Exp. Biol. and Med. Sc.*, 1952, **30**: 139.
14. Day, M. F., Fenner, F., Woodroffe, G. M., and McIntyre, G. A., Further studies on the mechanism of mosquito transmission of myxomatosis in the European rabbit, *J. Hyg.*, 1956, **54**: 258.
15. Shope, R. E., Immunization of rabbits to infectious papillomatosis, *J. Exp. Med.*, 1937, **65**: 219.

16. Kidd, J. G., Immunological reactions with a virus causing papillomas in rabbits. III. Antigenicity and pathogenicity of extracts of the growths of wild and domestic species: General discussion, *J. Exp. Med.*, 1938, **68**: 737.
17. Kidd, J. G., Beard, J. W., and Rous, P., Serological reactions with virus causing rabbit papillomas which become cancerous. II. Tests of the blood of animals carrying various epithelial tumors, *J. Exp. Med.*, 1936, **64**: 79.
18. Kidd, J. G., and Rous, P., A transplantable rabbit carcinoma originating in a virus-induced papilloma and containing the virus in masked or altered form, *J. Exp. Med.*, 1940, **71**: 813.

EXPLANATION OF PLATES

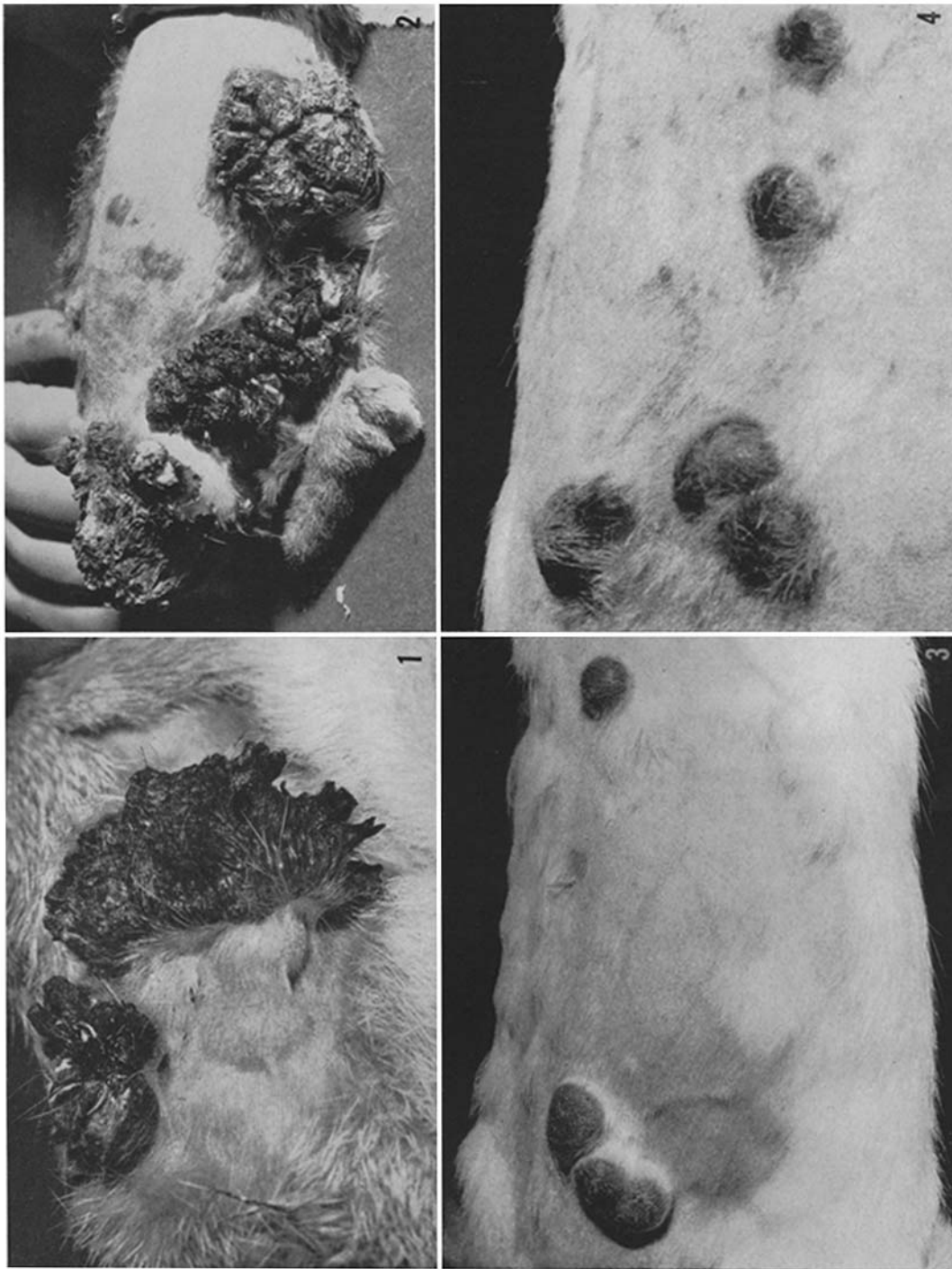
PLATE 1

FIG. 1. Papillomas (162 days old) of Cottontail 9-8C, induced by the refeeding of *Aedes aegypti* 4 days after they had fed on the papillomas of Cottontail 9-8. Note the developing subcutaneous cysts. $\times 0.8$.

FIG. 2. Papillomas (93 days old) of a cottontail rabbit due to the feeding through virus-moistened skin of *Aedes aegypti* (left), *Anopheles quadrimaculatus* (middle), and *Rhodnius prolixus* (right). $\times 0.4$.

FIG. 3. Growths (33 days old) of Domestic rabbit 1-64B resulting from feeding of *Aedes aegypti* that had fed on a subcutaneous papilloma of Cottontail 9-8 6 days previously. $\times 0.6$.

FIG. 4. Growths of Domestic rabbit 1-64E resulting from application to the scarified skin 13 days previously of a suspension of the contents of one of the subcutaneous growths of Cottontail 9-8. $\times 0.8$.



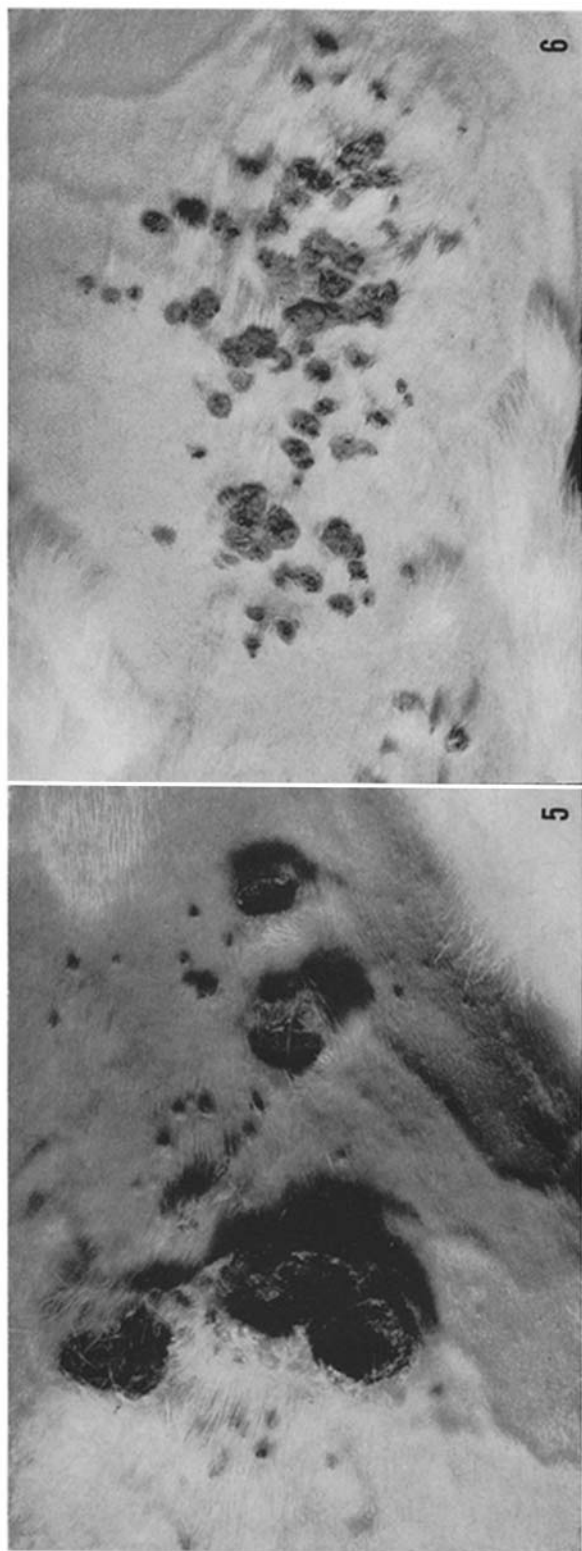
(Dalmat: Arthropod transmission of papillomatosis)

PLATE 2

FIG. 5. Same as in Fig. 4, 29 days after infection. Note the development of small papillomas in the same general area where the growths of Fig. 4 are regressing. $\times 0.9$.

FIG. 6. Same as in Fig. 5, 44 days after infection. The initial lesions have completely regressed while the papillomatous horns have developed further. $\times 0.9$.

FIG. 7. Large ulcerating mass that replaced the satellite cystic growths and much of the typical papillomatous expanse of Cottontail 9-8C-photographed 550 days after infection of a rabbit by arthropods fed on the papillomas of Cottontail 9-8. The mass was microscopically determined to be a squamous cell carcinoma. Arrows indicate the region in it from which mosquitoes picked up the papilloma virus while feeding. $\times 0.4$.



(Dalmat: Arthropod transmission of papillomatosis)