

Original Article

The influence of rotator cuff pathology on functional outcome in total shoulder replacement

Nathanael Ahearn, Philip A McCann, Andrew Tasker, Partha P Sarangi

ABSTRACT

Introduction: Total shoulder replacement (TSR) is a reliable treatment for glenohumeral osteoarthritis. In addition to proper component orientation, successful arthroplasty requires accurate restoration of soft tissues forces around the joint to maximize function. We hypothesized that pathological changes within the rotator cuff on preoperative magnetic resonance imaging (MRI) adversely affect the functional outcome following TSR.

Materials and Methods: A retrospective analysis of case notes and MRI of patients undergoing TSR for primary glenohumeral osteoarthritis over a 4-year period was performed. Patients were divided into three groups based upon their preoperative MRI findings: (1) normal rotator cuff, (2) the presence of tendonopathy within the rotator cuff, or (3) the presence of a partial thickness rotator cuff tear. Intra-operatively tendonopathy was addressed with debridement and partial thickness tears with repair. Functional outcome was assessed with the Oxford Shoulder Score (OSS), and quick disabilities of the arm, shoulder and hand score (quick-DASH).

Results: We had a full dataset of complete case-notes, PACS images, and patient reported outcome measures available for 43 patients, 15 in group 1, 14 in group 2, and 14 in group 3. Quick-DASH and OSS were calculated at a minimum of 24 months following surgery. There was no statistically significant difference between the results obtained between the three groups of either the OSS ($P = 0.45$), or quick-DASH ($P = 0.46$).

Conclusions: TSR is an efficacious treatment option for patients with primary glenohumeral osteoarthritis in the medium term, even in the presence of rotator cuff tendonopathy or partial tearing. Minor changes within the cuff do not significantly affect functional outcome following TSR.

Key words: MRI, outcome measures, rotator cuff, total shoulder replacement

INTRODUCTION

The aim of joint replacement surgery is to treat the symptoms of arthritis by reducing pain and improving function. Anatomically inspired shoulder prostheses mimic native articular surfaces with the ultimate aim of replicating normal shoulder biomechanics.^[1] Such implants are stabilized by the same mechanisms as the native glenohumeral joint,^[2] namely the rotator cuff. In addition to proper component orientation, successful arthroplasty requires accurate restoration of the soft tissues forces around the joint to maximize function.

Unconstrained anatomical implants are used in patients with primary glenohumeral osteoarthritis and a functioning rotator cuff. The current range of implants available may be broadly divided into humeral head resurfacing (with or without a glenoid component) and total shoulder replacement (TSR), which utilize a stemmed humeral implant. Current opinion favors TSR^[3-4] as it improves pain, range of motion, patient satisfaction, and has a significantly lower rate of revision surgery compared with humeral head resurfacing.^[5]

A thorough history and comprehensive examination will often distinguish between primary glenohumeral arthritis and cuff

Access this article online

Website:

www.internationalshoulderjournal.org

DOI:

10.4103/0973-6042.123509

Quick Response Code:



Department of Orthopaedic Surgery,
Level 5 Queens Building, Bristol Royal
Infirmary, Upper Maudlin Street, Bristol
BS2 8HW, United Kingdom

Address for correspondence:

Mr. Nathanael Ahearn,
24 Withey Close West, Bristol,
BS9 3SX, United Kingdom.
E-mail: nahearn@nhs.net

tear arthropathy. Plain radiographs may also be diagnostic, with loss of acromio-humeral joint space secondary to superior migration of the humeral head seen in cuff tear arthropathy.^[6] In primary glenohumeral osteoarthritis the rotator cuff is usually intact, or has only minimal lesions.^[7]

Diligent preoperative assessment is required to assess patency of the rotator cuff prior to TSR, using clinical examination techniques and appropriate investigations. Magnetic resonance imaging (MRI) confers potential benefits, in addition to diagnosis of rotator cuff tears, prior to operative intervention. It is able to demonstrate further pathology, such as acromioclavicular joint osteoarthritis and other soft tissue lesions that may influence management decisions. MRI is also able to evaluate glenoid bone stock and orientation of the glenoid.^[8] It is also more accurate than plain radiography in determining the extent of the characteristic glenoid retroversion that occurs with this degenerative process.^[9]

The size of rotator cuff tear measured preoperatively on arthrography or MRI scan has been shown to influence functional outcome following surgery to repair the rotator cuff.^[10] Tears of the subscapularis tendon has been shown to cause significant weakness in internal rotation strength testing, as well as significantly worse disabilities of the arm, shoulder and hand (DASH) scores in patients postoperatively following TSR.^[11] There have been no studies thus far who have correlated rotator cuff integrity on preoperative MRI scans with postoperative shoulder function following TSR. It is our standard practice to investigate patients listed for shoulder arthroplasty with MRI along with our routine clinical and plain radiographic assessment. The aim of this study was to assess whether the information obtained from further investigation of the rotator cuff can influence postoperative outcome.

MATERIALS AND METHODS

We performed a single surgeon, retrospective review of all patients who underwent elective shoulder arthroplasty at our institution between June 2007 and August 2011. Patients were traced by operative procedure code from computerized theatre records. Radiology was available *via* the Picture Archiving and Communications System (PACS) Centricity® Web software (GE Healthcare, Chalfont St Giles, UK). Primary TSR for glenohumeral osteoarthritis was the inclusion criteria for the study. Patients undergoing hemiarthroplasty, reverse geometry shoulder replacement for cuff tear arthropathy, or primary TSR for proximal humeral fracture were excluded. All procedures were performed by the senior author (PPS), with a standard operative technique and postoperative rehabilitation protocol used in all cases (EPOCA, Synthes, Paoli, Pennsylvania).

Patients were divided into three groups based upon their MRI findings, which were all reported by the head of the musculoskeletal radiologist service within our institution.

The reports stated the presence of a normal rotator cuff (group 1; Figure 1), the presence of tendonopathy within the rotator cuff (group 2; Figure 2), or the presence of a partial thickness rotator cuff tear (group 3; Figure 3). At the time of surgery an assessment of the integrity of the rotator cuff was assessed. Intra-operatively tendonopathy was addressed with debridement and partial thickness tears with repair.

Postoperatively patient reported outcome measures *via* an Oxford Shoulder Score (OSS),^[12] and quick disabilities of the arm, shoulder and hand score (quick-DASH)^[13] were obtained. Outcome measures were collected at a minimum of 24 months following surgery.

Statistical analysis was performed to compare the results following TSR in patients within each group of rotator cuff disease and those with a normal rotator cuff. This was performed using Analysis of Variance (ANOVA), and significance was determined to be at a *P*-value <0.05.

RESULTS

Elective TSR was performed in 51 patients who met our study inclusion criteria. We found that two patients had died since their surgery. We had a full dataset of complete case-notes, PACS images, and patient reported outcome measures available for 43 (88%) patients. Of these patients 17 (39.5%) patients were male and 26 (60.5%) patients were female. The mean age of patients at the time of surgery was 69.9 years (43–88). All patients had preoperative radiographs with evidence of glenohumeral joint osteoarthritis. Of the original patient group, 20 patients (39.2%) had MRI scans reported as normal, 17 (33.3%) had MRI scans reported as showing the presence of tendonopathy, and 14 (27.5%) had MRI scans reported as showing the presence of a partial thickness rotator cuff tear. One patient who was reported as having tendonopathy on MRI had a partial thickness tear of supraspinatus at the time of surgery. Another whose rotator cuff was thought to be intact on scan had a partial thickness tear of subscapularis found at the time of surgery. Both these patients were placed into the rotator cuff tear group, and their tears were repaired at the time of surgery. In the rotator cuff tear group there were supraspinatus tears in all but two patients who had tears in subscapularis. There was an additional infraspinatus tear in three patients. Both the tendonopathy and partial thickness cuff tear groups had lesions predominantly in supraspinatus [Table 1].

There were patient reported outcome measures obtained from a total of 15 patients in group 1, 14 in group 2, and 14 in group 3 [Chart 1]. The characteristics of each group are summarized below [Table 2]. Quick-DASH and Oxford Shoulder Scores were calculated at a minimum of 24 months following surgery, with the mean time from surgery to patient reported outcome measures being 32.5 months (24–46) in group 1, 35.2 months (24–62) in group 2, and 37.6 months (24–57) in group 3.

For patients with a normal MRI scan the mean Oxford score was 41.4 (31→48) and mean quick-DASH score was 12.4 (0-36.4). For the group with tendonopathy reported on the MRI the mean Oxford score was 38.2 (19-48) and mean quick-DASH score was 18.3 (0-56.8). For patients who had evidence of a rotator cuff tear either on MRI or intra-operatively the mean Oxford score was 39.9 (27→48) and mean quick-DASH score was 16.1 (0-36.4) [Chart 2].

Table 1: Table to show location of rotator cuff tendon pathology identified

Study Group	Infraspinatus	Supraspinatus	Subscapularis
Tendonosis (n=17)	2 (12%)	15 (88%)	2 (12%)
Partial Cuff Tear (n=14)	3 (21%)	12 (86%)	2 (14%)

Table 2: Table to show patient demographics of each group, divided by pre-operative MRI findings

	Group 1 - Normal	Group 2 - Tendonosis	Group 3 - Partial Cuff Tears
Mean age (years)	66.5 (57-76)	72.0 (58-88)	68.4 (43-86)
Sex (female %)	66.7% female	50.8% female	70.8% female
Mean time from surgery (months)	24.1 (3-46)	28.2 (7-57)	33.0 (7-57)

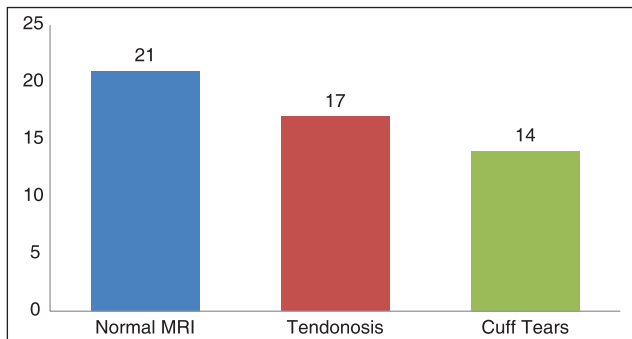


Chart 1: Graph to show number of patients in each group, divided by preoperative MRI findings

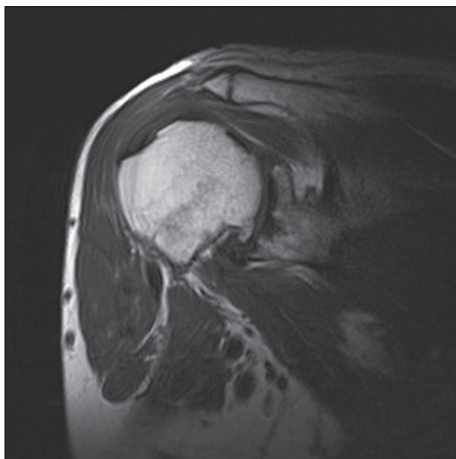


Figure 1: T2 weighted coronal MRI scan showing intact rotator cuff with muscle belly of normal signal and volume

There was no statistically significant difference between the results obtained between the three groups on either the Oxford Shoulder Score ($P = 0.45$), or quick-DASH ($P = 0.46$).

DISCUSSION

This study aimed to determine the effect of preoperative rotator cuff pathology on postoperative TSR function. We hypothesized that pathological changes within the cuff on preoperative MRI would adversely affect the functional outcome following TSR. Our study has demonstrated that the presence of mild rotator cuff disease on preoperative MRI has no significant effect on postoperative function following TSR. The functional outcomes were assessed at a mean 35.1 months and minimum 24 months following surgery.

Diagnosis of rotator cuff deficit, particularly small tears or tendonopathy is difficult and the true incidence is unknown.^[14]

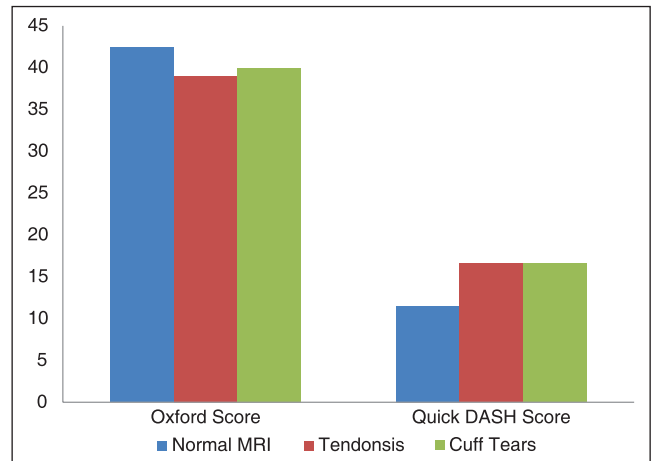


Chart 2: Graph to show postoperative quick-DASH and Oxford Shoulder Score of each group, divided by preoperative MRI findings

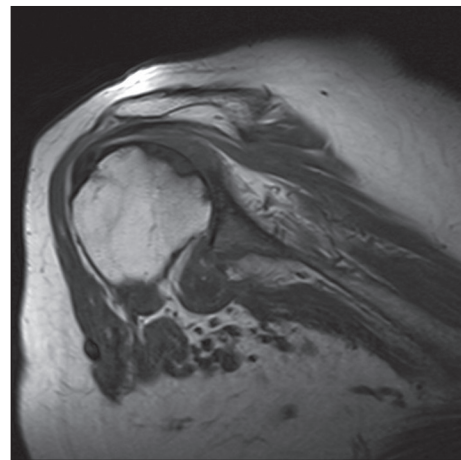


Figure 2: T2 weighted coronal MRI scan showing abnormal increased signal in the distal supraspinatus tendon which appears to be thinned and compressed with no definite tear or tendon retraction seen

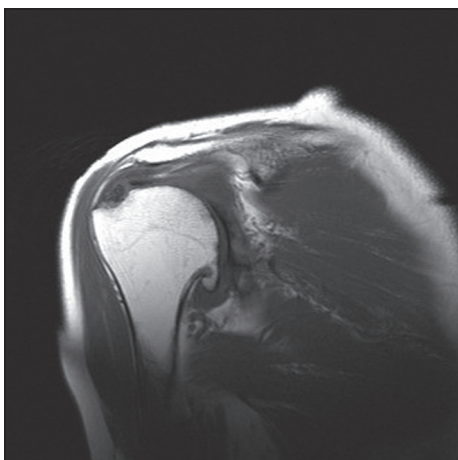


Figure 3: T2 weighted coronal MRI scan showing partial tearing of the supraspinatus tendon attachment. No full thickness tear or retraction is identified

Conventional arthrography had long been considered the gold standard investigation of rotator cuff tears,^[15] but this has been superseded by ultrasound (US), MRI, and MR-arthrography.^[14] MRI scanning has demonstrated equivalence to arthrography, when compared to an arthroscopic reference standard,^[16] and been shown to be equal to US to accurately determine the presence of a large or small rotator cuff tear.^[17] A recent meta-analysis concluded that MR-arthrogram is more sensitive and specific than either MRI or ultrasound scan in the diagnosis of full or partial thickness rotator cuff tears.^[18] By correlating the scan reports with operative findings, rotator cuff disease was diagnosed with a sensitivity of 87.5% and specificity of 100% in our study.

Edwards *et al.*,^[19] performed a large multi-center, multi-surgeon retrospective review of a series of primary shoulder arthroplasties performed for a variety of diagnoses. They correlated preoperative rotator cuff findings diagnosed on computed tomography scans with postoperative constant scores, mobility parameters, and subjective satisfaction. They concluded that small tears of the supraspinatus tendon do not appreciably affect outcome parameters in shoulder arthroplasty. Tendonopathy of infraspinatus and to a lesser degree subscapularis were found to adversely affect outcome. In our study we had two patients with tears in subscapularis and two with tears in infraspinatus. In these patients the mean OSS was 39.6 (33→45), and mean quick-DASH was 16.4 (9.1→29.5). These functional scores are toward the lower end, but no significant difference was observed. This may be due to the relatively small numbers of our study, as the majority of tendonopathic change or partial thickness tears were present in supraspinatus, but also the fact our study group was more tightly regulated and homogeneous in operative and rehabilitation protocol, being a single surgeon series. TSR was performed only for isolated primary glenohumeral osteoarthritis in our study, with strict exclusion criteria. This study also used MRI scan as opposed to CT scans to diagnose preoperative cuff

disease. Regarding the outcome measures used, the Oxford Shoulder Score and DASH scores were used as they correlate well with the constant score, but obviate the need for a trained investigator and the specialist equipment required to perform the constant score.^[20] It has also been demonstrated that the DASH score is of particular benefit following TSR as it allows for a comprehensive measurement of limb function.^[21] Our study compares favorably with other studies in relation to postoperative function following TSR, with respect to Oxford Shoulder Score and quick-DASH score.^[22,23]

This study has potential limitations. It was retrospective and therefore reliant on the accuracy and availability of case-notes results and subjected to potential recall bias. There are a small number of patients involved in the study, and a larger prospective study with patient reported outcome measures used preoperatively may have benefited our outcome. The study is completed at a minimum of 24 months postoperatively, although longer follow-up following surgery would potentially validate the findings further.

CONCLUSIONS

Our study demonstrates that total shoulder replacement is an efficacious treatment option for patients with primary glenohumeral osteoarthritis in the medium term, even in the presence of rotator cuff tendonopathy or partial tearing, which can be addressed at time of surgery. Minor changes within the cuff should not preclude patients undergoing total shoulder replacement in primary glenohumeral joint osteoarthritis.

REFERENCES

- Schneider D, Lee T. The biomechanics of total shoulder arthroplasty. *Oper Tech Orthop* 2002;12:2-9.
- Matsen FA 3rd, Boileau P, Walch G, Gerber C, Bicknell RT. The reverse total shoulder arthroplasty. *J Bone Joint Surg Am* 2007;89:660-7.
- Hattrup SJ. Current controversies in shoulder arthroplasty. *Curr Opin Orthop* 2001;12:301-6.
- Wiater MJ, Fabing MH. Shoulder Arthroplasty: Prosthetic Options and Indications. *J Am Acad Ortho Surg* 2009;17:415-25.
- Radnay CS, Setter KJ, Chambers L, Levine WN, Bigliani LU, Ahmad CS. Total shoulder replacement compared with humeral head replacement for the treatment of primary gleno-humeral osteoarthritis: A systematic review. *J Shoulder Elbow Surg* 2007;16:396-402.
- Drake GN, O'Connor DP, Edwards TB. Indications for reverse total shoulder arthroplasty in rotator cuff disease. *Clin Orthop Relat Res* 2010;468:1526-33.
- Neer CS 2nd. Replacement arthroplasty for glenohumeral osteoarthritis. *J Bone Joint Surg Am* 1974;56:1-13.
- Feeley BT, Gallo RA, Craig EV. Cuff tear arthropathy: Current trends in diagnosis and surgical management. *J Shoulder Elbow Surg* 2009;18:484-94.
- Raymond AC, McCann PA, Sarangi PP. Magnetic resonance scanning vs axillary radiography in the assessment of glenoid version for osteoarthritis. *J Shoulder Elbow Surg* 2013;22:1078-83.
- Iannotti JP, Bernot MP, Kuhlman JR, Kelley MJ, Williams GR. Postoperative assessment of shoulder function: A prospective

- study of full-thickness rotator cuff tears. *J Shoulder Elbow Surg* 1996;5:449-57.
11. Jackson JD, Cil A, Smith J, Steinmann SP. Integrity and function of the subscapularis after total shoulder arthroplasty. *J Shoulder Elbow Surg* 2010;19:1085-90.
 12. Dawson J, Fitzpatrick R, Carr A. Questionnaire on the perceptions of patients about shoulder surgery. *J Bone Joint Surg Br* 1996;78:593-600.
 13. Hudak PL, Amadio PC, Bombardier C. Development of an upper extremity outcome measure: The DASH (disabilities of the arm, shoulder and hand). The Upper Extremity Collaborative Group (UECG). *Am J Ind Med* 1996;29:602-8.
 14. Matava MJ, Purcell DB, Rudzki JR. Partial-thickness rotator cuff tears. *Am J Sports Med* 2005;33:1405-17.
 15. Mink J, Harris E, Rappaport M. Rotator cuff tears: Evaluation using double-contrast shoulder arthrography. *Radiology* 1985;157:621-3.
 16. Blanchard TK, Bearcroft PW, Constant CR, Griffin DR, Dixon AK. Diagnostic and therapeutic impact of MRI and arthrography in the investigation of full-thickness rotator cuff tears. *Eur Radiol* 1999 9:638-42.
 17. Teefey SA, Rubin DA, Middleton WD, Hildebolt CF, Leibold RA, Yamaguchi K. Detection and quantification of rotator cuff tears. Comparison of ultrasonographic, magnetic resonance imaging, and arthroscopic findings in seventy-one consecutive cases. *J Bone Joint Surg Am* 2004;86:708-16.
 18. de Jesus JO, Parker L, Frangos AJ, Nazarian LN. Accuracy of MRI, MR Arthrography, and Ultrasound in the diagnosis of rotator cuff tears: A meta-analysis. *AJR Am J Roentgenol* 2009;192:1701-7.
 19. Edwards TB, Boulahia A, Kempf JF, Boileau P, Nemoz C, Walch G. The influence of rotator cuff disease on the results of shoulder arthroplasty for primary osteoarthritis: Results of a multicenter study. *J Bone Joint Surg Am* 2002;84:2240-8.
 20. Allom R, Colegate-Stone T, Gee M, Ismail M, Sinha J. Outcome analysis of surgery for disorders of the rotator cuff: A comparison of subjective and objective scoring tools. *J Bone Joint Surg Br* 2009;91:367-73.
 21. Angst F, Goldhahn J, Drerup S, Aeschlimann A, Schwyzer HK, Simmen BR. Responsiveness of six outcome assessment instruments in total shoulder arthroplasty. *Arthritis Rheum* 2008;59:391-8.
 22. Al-Hadithy N, Doms P, Sewell MD, Naleem A, Papanna MC, Pandit R. Cementless surface replacement arthroplasty of the shoulder for osteoarthritis: Results of fifty Mark III Copeland prosthesis from an independent center with four-year mean follow-up. *J Shoulder Elbow Surg* 2012;21:1776-81.
 23. Kadum B, Mafi N, Norberg S, Sayed-Noor AS. Results of the Total Evolutive Shoulder System (TESS): A single-centre study of 56 consecutive patients. *Arch Orthop Trauma Surg* 2011;131:1623-9.

Source of Support: Nil, **Conflict of Interest:** There are no conflicts of interest.