

Microvascular Revascularization for Recurrent A1 Anterior Cerebral Artery Aneurysm Postendovascular Treatment: A Case Report and Review of the Literature

Abstract

The recurrence of aneurysms postcoil embolization is a common occurrence. Endovascular coiling has been noted to be more effective for small lesions rather than the giant aneurysms. A postembolization recurrent aneurysm is a difficult condition to manage. We present a case of a recurrent giant aneurysm of the anterior cerebral arteries (ACAs) first segment (A1). It was managed by superficial temporal artery to A3 segment of anterior cerebral artery bypass anastomotic revascularization plus distal A1- segment clipping. A literature review is presented for the management of giant A1 artery aneurysms.

Keywords: Aneurysm, coil embolization, clipping, cranial bypass, giant aneurysm, revascularization

Introduction

Postembolization recurrent aneurysms occur significantly in patients with intracranial aneurysms treated by coil embolization.^[1] Aneurysms occurring at the proximal A1 segment of the anterior cerebral artery (ACA) are uncommon, constituting 1%–4% of intracranial aneurysms. Giant aneurysms in this location are very rare.^[2,3] Endovascular coil embolization has been noted to be effective in small aneurysms and has been considered an effective treatment modality for A1 aneurysms. However, aneurysms arising from A1 are usually small, with a fragile wall and are often treated by microneurosurgical clipping.^[3] There is scanty information about the effectiveness of either method for giant aneurysms of A1.

Recanalization of aneurysms is more common with giant aneurysms and aneurysms in the posterior circulation with reported recanalization of 12%–54% of cases.^[4–8] Tight coil packing with a density of at least 20%–25% is known to be generally important for preventing recanalization after embolization of cerebral aneurysms. Large aneurysms sometimes recanalize regardless of the packing density, suggesting that the absolute residual

volume which is determined by aneurysm volume and packing density may be a more important risk factor for recanalization.^[9]

Case Report

The following is a case of recurrent ACA A1-segment giant aneurysm which recanalized postcoil embolization in a 60-year-old male. The first coiling was done 3 years earlier after rupture when he presented with subarachnoid hemorrhage of world federation of neurosurgical societies (WFNS) Grade 5. The aneurysm measured 26 mm in widest dimension. This was followed by ventriculoperitoneal shunt insertion for posthemorrhage-related progressive hydrocephalus 5 months later. The patient had to undergo second coiling 11 months after the first coiling because of recanalization, which again had to be redone after 6 months because of continued refilling. Despite the three coiling procedures, the repeat angiography confirmed the aneurysm had recanalized. An infarct is noted in the left frontal lobe on the computed tomography scan which occurred after the initial bleed [Figure 1]. The patient became hemiparetic as a result.

The patient was scheduled for left superficial temporal artery (STA) to ACA-A3 bypass with clip occlusion of the ACA ipsilaterally distal to the aneurysm

**Aaron Musara,¹
Yasuhiro Yamada¹,
Katsumi Takizawa²,
Kenichi Haraguchi¹,
Tsukasa Kawase¹,
Riki Tanaka¹,
Kyosuke Miyatani¹,
Takao Teranishi¹,
Krishna Mohan³,
Yoko Kato¹**

Department of Surgery, Neurosurgery Unit, University of Zimbabwe College of Health Sciences, Harare, Zimbabwe, ¹Department of Neurosurgery, Banbuntane Hotokukai Hospital, Fujita Health University, Toyoake, ²Department of Neurosurgery, Asahikawa Red Cross Hospital, Hokkaido, Japan, ³Department of Neurosurgery, KIMS Hospital, Nellore, Andhra Pradesh, India

Address for correspondence:

*Dr. Aaron Musara,
Department of Surgery,
Neurosurgery Unit, University
of Zimbabwe College of Health
Sciences, Harare, Zimbabwe.
E-mail: musaraaaron@zol.co.zw*

Access this article online

Website: www.asianjns.org

DOI: 10.4103/ajns.AJNS_113_19

Quick Response Code:



How to cite this article: Musara A, Yamada Y, Takizawa K, Haraguchi K, Kawase T, Tanaka R, et al. Microvascular revascularization for recurrent A1 anterior cerebral artery aneurysm postendovascular treatment: A case report and review of the literature. *Asian J Neurosurg* 2019;14:1004-7.

This is an open access journal, and articles are distributed under the terms of the Creative Commons Attribution-NonCommercial-ShareAlike 4.0 License, which allows others to remix, tweak, and build upon the work non-commercially, as long as appropriate credit is given and the new creations are licensed under the identical terms.

For reprints contact: reprints@medknow.com

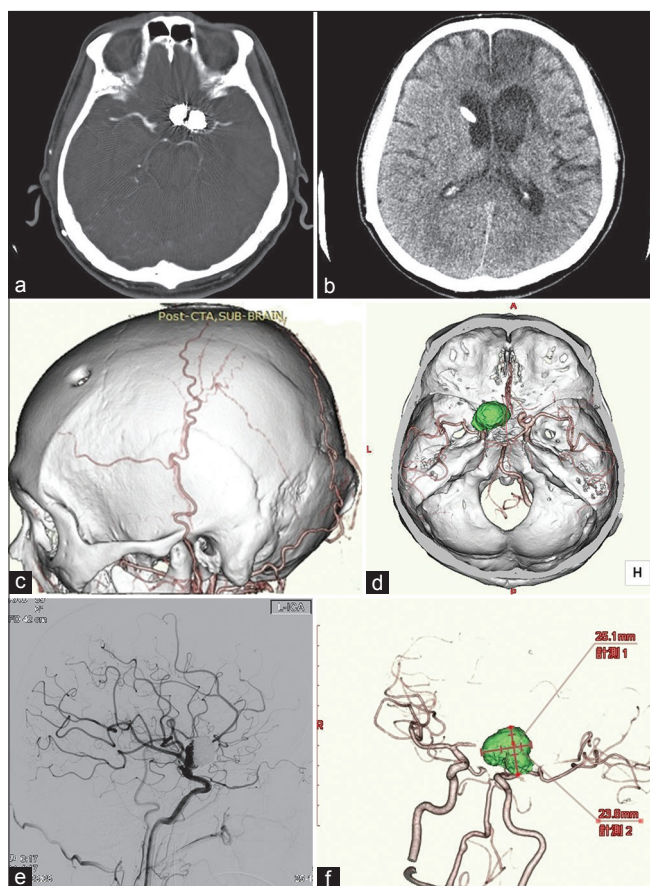


Figure 1: (a) A coronal computed tomography scan view of the brain with the coil *in situ*, (b) computed tomography scan of the brain showing the shunt *in situ* and a left anterior cerebral artery territory infarct, (c) three-dimensional computed tomography scan showing the STA artery, (d) a brain computed tomography reconstruction, three-dimensional brain computed tomography angiogram scan with the aneurysm showing the mass of coils, (e) shows the aneurysm filling on digital subtraction angiography and it is incompletely occluded, and (f) the aneurysm measuring 26.1 mm × 23.8 mm

before the anterior communicating artery. The strategy was to prevent further recanalization of the aneurysm, allowing for aneurysm thrombosis.

With the patient in supine position and the head turned 30° to the right on a Sugita frame, a curvilinear incision was made just behind the hairline, and the posterior (parietal) branch of the STA was isolated and prepared as the graft while fashioning a frontotemporal craniotomy. By microdissection, the carotid bifurcation and its branches, with the adjacent giant A1 aneurysm were exposed. Embolization coils were found lying outside the aneurysm [Figure 2a and b].

Adjacent frontal craniotomy was done in the parasagittal area to expose the A3 branches of the ACA [Figure 2c]. The patient's initial position needed just minor bed rotation to allow for the second osteotomy and anastomosis procedure without redoing the frame positioning. The STA-ACA bypass was done where the STA was anastomosed to the A3 segment of ACA (pericallosal artery) from the interhemispheric, supra-callosal area. The proximal segment

of ACA A1 segment could not be accessed because it was very short and continued manipulation created a risk of serious hemorrhage over the bifurcation of the carotid, which was noted to be atherosclerotic and with the short proximal segment being partially occluded by coils. There was no place for clip placement. The distal A1 segment was then occluded distally by clip ligation just proximal to the anterior communicating artery. To maximize on patient safety, motor-evoked potentials, indocyanine green, and dual-image video angiography were used during the procedure for safety monitoring [Figure 2e].

Discussion

Postembolization recurrent aneurysms have been reported several times in patients with intracranial aneurysms treated by embolization. In 2007, Tirakotai *et al.* classified the indications for surgical treatment after the coiling of aneurysms into the following three groups: (i) surgery of residual and recurrent aneurysms, (ii) surgery for mass effects on neural structures due to coil compaction, and (iii) surgery for vascular complications after endovascular procedures.^[1,10]

Retreating a recurrent aneurysm with additional coils is often bound for failure, in perhaps 50% of cases and it seems reasonable to offer something different than what was initially done to hope for better results.^[11] Proper patient selection for either coiling or clipping is important to avoid recanalization in the first place. Our patient had had coiling done three times and another treatment option, therefore, needed to be explored. Our patient was type III recanalization since the coils were partially occluding the vessel and the coils were also extruded outside the vessel. The narrowed vessel lumen caused by presence of the intraluminal coils coupled with atherosclerosis on a site with medial thalamostriate perforators precluded endovascular stenting with devices such as the flow diverting stents because of the increased risk both of injury to the main vessel and of occlusion of the perforators.^[12]

Some surgeons have advocated for clipping of the partially coiled aneurysm. Difficulties have, however, been reported because of the high risk of rupturing of the aneurysm during the clipping. In some cases, aneurysm trapping with occlusion of the proximal and distal segments relative to the aneurysm has been done.^[10] In this case, aneurysm clipping could not be done because of the very wide neck containing coils over a thickened wall. Proximal A1-segment occlusion could not be done because of the very small length of the segment which was inaccessible without posing a danger of rupturing the aneurysm or tearing the carotid bifurcation. Occlusion of A1 distal to the aneurysm and revascularization surgery through STA-A3 was, therefore, planned. Clip occlusion of the parent vessel with bypass revascularization protection of the brain has been well described before though the various series described proximal occlusion instead.^[1,5,10-15]

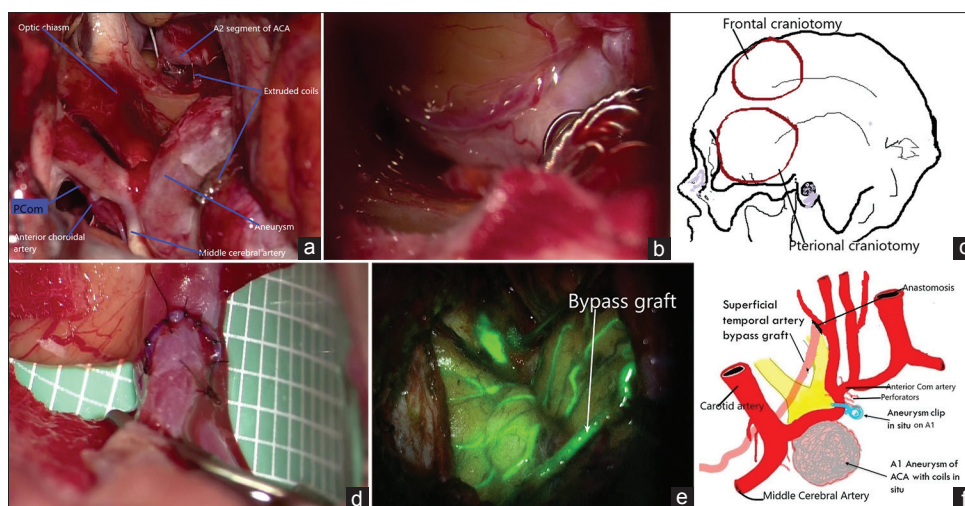


Figure 2: (a) Detailed intraoperative views seen at exposure of the aneurysm, (b) the extruded coils, (c) an illustration of the craniotomy done, (d) the bypass anastomosis, (e) a dual intraoperative visualization approach picture showing the patent graft just before the closure, and (f) graphic illustrative summary of the operation procedure done

Our patient had revascularization with STA-A3 segment anastomosis [Figure 2d]. Revascularization was important to ensure continued blood flow distal to the arterial occlusion after clipping. Occlusion with no plan for revascularization was going to risk the brain from infarction. The area getting revascularization had suffered an infarct before. This was delayed revascularization with less chance of revascularization injury.^[16,17] Aneurysm trapping was too risky and was, therefore, not done because of the risk of rupture and infarction in the distribution of the perforators involved. Distal A1-segment clipping was done as a way of stopping continued flow. Recoiling of the aneurysm to fill up the space is expected to result in complete obliteration of the aneurysm, thereby minimizing the risk of regrowth of the aneurysm. This technique may solve the perforator vessel ischemia problem that has been experienced with giant aneurysm trapping.^[18] This, however, still has the potential risk which still needs to be evaluated for possible growth of the aneurysm.^[19]

The posterior branch of the STA was used as the graft. This is because this was the longer and bigger branch of the artery as seen in Figure 1c. The posterior branch of the STA has been described in the literature as being usually the bigger and longer branch of the two terminal branches of STA, as it goes to anastomose its branches with the contralateral one.^[20,21] It, therefore, provided enough length to reach the A3 segment of the ACA without requiring an interposition graft. The blood flow will continue into the territory of the obliterated vessel through the preserved anterior communication artery and the revascularization [Figure 2f]. Current literature describes anterior circulation bypass as from STA to middle cerebral artery or internal carotid or the use of interposition grafts on doing STA to ACA bypass.^[22-24] While A3 to A3 ACA revascularization has been described, its ability to supply enough blood bilaterally was doubtful because of the

atherosclerotic changes noted at surgery in the carotid arteries.^[25]

This case is an illustrative case of successful direct use of the STA-ACA bypass for revascularization where there is a need for vessel occlusion on A1, thereby obviating the risk of brain ischemia.

Conclusion

A combination of STA-A3 segment revascularization with distal A1-segment clipping is a treatment option for the A1 aneurysms that reoccur post coiling for SAH from a giant A1 aneurysm. This is especially useful where the anterior communicating artery cannot provide enough flow. Further evaluation will be needed to assess for the sustainability of this treatment option over time.

Financial support and sponsorship

Nil.

Conflicts of interest

There are no conflicts of interest.

References

- Shi L, Yuan Y, Guo Y, Yu J. Intracranial post-embolization residual or recurrent aneurysms: Current management using surgical clipping. *Interv Neuroradiol* 2016;22:413-9.
- De Jesús O. Giant aneurysm of the proximal anterior cerebral artery. *Surg Neurol* 1996;46:553-6.
- Dashti R, Hernesniemi J, Lehto H, Niemelä M, Lehecka M, Rinne J, *et al.* Microneurosurgical management of proximal anterior cerebral artery aneurysms. *Surg Neurol* 2007;68:366-77.
- Niimi Y, Song J, Madrid M, Berenstein A. Endosaccular treatment of intracranial aneurysms using matrix coils: Early experience and midterm follow-up. *Stroke* 2006;37:1028-32.
- Jeon JP, Cho YD, Yoo DH, Moon J, Lee J, Cho WS, *et al.* Risk factor analysis of recanalization timing in coiled aneurysms:

- Early versus late recanalization. *AJNR Am J Neuroradiol* 2017;38:1765-70.
6. Lee J, Lim JW, Cho YD. Follow-up outcomes after re-embolization for recanalized aneurysms after initial coiling: Further recurrence rates and related risk factors. *World Neurosurg* 2018;114:e508-17.
 7. Tan IY, Agid RF, Willinsky RA. Recanalization rates after endovascular coil embolization in a cohort of matched ruptured and unruptured cerebral aneurysms. *Interv Neuroradiol* 2011;17:27-35.
 8. Zhang Q, Jing L, Liu J, Wang K, Zhang Y, Paliwal N, *et al.* Predisposing factors for recanalization of cerebral aneurysms after endovascular embolization: A multivariate study. *J Neurointerv Surg* 2018;10:252-7.
 9. Sadato A, Hayakawa M, Adachi K, Nakahara I, Hirose Y. Large residual volume, not low packing density, is the most influential risk factor for recanalization after coil embolization of cerebral aneurysms. *PLoS One* 2016;11:e0155062.
 10. Tirakotai W, Sure U, Yin Y, Benes L, Schulte DM, Bien S, *et al.* Surgery of intracranial aneurysms previously treated endovascularly. *Clin Neurol Neurosurg* 2007;109:744-52.
 11. Raymond J, Darsaut TE. An approach to recurrent aneurysms following endovascular coiling. *J Neurointerv Surg* 2011;3:314-8.
 12. Zhao J, Lin H, Summers R, Yang M, Cousins BG, Tsui J. Current treatment strategies for intracranial aneurysms: An overview. *Angiology* 2018;69:17-30.
 13. Izumo T, Matsuo T, Morofuji Y, Hiu T, Horie N, Hayashi K, *et al.* Microsurgical clipping for recurrent aneurysms after initial endovascular coil embolization. *World Neurosurg* 2015;83:211-8.
 14. Lejeune JP, Thines L, Taschner C, Bourgeois P, Henon H, Leclerc X. Neurosurgical treatment for aneurysm remnants or recurrences after coil occlusion. *Neurosurgery* 2008;63:684-91.
 15. Petr O, Brinjikji W, Thomé C, Lanzino G. Safety and efficacy of microsurgical treatment of previously coiled aneurysms: A systematic review and meta-analysis. *Acta Neurochir (Wien)* 2015;157:1623-32.
 16. Smith RD. Extracranial-intracranial bypass in cerebral ischemia. *Ochsner J* 2003;5:31-5.
 17. Nour M, Scalzo F, Liebeskind DS. Ischemia-reperfusion injury in stroke. *Interv Neurol* 2013;1:185-99.
 18. Hara T, Arai S, Goto Y, Takizawa T, Uchida T. Bypass surgeries in the treatment of cerebral aneurysms. *Acta Neurochir Suppl* 2016;123:57-64.
 19. Henkes H, Brew S, Miloslavski E, Fischer S, Tavrovski I, Kühne D. The underlying mechanisms of endovascular exclusion of intracranial aneurysms by coils. How important is electrothrombosis? *Interv Neuroradiol* 2003;9:127-40.
 20. Daou B, Chalouhi N, Starke RM, Barros G, Ya'qoub L, Do J, *et al.* Clipping of previously coiled cerebral aneurysms: Efficacy, safety, and predictors in a cohort of 111 patients. *J Neurosurg* 2016;125:1337-43.
 21. Soldozy S, Costello JS, Norat P, Sokolowski JD, Soldozy K, Park MS, *et al.* Extracranial-intracranial bypass approach to cerebral revascularization: A historical perspective. *Neurosurg Focus* 2019;46:E2.
 22. Standring S, Harold E, Caroline W. *Gray's Anatomy: The Anatomical Basis of Clinical Practice*. 39 (electronic). Edinburgh: Elsevier Churchill Livingstone; 2015. p. 559.
 23. Park ES, Ahn JS, Park JC, Kwon DH, Kwun BD, Kim CJ. STA-ACA bypass using the contralateral STA as an interposition graft for the treatment of complex ACA aneurysms: Report of two cases and a review of the literature. *Acta Neurochir (Wien)* 2012;154:1447-53.
 24. Lee SH, Chung Y, Ryu JW, Choi SK, Kwun BD. Surgical revascularization for the treatment of complex anterior cerebral artery aneurysms: Experience and illustrative review. *World Neurosurg* 2018;111:e507-18.
 25. Ozaki S, Miyazaki H, Fumoto N, Onoue S, Ichikawa H, Fukumoto S, *et al.* Ruptured giant fusiform anterior cerebral artery aneurysm treated by proximal clipping with a3-a3 bypass: Case report. *No Shinkei Geka* 2015;43:435-43.