

Received: 2014.01.04
Accepted: 2014.02.17
Published: 2014.05.24

Early clinical effects of the Dynesys system plus transfacet decompression through the Wiltse approach for the treatment of lumbar degenerative diseases

Authors' Contribution:

Study Design A
Data Collection B
Statistical Analysis C
Data Interpretation D
Manuscript Preparation E
Literature Search F
Funds Collection G

ABC 1 **Chao Liu***
A 2 **Lei Wang***
CD 2 **Ji-wei Tian**

1 Shanghai Jiao Tong University School of Medicine, Shanghai, China
2 Department of Orthopedics, First People's Hospital Affiliated to Shanghai Jiaotong University, Shanghai, China

* Chao Liu and Lei Wang contributed equally

Corresponding Author: Lei Wang, e-mail: wanglewlw@163.com

Source of support: Departmental sources

Background: This study investigated early clinical effects of Dynesys system plus transfacet decompression through the Wiltse approach in treating lumbar degenerative diseases.

Material/Methods: 37 patients with lumbar degenerative disease were treated with the Dynesys system plus transfacet decompression through the Wiltse approach.

Results: Results showed that all patients healed from surgery without severe complications. The average follow-up time was 20 months (9–36 months). Visual Analogue Scale and Oswestry Disability Index scores decreased significantly after surgery and at the final follow-up. There was a significant difference in the height of the intervertebral space and intervertebral range of motion (ROM) at the stabilized segment, but no significant changes were seen at the adjacent segments. X-ray scans showed no instability, internal fixation loosening, breakage, or distortion in the follow-up.

Conclusions: The Dynesys system plus transfacet decompression through the Wiltse approach is a therapeutic option for mild lumbar degenerative disease. This method can retain the structure of the lumbar posterior complex and the motion of the fixed segment, reduce the incidence of low back pain, and decompress the nerve root.

MeSH Keywords: **Lumbar Degenerative Disease • Wiltse Approach • Dynesys • Osteoarthritis, Spine • Decompression, Surgical**

Full-text PDF: <http://www.medscimonit.com/download/index/idArt/890292>

 2908

 3

 1

 20

Background

Spinal fusion has been used to treat lumbar degenerative diseases for many years, but as follow-up time extended, the complications such as back amyotrophia resulting from extensive dissection, normal spinal function loss, and degenerative adjacent segments were reported frequently [1]. In recent years, the Dynesys system has been used clinically. With the design targeted to achieve instant stability and retain activities of the fixed segments, the Dynesys system plus transfacet decompression through the Wiltse approach could retain posterior ligamentous complex and reduce the damage to bony structure to the largest extent [2]. From June 2009 to June 2012, we treated 37 patients with lumbar degenerative disease by using the Dynesys system plus transfacet decompression through the Wiltse approach and obtained satisfactory effects at the initial stage.

Material and Methods

General data

From June 2009 to June 2012, 37 patients with lumbar degenerative disease were enrolled in this study. There were 21 males and 16 females with average age of 40.5 years (age range: 27–52 years). The preoperative diagnosis included lumbar spinal stenosis (6 cases) with obvious backache and intermittent lameness accompanied by unilateral or bilateral leg pain; and lumber intervertebral disc herniation (31 cases) with backache and lateral leg pain. The disease course was 20.40 ± 12.36 months (range: 8–36 months). All patients had conservative treatment for 4–8 weeks without any effect and never had lumbar surgery. Thirty cases involved only 1 segment, while 7 cases involved 2 segments. There were 18 cases in L4/5, 12 cases in L5/S1, and 7 cases in both L4/5 and L5/S1. The patients with spondylolysis degree $>11^\circ$, scoliosis degree $>10^\circ$, severe OP, severe obesity, and BMI $>35 \text{ Kg/m}^2$ were excluded. All patients accepted routine preoperative examinations, including X-ray, CT, MRI, and postoperative X-ray rechecking of lumbar vertebrae. Visual Analogue Scale (VAS) and Oswestry Disability Index (ODI) evaluating standards were applied to evaluate the therapeutic effect before and after surgery.

Surgical procedures

Position and anesthesia

All patients were placed in the prone position under general anesthesia, and pillows were put under the shoulders and bilateral thoracic and abdominal walls.

The Wiltse approach

Based on preoperative MRI image, 2 incisions were made over the spinous process (vertical incisions 1–2 cm from the lateral spine process) and 1 incision was made to bilaterally isolate from lumbodorsal fascia to the space between the longissimus with multifidi. The positions of longissimus and multifidi were determined by incisions on the skin. Blunt dissection was performed slightly between longissimus and multifidi with fingers, directing to the superficial transfacet from superficial to underlying.

Some soft tissues of the upper and lower lateral facet joints, processus transversus, and vertebral plate were dissected so as to clearly expose the above structures without strongly pulling paravertebral muscle groups or other soft tissues.

Dynesys fixation

A pedicle screw was inserted at the point of the midline connecting facet joint superior articular process exterior margin with processus transversus, or it could be placed slightly outward under the guide of a C-arm X-ray machine. Then the distance between the upper and lower pedicle screws was measured when keeping anterior protruding position of lumbar vertebra and mild separation of spine. A tube-like over-sleeve was selected based on the measured length. Lastly, polyester rope was fit between polyester pipe and the upper and lower pedicle screws, and then tightened and locked with small screws.

Decompression

Through the Wiltse approach, after the segments were targeted and confirmed by intraoperative a C-arm X-ray machine, some soft tissues were removed from the surface of the upper and lower lateral facet joints, processus transversus and vertebral plate, thus exposing the above structures without strongly pulling paravertebral muscle groups or other soft tissues. The ligamentum flavum was exposed at the place of the intervertebral soft tissues between upper and lower articular processes, dissected with a small spatula along the lower edge of the superior and inferior vertebral plate, as well as the medial edge of the upper and lower articular processes, and excised to enter the spinal canal parrying posterior bony structure between the upper and lower vertebral plates. Then a sharp osteotome of less than 1 cm was used to remove some tissues along the medial edge of the hypozygal of vertebral body. Thereby, the hyperplastic and cohesive articular surface of the superior articular process of the inferior vertebral body towards coronal plane was exposed. Beneath the vertebral body was the extruded lateral crypt and nerve root canal mouth, which were removed. The removal range was determined based on

the following standard: the remaining spinal nerve roots and traversing spinal nerve roots through this region could be effectively exposed; the pressed nerve roots could be released and decompressed and the intervertebral disc space could be clearly exposed. In most cases, only the parts that moved from the sagittal plane to the coronal plane, showing hyperplasia and hypertrophy and expanded to the edge of the midline during degenerative process, should be excised precisely but not the entire facet joints. A drainage tube was used, and the incisions, especially in the bilateral lumbodorsal fascia, were sutured layer by layer.

Postoperative management

The drainage tube was placed for 24–48 h; antibiotics were administered for 1 day; and the stitches were removed 12–14 days after the operation. To reduce nerve root adhesion, the patients were guided to perform the straight leg-raising test after the drainage tube was removed. Two weeks later, the patients whose wound had healed properly could take lumbar exercise supported by 5 points to promote the recovery of lumbar muscle force. The time to get out of bed was determined based on the bony damage during the operation and the quality of the internal fixation. The time to get out of bed in this study was 3.5 days on average (range: 3–7 days) after the operation. The patients had low-intensity activities on the ground under the protection of a gait belt after getting out of bed and more activities were gradually performed. Three to 4 weeks after the operation, patients could move freely on the ground under the protection of gait belt and were photographed and provided with follow-up. Three months after the operation, the patients were photographed again for the purpose of recheck. With good results, they could return to normal activities without protection of a gait belt. Lumbar lateral X-ray was necessary after the operation and during the follow-up.

Evaluation method

Imaging evaluation: the patient received routine lumbar X-ray (anteroposterior and lateral view and flexion and extension view), CT, and MRI of lumbar before the operation. After the operation (after the drainage tube was removed) and during the follow-up, they received lumbar X-ray (anteroposterior and lateral view and flexion and extension view). CT and MRI could also be performed if necessary. Height of intervertebral space: a lateral X-ray of the lumbar spine was taken, and the height of intervertebral space at the operated segments and the adjacent segments (the upper and lower segment) was measured (in patients with L5/S1 as the operated segment, only the upper adjacent segment was measured). The average value of anterior height, central height, and posterior height was taken as the height of intervertebral space of this segment. Intervertebral range of motion (ROM): the ROM of the

operated segment and the adjacent segment was measured based on X-ray film (flexion and extension view). VAS and ODI evaluating standards were applied to evaluate the therapeutic effect. Preoperative, postoperative, and final follow-up clinical sign, symptom, and sphincter function were evaluated.

Statistical analysis

Statistical analysis was conducted with SPSS 19.0, and the statistical comparison of VAS and ODI scores before and after operation and at the final follow-up, as well as the height of intervertebral space and intervertebral ROM of the operated segment and the adjacent segment, was implemented by paired *t* test. The difference with $P < 0.05$ was considered significant.

Results

No complications occurred in patients in this study during the operation. The time of surgery was 130 ± 28 min, and the intraoperative bleeding volume was 275 ± 45 ml. The drainage tube was removed at 48 h after the operation, with the postoperative drainage volume of 151 ± 55 ml. The average follow-up time was 20 months (9–36 months). Compared with preoperative parameters, the scores of VAS and ODI decreased significantly after surgery and at the final follow-up ($P < 0.05$), while the difference of the scores after surgery and at the final follow-up was of no statistical significance ($P > 0.05$) (Table 1). Compared to preoperation, the height of intervertebral space at the operated segments (L4/L5 and L5/S1) ($P < 0.05$) after the operation was increased significantly, and the intervertebral ROM at the operated segment after surgery was obviously reduced ($P < 0.05$) (Table 2). However, no significant changes were seen in the height of intervertebral space and the intervertebral ROM at the upper and lower adjacent segments ($P > 0.05$) (Table 3). The postoperative X-ray showed no instability signs of lumbar, loosened pedicle screw, breakage, or distortion in any patients (Figure 1).

Discussion

Advantages of the Wiltse approach

Surgical interventions have been found to restore function, decrease pain, and enhance quality of life in properly selected patients with lumbar degenerative diseases [3]. Posterior lumbar interbody fixation and fusion after decompression is the standard method used to treat lumbar degenerative diseases. However, traditional surgery selects a post-middle approach that results in muscle injury and innervation loss due to dissection and traction, which involves a wide range of soft tissues. Worse, this process will last longer and cause backache

Table 1. VAS and ODI evaluating results.

Item	Pre-operation	Post-operation	Last follow-up
VAS evaluating standard	7.43±1.19	2.46±1.45*	2.24±1.48*
ODI evaluating standard	67.68±13.29	24.32±12.07*	20.43±10.12*

* Compared with the preoperation, *P*<0.05.

Table 2. Intervertebral space height and ROM at the stabilized segments.

Item	L4/L5 (n=18)		L5/S1 (n=12)	
	Pre-operation	Post-operation	Pre-operation	Post-operation
Intervertebral space height (mm)	9.31±1.12	11.19±1.27*	7.25±0.70	8.81±0.73*
ROM (°)	8.83±0.79	3.33±0.69*	6.83±0.72	2.67±0.78*

* Compared with the pre-operation, *P*<0.05.

Table 3. Intervertebral space height and ROM at the adjacent segments.

Item	L4/L5 (n=18, upper adjacent L3/L4)		L4/L5 (n=18, lower adjacent L5/S1)		L5/S1 (n=12, upper adjacent L4/L5)	
	Pre-operation	Post-operation	Pre-operation	Post-operation	Pre-operation	Post-operation
Intervertebral space height (mm)	10.00±1.27	9.96±1.14*	8.96±0.94	9.19±1.07*	9.39±0.84	9.83±0.78*
ROM (°)	6.44±0.70	6.78±0.73*	6.22±0.88	6.50±0.86*	6.75±0.75	7.08±0.79*

* Compared with the pre-operation, *P*>0.05.

and amyotrophy due to the specific features of blood supply, metabolism, and innervation of paravertebral muscle ⁴; post-operative lumbar disability and instability will also appear because the healed scar cannot effectively withstand spinal pressure [5]. For the purpose of reducing the harm to paravertebral muscle, Wiltse proposed the approach of inter-muscular space of the lumbar spine in 1968 [6]. In this approach, physicians can reach the operative processus transversus, articular facet, and other parts through the space between multifidi and longissimus without stripping the muscle entheses. This approach also has little impact on the blood supply and innervation of paravertebral muscle. In conclusion, the advantages include reducing operative bleeding, muscle injury, avascular necrosis caused by the operation, release of the postoperative inflammatory factor, and incidence of postoperative backache [7,8]. Moreover, this approach can direct to the articular surface and processus transverses, and can better meet the requirements of the Dynesys system for screw placement in the articular process and the lateral joint without strong traction of paravertebral muscle compared with the median incision involving muscular traction. Meanwhile, as for this approach, the double incision has been changed into a single incision besides the spinous process. Based on the obesity of the patients and the distance between muscular space inlet and median

line measured by T2-weighted MRI before the operation, 2 incisions are made in patients involving L5/S1 with relative obesity in general, while a single incision is usually made for L4/5 [9]. Above all, the advantages of the Wiltse approach include less bleeding, less damage to back muscle, and better exposure of articular process to place screws for the Dynesys system.

Features of transfacet decompression

Decompression fixation fusion is the “golden rule” for spinal surgery. The laminectomy is always a standard approach to treat lumbar degenerative disease, but it can damage the posterior structure of lumbar, affect spinal stability, cause backache due to the postoperative scar adhesions, and cause failed back surgery syndrome. According to the clinical follow-up implemented by Kawaguchi et al. [10], 10% of patients had spondylolysis. The study of Sen et al. [11] suggested that the incidence of failed back surgery syndrome caused by epidural scar adhesion was 8–24%. Based on further understanding of lumbar structure and lumbar degenerative disease, the vertebral plate has no pressure on the nerve root in the spinal canal, but the degenerative articular process with hyperplasia, looseness, and cohesion will compress the nerve root going through the nerve root canal. In view of this pathological change, from the

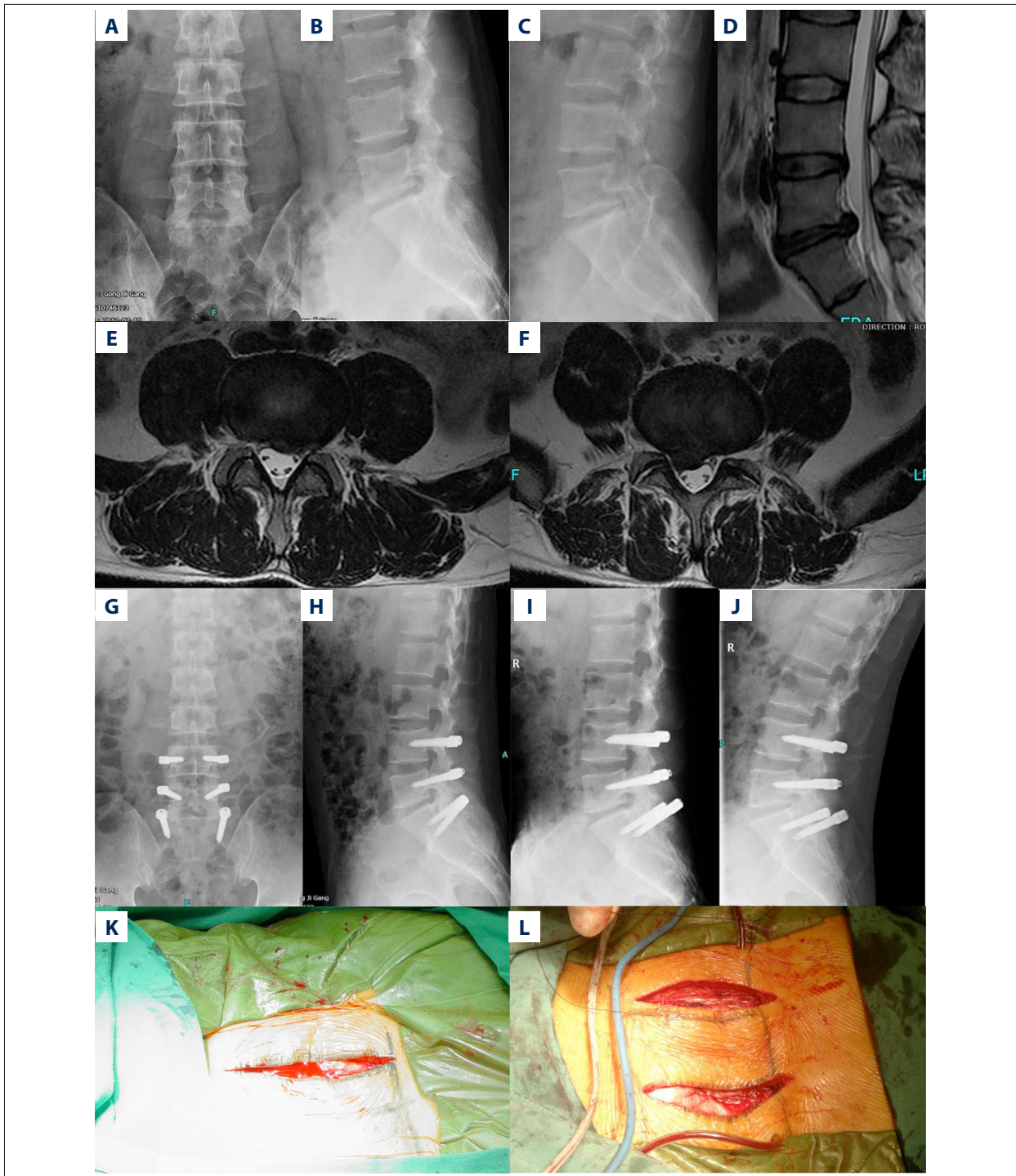


Figure 1. A 35-year-old male with low back and the right lower extremity pain for 12 months aggravating for a month. (A–C) The X-ray before surgery showed lumbar degeneration, L4/5 instability, L5/S1 disc space narrowing, lumbar flexion, and hyperextension limited. (D) MRI showed L4/5 disc bulge, L5/S1 disc herniation. (E) MRI showed L4/5 disc bulge to the left behind. (F) MRI showed L5/S1 disc herniation to the right rear and right nerve root compression. (G, H) The X-ray after surgery showed L5/S1 decompression, Dynesys fixation. There is no clinical symptom with L4/L5, L4/L5 mild instability, so dynamic fixation was given. (I, J) The X-ray 9 month after surgery showed L4/5, L5/S1 segments retain some activity, lumbar flexion and hyperextension limited. (K) Single incision (for underweight persons and L4/5). (L) Two incisions (for obesity and L5/S1).

simple extensive decompression to limited precise decompression, vertebral plate incision is unnecessary in most cases and it is better to remove part of or the entire facet joint for a limited but effective decompression [12]. Advantages of transfacet decompression are that the depression phase and range are technically determined based on a comprehensive analysis of the symptoms and signs of patients and relevant imaging materials. It realizes a full decompression in disc-flava ligament space, lateral intervertebral canal, and the mouth of foramen intervertebral through which the nerve roots move, and can also release the nerve root completely by excising the zygapophyseal joint, exposing foramen intervertebral and removing intraspinal compression to the nerve roots (osteophyte, thickening and calcified ligamentum flavum, and protruding intervertebral disc). In structural protection, it retains the spinous process, interspinous ligaments, muscular points, and lateral joint capsule, appropriately maintains the midline structure, enhances spinal stability, relieves postoperative backache, and improves recovery of the patients after transfacet decompression. By combining it with the Wiltse approach, it can also effectively protect the structure and reduce the incidence of postoperative backache by exposing the articular process directly without excessive stripping and traction of paravertebral muscle. A randomized controlled trial on the 5-year follow-up implemented by Hallett et al. [13] suggested transfacet decompression and fusion combined with posterior internal fixation had better effects in the backache scores, SF-36 Scale, and Roland Morris Dysfunction Questionnaire scores. In our opinion, this approach can not only direct to the zygapophyseal joint, but also complete removal of zygapophyseal joint after screw placement for Dynesys outside the articular process. Additionally, it can retain the bone at lateral border and the ventral joint capsule, thus keeping midline structure and joint capsule stability without exposing the superior nerve root in the operation field. The superior and medial parts of this lateral superior articular process were excised without removal of the entire superior articular process, and the excision region and range can be adjusted on the basis of the preoperative symptom, imaging materials, and compression condition during the operation.

Dynesys non-fusion fixation

With the development of the technology for internal fixation and fusion, the spinal fusion rate is higher than 95%. However, the improvement of fusion was not always accompanied by the increase of the clinical effects. Limited lumbar motion, biomechanics changes after fusion, unstable lumbar spine, and pseudarthrosis formations can cause accelerated degeneration of the adjacent segments [14]. According to Mulholland [15], it is optional to limit segment motion within a certain range so as to maintain an approximately normal loading capacity. The dynamic fixation was proposed to stabilize the spine, improve loading capacity, retain part of the motion of the fixed segments,

and prevent instability and degenerative adjacent segments. As a typical demonstration of this concept, the Dynesys system uses a titanium alloy pedicle screw for fixation, which is then connected with a transparent polyurethane tube and polyester rope. It may retain partial motion of the fixed segments and realize decompression of zygapophyseal joint and intervertebral disc [2]. First, on the biomechanics, Schulte et al. [16] proved that the decompression in addition to Dynesys system could better limit the flexion, extension, and lateral bending of a fixed segment. Gedet et al. [17] proposed that the Dynesys system could reduce the ROM of the fixed segment in extension, lateral curvature, and rotation position to 26%, 33%, and 76%, respectively, of the normal parameters. Second, on the relation of degenerative adjacent segments, the cadaver study of Schilling et al. [18] indicated that dynamic fixation could reduce intervertebral disc pressure of the fixed segments remarkably without affecting the adjacent segments. Likewise, Cabello et al. [19] performed a 6-cadaver study, reporting that the intervertebral disc pressure was reduced by 65% with fixation in L5/S1 and the pressure in L4/5 increased by 20%. But by inserting the Dynesys system in L4/5, the pressure was reduced to 50% and the pressure in L3/4 only increased by 10%. Therefore, the Dynesys system can better decrease the pressure of the adjacent segments than rigid fixation. In a randomized controlled trial with 3-year follow-up, Yu et al. [20] made a comparison between the Dynesys system and PLIF approach in clinical effects and imaging inspection. They found the Dynesys system could better retain the vertebral motion but less affected adjacent segments and had lower incidence of degeneration (1/27 and 6/26). According to recent follow-up results, the postoperative scores in VAS and ODI both declined compared with the pre-operation, and no aggravation of the degeneration of lumbar vertebra was observed from the imaging. The fixed segments had limited motion, but its long-term effect needs further observation.

With equivalent efficacy to traditional fixation fusion, the Dynesys system can also decompress the fixed and adjacent segments. The Dynesys system, in addition to transfacet decompression through the Wiltse approach, can effectively protect posterior structure, reduce operative injury with full decompression, and allow the patients to get out of bed sooner. Additionally, it decreases the incidence of low back pain and has satisfactory clinical effects. Thus, it is a therapeutic option for lumbar degenerative diseases by integration of the advantages of different techniques.

Conclusions

The Dynesys system plus transfacet decompression through the Wiltse approach is a therapeutic option for mild lumbar degenerative disease. This method can retain the structure of

the lumbar posterior complex and the motion of the fixed segment, reduce the incidence of low back pain, and decompress the nerve root. The early clinical effects are satisfactory, but its long-term effect needs further observation.

References:

1. Videbaek TS, Egund N, Christensen FB et al: Adjacent segment degeneration after lumbar spinal fusion: the impact of anterior column support: a randomized clinical trial with an eight- to thirteen-year magnetic resonance imaging follow-up. *Spine (Phila Pa 1976)*, 2010; 35: 1955–64
2. Kaner T, Sasani M, Oktenoglu T, Ozer AF: Dynamic stabilization of the spine: a new classification system. *Turk Neurosurg*, 2010; 20: 205–15
3. Garczyk D, Jankowski R, Mistowska E et al: Patient satisfaction with nursing after surgery due to cervical or lumbar discopathy. *Med Sci Monit*, 2013; 19: 892–902
4. Stevens KJ, Spenciner DB, Griffiths KL et al: Comparison of minimally invasive and conventional open posterolateral lumbar fusion using magnetic resonance imaging and retraction pressure studies. *J Spinal Disord Tech*, 2006; 19: 77–86
5. Schwender JD, Holly LT, Rouben DP, Foley KT: Minimally invasive transforaminal lumbar interbody fusion (TLIF): technical feasibility and initial results. *J Spinal Disord Tech*, 2005; 18(Suppl.): S1–6
6. Wiltse LL, Bateman JG, Hutchinson RH, Nelson WE: The paraspinous-splitting approach to the lumbar spine. *J Bone Joint Surg Am*, 1968; 50: 919–26
7. Vialle R, Wicart P, Drain O et al: The Wiltse paraspinous approach to the lumbar spine revisited: an anatomic study. *Clin Orthop Relat Res*, 2006; 445: 175–80
8. Youssef JA, McAfee PC, Patty CA et al: Minimally invasive surgery: lateral approach interbody fusion: results and review. *Spine (Phila Pa 1976)*, 2010; 35: S302–11
9. Olivier E, Beldame J, Ould Slimane M et al: Comparison between one midline cutaneous incision and two lateral incisions in the lumbar paraspinous approach by Wiltse: a cadaver study. *Surg Radiol Anat*, 2006; 28: 494–97
10. Kawaguchi Y, Kanamori M, Ishihara H et al: Clinical and radiographic results of expansive lumbar laminoplasty in patients with spinal stenosis. *J Bone Joint Surg Am*, 2005; 87(Suppl.1): 292–99
11. Sen O, Kizilkilic O, Aydin MV et al: The role of closed-suction drainage in preventing epidural fibrosis and its correlation with a new grading system of epidural fibrosis on the basis of MRI. *Eur Spine J*, 2005; 14: 409–14
12. Bransford R, Zhang F, Bellabarba C et al: Early experience treating thoracic disc herniations using a modified transfacet pedicle-sparing decompression and fusion. *J Neurosurg Spine*, 2010; 12: 221–31
13. Hallett A, Huntley JS, Gibson JN: Foraminal stenosis and single-level degenerative disc disease: a randomized controlled trial comparing decompression with decompression and instrumented fusion. *Spine (Phila Pa 1976)*, 2007; 32: 1375–80
14. Yorimitsu E, Chiba K, Toyama Y, Hirabayashi K: Long-term outcomes of standard discectomy for lumbar disc herniation: a follow-up study of more than 10 years. *Spine (Phila Pa 1976)*, 2001; 26: 652–57
15. Mulholland RC, Sengupta DK: Rationale, principles and experimental evaluation of the concept of soft stabilization. *Eur Spine J*, 2002;11(Suppl.2): S198–205
16. Schulte TL, Hurschler C, Haversath M et al: The effect of dynamic, semi-rigid implants on the range of motion of lumbar motion segments after decompression. *Eur Spine J*, 2008; 17: 1057–65
17. Gedet P, Haschtmann D, Thistlethwaite PA, Ferguson SJ: Comparative biomechanical investigation of a modular dynamic lumbar stabilization system and the Dynesys system. *Eur Spine J*, 2009; 18: 1504–11
18. Schilling C, Kruger S, Grupp TM et al: The effect of design parameters of dynamic pedicle screw systems on kinematics and load bearing: an *in vitro* study. *Eur Spine J*, 2011; 20: 297–307
19. Cabello J, Cavanilles-Walker JM, Iborra M et al: The protective role of dynamic stabilization on the adjacent disc to a rigid instrumented level. An *in vitro* biomechanical analysis. *Arch Orthop Trauma Surg*, 2013; 133: 443–48
20. Yu SW, Yang SC, Ma CH et al: Comparison of Dynesys posterior stabilization and posterior lumbar interbody fusion for spinal stenosis L4L5. *Acta Orthop Belg*, 2012; 78: 230–39

Conflicts of interests

There were no conflicts of interests to declare.