


Colonic Adenocarcinoma Presenting as Splenic Abscess Secondary to Suspected Microperforation

Journal of Investigative Medicine High Impact Case Reports
Volume 8: 1–4
© 2020 American Federation for Medical Research
DOI: 10.1177/2324709620978317
journals.sagepub.com/home/hic


Emily Fitzsimmons, BS¹, Tyler J. Torrico, MD²,
Tushar Bajaj, MD² , and Alan Scott Ragland, DO²

Abstract

Splenic abscesses are a rare infection that usually requires seeding from another primary source; however, direct contact of bacteria can occur with microperforation secondary to colon cancer leading to abscess formation. This occurrence is rare, and through literature review only 12 previous cases have been reported with associated bacteremia. Our patient is a 62-year-old female who presented with left upper quadrant pain with a history of tobacco and alcohol abuse that was febrile and hypoxic. Blood cultures were obtained that eventually grew *Fusobacterium mortiferum*. Computed tomography of the abdomen and the pelvis revealed 2 splenic abscesses that were cultured to grow *Escherichia coli* and β -hemolytic *Streptococcus* group C. Colonoscopy was performed, which identified 2 masses that were biopsied, and histopathology confirmed well-differentiated adenocarcinoma with possible muscular invasion. The patient had no other identifiable risk factors for bacterial seeding from another primary source. We present the first reported case report of splenic abscess secondary to colonic adenocarcinoma suspected microperforation associated with *Fusobacterium mortiferum* bacteremia.

Keywords

splenic abscess, colon cancer, adenocarcinoma, bacteremia

Case Presentation

A 62-year-old female presented with sharp left upper quadrant pain that worsened with inspiration. The patient has a history of tobacco abuse (35-pack-year equivalent) and alcohol abuse; however, she denied any illicit drug use. She was febrile with temperature 103 °F and hypoxic saturating 90% on room air. Physical examination demonstrated left upper quadrant pain to both light and deep palpation. Laboratory results were significant for normocytic anemia and absence of leukocytosis. Blood cultures were collected on admission with gram stain growing gram-negative rods resembling enterics and an anaerobic culture eventually growing *Fusobacterium mortiferum*.

An initial chest X-ray revealed a left lower lobe consolidation with a pleural effusion. Computed tomography (CT) of the abdomen with contrast revealed 2 perisplenic fluid collections, one at the lower lateral periphery measuring 4.1 × 2.1 cm in size, and the second at the inferior pole measuring 3.8 × 2.2 cm (Figure 1). The patient was then started on intravenous fluids, acetaminophen/oxycodone for pain management, and intravenous piperacillin/tazobactam 4.5 g every 6 hours.

Repeat CT abdomen with contrast scan on hospital day 3 demonstrated enlargement of the 2 splenic subcapsular fluid

collections, the lesion at the superior pole of the spleen now measured 10.8 cm × 7.4 cm × 9.7 cm and the second lesion at the inferior pole adjacent with the splenic flexure now measured 2.3 cm × 3.9 × 3.6 cm (Figure 2). A CT-guided aspiration and drainage of the superior perisplenic collection (100 mL removed) and of the inferior perisplenic collection (15 mL removed) was obtained. The superior aspirate culture did not grow any bacteria or fungus; however, the inferior aspirate culture grew *Escherichia coli* and β -hemolytic *Streptococcus* group C.

A transesophageal echocardiogram and oral X-rays showed no vegetations or lesions. Colonoscopy revealed 2 masses in the transverse and descending colon as well as a rectal polyp. The smaller mass in the transverse colon measured 2.4 cm, and the larger tumor in the descending colon

¹Ross University, Miramar, FL, USA

²UCLA—Kern Medical, Bakersfield, CA, USA

Received August 15, 2020. Revised October 22, 2020. Accepted October 31, 2020.

Corresponding Author:

Tushar Bajaj, MD, UCLA—Kern Medical, Department of Medicine, 1700 Mount Vernon Avenue, Bakersfield, CA 93306, USA.
Email: tusharbjajMD@gmail.com



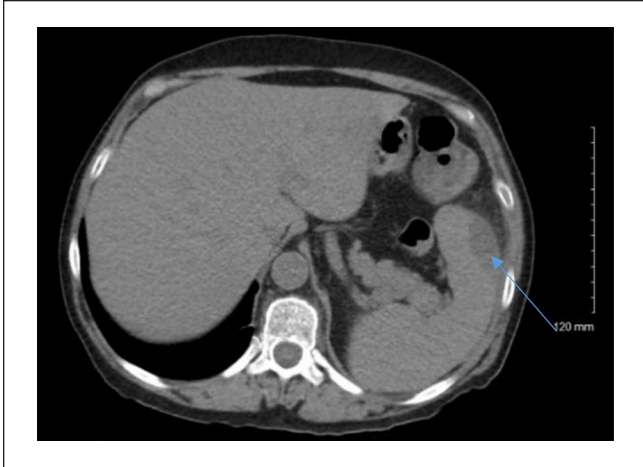


Figure 1. Computed tomography of abdomen with contrast demonstrating splenic abscess (blue arrow).

measured 8.4 cm. Both lesions were biopsied and the smaller lesion showed well-differentiated adenocarcinoma with suspicion for muscular invasion. The larger descending colonic mass showed moderately differentiated invasive adenocarcinoma. Assessment from oncology determined the staging to be Stage IIB (pT4aN0M0).

The patient underwent colorectal surgery for left hemicolectomy with ileocolonic anastomosis. During surgery, the colon was found to be adherent to the superior pole of the spleen. The surgical pathology report revealed adenocarcinoma in the transverse colon tumor that invaded through the muscularis interna, and adenocarcinoma in the larger tumor with 15% mucinous carcinoma component that invaded through the muscularis propria and perforated the peritoneum and into the pericolic fat. The patient discharged in stable condition and was instructed to follow with oncology for adjuvant chemotherapy as an outpatient.

Discussion

This case describes the rare occurrence of a splenic abscess forming by direct spread rather than distant seeding. Splenic abscesses are a rare medical occurrence usually caused by hematogenous spread from a distant infection.¹⁻³ Splenic abscess should be suspected in a patient with left upper quadrant pain, splenomegaly, left costovertebral tenderness, left pleural effusion on X-ray, and leukocytosis with a left shift. Associated risk factors for developing a splenic abscess include infective endocarditis, diabetes mellitus, trauma, intravenous drug abuse, or hemoglobinopathies,^{1,4-8} of which our patient had none. Rarely, colon cancer can perforate the bowels and communicate into the spleen allowing for direct spread of bacteria and eventual abscess formation. Through literature review, 12 cases of this phenomenon have been reported^{4,9-19} (Table 1), all of which had an associated bacteremia. The most common bacteria

cultured in splenic abscess are *Escherichia coli*, *Proteus mirabilis*, *Streptococcus* group D, *Klebsiella pneumoniae*, and *Bacteroides fragilis*.

In the absence of endocarditis, patients presenting with a splenic abscess usually have a concomitant immunodeficiency disorder, trauma, splenic infarct, diabetes, or malignancy.^{1,4-8} With the absence of typical risk factors, combined with the clinical and surgical findings, we highly suspect that our patient developed a splenic abscess by direct contact via microperforation secondary to the adenocarcinoma of the distal transverse colon rather than by seeding of a distant source.

Bacteremia is another common finding that is associated with a splenic abscess.¹⁻³ Bacteremia associated with splenic abscesses are most often gram positive due to the seeding from infective endocarditis.¹⁻³ However, this patient's gram-negative bacteremia grew *F. mortiferum*, which is typically associated with infections of the oral cavity, female genital tract, gastrointestinal tract, and often plays a role in septic shock and abscess formation.²⁰⁻²² The 2 most common species of *Fusobacterium* widely discussed in the literature are *F. necrophorum* and *F. nucleatum*. *F. mortiferum* is less commonly an isolated specimen in clinical cases related to gastrointestinal neoplasms.²⁰⁻²² There is a well-established connection between *Fusobacterium* and colorectal cancers, with the most reported species in the literature being *F. nucleatum*.²⁰⁻²² It is possible that *F. mortiferum* was not able to be cultured from the splenic abscess in our patient as she had received 3 days of intravenous antibiotics prior to having the CT-guided biopsy. We were unable to find any documented cases of *F. mortiferum* bacteremia in the setting of colorectal cancer.

Although there are no specific diagnostic criteria for splenic abscess, CT-guided imaging appears to be a sufficient technique to confirm splenic abscess if there is strong clinical suspicion.⁴ The treatment recommendation for splenic abscess varies in the literature.⁴⁻⁹ Though splenectomy was once considered the gold standard of treatment for a splenic abscess, drainage and broad-spectrum antibiotics are now the preferred route over a splenectomy, but this must be weighed against the risks of bleeding.^{5,8} The number of splenectomies performed due to a splenic abscess is not well documented in the literature. Definitive management for a splenic abscess is typically a combination of antibiotic therapy and splenectomy.¹⁻³ However, as in this case, antibiotic therapy and drainage may have a favorable outcome without the need for a splenectomy.

Conclusion

In our case report, we describe an unusual suspected etiology of a splenic abscess formation by direct spread, an unusual presentation of colon cancer, and a previously undocumented splenic abscess with associated *F. mortiferum* bacteremia. Patients presenting with the clinical symptoms and associated risk factors for splenic abscess should undergo the appropriate diagnostic workup, including identifying the source of bacterial exposure to the spleen.

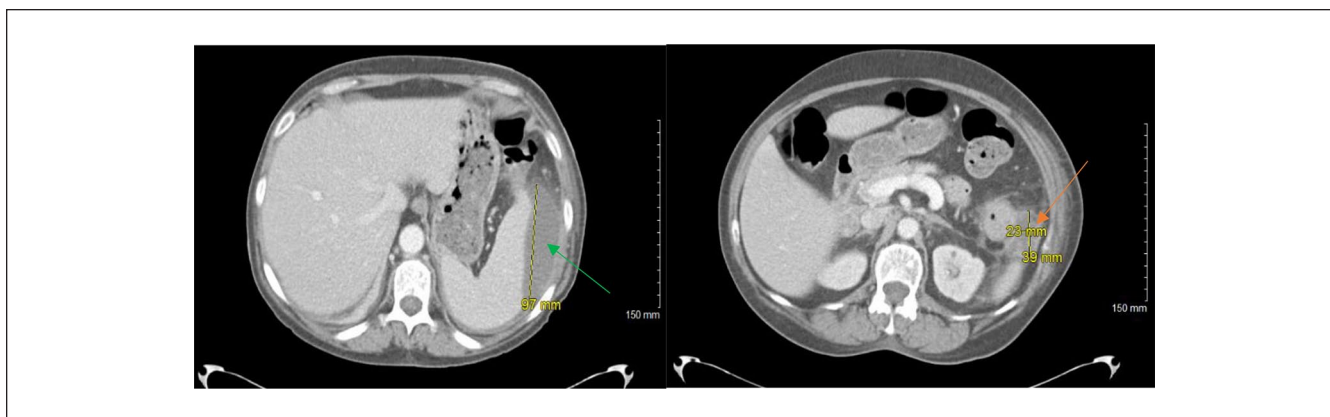


Figure 2. Repeat computed tomography of abdomen with contrast demonstrating 2 perisplenic abscesses, one in the superior spleen (green arrow) and one in the inferior spleen (orange arrow).

Table 1. Literature Review.

Reference #	Author	Year	Journal
9	Cartanese et al	2012	<i>Annali Italiani di chirurgia</i>
10	Kawamoto et al	1993	<i>Jpn J Clin Oncol</i>
11	Michowits et al	1982	<i>J Surg Oncol</i>
12	Leibovitz et al	2002	<i>Harefuah</i>
13	Nakao et al	1999	<i>Anticancer Res</i>
14	Belinkie et al	1983	<i>Dis Colon Rectum</i>
15	Parmelle et al	2001	<i>J Radiol</i>
16	Pisanu et al	2007	<i>World J Gastroenterol</i>
17	Gervaise et al	2010	<i>J Radiol</i>
18	Awotar et al	2016	<i>Medicine</i>
19	Rishitha et al	2017	<i>Gastroenterology</i>
4	Johnson et al	1985	<i>Rev Infect Dis</i>

Authors' Note

An oral presentation of this case report was presented at the 2020 Western Medical Research Conference in Carmel, California, on January 24, 2020.

Declaration of Conflicting Interests

The author(s) declared no potential conflicts of interest with respect to the research, authorship, and/or publication of this article.

Funding

The author(s) received no financial support for the research, authorship, and/or publication of this article.

Ethics Approval

Ethical approval to report this case was obtained from our institutional review board (IRB #19029).

Informed Consent

Written informed consent was obtained from the patient for their anonymized information to be published in this article.

ORCID iD

Tushar Bajaj  <https://orcid.org/0000-0002-8863-9399>

References

- Robinson SL, Saxe JM, Lucas CE, Arbulu A, Ledgerwood AM, Lucas WF. Splenic abscess associated with endocarditis. *Surgery*. 1992;112:781-786.
- Brook I, Frazier EH. Microbiology of the liver and spleen abscesses. *J Med Microbiol*. 1998;47:1075-1080.
- Lee CH, Leu HS, Hu TH, Liu JW. Splenic abscess in southern Taiwan. *J Microbiol Immunol Infect*. 2004;37:39-44.
- Johnson JD, Raff MJ, Drasin GF, Daffner RH. Radiology in the diagnosis of splenic abscess. *Rev Infect Dis*. 1985;7:10-20.
- Waheed A, Mathew G, Zemaitis MR. *Splenic Abscess*. StatPearls; 2019.
- Divyashree S, Gupta N. Splenic abscess in immunocompetent patients managed primarily without splenectomy: a series of 7 cases. *Perm J*. 2017;21:16-139. doi:10.7812/TPP/16-139
- Ting W, Silverman NA, Arzouman DA, Levitsky S. Splenic septic emboli in endocarditis. *Circulation*. 1990;82(5 suppl): IV105-IV109.
- Westh H, Reines E, Skibsted L. Splenic abscess: a review of 20 cases. *Scand J Infect Dis*. 1990;22:569-573.
- Cartanese C, Carbotta G, Di Candia, et al. A rare case of colon cancer with splenic abscess [in Italian]. *Ann Ital Chir*. 2013; 84:201-204.
- Kawamoto K, Teramoto T, Watanabe M, et al. Splenic abscess associated with colon cancer: a case report. *Jpn J Clin Oncol*. 1993;23:384-388.
- Michowits M, Avnieli D, Lazarovici I, Solowiejczyk M. Perforation complicating carcinoma of the colon. *J Surg Oncol*. 1982;19:18-21.
- Leibovitz I, Polychuck I, Reitblat TD, Gheorghiu D, Zamir D. Splenic abscess as an unusual manifestation of colonic carcinoma [in Hebrew]. *Harefuah*. 2002;141:231-238, 315, 316.
- Nakao A, Iwagaki H, Isozaki H, et al. Portal venous gas associated with splenic abscess secondary to colon cancer. *Anticancer Res*. 1999;19:5641-5644.
- Belinkie SA, Narayanan NC, Russell JC, et al. Splenic abscess associated with *Streptococcus bovis* septicemia and

- neoplastic lesions of the colon. *Dis Colon Rectum*. 1983;26: 823-824.
15. Paramelle PJ, Ferretti G, Desroches E, Coulomb M. Quid? Cancer of the left colonic angle with colonic-splenic fistula, thrombosis of the splenic vein and left portal branch [in French]. *J Radiol*. 2001;82:511-513.
 16. Pisanu A, Ravarino A, Nieddu R, Uccheddu A. Synchronous isolated splenic metastasis from colon carcinoma and concomitant splenic abscess: a case report and review of the literature. *World J Gastroenterol*. 2007;13:5516-5520.
 17. Gervaise A, De Saint Roman C, Sockeel P, et al. Splenic abscess secondary to a colosplenic fistula as the presenting manifestation of colon cancer [in French]. *J Radiol*. 2010;91(12 pt 1):1259-1262.
 18. Awotar GK, Luo F, Zhao Z, et al. Splenic abscess owing to cancer at the splenic flexure a case report and comprehensive review. *Medicine (Baltimore)*. 2016;95:e4941.
 19. Yelisetti R, Khurshid M, Awad A, Kaji A. Splenic abscess: an unusual complication of colon cancer. *Gastroenterology Res*. 2017;10:247-250.
 20. Prout J, Glymph R. Anaerobic septicemia secondary to *Fusobacterium mortiferum*. *J Natl Med Assoc*. 1986;78: 334,337.
 21. Shang FM, Liu HL. *Fusobacterium nucleatum* and colorectal cancer: a review. *World J Gastrointest Oncol*. 2018;10:71-81. doi:10.4251/wjgo.v10.i3.71
 22. Zhou Z, Chen J, Yao H, Hu H. *Fusobacterium* and colorectal cancer. *Front Oncol*. 2018;8:371. doi:10.3389/fonc.2018.00371