

CASE REPORT

18F-FDG PET/CT contribution to tuberculous vertebral osteomyelitis diagnosis: a case report

Katerina Manika^{1,*}, Maria Kipourou², Stamata Georga³, Eleni Faniadou¹, Georgios Pilianidis⁴, Georgios Arsos³ and Ioannis Kioumis¹

¹Respiratory Infections Unit, Pulmonary Department, Aristotle University of Thessaloniki, “G. Papanikolaou” Hospital, Thessaloniki, Greece, ²Pulmonary Department, 424 General Military Hospital, Thessaloniki, Greece, ³Nuclear Medicine Department, Aristotle University of Thessaloniki, “Papageorgiou” Hospital, Thessaloniki, Greece, ⁴Department of Internal Medicine, “G. Papanikolaou” Hospital, Thessaloniki, Greece

*Correspondence address. Respiratory Infections Unit, Pulmonary Department, Aristotle University of Thessaloniki, “G. Papanikolaou” Hospital, Thessaloniki, Greece. Tel: +302313307858; E-mail: ktmn05@yahoo.gr

Abstract

Tuberculous vertebral osteomyelitis (TVO) is an extrapulmonary tuberculosis form characterized by difficulty and delay in diagnosis. PET/CT is a valuable, well-established tool in the diagnostic workup of cancer and fever of unknown origin, which is increasingly appreciated in the management of infectious diseases. We report a TVO case where PET/CT had a valuable contribution towards diagnosis and monitoring of treatment response, highlighting its advantages and future perspectives when dealing with infectious diseases.

INTRODUCTION

Fever of unknown origin (FUO) is a common clinical challenge demanding recruitment of additive diagnostic tools.

CASE REPORT

A 64-year-old male patient with unremarkable previous history was hospitalized for the investigation of persistent low-grade fever and malaise during the past month. Systemic inflammatory markers were elevated, but repeated blood and urine cultures were negative. The patient received different combinations of broad-spectrum antibiotics (including an antistaphylococcal regimen), without signs of clinical or laboratory improvement. No abnormal findings were detected on transesophageal echocardiography or chest and abdomen computed tomography (CT) imaging, and HIV testing was negative.

The patient was an immigrant originated from a country with TB incidence 18/100 000 and had a family history of tuberculosis (TB). He had been assessed 2 years ago, due to close household contact with an active pulmonary TB case. At that time chest X-ray was normal, and tuberculin skin test (TST) was negative.

At admission, a new TST test and an interferon- γ assay (IGRA) were both positive. Sixty minutes after intravenous injection of 268 MBq (7.2 mCi) of ¹⁸F-fluorodeoxyglucose (¹⁸F-FDG), a whole-body PET/CT scan (¹⁸F-FDG PET/CT) was performed as part of the investigation for FUO which revealed diffusely elevated metabolic activity (Standardized Uptake Value, SUVmax 7.0) in T11 vertebra (Fig. 1a and c, arrows). Since no other hypermetabolic foci were detected on the whole-body imaging (Fig. 1a), the test was considered compatible with isolated vertebral osteomyelitis (VO). Interestingly enough the patient had never reported focal myoskeletal pain in the affected area and neurologic examination was normal.

Received: November 5, 2019; Accepted: June 21, 2020

© The Author(s) 2020. Published by Oxford University Press. All rights reserved. For Permissions, please email: journals.permissions@oup.com

This is an Open Access article distributed under the terms of the Creative Commons Attribution Non-Commercial License (<http://creativecommons.org/licenses/by-nc/4.0/>), which permits non-commercial re-use, distribution, and reproduction in any medium, provided the original work is properly cited. For commercial re-use, please contact journals.permissions@oup.com

As the patient denied confirmatory diagnosis by means of vertebral biopsy, empirical first-line anti-TB treatment (isoniazid, rifampicin, ethambutol and pyrazinamide) was initiated soon after the PET/CT imaging, leading to rapid decline of the fever and improvement of inflammatory markers. A follow-up ^{18}F -FDG PET/CT with 280 MBq (7.6 mCi) of ^{18}F -FDG which was performed after 6 months of anti-TB treatment was normal (Fig. 1d and f), thus indirectly confirming the diagnosis of TB osteomyelitis. The patient received a total of 9 months of anti-TB treatment.

DISCUSSION

^{18}F -FDG PET/CT relies on increased glycolytic metabolism, reflected as elevated glucose uptake (quantified by SUVmax) by the inflammatory cells (especially the neutrophils and the monocyte/macrophage family) [1]. The role of ^{18}F -FDG PET/CT is well established in cancer management and rapidly emerging in inflammation and infection (including FUO) investigation.

As far as TB is concerned, some clinically significant aspects have been shown. Firstly, ^{18}F -FDG PET/CT can reveal more extensive disease in comparison to CT alone in cases of active TB, with its incremental diagnosing value based on both revealing hilar involvement but also unexpected sites of extrapulmonary TB [2]. Furthermore, SUVmax has been shown to be a sensitive and accurate marker for noninvasive evaluation of treatment response, thereby indirectly prompting early diagnosis of resistant *Mycobacterium tuberculosis* strains [2, 3]. Finally, a recent study evaluating asymptomatic patients with high SUVmax lesions provided new insights in the TB latency period [4]. It is worthy to remember, however, that no discriminative SUVmax value exists able to differentiate active TB from other malignant or infectious lesions [5, 6].

In our case ^{18}F -FDG PET/CT performed as part of the diagnostic workup for FUO, according to EANM/SNMMI guidelines [1], was suggestive of the diagnosis of isolated vertebral osteomyelitis. Although MRI is the imaging of choice in cases of suspected spine infection (proposed by both IDSA and EANM/SNMMI guidelines [1, 7]), PET/CT was recently found to have higher specificity for active spondylodiscitis diagnosis [8]. Advantages and disadvantages of both MRI and PET/CT, when investigating cases of VO or spondylodiscitis, are presented in Table 1.

Tuberculous vertebral osteomyelitis (TVO), also known as Pott's disease, is not an uncommon extrapulmonary location of TB and is frequently associated with difficulty and delay in diagnosis [9, 10]. Late diagnosis is the main factor to determine poor prognosis for TVO [9]. Lack of specific clinical features is a main characteristic of TVO; in our case, back pain, a predominant symptom of VO and TVO, was absent, whereas fever, usually present in just half the patients diagnosed with TVO, was the only symptom. In this problematic context, ^{18}F -FDG PET/CT was very useful both in guiding the diagnosis and assessing the response to treatment.

The ^{18}F -FDG PET/CT presumptive diagnosis of TVO was in agreement with the microbiological, epidemiological and clinical findings suggestive of recent tuberculosis infection, namely, conversion of the TST over the past 2 years, low-grade fever, a recent positive IGRA assay and the history of recent close contact with a case of active pulmonary tuberculosis. A TST or IGRA assay is indicated as part of the diagnostic workup in cases of suspected VO, especially in patients originating from high TB incidence countries, on the basis that a negative result of either would make the diagnosis of TVO unlikely but not impossible [7]. Microbiologic confirmation is highly recommended for the

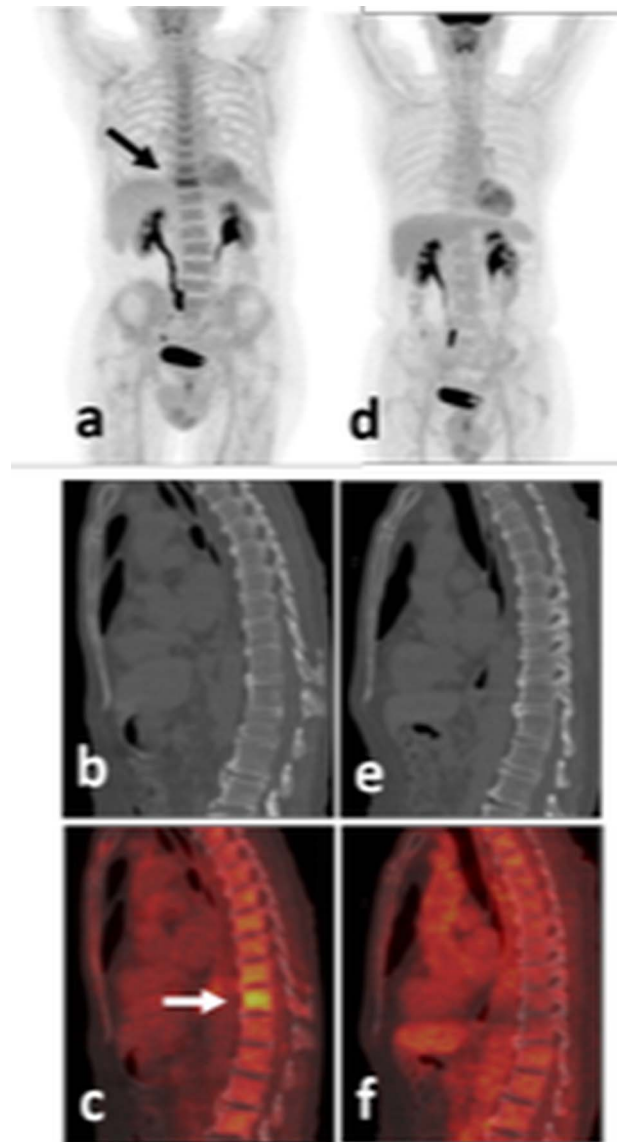


Figure 1: ^{18}F -FDG PET/CT, baseline (a, b, c) and after 6 months of anti-TB treatment (d, e, f). (a, d) Maximum intensity projection images; (b, e) sagittal CT spine reconstruction; (c, f) fused PET/CT sagittal spine sections. Intense ^{18}F -FDG accumulation is observed in the intact body of the T11 vertebra (a, b, c, arrows), completely normalized post-treatment (d, f). Of notice the, probably reactive to the infection, moderate metabolic enhancement of the entire skeletal bone marrow at baseline (a), returning to normal post-treatment (d).

diagnosis of VO, either by means of conventional blood cultures or fungal, mycobacterial and brucellar cultures following an image-guided aspiration biopsy [7]. Diagnostic yield of vertebral biopsy ranges between 42% and 76% for TVO, and the use of molecular methods is strongly encouraged in addition to conventional methods, for the detection of *M. tuberculosis* in the specimen [9]. Our patient did not consent to an interventional approach, and since he had already received broad-spectrum antibiotics-including antistaphylococcal regimen—without clinical improvement, the diagnosis of TVO was considered very possible. A negative follow-up ^{18}F -FDG PET/CT after 6 months (Fig. 1d and f) provided indirect evidence of appropriate diagnosis and treatment in the case presented.

Table 1: Advantages and disadvantages of MRI vs PET/CT when investigating cases of vertebral osteomyelitis or spondylodiscitis

	MRI	¹⁸ F-FDG PET/CT
Cost	Lower	Higher
Exposure to radiation	No	Yes
Anatomical details	More	Less
Availability	Yes	Yes
Symptom directed	Yes	No
Whole-body	No (usually)	Yes (always)
Diagnostic performance in spondylodiscitis	(Possibly) lower	(Possibly) higher
Renal function concern	Yes	No
Contrast agent concern	Yes	No
Patient discomfort (claustrophobia)	Yes	No
Metallic implants concern	Yes	No
Implantable cardiac devices concern	Yes	No

In conclusion, some distinct advantages of the ¹⁸F-FDG PET/CT were highlighted through the successful management of this case of TVO. Increased experience could further define the exact role of ¹⁸F-FDG PET/CT in the management of extrapulmonary TB.

FUNDING

No funding.

Conflict of interest statement. None to declare.

GUARANTORS

Prof. Katerina Manika and Prof. Ioannis Kioumis

REFERENCES

- Jamar F, Buscombe J, Chiti A, Christian PE, Delbeke D, Donohoe KJ et al. EANM/SNMMI guideline for 18F-FDG use in inflammation and infection. *J Nucl Med* 2013;**54**:647–58.
- Martinez V, Castilla-Lievre MA, Guillet-Caruba C, Grenier G, Fior R, Desarnaud S et al. 18F-FDG PET/CT in tuberculosis: an early non-invasive marker of therapeutic response. *Int J Tuberc Lung Dis* 2012;**16**:1180–5.
- Sánchez-Montalvá A, Barrios M, Salvador F, Villar A, Tórtola T, Molina-Morant D et al. Usefulness of FDG PET/CT in the management of tuberculosis. *PLoS One* 2019;**14**: e0221516.
- Geadas C, Acuna-Villaorduna C, Mercier G, Kleinman MB, Horsburgh CR Jr, Ellner JJ et al. FDG-PET/CT activity leads to the diagnosis of unsuspected TB: a retrospective study. *BMC Res Notes* 2018;**11**:464.
- Sathekge MM, Maes A, Pottel H, Stoltz A, van de Wiele C. Dual time-point FDG PET/CT for differentiating benign from malignant solitary pulmonary nodules in a TB endemic area. *S Afr Med J* 2010;**100**:598–601.
- Ankrah AO, van der Werf TS, de Vries EFJ, Dierckx RAJO, Sathekge MM, Glaudemans AWJM. PET/CT imaging of Mycobacterium tuberculosis infection. *Clin Transl Imag* 2016;**4**:131–44.
- Berbari EF, Kanj SS, Kowalski TJ, Darouiche RO, Widmer AF, Schmitt SK et al. Infectious Diseases Society of America (IDSA) clinical practice guidelines for the diagnosis and treatment of native vertebral osteomyelitis in Adults. *Clin Infect Dis* 2015, 2015;**61**:e26–46.
- Kim S-J, Pak K, Kim K, Lee JS. Comparing the diagnostic accuracies of F-18 FDG PET and MRI for the detection of spondylodiscitis: a meta-analysis. *Spine* 2018.
- Colmenero JD, Ruiz-Mesa JD, Sanjuan-Jimenez R, Sobrino B, Morata P. Establishing the diagnosis of tuberculous vertebral osteomyelitis. *Eur Spine J* 2013;**22**:579–86.
- Kourbeti IS, Tsiodras S, Boumpas DT. Spinal infections: evolving concepts. *Curr Opin Rheumatol* 2008;**20**:471–9.