



CASE REPORT

REVISED Case Report: A Case of Encephalopathy Presenting the Lentiform Fork Sign on MRI in a Diabetic Dialysis Patient

[version 3; peer review: 2 approved]

Yuri Ishizaki ¹, Ryuzoh Nishizono ¹, Masao Kikuchi¹, Hiroko Inagaki²,
Yuji Sato ^{1,2}, Shouichi Fujimoto ¹⁻³

¹Department of Nephrology, University of Miyazaki Hospital, Faculty of Medicine, University of Miyazaki, 5200 Kihara, Kiyotake, Miyazaki, 889-1692, Japan

²Dialysis Division, University of Miyazaki Hospital, Faculty of Medicine, University of Miyazaki, Miyazaki, Japan

³Department of Hemovascular Medicine and Artificial Organs, Faculty of Medicine, University of Miyazaki, Miyazaki, Japan

V3 First published: 11 Aug 2020, 9:969
<https://doi.org/10.12688/f1000research.25597.1>

Second version: 20 Oct 2021, 9:969
<https://doi.org/10.12688/f1000research.25597.2>

Latest published: 02 Dec 2021, 9:969
<https://doi.org/10.12688/f1000research.25597.3>

Abstract

Basal ganglia lesions showing an expansile high signal intensity on T2-weighted MRI are termed the lentiform fork sign. This specific finding is mainly observed in diabetic patients with uremic encephalopathy with metabolic acidosis, although there are also reports in patients with ketoacidosis, dialysis disequilibrium syndrome, intoxication, and following drug treatment (e.g., metformin). A 57-year-old Japanese man on chronic hemodialysis for 4 years because of diabetic nephropathy was admitted to our hospital for relatively rapid-onset gait disturbance, severe dysarthria, and consciousness disturbance. Brain T2-weighted MRI showed the lentiform fork sign. Hemodialysis was performed the day before admission, and laboratory tests showed mild metabolic (lactic) acidosis, but no uremia. Surprisingly, metformin, which is contraindicated for patients with end-stage kidney disease, had been prescribed for 6 months in his medication record, and his sluggish speaking and dysarthria appeared gradually after metformin treatment was started. Thus, the encephalopathy was considered to be related to metformin treatment. He received hemodialysis treatment for 6 consecutive days, and his consciousness disturbance and dysarthria improved in 1 week. At the 8-month follow-up, the size of the hyperintensity area on MRI had decreased, while the mild gait disturbance remained. Considering the rapid onset of gait and consciousness disturbance immediately before admission, diabetic uremic syndrome may also have occurred with metformin-related encephalopathy, and resulted in the lentiform fork sign, despite the patient showing no evidence of severe uremia on laboratory data.

Open Peer Review

Reviewer Status

Invited Reviewers

1 2

version 3

(revision)
02 Dec 2021

version 2

(revision)
20 Oct 2021



report



report



report

version 1

11 Aug 2020

1. **Shashwati Sarkar Sen** , Mohak

Superspeciality Hospital, Prayagraj, India

2. **Ping-Hsun Wu**, Kaohsiung Medical University

Hospital, Kaohsiung Medical University,
Kaohsiung, Taiwan

Any reports and responses or comments on the article can be found at the end of the article.

Keywords

lentiform fork sign, basal ganglia lesion, diabetic uremic syndrome, metformin, consciousness disturbance

Corresponding author: Yuri Ishizaki (yuri_ishizaki@med.miyazaki-u.ac.jp)

Author roles: **Ishizaki Y:** Writing – Original Draft Preparation; **Nishizono R:** Writing – Review & Editing; **Kikuchi M:** Writing – Review & Editing; **Inagaki H:** Writing – Review & Editing; **Sato Y:** Writing – Review & Editing; **Fujimoto S:** Supervision

Competing interests: No competing interests were disclosed.

Grant information: The author(s) declared that no grants were involved in supporting this work.

Copyright: © 2021 Ishizaki Y *et al.* This is an open access article distributed under the terms of the [Creative Commons Attribution License](#), which permits unrestricted use, distribution, and reproduction in any medium, provided the original work is properly cited.

How to cite this article: Ishizaki Y, Nishizono R, Kikuchi M *et al.* **Case Report: A Case of Encephalopathy Presenting the Lentiform Fork Sign on MRI in a Diabetic Dialysis Patient [version 3; peer review: 2 approved]** F1000Research 2021, 9:969 <https://doi.org/10.12688/f1000research.25597.3>

First published: 11 Aug 2020, 9:969 <https://doi.org/10.12688/f1000research.25597.1>

REVISED Amendments from Version 2

We responded to each reviewer's comments as follows.

1) In the part of Case report, we added the extra information about hemodialysis conditions: quantity of blood flow of 200 mL/min, quantity of dialysate flow of 500 mL/min, 1.5 m² -dialysis membrane made of polymer alloy (polyarylate/polyethersulfone). Furthermore, we mentioned the time interval of hemodialysis treatment after recovery.

2) In the amendments from version 1 of the PDF file of this article, we described that the level of metabolic(lactic) acidosis on admission was also much mild not so high. As written here, we modified "severe lactic acidosis was not observed" to "the level of metabolic acidosis on admission was not very high (bicarbonate, 18.1 mEq/L; lactic acid, 6.2 mmol/L)" in the part of Discussion.

Any further responses from the reviewers can be found at the end of the article

Introduction

Metabolic encephalopathy with abnormal basal ganglia lesions has been reported in hemodialysis patients. Ingestion of some types of mushroom, star fruit, and drugs (e.g., anti-herpes virus drugs) can cause encephalopathy in these patients¹⁻³. In particular, diabetic dialyzed patients can present with bilateral symmetrical low densities in the basal ganglia on brain computed tomography (CT), with a bilateral symmetrical hyperintensity in the same area and a lentiform fork sign on T2-weighted MRI⁴⁻¹⁰. In addition to diabetic uremic syndrome (DUS)^{4,5}, the lentiform fork sign can be observed in severe metabolic acidosis¹¹⁻¹³, dialysis disequilibrium syndrome¹⁴, and

metformin-associated encephalopathy (ME)^{6,7}. The pathogenic basis of this sign is considered to relate to cytotoxic edema based on the severity of metabolic acidosis^{8,11}. Intensive dialysis is a therapeutic option for removing the uremic toxins, to correct metabolic acidosis and remove medications. Herein, we present a case of a 57-year-old Japanese man in whom the lentiform fork sign was a clue for the differential diagnosis of ME or DUS. Metformin tends to increase lactate production and result in metabolic acidosis in ME^{6,7,9,10}, while chronic hyperglycemia with coexistence of uremic toxins and metabolic acidosis is the main mechanism in DUS^{4,5}. Which of these is the main cause in our case presenting with the lentiform fork sign is discussed below.

Case report

A 57-year-old Japanese man who had been on maintenance hemodialysis three-times weekly for four years because of diabetic nephropathy developed gait and consciousness disturbance (the Glasgow Coma Scale score of E3V4M6), fatigue, numbness in his left upper limb, and a slow response during conversation approximately 10 days before admission. His wife denied him taking mushrooms or star fruit, which can cause consciousness disturbance in hemodialysis patients. There were no abnormal neurologic findings on physical examination. However, bilateral symmetrical basal ganglia lesions were noted on brain CT (Figure 1a).

On admission to our hospital, his consciousness was disturbed, such as he only could open his eyes following calling, and he had difficulty sitting alone. He showed a tonic planter reflex on

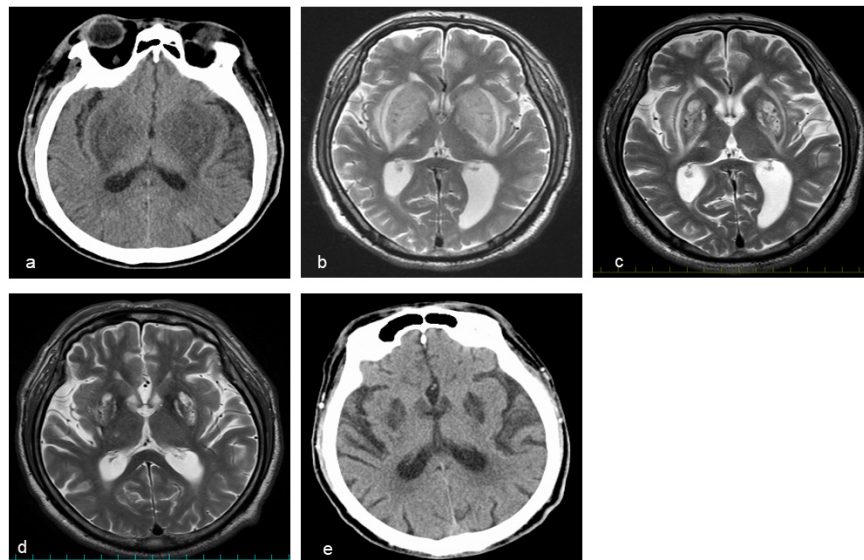


Figure 1. a, e Head computed tomography (CT) and b-d head MRI (T2-weighted image). a, b High-resolution lesions in the bilateral symmetrical basal ganglia were evident at admission. c, d The bilateral symmetrical basal ganglia lesions gradually improved on the 18th hospital day and at three-month follow-up. e However, the basal ganglia lesions remained at eight-month follow-up.

physical examination. His blood pressure was 190/91 mmHg, and his heart rate was 104 beats per min. Arterial blood gas analysis showed a pH of 7.37, bicarbonate ion of 18.1 mEq/L, and lactic acid of 6.2 mmol/L (normal, 0.5-1.6 mmol/L). Serum vitamin B1 (thiamin) level was 45 ng/mL (normal, 24-66 ng/mL). Serum calcium and blood aluminum levels were all within the acceptable range. Kidney function data sampled the day after dialysis, blood urea nitrogen, and serum creatinine were consistent with dialysis. His HbA1c was 5.8% on admission.

Brain MRI showed bilateral symmetrical basal ganglia lesions with an expansile high signal intensity (lentiform fork sign) on T2-weighted sequences (Figure 1b), which was not seen on MRI taken one-year prior when he developed a right thalamic lacunar infarction.

In his medication history, he had taken metformin for six months. His wife said that his sluggish speaking and dysarthria appeared gradually after starting metformin treatment (Figure 2). His plasma metformin concentration was extremely high (25,700 ng/mL). Thus, we considered that metformin may have initially caused the encephalopathy. However, we

also considered the possibility of DUS, because his gait and consciousness disturbance appeared relatively rapidly approximately 10 days before hospitalization. DUS typically occurs in uncontrolled uremic patients with diabetic mellitus.

In either case, we stopped metformin treatment, and immediately performed intensive hemodialysis (four hours daily; blood flow, 200 mL/min; dialysate flow, 500 mL/min; 1.5 m²-dialysis membrane, polymer alloy (polyarylate/polyethersulfone) for six days after hospitalization to remove metformin and uremic toxin, and to correct metabolic acidosis. The first dialysis session reduced his lactic acid levels from 6.2 to 1.3 mmol/L. After six consecutive sessions of hemodialysis, his consciousness was restored, and his tonic plantar reflex disappeared. Subsequently, we performed hemodialysis treatment for four hours per day, three times a week on the same hemodialysis conditions as above. After starting meals, linagliptin was chosen as an anti-diabetic drug to replace metformin.

On the 18th hospital day, T2-weighted brain MRI revealed a modest improvement in the lentiform fork sign (Figure 1c). The patient was gradually able to sitting alone, walk, and talk with staff and his wife. He was discharged from our hospital within one month.

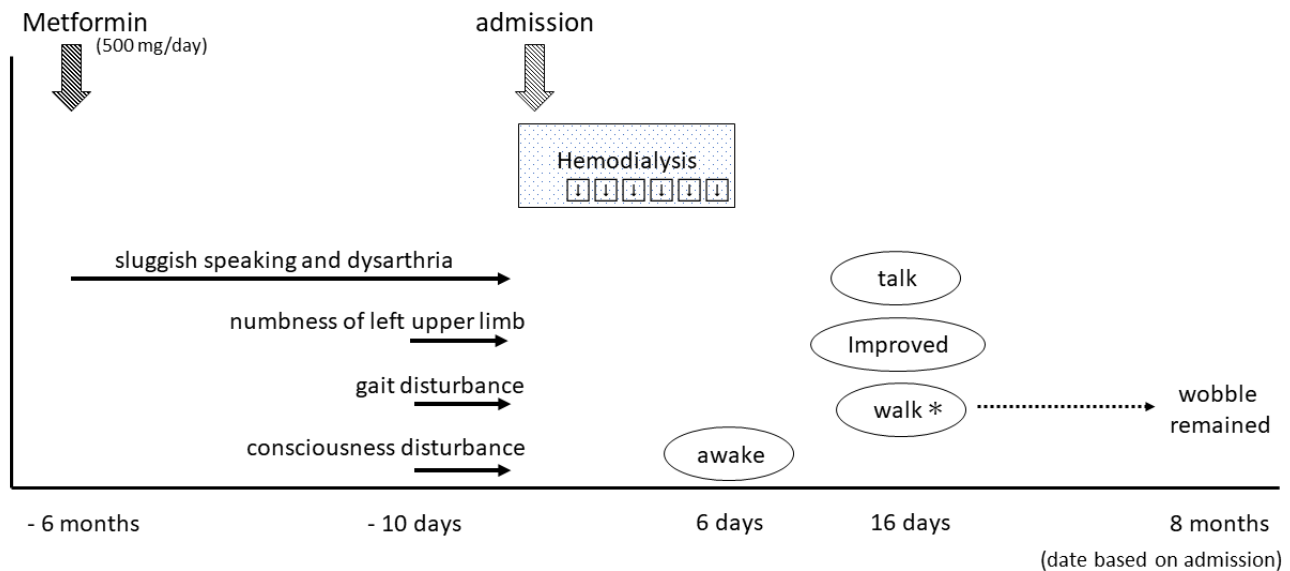


Figure 2. The patient started metformin treatment at six months prior to admission. Since that time, he developed gradual symptoms of sluggish speaking and dysarthria, while numbness of his left upper limb, gait disturbance, and consciousness disturbance appeared 10 days before admission. He received emergency consecutive hemodialysis for six days, after which he awoke, and was gradually able to walk and talk. *Walking was possible, but wobbling during walking remained at eight-month follow-up.

At three-month follow-up, the lentiform fork sign was further improved on brain MRI (Figure 1d). However, at eight months after the onset, he still complained movement disorders, such as a wobble when walking and body tilting when resting. Brain lesions were still evident on CT scan (Figure 1e).

Discussion

Herein, we report a diabetic hemodialysis patient with consciousness disturbance who presented with the lentiform fork sign on T2-weighted brain MRI. This finding appears in the basal ganglia, which is vulnerable to addictive toxins and metabolic products^{8,12}. The lentiform fork sign is comprised of the following elements: 1) the lateral arm, formed by the edematous external capsule and extending from the anterior end of the putamen to the stem; 2) the stem, created by merging of the edematous external and internal capsules at the inferoposterior end of the putamen; and 3) the medial arm, which extends from the stem anteriorly up to one third of the medial edge, where it splits into two slightly less T2/FLAIR-hyperintense branches engulfing the globus pallidus^{11,12,15}. In the present case, brain MRI showed the same expansile high signal intensity (Figure 1b). The lentiform fork sign is rare but non-specific. Thus, a differential diagnosis should be considered (Table 1)^{8,11-15}, of which ME or DUS may be the cause in the present case.

The use of metformin in dialyzed patients can cause drug accumulation in the brain, leading to neurological abnormalities, difficulties of speech and walking, with worsening of sensory disturbance, tiredness, drowsiness, and weakness (i.e., ME)^{6,7,9,10}. Metformin is first-line drug used in type 2 diabetes mellitus. However, it is contraindicated in patients with an estimated glomerular filtration rate <30 mL/min/1.73 m², because of an increased risk of lactic acidosis. Acidosis can damage the basal ganglia, resulting in cytotoxic edema⁷, which is sometimes irreversible despite intensive hemodialysis to remove metformin and lactic acid, and to correct acidosis. According to the

previous reports, hemodialysis patients are at risk for thiamin deficiency which is induced to encephalopathy, because they are in the condition of malnutrition and tend to lose water-soluble vitamins in the hemodialysis procedure^{16,17}. Furthermore, thiamin deficiency may be a possible mechanism in metformin-induced encephalopathy¹⁸. In our case, thiamin level was not decreased and the level of metabolic acidosis on admission was not very high (bicarbonate ion, 18.1 mEq/L; lactic acid, 6.2 mmol/L). In addition to these, the occurrence of gait disturbance, severe dysarthria, and consciousness disturbance was subacute even though sluggish speaking and dysarthria had been gradually worsening six months before starting taking metformin as shown in Figure 2, and the patient was neither malnutrition nor weight loss. That is why it was not necessarily ME.

Alternatively, DUS is characterized by acute or subacute progression with a variety of movement disorders such as gait disorders, dysarthria, parkinsonism, and consciousness disturbance. DUS can cause bilateral symmetrical basal ganglia lesions on brain CT and T2-weighted MRI^{4,5} in patients with diabetic nephropathy, even if they are not on hemodialysis. To date, approximately 30 cases of DUS have been reported, many of which are Asian. The reported risk factors of DUS include a high level of HbA1c before and at hemodialysis, and increasing metabolic acidosis. Hyperglycemia damages the microvasculature, resulting in a fragile vascular smooth muscle, and the accumulation of uremic toxins and/or metabolic acidosis can damage the blood-brain-barrier, leading to altered metabolism and homeostasis in the brain. This can result in basal ganglia injury, including angiogenic edema, which is reversible and shows favorable prognosis.

The clinical presentation in our case was not helpful for differentiating ME and DUS, because these symptoms were indistinguishable (Table 2). Initial hemodialysis improved lactic acidosis, although intensive hemodialysis for six consecutive days was required to improve his consciousness. The lentiform fork sign on MRI improved at first, although brain CT findings at eight-month follow-up showed low density signals in those regions, and his neurological sequelae remained, suggestive of continued cytotoxic edema. ME was likely the main cause of injury in our case. Nevertheless, the patient's condition worsened relatively rapidly before admission, similar to that seen in DUS. DUS can also contribute to cytotoxic edema in the basal ganglia, and has a variable progression. Thus, DUS may have also contributed to the encephalopathy in our case.

Table 1. Differential diagnosis of pathological conditions presenting with the lentiform fork sign^{8,11-15}.

a) Uremic encephalopathy *
b) Severe metabolic acidosis
c) Ketoacidosis
d) Dialysis disequilibrium syndrome
e) Intoxication (methanol, ethylene glycol, etc)
f) Drug-induced (metformin)

*The lentiform fork sign mainly occurs in patients with diabetic kidney disease.

Table 2. Comparison with metformin-encephalopathy (ME) and diabetic uremic syndrome (DUS)^{4-7,11-14}.

	ME	DUS	Present case
Clinical findings	sensorium, tiredness, dysarthria, gait disorder, consciousness disturbance	dysarthria, gait disorder, parkinsonism, consciousness disturbance	tiredness, dysarthria, gait disorder, consciousness disturbance
Onset	gradually and subacute	acute and subacute	gradually (dysarthria) and subacute (gait and consciousness disturbance)
Acidosis	Lactic acidosis	Metabolic acidosis	Lactic & metabolic acidosis
Uremia	-	+	-
Hyperglycemia	-	+	-
CT	low density area	low density area	low density area
MRI (T2-weighted)	high intense lesion	high intense lesion	high intense lesion
Characteristic of edema	cytotoxic	vasogenic	cytotoxic
Therapy	stop metformin intensive hemodialysis	intensive hemodialysis	intensive hemodialysis
Prognosis	remained	good	remained

ME, metformin-associated encephalopathy; DUS, diabetic uremic syndrome.

In summary, we report a diabetic hemodialysis patient with encephalopathy presenting as the lentiform fork sign derived from ME and/or DUS. In dialysis patients showing gait and consciousness disturbance, the lentiform fork sign on brain CT and T2-weighted MRI may be useful for differential diagnosis.

Data availability

All data underlying the results are available as part of the article and no additional source data are required.

Consent

Written informed consent for publication of their clinical details and clinical images was obtained from the patient.

Acknowledgements

We thank Edanz Group (<https://en-author-services.edanzgroup.com/>) for editing a draft of this manuscript.

References

- Akiyama H, Matsuoka H, Okuyama T, et al.: **The acute encephalopathy induced by intake of sughiratake mushroom in the patients with renal damage might be associated with the intoxication of cyanide and thiocyanate.** *Food Safety.* 2015; **3**(1): 16–29. [PubMed Abstract](#) | [Publisher Full Text](#)
- Auxiliadora-Martins M, Alkmin Teixeira GC, da Silva GS, et al.: **Severe encephalopathy after ingestion of star fruit juice in a patient with chronic renal failure admitted to the intensive care unit.** *Heart Lung.* 2010; **39**(5): 448–452. [PubMed Abstract](#) | [Publisher Full Text](#)
- Delluc A, Mocquard Y, Latour P, et al.: **Encephalopathy and acute renal failure during acyclovir treatment.** *Rev Neurol (Paris).* 2004; **160**(6–7): 704–706. [PubMed Abstract](#) | [Publisher Full Text](#)
- Wang HC, Cheng SJ: **The syndrome of acute bilateral basal ganglia lesions in diabetic uremic patients.** *J Neurol.* 2003; **250**(8): 948–955. [PubMed Abstract](#) | [Publisher Full Text](#)
- Finelli PF, Singh JU: **A syndrome of bilateral symmetrical basal ganglia lesions in diabetic dialysis patients.** *Am J Kidney Dis.* 2014; **63**(2): 286–288. [PubMed Abstract](#) | [Publisher Full Text](#)
- Kang YJ, Bae EJ, Seo JW, et al.: **Two additional cases of metformin-associated encephalopathy in patients with end-stage renal disease undergoing hemodialysis.** *Hemodial Int.* 2013; **17**(1): 111–115. [PubMed Abstract](#) | [Publisher Full Text](#)
- Simon SP, Thomas J: **Metformin-associated encephalopathy in hemodialysis.** *Indian J Nephrol.* 2019; **29**(3): 194–196. [PubMed Abstract](#) | [Publisher Full Text](#) | [Free Full Text](#)
- Kim DM, Lee IH, Song CJ: **Uremic encephalopathy: MR imaging findings and clinical correlation.** *ANJR Am J Neuroradiol.* 2016; **37**(9): 1604–1609. [PubMed Abstract](#) | [Publisher Full Text](#)
- Abdel SC, Carland JE, Graham GG, et al.: **Is the use of metformin in patients undergoing dialysis hazardous for life? A systematic review of the safety of metformin in patients undergoing dialysis.** *Br J Clin Pharmacol.* 2019; **85**(12):

2772–2783.

[PubMed Abstract](#) | [Publisher Full Text](#) | [Free Full Text](#)

10. Vecchio S, Giampreti A, Petrolini VM, *et al.*: **Metformin accumulation: lactic acidosis and high plasmatic metformin levels in a retrospective case series of 66 patients on chronic therapy.** *Clin Toxicol (Phila)*. 2014; **52**(2): 129–35.
[PubMed Abstract](#) | [Publisher Full Text](#)
11. Kumar G, Goyal MK: **Lentiform Fork sign: a unique MRI picture. Is metabolic acidosis responsible?** *Clin Neurol Neurosurg*. 2010; **112**(9): 805–812.
[PubMed Abstract](#) | [Publisher Full Text](#)
12. Grasso D, Borreggine C, Perfetto F, *et al.*: **Lentiform fork sign: a magnetic resonance finding in a case of acute metabolic acidosis.** *Neuroradiol J*. 2014; **27**(3): 288–292.
[PubMed Abstract](#) | [Publisher Full Text](#) | [Free Full Text](#)
13. Saini AG, Sreevilasan SK, Singh P, *et al.*: **Lentiform fork sign due to severe metabolic acidosis.** *BMJ Case Rep*. 2017; **2017**: bcr2017222871.
[PubMed Abstract](#) | [Publisher Full Text](#) | [Free Full Text](#)
14. da Rocha AJ, Maia AC Jr, da Silva CJ, *et al.*: **Lentiform fork sign in a child with dialysis disequilibrium syndrome: a transient MRI pattern which emphasizes neurologic consequence of metabolic acidosis.** *Clin Neurol Neurosurg*. 2013; **115**(6): 790–792.
[PubMed Abstract](#) | [Publisher Full Text](#)
15. Beltz EE, Mullins ME: **Radiological reasoning: hyperintensity of the basal ganglia and cortex on FLAIR and diffusion-weighted imaging.** *AJR Am J Roentgenol*. 2010; **195**(3 Suppl): S1–8 (Quiz S9-11).
[PubMed Abstract](#) | [Publisher Full Text](#)
16. Szu-Chun H, Sze-Hung H, Der-Cherng T, *et al.*: **Chorea Induced by thiamin deficiency in hemodialysis patients.** *Am J Kidney Dis*. 2001; **37**(2): 427–430.
[PubMed Abstract](#) | [Publisher Full Text](#)
17. Szu-Chun H, Sze-Hung H, Der-Cherng T, *et al.*: **Thiamin deficiency and unexpected encephalopathy in hemodialysis and peritoneal dialysis patients.** *Am J Kidney Dis*. 2001; **38**(5): 941–947.
[PubMed Abstract](#) | [Publisher Full Text](#)
18. McGarvey C, Franconi C, Prentice D, *et al.*: **Metformin-induced encephalopathy: the role of thiamine.** *Intern Med J*. 2018; **48**(2): 194–197.
[PubMed Abstract](#) | [Publisher Full Text](#)

Open Peer Review

Current Peer Review Status:  

Version 2

Reviewer Report 18 November 2021

<https://doi.org/10.5256/f1000research.78515.r97746>

© 2021 Wu P. This is an open access peer review report distributed under the terms of the [Creative Commons Attribution License](#), which permits unrestricted use, distribution, and reproduction in any medium, provided the original work is properly cited.



Ping-Hsun Wu

Division of Nephrology, Department of Internal Medicine, Kaohsiung Medical University Hospital, Kaohsiung Medical University, Kaohsiung, Taiwan

Yuri Ishizaki *et al.* reported a case of lentiform fork sign on MRI in a dialysis patient. The case presentation is good and well written. I have some questions about this case report.

1. The consciousness disturbance improved after intensive hemodialysis. The hemodialysis dosage and time interval could be mentioned in this paper.
2. Metformin was prescribed for diabetic hemodialysis patients. In this condition, metformin-associated lactic acidosis may present. In the revised main text, the author mentioned that the level of metabolic (lactic) acidosis on admission was not very high. Please provide the acidosis status (HCO₃ level and lactate level) in the main text.

Is the background of the case's history and progression described in sufficient detail?

Yes

Are enough details provided of any physical examination and diagnostic tests, treatment given and outcomes?

Yes

Is sufficient discussion included of the importance of the findings and their relevance to future understanding of disease processes, diagnosis or treatment?

Partly

Is the case presented with sufficient detail to be useful for other practitioners?

Yes

Competing Interests: No competing interests were disclosed.

Reviewer Expertise: Clinical nephrology, hemodialysis, chronic kidney disease

I confirm that I have read this submission and believe that I have an appropriate level of expertise to confirm that it is of an acceptable scientific standard.

Author Response 27 Nov 2021

Yuri Ishizaki, University of Miyazaki, 5200 Kihara, Kiyotake, Miyazaki, Japan

Dear Dr. Ping-Hsun Wu,

Thank you for providing your valuable comments. Our responses are as follows.

1) The consciousness disturbance improved after intensive hemodialysis. The hemodialysis dosage and time interval could be mentioned in this paper.

In the part of the Case report, we mentioned that the patient received intensive hemodialysis (four hours per day) for six days after hospitalization. We added the extra information about hemodialysis condition: quantity of blood flow of 200 mL/min, quantity of dialysate flow of 500 mL/min, 1.5 m² -dialysis membrane made of polymer alloy (polyarylate/polyethersulfone). After his consciousness recovered, we performed hemodialysis treatment regularly (four hours, three times a week).

2) Metformin was prescribed for diabetic hemodialysis patients. In this condition, metformin-associated lactic acidosis may present. In the revised main text, the author mentioned that the level of metabolic (lactic) acidosis on admission was not very high. Please provide the acidosis status (HCO₃ level and lactate level) in the main text.

As you mentioned, metformin-associated lactic acidosis may present. In our amendments from version 1 of the PDF file of this article, we considered and described that the level of metabolic(lactic) acidosis on admission was also much mild not so high. As written here, we modified "severe lactic acidosis was not observed" to "the level of metabolic acidosis on admission was not very high (bicarbonate ion, 18.1 mEq/L; lactic acid, 6.2 mmol/L)".

Sincerely yours,
Yuri Ishizaki

Competing Interests: None.

Reviewer Report 08 November 2021

<https://doi.org/10.5256/f1000research.78515.r97466>

© 2021 Sen S. This is an open access peer review report distributed under the terms of the [Creative Commons Attribution License](#), which permits unrestricted use, distribution, and reproduction in any medium, provided the original work is properly cited.



Shashwati Sarkar Sen 

Department of Reproductive Medicine and Surgery, Mohak Superspeciality Hospital, Prayagraj, Uttar Pradesh, India

The queries and suggestions have been answered satisfactorily.

Is the background of the case's history and progression described in sufficient detail?

Yes

Are enough details provided of any physical examination and diagnostic tests, treatment given and outcomes?

Yes

Is sufficient discussion included of the importance of the findings and their relevance to future understanding of disease processes, diagnosis or treatment?

Yes

Is the case presented with sufficient detail to be useful for other practitioners?

Yes

Competing Interests: No competing interests were disclosed.

Reviewer Expertise: Endocrine disorders, Assisted reproductive technology, Infertility, Gynaecology, Obstetrics

I confirm that I have read this submission and believe that I have an appropriate level of expertise to confirm that it is of an acceptable scientific standard.

Author Response 11 Nov 2021

Yuri Ishizaki, University of Miyazaki, 5200 Kihara, Kiyotake, Miyazaki, Japan

Dear Shashwati Sarkar Sen,

Thank you for your valuable comments and suggestions.

Sincerely,
Yuri Ishizaki

Competing Interests: None.

Version 1

Reviewer Report 27 September 2021

<https://doi.org/10.5256/f1000research.28250.r95340>

© 2021 Sen S. This is an open access peer review report distributed under the terms of the [Creative Commons Attribution License](#), which permits unrestricted use, distribution, and reproduction in any medium, provided the original work is properly cited.



Shashwati Sarkar Sen 

Department of Reproductive Medicine and Surgery, Mohak Superspeciality Hospital, Prayagraj, Uttar Pradesh, India

Summary: It is prudent to avoid Metformin in Diabetic patients with chronic renal insufficiency. Metformin toxicity can cause lactic acidosis induced encephalopathy eventually leading to multi-organ failure and death. Lentiform fork sign is a specific MRI finding in basal ganglia of these patients probably due to vasogenic edema induced by metabolic acidosis. Suspicion about Metformin intake will help in an early diagnosis and treatment.

A few suggestions to the authors:

1. Restrict the number of words in the title. Too many medical terms are used.
2. Case Report: Correction - Arterial Blood Gas analysis.
3. Mention the Glasgow Coma Score.
4. DUS may have a subacute presentation. Yoshiko Nishimura *et al.*² have reported a case of Diabetic Uremic Syndrome where the clinical features developed over 3 months. In your case, ME seems to be the primary diagnosis and DUS may be considered as a differential diagnosis rather than a contributory factor.

Add these References:

1. Metformin-induced encephalopathy: the role of thiamine¹. McGarvey *et al.* (2018) suggested that Metformin may cause thiamine deficiency in patients with end-stage diabetic renal failure, resulting in a specific type of encephalopathy. A quick resolution of the signs and symptoms was observed on stopping the drug in these patients.
2. A case of subacute Parkinsonism presenting as bilateral basal ganglia lesions by MRI in Diabetic uremic Syndrome.²

References

1. McGarvey C, Franconi C, Prentice D, Bynevelt M: Metformin-induced encephalopathy: the role of thiamine. *Intern Med J.* **48** (2): 194-197 [PubMed Abstract](#) | [Publisher Full Text](#)
2. Nishimura Y, Shibata K, Funaki T, Ito H, et al.: [A case of subacute parkinsonism presenting as bilateral basal ganglia lesions by MRI in diabetic uremic syndrome]. *Rinsho Shinkeigaku.* 2013; **53** (3): 217-23 [PubMed Abstract](#) | [Publisher Full Text](#)

Is the background of the case's history and progression described in sufficient detail?

Yes

Are enough details provided of any physical examination and diagnostic tests, treatment

given and outcomes?

Yes

Is sufficient discussion included of the importance of the findings and their relevance to future understanding of disease processes, diagnosis or treatment?

Yes

Is the case presented with sufficient detail to be useful for other practitioners?

Yes

Competing Interests: No competing interests were disclosed.

Reviewer Expertise: Endocrine disorders, Assisted reproductive technology, Infertility, Gynaecology, Obstetrics

I confirm that I have read this submission and believe that I have an appropriate level of expertise to confirm that it is of an acceptable scientific standard.

Author Response 16 Oct 2021

Yuri Ishizaki, University of Miyazaki, 5200 Kihara, Kiyotake, Miyazaki, Japan

Dear Dr. Shashwati Sarkar Sen,

Thank you for your valuable comments about my case report. We respond to each suggestion as follows.

1) Restrict the number of words in the title. Too many medical terms are used.

As suggested by the reviewer, we shorten the title to "A Case of Encephalopathy Presenting the Lentiform Fork Sign on MRI in a Diabetic Dialysis Patient".

2) Case Report: Correction - Arterial Blood Gas Analysis.

Thank you for pointing it out. We corrected "Atrial blood gas" to "Arterial blood gas analysis".

3) Mention the Glasgow Coma Score.

We mentioned the Glasgow Coma Scale Score of E3V4M6 in the first line of the case report section.

4) DUS may have a subacute presentation. Yoshiko Nishimura *et al.* have reported a case of Diabetic Uremic Syndrome where the clinical features developed over 3 months. In your case, ME seems to be the primary diagnosis and DUS may be considered as a differential diagnosis rather than a contributory factor.

Thank you for your comment. In our case, there was not enough evidence to diagnose ME. The first reason was the thiamin level was not decreased, even though metformin may induce thiamin deficiency. (We added serum thiamin value in the part of the case

presentation.) Furthermore, thiamin deficiency can be caused by malnutrition and loss of water-soluble vitamins in the hemodialysis progression, but the patient did not have the symptoms of weight loss and seemed not to be undernourished. Secondly, the level of metabolic (lactic) acidosis on admission was also much mild not so high. Thirdly, as shown in Fig. 2, although the patient had had sluggish speaking and dysarthria and these findings had been gradually worsening six months before starting taking metformin, the relatively rapid-onset gait disturbance, severe dysarthria, and consciousness disturbance had appeared ten days before admission, which was a subacute progression. We could say that it was difficult to distinguish between ME and DUS, just considering the appearance of the findings. That is why we cannot necessarily diagnose ME, and we listed the two differential diagnoses, ME and/or DUS.

We added the following sentences in the Discussion section:

According to the previous reports, hemodialysis patients are at risk for thiamin deficiency which is induced to encephalopathy, because they are in the condition of malnutrition and tend to lose water-soluble vitamins in the hemodialysis procedure [16, 17]. Furthermore, thiamin deficiency may be a possible mechanism in metformin-induced encephalopathy [18]. In our case, the thiamin level was not decreased and severe lactic acidosis was not observed. In addition to these, the occurrence of gait disturbance, severe dysarthria, and consciousness disturbance was subacute even though sluggish speaking and dysarthria had been gradually worsening six months before starting taking metformin as shown in Fig.2, and the patient was neither malnutrition nor weight loss. That is why it was not necessarily ME.

References

We also read the two references which you indicated. According to Reference #1, thiamine must be a key to diagnose Metformin-induced encephalopathy. In the part of that we showed the thiamin level of our case, we quoted reference #1. On the other hand, we did not add reference #2 because it is written in Japanese and we thought that reader cannot understand it well.

Furthermore, we quoted two more references to mention that our case is not necessarily ME in the perspective of thiamin level in hemodialysis patients (Szu-Chun H et al, AJKD, 2001).

Sincerely yours,

Yuri Ishizaki

Competing Interests: None

The benefits of publishing with F1000Research:

- Your article is published within days, with no editorial bias
- You can publish traditional articles, null/negative results, case reports, data notes and more
- The peer review process is transparent and collaborative
- Your article is indexed in PubMed after passing peer review
- Dedicated customer support at every stage

For pre-submission enquiries, contact research@f1000.com

F1000Research