

Short Communication

## Effects of cadmium exposure on Iberian ribbed newt (*Pleurodeles waltl*) testes

Ayano Hirako<sup>1</sup>, Yuki Takeoka<sup>1</sup>, Toshinori Hayashi<sup>2</sup>, Takashi Takeuchi<sup>2</sup>, Satoshi Furukawa<sup>3</sup>, and Akihiko Sugiyama<sup>1\*</sup>

<sup>1</sup> Joint Department of Veterinary Medicine, Faculty of Agriculture, Tottori University, Minami 4-101 Koyama-cho, Tottori, Tottori 680-8553, Japan

<sup>2</sup> Division of Biosignaling, Department of Biomedical Sciences, School of Life Science, Faculty of Medicine, Tottori University, Yonago-shi, Tottori 683-8503, Japan

<sup>3</sup> Toxicology and Environmental Science Department, Biological Research Laboratories, Nissan Chemical Industries, Ltd., 1470 Shiraoka, Shiraoka-shi, Saitama 349-0294, Japan

**Abstract:** To characterize the histomorphologic effects of cadmium on adult newt testes, male Iberian ribbed newts (6 months post-hatching) were intraperitoneally exposed to a single dose of 50 mg/kg of cadmium, with histologic analysis of the testes at 24, 48, 72, and 96 h. Beginning 24 h after cadmium exposure, apoptosis of spermatogonia and spermatocytes was observed, and congestion was observed in the interstitial vessels of the testes. Throughout the experimental period, the rates of pyknotic cells and TUNEL and cleaved caspase-3 positivity were significantly higher in the spermatogonia and spermatocytes of cadmium-treated newts compared with control newts. There were no significant differences between cadmium-treated and control newts in phospho-histone H3 positivity in the spermatogonia and spermatocytes. These results suggest that spermatogonia and spermatocytes in adult Iberian ribbed newts are highly sensitive to cadmium. This is the first report of the histomorphologic characteristics of cadmium-induced testicular dysfunction in newts. (DOI: 10.1293/tox.2017-0032; J Toxicol Pathol 2017; 30: 345–350)

**Key words:** apoptosis, cadmium, congestion, Iberian ribbed newt, testes

Cadmium is a toxic environmental and industrial pollutant<sup>1–3</sup>. Cadmium enters the environment from anthropogenic sources such as paints, fertilizers, plastic stabilizers, plating, metal smelting, battery manufacturing, and mining<sup>1–3</sup>. Several organs, such as the kidney and liver, are affected by cadmium, and the testes are exceedingly sensitive<sup>4</sup>. In the testes, cadmium induces apoptosis and necrosis of germ cells, decreases in sperm number and motility, endothelial cell damage, and congestion of testicular blood vessels, with edema and hemorrhage<sup>4</sup>. These cadmium-induced testicular manifestations are associated with distortion of the blood-testis barrier and oxidative stress<sup>4</sup>. Previous studies reported that cadmium induces testicular dysfunction in a variety of mammalian and bird species, including mice, rats, hamsters, rabbits, dogs, and mallard ducks<sup>5–12</sup>.

As a result of runoff, aquatic ecosystems are the ter-

restrial receptacle of land-based chemicals<sup>13</sup>; therefore, it is assumed that compared with terrestrial vertebrates, aquatic vertebrates are more readily affected by exposure to chemicals containing metals such as cadmium. Nevertheless, only a few histopathologic studies of cadmium-induced testicular dysfunction in amphibian species have been published<sup>14, 15</sup>. In the testes of *Rhinella arenarum*, injection of 5 mg/kg of cadmium into the dorsal lymphatic sac daily for 15 days caused necrosis and apoptosis of germ cells and enlargement of the lumen of the interstitial vessels<sup>14</sup>. In the testes of Chinese fire-bellied newts exposed subcutaneously to 50 mg/kg of cadmium for 36 h, increases in the number of TUNEL-positive cells and increases in caspase-3 gene expression and enzyme activity were observed<sup>15</sup>. However, there are no reports describing the histomorphologic effects of cadmium on newt testes. Therefore, the histomorphologic characteristics of cadmium-induced testicular dysfunction, such as the expanse and distribution of damaged germ cells and the presence and degree of interstitial lesions, and their temporal changes in newts remain unclear. Therefore, in the present study, we examined the temporal changes in various histomorphologic characteristics in the testes of adult male newts exposed to cadmium.

Iberian ribbed newts (*Pleurodeles waltl*) were originally purchased from an animal handling company (Tao, Chiba, Japan). The animals used in the present study were

Received: 19 May 2017, Accepted: 5 July 2017

Published online in J-STAGE: 23 July 2017

\*Corresponding author: A Sugiyama

(e-mail: sugiyama@muses.tottori-u.ac.jp)

©2017 The Japanese Society of Toxicologic Pathology

This is an open-access article distributed under the terms of the Creative Commons Attribution Non-Commercial No Derivatives

(by-nc-nd) License. (CC-BY-NC-ND 4.0: <https://creativecommons.org/licenses/by-nc-nd/4.0/>).



raised in our laboratory from the originally purchased newts. Male Iberian ribbed newts (6 months post-hatching) were maintained at 25–26°C in a recirculating aquaculture system equipped with carbon filtration and biofiltration. The photoperiod was adjusted to a 14:10 hour (light:dark) cycle. The present experiments were performed following the guidelines of the Animal Research Committee of Tottori University.

A total of 32 newts were divided into two groups: a control group (n=16) and a cadmium-treated group (n=16). Cadmium chloride (Wako Pure Chemical Industries, Osaka, Japan) was dissolved in saline. The newts received intraperitoneal (i.p.) injections of cadmium (50 mg/kg body weight) or saline (control). The decision to use this concentration was based on results of a preliminary study in which exposure to 5, 10, and 25 mg/kg of cadmium induced few histopathologic changes in the testes, whereas exposure to 50 mg/kg caused stable pyknotic changes in the testes. No individual differences in the pyknotic rate were observed in the 50 mg/kg cadmium-treated group.

Testes samples were collected after euthanasia by administration of an overdose of pentobarbiturate (100 mg/kg, i.p.) at 24, 48, 72, or 96 h after cadmium exposure. The testes were fixed in Bouin's fluid overnight, refixed in neutral buffered formalin, embedded in paraffin, cut into sections, and routinely stained with hematoxylin-eosin.

Testicular cells with fragmented DNA were detected using a terminal deoxynucleotidyl-transferase (TdT)-mediated deoxyuridine triphosphate-digoxigenin (dUTP) nick-end labeling (TUNEL) assay, which was performed using a TACS 2 TdT-DAB *In Situ* Apoptosis Detection Kit (Trevigen, Inc., Gaithersburg, MD, USA). The rate of TUNEL positivity was calculated as the percentage of TUNEL-positive cells among the total number of spermatogonia and spermatocytes.

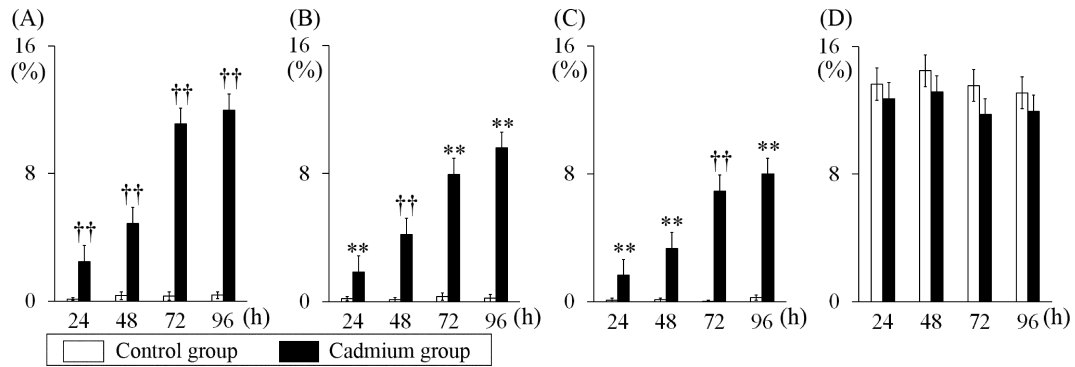
Immunohistochemical staining was carried out using a labeled-polymer method with Histofine Simple Stain MAX-PO (R) (Nichirei, Tokyo, Japan). For cleaved caspase-3 antigen retrieval, tissue sections were immersed in citrate buffer (pH 6.0) (Dako, Glostrup, Denmark) and autoclaved for 15 min at 121°C. For detection of phospho-histone H3, tissue sections were immersed in citrate buffer (pH 6.0) (Dako) and microwaved for 15 min. Histone H3, a protein involved in chromatin structure, is phosphorylated at serine 10 during chromatin condensation in mitosis<sup>16</sup>; therefore, phospho-histone H3 is recognized as a mitosis-specific marker<sup>17, 18</sup>. Endogenous peroxidase activity was quenched by immersing the sections in 3% hydrogen peroxide in methanol for 15 min. Sections were incubated with cleaved caspase-3 rabbit polyclonal antibody (1:50 dilution; Cell Signaling Technology, Inc., Danvers, MA, USA) for 30 min at room temperature. Sections were incubated with phospho-histone H3 rabbit monoclonal antibody (1:1,500 dilution; Abcam, Tokyo, Japan) for 30 min at room temperature. The sections were then treated with Histofine Simple Stain MAX-PO (R) (Nichirei) for 30 min at room temperature. After exposure to a solution of 3,3'-diaminobenzidine containing hydrogen

peroxide (Nichirei) to facilitate a peroxidase color reaction, the sections were counterstained with Mayer's hematoxylin. The rates of cleaved caspase-3 and phospho-histone H3 positivity were calculated as the percentage of cleaved caspase-3-positive and phospho-histone H3-positive cells, respectively, among the total number of spermatogonia and spermatocytes.

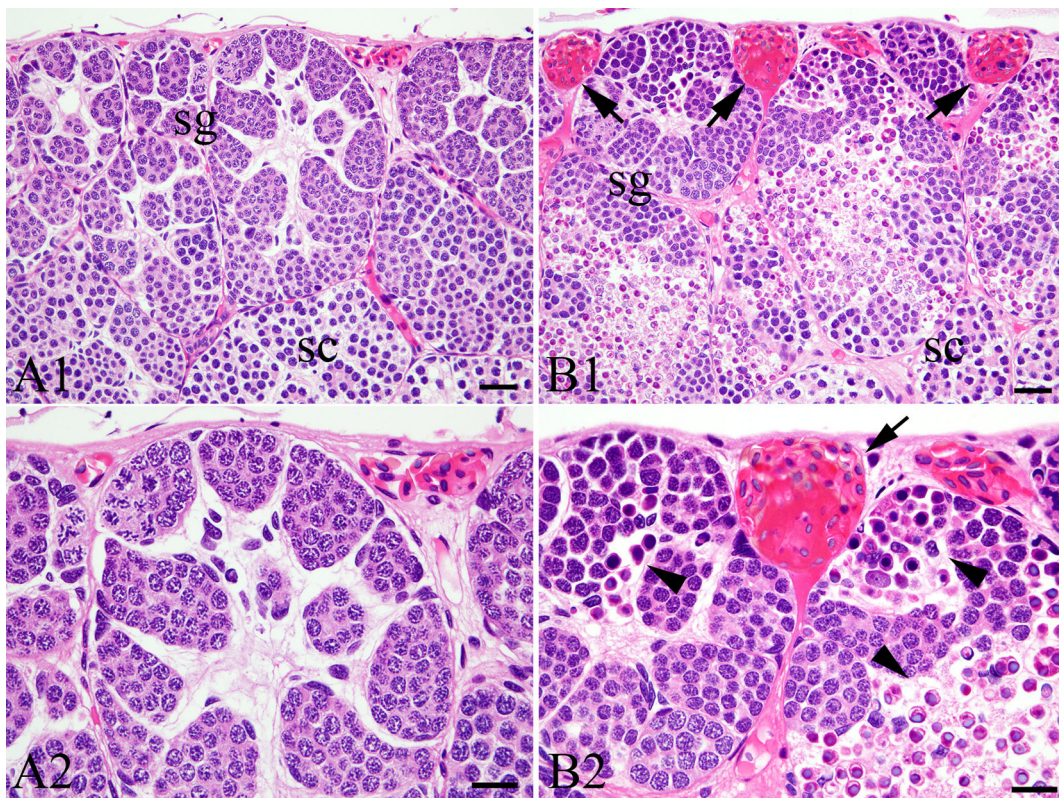
All values are expressed as the mean  $\pm$  standard error. Comparisons of differences between the control and cadmium-treated groups were analyzed using Excel-Toukei 2015 statistical software (SSRI Co., Ltd., Tokyo, Japan). The data from two groups were analyzed using an *F*-test. When variances were homogenous, Student's *t*-test was performed. Welch's *t*-test was performed when variances were not homogeneous ( $P < 0.05$ ). *P* values of  $< 0.05$  or  $< 0.01$  were considered indicative of statistical significance.

In both the control and cadmium-treated groups, all newts survived, and none exhibited behavioral disorders or abnormal appearance throughout the entire experimental period. A few pyknotic cells were observed among the spermatogonia and spermatocytes within the testes in the control groups throughout the experiment (Fig. 1 and 2). In the cadmium-treated group, pyknotic cells among the spermatogonia and spermatocytes were observed at 24 h after cadmium treatment (Fig. 1). At 72 and 96 h, numerous pyknotic cells were observed among the spermatogonia and spermatocytes, and the structure of cysts collapsed in the testes of the cadmium-treated group (Fig. 1 and 2). These pyknotic cells were positive for TUNEL staining and anti-cleaved caspase-3 antibody (Fig. 3 and 4). Throughout the experimental period, the rates of pyknotic cells and TUNEL and cleaved caspase-3 positivity in the spermatogonia and spermatocytes of cadmium-treated newts were significantly higher than in control newts (Fig. 1). In addition, almost equal numbers of phospho-histone H3-positive cells were present among the spermatogonia and spermatocytes in both groups (Fig. 5). No significant difference in phospho-histone H3-positive rate in the spermatogonia and spermatocytes was observed (Fig 1). Throughout the entire experimental period, few histopathological changes were observed in the round spermatids or elongating spermatids of the cadmium-treated group (Fig. 6).

In the present study, i.p. injection of 50 mg/kg of cadmium induced an increase in the number of pyknotic cells among the spermatogonia and spermatocytes in adult male Iberian ribbed newt testes. These pyknotic cells were positive for TUNEL staining and cleaved caspase-3. Cleavage of caspase-3 is associated with induction of apoptosis; therefore, cleaved caspase-3 is recognized as an apoptosis marker<sup>9</sup>. Our results thus indicate that the cadmium-induced pyknotic changes in the spermatogonia and spermatocytes of Iberian ribbed newt testes were caused by apoptosis. Mitochondria are considered to be the primary target of cadmium-induced apoptosis<sup>20</sup>. Other studies demonstrated that in the testes of frogs, rats, and mice, cadmium induces upregulation of Bax and caspase-3 expression and downregulation of Bcl-2 expression<sup>9, 10, 21</sup>. In rat testes, cadmium-induced



**Fig. 1.** Changes over time in the rates of pyknotic cells (A), TUNEL positivity (B), cleaved caspase-3 positivity (C), and phospho-histone H3 positivity (D) in the spermatogonia and spermatocytes of newts. Values are expressed as the mean  $\pm$  SE. \*\*Significantly different from the control group at  $P < 0.01$  (Student's *t*-test). ††Significantly different from the control group at  $P < 0.01$  (Welch's *t*-test).

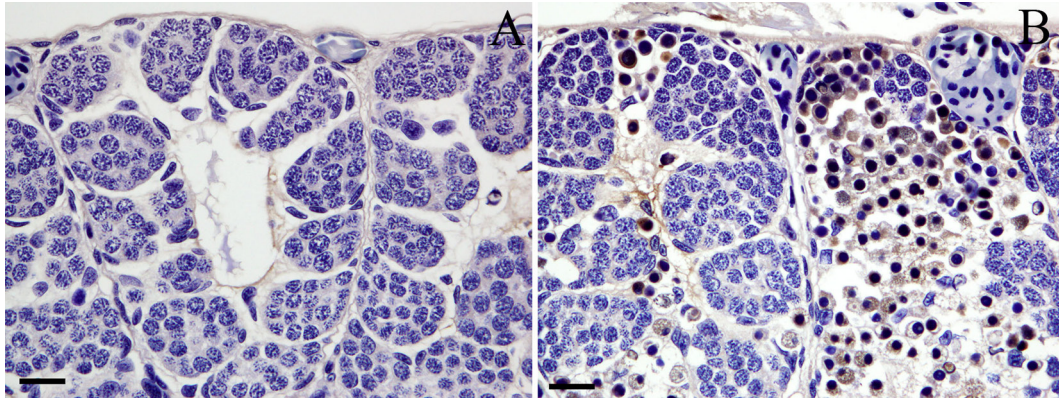


**Fig. 2.** Pyknotic changes in the spermatogonia and spermatocytes 96 h after cadmium treatment. (A) Control group. (B) Cadmium-treated group. Abbreviations: sg, spermatogonia; sc, spermatocytes. Bar = 30  $\mu$ m. 1. Low-power view of newt testes. Bar = 50  $\mu$ m. 2. High-power view of newt testes. Bar = 30  $\mu$ m. Arrows indicate congestion. Arrowheads indicate pyknotic cells.

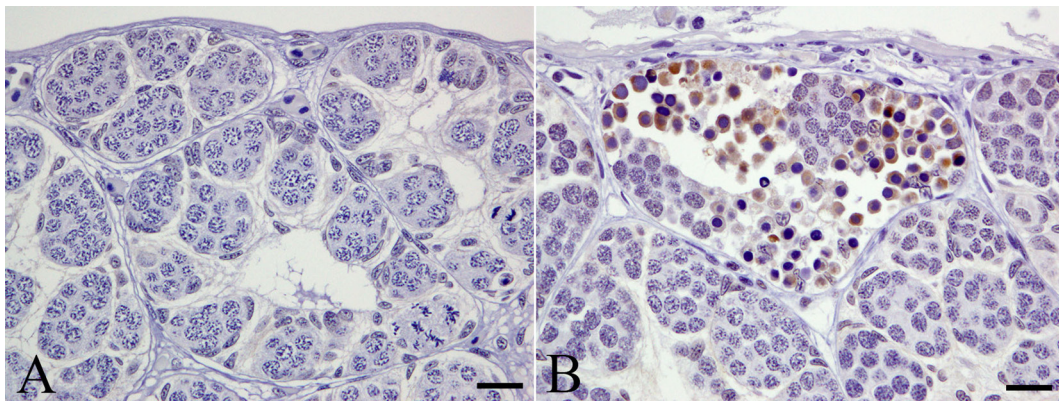
apoptosis is mediated by the translocation of apoptosis inducing factor from the mitochondria to the nucleus<sup>22</sup>.

In newts, the testis can be divided into four zones, each containing spermatogenic cells at the same differentiation stage of spermatogenesis: the spermatogonial stage, spermatocyte stage, round spermatid stage, and elongating spermatid stage<sup>23</sup>. The lobules formed at the cephalic region gradually assume a more caudal position as the cells mature<sup>23</sup>. Therefore, it is easy to distinguish the germ cell

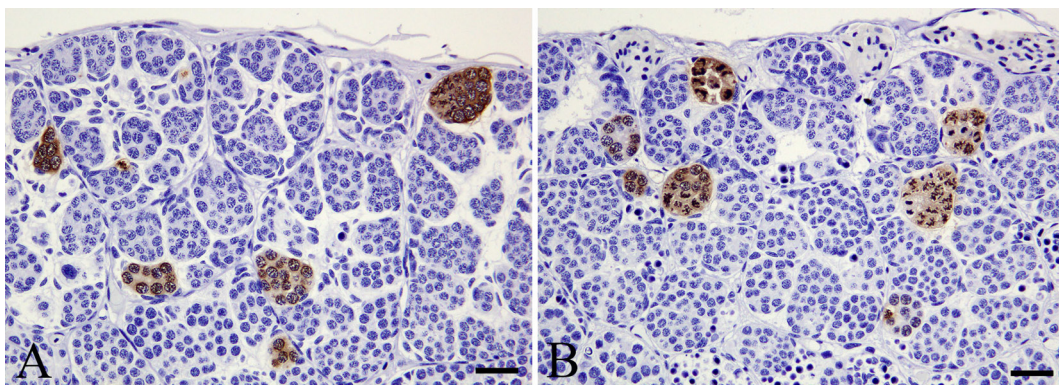
differentiation stage, which is highly sensitive to chemicals, by histomorphologic examinations using hematoxylin-eosin staining. In the present study, i.p. injection of 50 mg/kg of cadmium induced apoptosis of the spermatogonia and spermatocytes in Iberian ribbed newts. The observed histopathologic findings in the testes of newts exposed to cadmium were similar to those reported for testes of several frogs, such as *Bufo melanostictus* and *Rana hexadactyla* Lesson<sup>24, 25</sup>, and fish, such as *Oryzias latipes*<sup>26</sup>.



**Fig. 3.** TUNEL-positive cells in the spermatogonia and spermatocytes 96 h after cadmium treatment. (A) Control group. (B) Cadmium-treated group. Bar = 30 µm.



**Fig. 4.** Cleaved caspase-3-positive cells in the spermatogonia and spermatocytes 96 h after cadmium treatment. (A) Control group. (B) Cadmium-treated group. Bar = 30 µm.

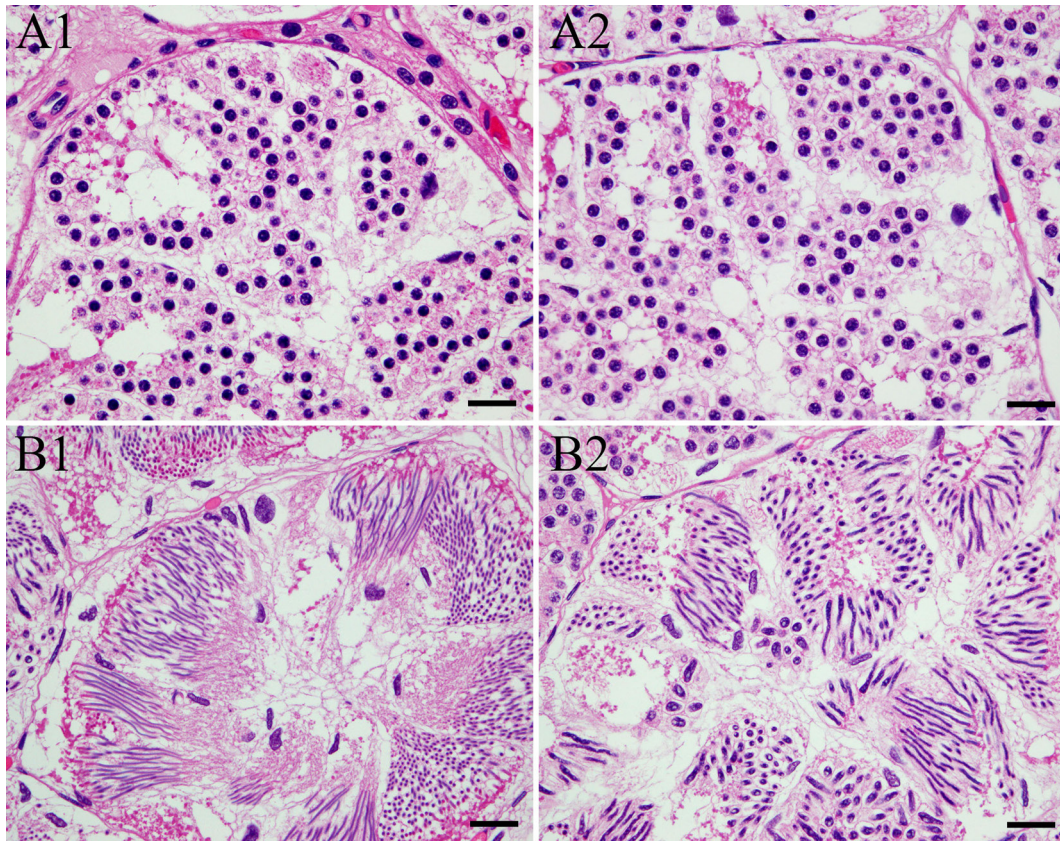


**Fig. 5.** Phospho-histone H3-positive cells in the spermatogonia and spermatocytes 96 h after cadmium treatment. (A) Control group. (B) Cadmium-treated group. Bar = 30 µm.

In the present study, congestion was also observed in the testes of Iberian ribbed newts exposed to cadmium. Previous studies demonstrated congestion of interstitial blood vessels in the testes of frogs, fish, and rats exposed to cadmium<sup>13, 14, 27, 28</sup>. The congestion is speculated to be associated

with disruption of the vascular system<sup>2, 29</sup>; however, details of the pathogenesis of cadmium-induced congestion remain unclear.

The results of the present study revealed that a 50 mg/kg exposure to cadmium induces significant apoptosis of



**Fig. 6.** Histopathological findings in the round spermatids (A) and elongating spermatids (B) of newts 96 h after cadmium treatment. (1) Control group. (2) Cadmium-treated group. Bar = 30  $\mu\text{m}$ .

spermatogonia and spermatocytes in the testes of adult Iberian ribbed newts, indicating that germ cells in these differentiation stages are highly sensitive to cadmium. The histopathologic findings of the present study are similar to those reported for cadmium-exposed frogs, such as *B. melanostictus* and *R. hexadactyla* Lesson, and fish, such as *O. latipes*<sup>24–26</sup>. To our knowledge, this is the first report of the histomorphologic characteristics of cadmium-induced testicular dysfunction in newts.

**Acknowledgments:** This work was supported by JSPS KAKENHI Grant Numbers JP16H04794, JP16H01254, and JP16K08467.

**Disclosure of Potential Conflicts of Interest:** We have no conflicts of interest to be declared.

## References

1. Yang JM, Arnush M, Chen QY, Wu XD, Pang B, and Jiang XZ. Cadmium-induced damage to primary cultures of rat Leydig cells. *Reprod Toxicol.* **17**: 553–560. 2003. [[Medline](#)] [[CrossRef](#)]
2. Siu ER, Mruk DD, Porto CS, and Cheng CY. Cadmium-induced testicular injury. *Toxicol Appl Pharmacol.* **238**: 240–249. 2009. [[Medline](#)] [[CrossRef](#)]
3. Capaldo A, Gay F, Scudiero R, Trinchella F, Caputo I, Lepretti M, Marabotti A, Esposito C, and Laforgia V. Histological changes, apoptosis and metallothionein levels in *Triturus carnifex* (Amphibia, Urodela) exposed to environmental cadmium concentrations. *Aquat Toxicol.* **173**: 63–73. 2016. [[Medline](#)] [[CrossRef](#)]
4. Järup L, and Akesson A. Current status of cadmium as an environmental health problem. *Toxicol Appl Pharmacol.* **238**: 201–208. 2009. [[Medline](#)] [[CrossRef](#)]
5. White DH, Finley MT, and Ferrell JF. Histopathologic effects of dietary cadmium on kidneys and testes of mallard ducks. *J Toxicol Environ Health.* **4**: 551–558. 1978. [[Medline](#)] [[CrossRef](#)]
6. Nagy F. Cadmium-induced alterations in the Siberian hamster epididymis. *Arch Androl.* **15**: 91–104. 1985. [[Medline](#)] [[CrossRef](#)]
7. Foote RH. Cadmium affects testes and semen of rabbits exposed before and after puberty. *Reprod Toxicol.* **13**: 269–277. 1999. [[Medline](#)] [[CrossRef](#)]
8. Aoyagi T, Ishikawa H, Miyaji K, Hayakawa K, and Hata M. Cadmium-induced testicular damage in a rat model of subchronic intoxication. *Reprod Med Biol.* **1**: 59–63. 2002. [[CrossRef](#)]
9. Al-Azemi M, Omu FE, Kehinde EO, Anim JT, Oriowo MA, and Omu AE. Lithium protects against toxic effects of cadmium in the rat testes. *J Assist Reprod Genet.* **27**: 469–476. 2010. [[Medline](#)] [[CrossRef](#)]
10. Bu T, Mi Y, Zeng W, and Zhang C. Protective effect of quer-

- ctin on cadmium-induced oxidative toxicity on germ cells in male mice. *Anat Rec (Hoboken)*. **294**: 520–526. 2011. [[Medline](#)] [[CrossRef](#)]
11. Ogawa Y, Itoh M, Hirai S, Suna S, Naito M, Qu N, Terayama H, Ikeda A, Miyaso H, Matsuno Y, Komiyama M, and Mori C. Cadmium exposure increases susceptibility to testicular autoimmunity in mice. *J Appl Toxicol*. **33**: 652–660. 2013. [[Medline](#)] [[CrossRef](#)]
  12. Niknafs B, Salehnia M, and Kamkar M. Induction and determination of apoptotic and necrotic cell death by cadmium chloride in testis tissue of mouse. *J Reprod Infertil*. **16**: 24–29. 2015. [[Medline](#)]
  13. Vergilio CS, Moreira RV, Carvalho CE, and Melo EJ. Evolution of cadmium effects in the testis and sperm of the tropical fish *Gymnotus carapo*. *Tissue Cell*. **47**: 132–139. 2015. [[Medline](#)] [[CrossRef](#)]
  14. Medina MF, Cosci A, Cisint S, Crespo CA, Ramos I, Iruzubietta Villagra AL, and Fernández SN. Histopathological and biological studies of the effect of cadmium on *Rhinella arenarum* gonads. *Tissue Cell*. **44**: 418–426. 2012. [[Medline](#)] [[CrossRef](#)]
  15. Wang DH, Hu JR, Wang LY, Hu YJ, Tan FQ, Zhou H, Shao JZ, and Yang WX. The apoptotic function analysis of p53, Apaf1, Caspase3 and Caspase7 during the spermatogenesis of the Chinese fire-bellied newt *Cynops orientalis*. *PLoS One*. **7**: e39920. 2012. [[Medline](#)] [[CrossRef](#)]
  16. Hendzel MJ, Wei Y, Mancini MA, Van Hooser A, Ranalli T, Brinkley BR, Bazett-Jones DP, and Allis CD. Mitosis-specific phosphorylation of histone H3 initiates primarily within pericentromeric heterochromatin during G2 and spreads in an ordered fashion coincident with mitotic chromosome condensation. *Chromosoma*. **106**: 348–360. 1997. [[Medline](#)] [[CrossRef](#)]
  17. Duregon E, Molinaro L, Volante M, Ventura L, Righi L, Bolla S, Terzolo M, Sapino A, and Papotti MG. Comparative diagnostic and prognostic performances of the hematoxylin-eosin and phospho-histone H3 mitotic count and Ki-67 index in adrenocortical carcinoma. *Mod Pathol*. **27**: 1246–1254. 2014. [[Medline](#)] [[CrossRef](#)]
  18. Veras E, Malpica A, Deavers MT, and Silva EG. Mitosis-specific marker phospho-histone H3 in the assessment of mitotic index in uterine smooth muscle tumors: a pilot study. *Int J Gynecol Pathol*. **28**: 316–321. 2009. [[Medline](#)] [[CrossRef](#)]
  19. Gown AM, and Willingham MC. Improved detection of apoptotic cells in archival paraffin sections: immunohistochemistry using antibodies to cleaved caspase 3. *J Histochem Cytochem*. **50**: 449–454. 2002. [[Medline](#)] [[CrossRef](#)]
  20. Pulido MD, and Parrish AR. Metal-induced apoptosis: mechanisms. *Mutat Res*. **533**: 227–241. 2003. [[Medline](#)] [[CrossRef](#)]
  21. Zhang H, Cai C, Shi C, Cao H, Han Z, and Jia X. Cadmium-induced oxidative stress and apoptosis in the testes of frog *Rana limnocharis*. *Aquat Toxicol*. **122–123**: 67–74. 2012. [[Medline](#)] [[CrossRef](#)]
  22. Kim J, and Soh J. Cadmium-induced apoptosis is mediated by the translocation of AIF to the nucleus in rat testes. *Toxicol Lett*. **188**: 45–51. 2009. [[Medline](#)] [[CrossRef](#)]
  23. Abé S. Hormonal control of meiosis initiation in the testis from Japanese newt, *Cynops pyrrhogaster*. *Zool Sci*. **21**: 691–704. 2004. [[Medline](#)] [[CrossRef](#)]
  24. Biswas NM, Chanda S, Ghosh A, and Chakraborty J. Effect of cadmium on spermatogenesis in toad (*Bufo melanostictus*). *Endokrinologie*. **68**: 349–352. 1976. [[Medline](#)]
  25. Kasinathan S, Veeraraghavan K, and Ramakrishnan S. Effect of cadmium on the spermatogenesis of *Rana hexadactyla* Lesson. *Acta Morphol Hung*. **35**: 183–187. 1987. [[Medline](#)]
  26. Hirako A, Takeoka Y, Furukawa S, and Sugiyama A. Effects of cadmium exposure on medaka (*Oryzias latipes*) testes. *J Toxicol Pathol*. **30**: 255–260. 2017. [[CrossRef](#)]
  27. Alkhedaide A, Alshehri ZS, Sabry A, Abdel-Ghaffar T, Soliman MM, and Attia H. Protective effect of grape seed extract against cadmium-induced testicular dysfunction. *Mol Med Rep*. **13**: 3101–3109. 2016. [[Medline](#)]
  28. Adamkovicova M, Toman R, Cabaj M, Massanyi P, Martiniakova M, Omelka R, Krajevicova V, and Duranova H. Effects of subchronic exposure to cadmium and diazinon on testis and epididymis in rats. *Sci World J*. **2014**: 632581. 2014. [[Medline](#)] [[CrossRef](#)]
  29. Margettová E, Margetta M, and Legáth J. Toxic effects of cadmium on testis of birds and mammals: a review. *Anim Reprod Sci*. **155**: 1–10. 2015. [[Medline](#)] [[CrossRef](#)]